

CHARLES UNIVERSITY IN PRAGUE
FACULTY OF PHYSICAL EDUCATION AND SPORT
Department of physiotherapy

**Case study of a physiotherapy treatment of patient with
Arthritis of the wrist joints**

Bachelor Thesis

Supervisor:

Mgr. Lenka Satrapová, PhD

Author:

Achilleas Liapis

Prague, April 2015

Abstract

Title: Case study of a physiotherapy treatment of patient with Arthritis of the wrist joints.

Název: Kazuistika fyzioterapeutické péče o pacienta s diagnózou artróza zápěstních kloubů

Aim

The aim of my bachelor thesis is to analyze the diagnosis of my patient and find a proper therapeutic plan for his health care and to prevent any further complication. Moreover I will be able to understand the function and the structure of wrist joint.

Summary

My bachelor thesis is divided into two main parts. The first part is called general part and I mention a brief description of the anatomy, kinesiology and biomechanics of the wrist joint. Etiopathogenesis and proper therapeutic plan is mentioned below. The second part which is the practical (special) part give us all the proper information about the patient's anamnesis, all the examination that where performed and also my therapeutic plan that I proceed to my patient for six days by using special strengthening exercises, Propriomed, myorelaxation techniques and modalities like magnetotherapy.

Results

After six sessions the situation of my patient was improved. The main goals have been accomplished. The pain was decrease and there was greater ROM of the wrist joint. The patient was able in the end to be active and confident without the sign of pain which was the main problem.

Key words: wrist, arthritis, physiotherapy, range of motion, exercise

Declaration

I declare that this bachelor thesis was managed by me and under the instructions of Mgr. Satrapova, PhD. My clinical practice took place at U.V.N (Ústřední Vojenská Nemocnice) in Prague from 12/01/2015 until 23/01/2015 under the supervising of Mgr. Romana Kozderková.

The examinations and the therapeutic procedures that I provided were based on my knowledge that I gained from Charles University in Prague in physiotherapy department. In the end of my bachelor thesis are mentioned all the references that I proceed.

Finally my patient and I were assigned a proposed informed approval and he was informed for all the examinations and therapies that will be used on him.

Achilleas Liapis

April 2015, Prague

Acknowledgment

I would like to express my whole-hearted thanks to my family for the support that they offer me during the stressful process on examination period.

Moreover I would like also to give my most grateful thanks to my supervisor Mgr. Satrapova, PhD for her valuable help cooperation and advises that she offered me to create my bachelor thesis include the guidance of Mgr. Romana Kozderková during my clinical practice at U.V.N hospital. In addition I would like to thank all of my professors for their knowledge and help during the years of my studies.

Finally I would like to express my gratitude to my closest friends in Prague, Konstantinos Falidas, Konstantinos Varotsis and Dimitrios Millas for their friendship, support and help during my studies.

Contents

1. Preface.....	1
2. General Part	2
2.1 Anatomy of the wrist joint.....	2
2.1.2 Bones of wrist joint	3
2.1.3 Ligaments of wrist joint.....	3
2.1.4 Muscles of the wrist joint	5
2.1.5 Blood supply related to wrist.....	14
2.2 Kinesiology of wrist joint	17
2.3 Biomechanics of wrist joint.....	18
2.4 Arthrosis of the wrist joints	20
2.4.2 Etiopathogenesis.....	21
2.4.3 Clinical image.....	22
2.4.4 Diagnosis	22
2.5 Physiotherapists examinations.....	22
2.6 Treatment.....	25
3. Special Part (Case Study)	27
3.1. Methodology.....	27
3.2. Anamnesis	28
3.2.1. Present State	28
3.2.2. Personal Anamnesis.....	28
3.2.3. Family anamnesis	28
3.2.4. Operation Anamnesis	29
3.2.5. Medication	29
3.2.6. Allergy Anamnesis	29
3.2.7. Social Anamnesis	29
3.2.8. Occupation Anamnesis.....	29
3.2.9. Hobbies.....	29
3.2.10. Abuses	29
3.2.11. Previous Rehabilitation	29
3.2.12. Statement from the patient's medical documentation	30

3.2.13. Indication of rehabilitation	30
3.2.14. Differential Diagnosis	30
3.3. Initial Kinesiology Examination.....	30
3.3.1 Observation:	30
3.3.2 Posture evaluation in standing.....	31
Posterior view.....	31
Anterior view	31
Lateral view (right side)	32
Lateral view (left side).....	33
3.3.3 Dynamic examination.....	33
3.3.4 Anthropometric measurements of upper extremities.....	33
3.3.5 Range of motion examination according to Kendall	34
3.3.6 Muscle tone examination.....	36
3.3.7 Soft tissue examination according to Lewit	37
3.3.8 Muscle strength test according to Kendall	37
3.3.10 Joint play examination according to Lewit.....	40
3.3.11 Neurological examination	42
3.3.12 Conclusion of initial kinesiology examination.....	42
3.4 Short-term and long-term rehabilitation plan	43
3.4.1 Short-term rehabilitation plan.....	43
3.4.2 Long-term rehabilitation plan.....	44
3.4.3 Therapy proposal	44
3.5 Therapy progress	45
3.5.1. Session 1 st Monday on 12.1.2015.....	45
3.5.2. Session 2 nd Wednesday on 14.01.2015.....	47
3.5.3. Session 3 rd Friday on 16.01.2015	50
3.5.4. Session 4 th Monday 19.01.2015.....	52
3.5.5. Session 5 th Wednesday on 21.01.2015	55
3.5.6. Session 6 th Friday on 23.01.2015	57
3.6 Final Kinesiology Examination.....	60
3.6.1 Final Observation	60

3.6.2 Final Postural examination	60
Posterior view	60
Anterior view	61
Lateral view (right side)	61
Lateral view (left side).....	62
3.6.3 Final Dynamic examination	62
3.6.4 Final Anthropometric measurements of upper extremities	63
3.6.5 Final Range of motion examination according to Kendall.....	63
3.6.6 Final Muscle tone examination	65
3.6.7 Soft tissue examination according to Lewit	66
3.6.8 Muscle strength test according to Kendall	66
3.6.9 Final Muscle length examination according to Lewit	69
3.6.10 Final Joint play examination according to Lewit	69
3.6.11 Final Neurological examination	71
3.6.12 Conclusion of final kinesiology examination.....	71
3.7 Evaluation of the effect of the therapy	72
3.8 Prognosis	73
4. Conclusion.....	73
5. Bibliography	75
6. Supplements	78
6.1. Application for Ethics Board Review.....	79
6.2 INFORMOVANÝ SOUHLAS.....	79
6.3 List of tables	81
6.4 List of Figures.....	82
6.5 List of Abbreviation	83

1. Preface

My clinical practice took place at U.V.N (Ústřední Vojenská Nemocnice) for two weeks. It started on 12th of January until 23rd of January 2015. I met my patient with the diagnosis of Arthritis in wrist joints in the first day of my practice. There are hundreds of kinds of arthritis; most wrist pain is caused by just two types: osteoarthritis and rheumatoid arthritis. I find this topic very interesting because of the high proportion of this disease to people. Approximately 33% of people in the age of 45 will suffer from Arthritis (49% women and 42% on men).

My topic is analyzed in details in the next chapters and divided into two main parts. In the general part I described briefly the anatomy of wrist which includes the muscles, tendons, joints, bones, arteries and nerves. Important and also briefly information about the biomechanical point of view for wrist joint is mentioned after the anatomical part. Some general information about the anatomy of the neck were mentioned but I didn't want to analyze it because it wasn't the main problem of the patient but there is a possibility of some connection between wrist and neck problems due to compression of the nerves. Moreover in my bachelor thesis I mention the kinesiology of wrist and some information about the etiopathogenesis and how the clinical picture of the patient look like.

In the second and most important part, is the case study of the patient with arthrosis of wrist joint. All the proper information about the anamnesis of the patient, the examinations, therapeutic plan, conclusion and the evaluation of the effect of therapy are described in this chapter.

2. General Part

2.1 Anatomy of the wrist joint

Wrist: The anatomy of the wrist joint is excessively complex and maybe the most complex compare with the rest joints of the human body. Every hand consists by 27 distinct bones which give to the hand an incredible range and precision of motion. Moreover the bones give you the ability to manipulate objects in many different directions (Taylor, 2006).

The wrist joint is a synovial joint of the upper extremity, marking the area of transition between the hand and forearm. It is also known as radiocarpal joint also and is formed by:

- ✓ Distally – characterized the proximal row of carpal bones except the pisiform
- ✓ Proximally – characterized the distal part of radius and the articular disk which is located between the lunate bone and ulna (Jones, 2015).

The joint capsule is divided into outer layer which attaches the radius, ulna and the proximal row of carpal bones and the internal layer in which there is secretion of synovial fluid (fertilize the joint). Many muscles and ligaments are located in the wrist (Jones, 2015).

Furthermore it consists by joints and ligaments such as atlanto-occipital and atlantoaxial joints which are both synovial joints. The main function of the atlanto-occipital joint is flexion and extension of neck. On the other hand the atlantoaxial permits one to rotate the head from side to side (Netter, 2009).

There are some different between the cervical and lumbosacral vertebrae:

- ✓ There are foramina on each side
- ✓ Facet joints in the cervical spine have steeper angles
- ✓ “Joint of Luschka” prevents a disc rupture from directly pressing onto the nerve root. (Daniel, 2010).

2.1.2 Bones of wrist joint

Wrist: The wrist joint contains eight small bones which are called carpal bones and those bones are divided into two groups. The first one is called proximal row and consist by scaphoid, lunate and triquetrum. Moreover it connects the radius and ulna to the bones of the hand. The other group is called distal row and is made up of the trapezium, trapezoid, capitate, hamate and pisiform bones. (Lewis, Hamshere, Bucknill, 1970).

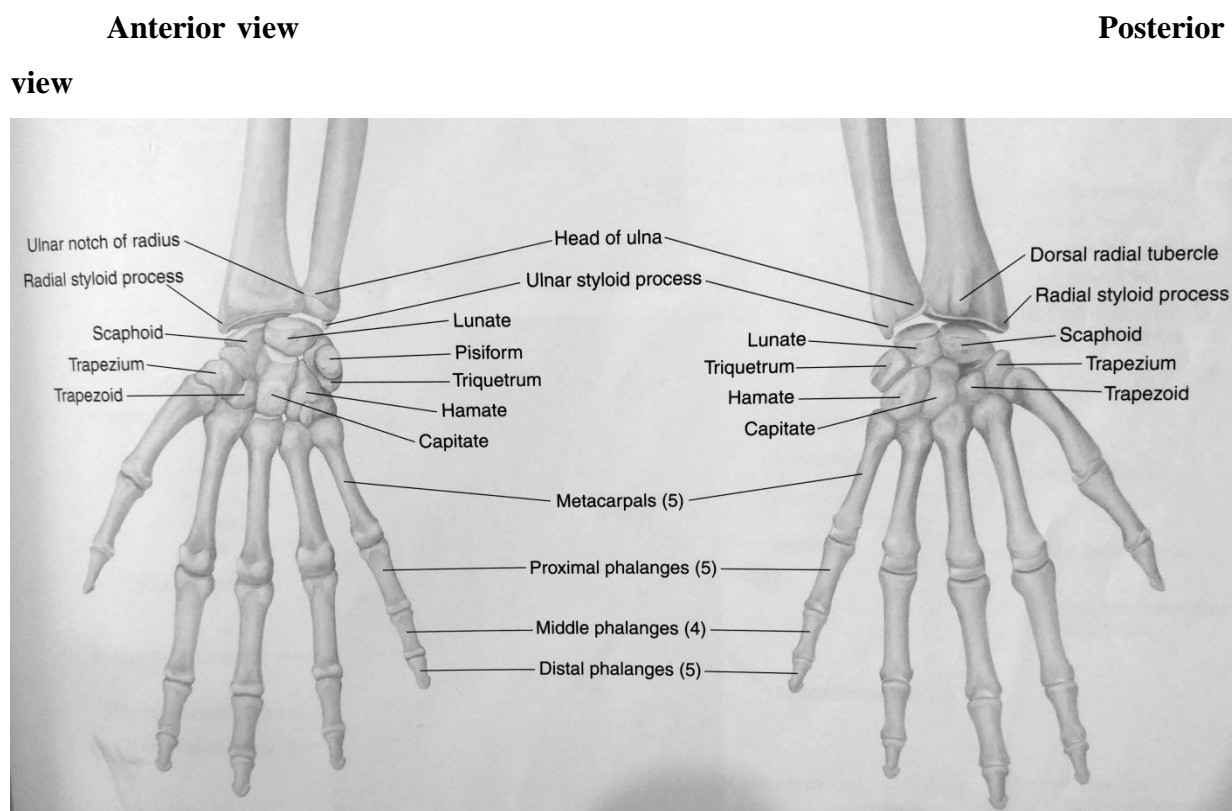


Figure 1 Skeleton of the Distal Upper Limb (Tank, 2009)

2.1.3 Ligaments of wrist joint

There are several ligaments in the wrist joint and some of those are:

- **Radial collateral:** attaches on radial styloid process to the scaphoid and trapezium and prevent excessive lateral joint displacement.

- **Ulnar collateral:** attaches on ulnar styloid process to the triquetrum and pisiform and prevent excessive lateral joint displacement.
- **Dorsal radiocarpal:** it passes from radius to both rows of carpal bones and is located in the posterior side of the hand. It used during pronation of the forearm and contributes to the stability of wrist.
- **Palmar radiocarpal:** it passes from radius to both rows of carpal bones and the function is to ensure that the hand follows the forearm during pronation and is located in the anterior side of the hand (Clemente, 2006).

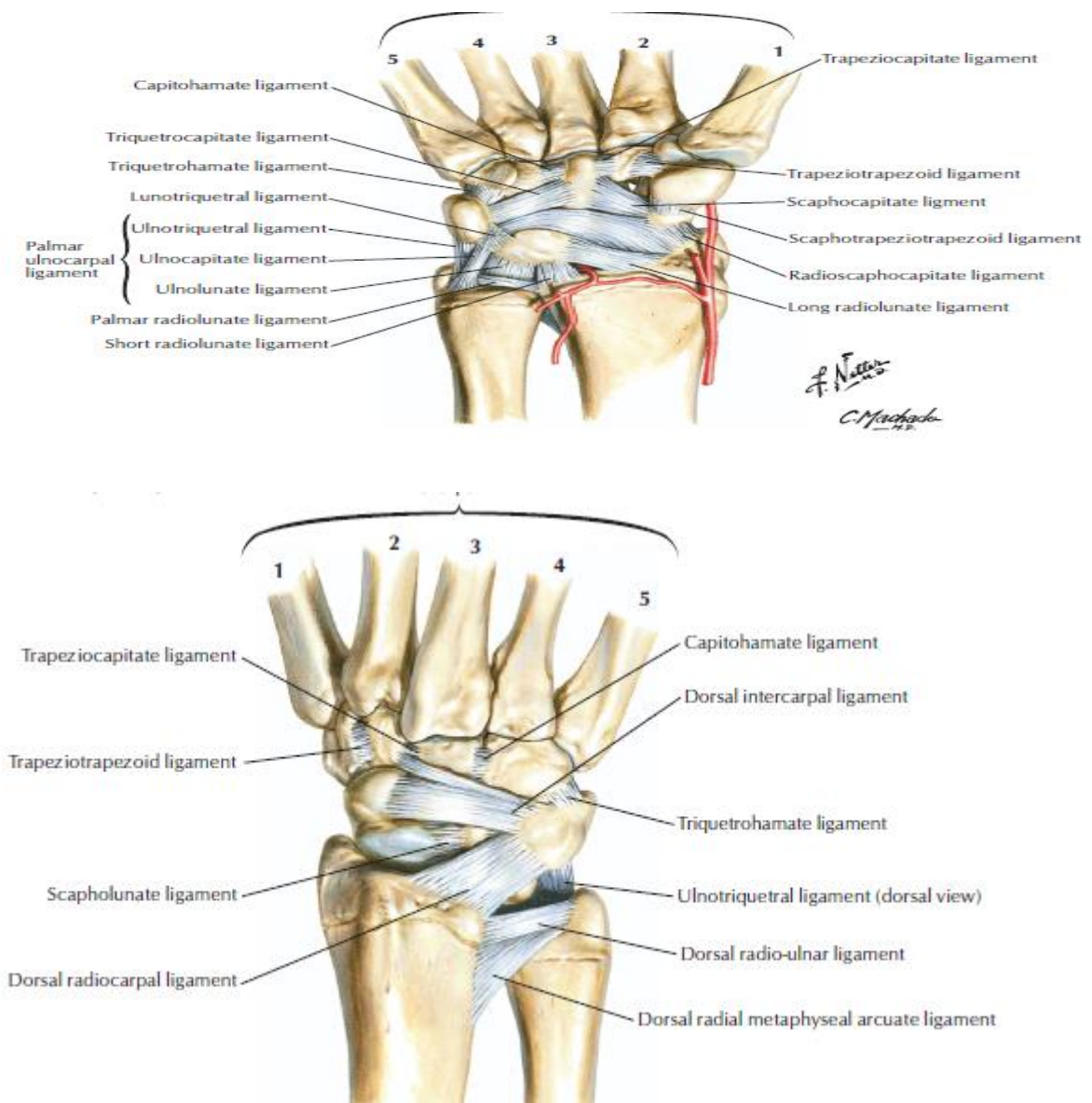


Figure 2 Ligaments of wrist in palmar and posterior view (Netter, 2014)

2.1.4 Muscles of the wrist joint

Wrist: In upper extremity and more specific in hand, wrist and forearm, there are more than 30 individual muscles to allow you perform any movement. Those muscles give you the ability to provide any movement with flexibility, extremely precise control and gripping strength which is necessary for gripping a ball in sports, writing etc. There are six flexor muscles in the palmar side of the forearm. Those muscles run through the wrist via tendons to insert into the bones of the wrist palm and fingers. The tendons of the flexor muscles and median nerve pass through carpal tunnel and with repetitive motion of flexor can lead to impinge the median nerve, pain, tingling (Tank, 2009).

Muscles	Origin	Insertion	Innervation	Function
Flexor carpi radialis	Common flexor tendon from the medial epicondyle of the humerus	Base of the second and third metacarpals	Median nerve	Flexes the wrist, abducts the hand
Flexor carpi ulnaris	Medial border of olecranon & upper 2/3 of posterior border of ulna	Pisiform, hook of hamate and base of 5 th metacarpal	Ulnar nerve	Flexes wrist, adducts hand
Flexor digitorum profundus	Posterior border of the ulna, proximal two-thirds of medial border of ulna, interosseous membrane	Base of the distal phalanx of digits 2-5	Median nerve, ulnar nerve	Flexes the metacarpophalangeal, proximal interphalangeal and distal interphalangeal joints

Flexor pollicis brevis	Flexor retinaculum, trapezium	Proximal phalanx of the 1 st digit	Recurrent branch of the median nerve	Flexes the carpometacarpal and metacarpophalangeal joints of the thumb
Flexor digitorum superficialis	Humeroulnar head: common flexor tendon, radial head: middle 1/3 of radius	Shafts of the middle phalanges of digits 2-5	Median nerve	Flexes the metacarpophalangeal and proximal interphalangeal joints
Flexor digiti minimi brevis	Hook of hamate & the flexor retinaculum	Proximal phalanx of the 5 th digit	Ulnar nerve	Flexes the carpometacarpal and metacarpophalangeal joints of the 5 th digit

Table 1 Flexors of the hand (Kendall, 2005)

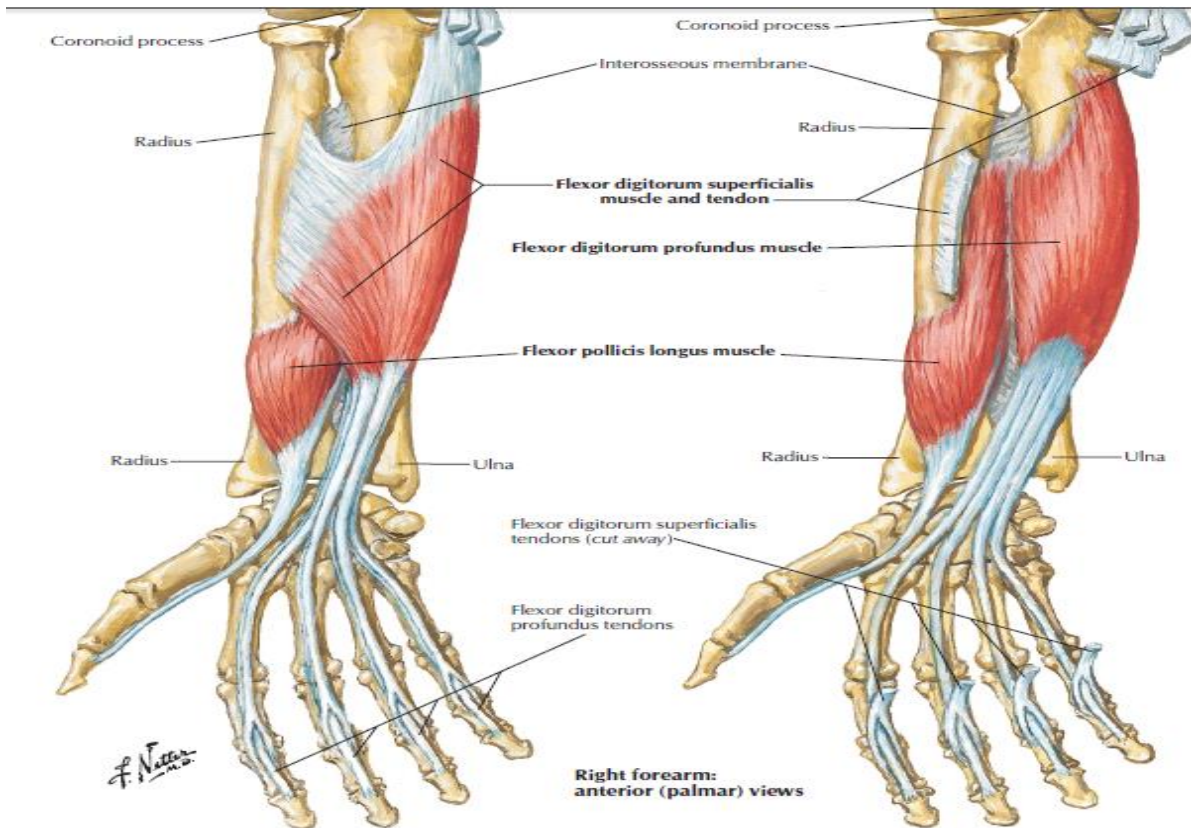


Figure 3 Individual muscles of forearm: flexors of wrist (Netter, 2014)

There are also eight extensor muscles in the posterior side of the forearm that give the ability to human to extend the hand and fingers or open flat, joints etc. Those muscles work against the flexors of the forearm (Lewis, 1970).

Muscles	Origin	Insertion	Innervation	Function
Extensor carpi radialis brevis	Lateral supracondylar ridge of the humerus	Dorsum of the third metacarpal bone	Radial nerve	Extends the wrist, abducts the hand

Extensor carpi radialis longus	Lower one-third of the lateral supracondylar ridge of the humerus	Dorsum of the second metacarpal bone	Deep radial nerve	Extends the wrist, abducts the hand
Extensor carpi ulnaris	Common extensor tendon & the middle one-half of the posterior border of the ulna	Medial side of the base of the 5 th metacarpal	Deep radial nerve	Extend the wrist, adducts the hand
Extensor digiti minimi	Common extensor tendon (lateral epicondyle of the humerus)	Joints the extensor digitorum tendon to the 5 th digit and inserts into the extensor expansion	Deep radial nerve	Extends the metacarpophalangeal proximal interphalangeal and distal interphalangeal joints of the 5 th digit
Extensor digitorum	Common extensor tendon (lateral epicondyle of the humerus)	Extensor expansion of digits 2-5	Deep radial nerve	Extend the metacarpophalangeal, proximal interphalangeal and distal interphalangeal joint of the 2 nd -5 th digits, extends wrist

Extensor indicis	Interosseous membrane and the posterolateral surface of the distal ulna	Tendon of the extensor digitorum to the second digit	Deep radial nerve	Extends the index finger at the metacarpophalangeal, proximal interphalangeal and distal interphalangeal joints
Extensor pollicis brevis	Interosseous membrane and the posterior surface of the distal radius	Base of the proximal phalanx of the thumb	Deep radial nerve	Extends the thumb at the metacarpophalangeal joint
Extensor pollicis longus	Interosseous membrane and middle part of the posterolateral surface of the ulna	Base of the distal phalanx of the thumb	Deep radial nerve	Extends the thumb at the interphalangeal joint.

Table 2 Extensor muscles of the hand (Tank, 2009)

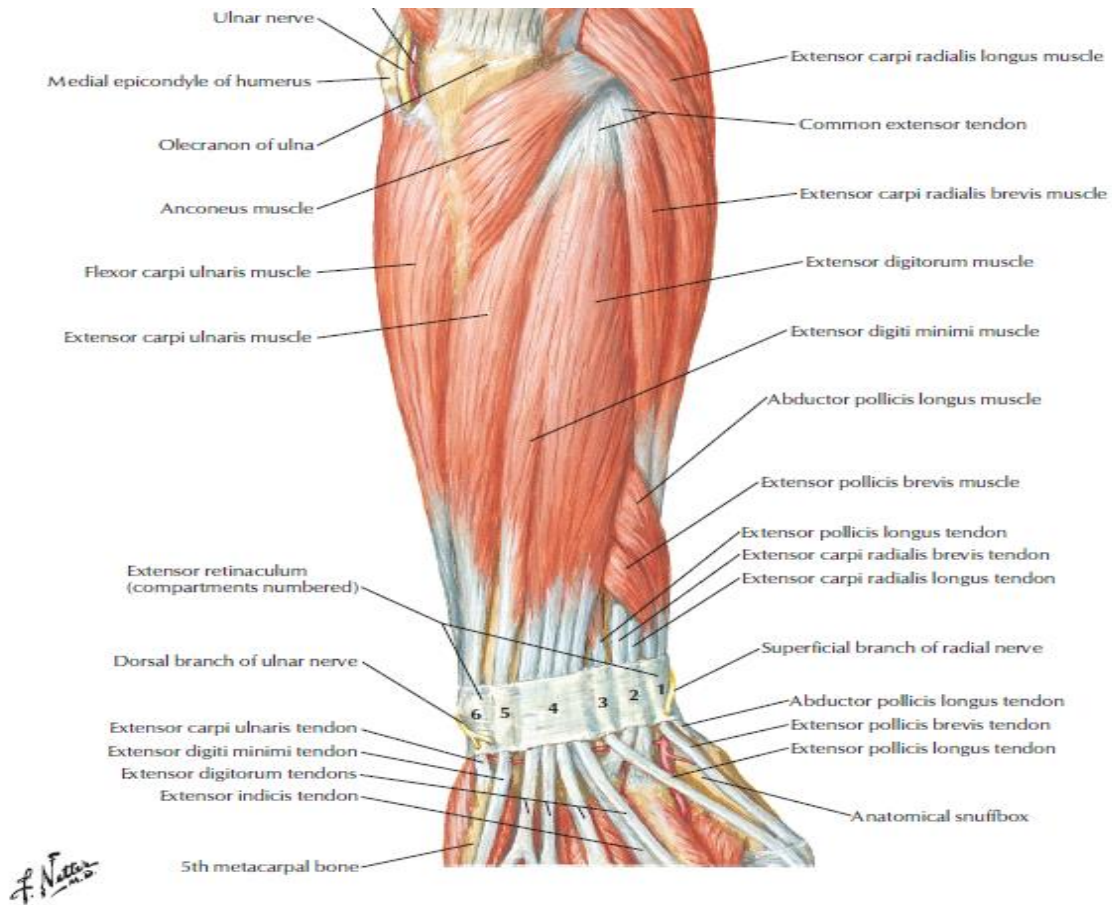


Figure 4 Muscles of forearm (Superficial layer): posterior view (Netter, 2014)

There are several muscles which influence the wrist and hand to rotate such as the supinator. On the other hand the pronator quadratus and pronator teres muscles provide rotation of the hand in the direction of pronation (antagonist of supinator) (Lee, 2014).

Muscles	Origin	Insertion	Innervation	Function
Pronator quadratus	Medial side of the anterior surface of the distal one fourth of the ulna	Anterior surface of the distal one-fourth of the radius	Median nerve via the anterior interosseous nerve	Pronates the forearm

Pronator teres	Common flexor tendon and from media side of coronoid process of the ulna	Midpoint of the lateral side of the shaft of the radius	Median nerve	Pronates the forearm
Supinator	Lateral epicondyle of the humerus, supinator crest & fossa of the ulna, radial collateral ligament	Lateral side of proximal one-third of the radius	Deep radial nerve	Supinates the forearm

Table 3 Rotators of the forearm (Tank, 2009)

We can divide the muscles of the hand into three main groups: the thenar, hypothenar and intermediate muscles. The muscles that are located in the lateral or thumb side of the palm are opponens pollicis, abductor pollicis brevis and adductor pollicis. The three hypothenar muscles are abductor digiti minimi, flexor digiti minimi and opponens digiti minimi and the located area which characterized as hypothenar is in the medial or little finger side of the palm. In the last group that I mentioned was the intermediate muscles and those are the lumbrical muscles. Those attach to the tendons the flexor digitorum profundus and extensors of the phalanges. Finally there are four palmar interossei muscles (Netter, 2014).

Muscles	Origin	Insertion	Innervation	Function
Interosseous, dorsal	Four muscles, each arising from two adjacent metacarpal shafts	Base of the proximal phalanx and extensor expansion on lateral side of 2 nd digit, lateral & medial sides of the 3 rd digit	Ulnar nerve	Flex the metacarpophalangeal joint, extend the proximal and distal interphalangeal joints of digits 2-4, abduct digits 2-4
Interosseous, palmar	Four muscles, arising from palmar surface of the shafts of metacarpals 1, 2, 4 & 5	Base of the proximal phalanx and extensor expansion of the medial side of digits 1 & 2 and lateral side of digits 4 & 5	Ulnar nerve	Flexes the metacarpophalangeal, extends proximal and distal interphalangeal joints and adducts digits 1, 2, 4 & 5
Lumbrical (hand)	Flexor digitorum profundus tendons of digits 2-5	Extensor expansion on the radial side of the proximal phalanx of digits 2-5	Median nerve via palmar digital nerves & ulnar nerve via deep branch	Flex the metacarpophalangeal joints, extend the proximal and distal interphalangeal joints of digits 2-5
Opponens pollicis	Flexor retinaculum, trapezium	Shaft of 1 st metacarpal	Median nerve	Opposes the thumb

Opponens digiti minimi	Hook of hamate and flexor retinaculum	Shaft of 5 th metacarpal	Ulnar nerve	Opposes the 5 th digit
Abductor digiti minimi (hand)	pisiform	Base of the proximal phalanx of the 5 th digit on its ulnar side	Ulnar nerve	Abducts the 5 th digit
Abductor pollicis brevis	Flexor retinaculum, scaphoid, trapezium	Base of the proximal phalanx of the first digit	Median nerve	Abducts thumb
Abductor pollicis longus	Middle one-third of the posterior surface of the radius, interosseous membrane, mid-portion of posterolateral ulna	Radial side of the base of the first metacarpal	Radial nerve	Abducts the thumb at carpometacarpal joint

Table 4 Wrist and Palm of the Hand (Tank, 2009)

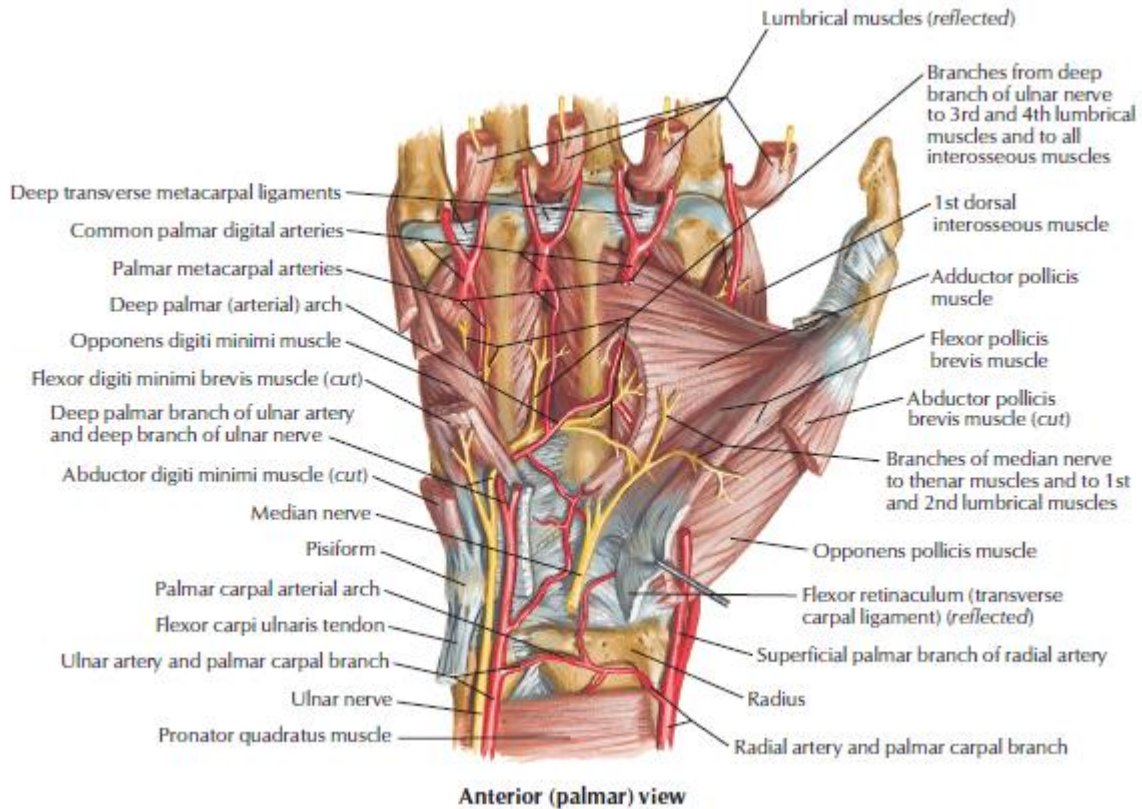


Figure 5 Intrinsic muscles of hand (Netter, 2014)

2.1.5 Blood supply related to wrist

In the distal part of the elbow and more specific in the region of cubital fossa, the brachial artery is divided into the radial and ulnar arteries. The radial artery is passing through the posterior aspect of the forearm and the ulnar artery from the anterior aspect. As I mentioned before the radial artery is a continuation of brachial, then it passes deep to brachioradialis, is crossing the floor of the anatomical snuffbox and ends in the hand by anastomosis with ulnar artery completing the deep palmar arch (Kaufman, 2013).

Moreover the ulnar artery passes deep to pronator teres, palmaris longus, flexor carpi radialis and flexor digitorum superficialis, it continue as the radial artery though the anatomical snuffbox and ends in the hand by anastomosis, making the superficial palmar arch. The radial artery is supplying blood to the thumb and the lateral side of the index finger and the ulnar artery supply the rest of the digits and medial side of the index finger. In the distal part of ulnar artery gives rise to the anterior and posterior interosseous artery. The anterior

interosseous artery starts from the proximal border of interosseous membrane, descends on anterior aspect of it with anterior interosseous branch of median nerve. Furthermore it supplies pronator quadratus, flexor pollicis longus and flexor digitorum profundus. Additionally the posterior interosseous artery has the same origin but it goes through supinator and abductor pollicis longus, it descends deep between extensor digiti minimi and extensor carpi ulnaris (Agur, 2010).

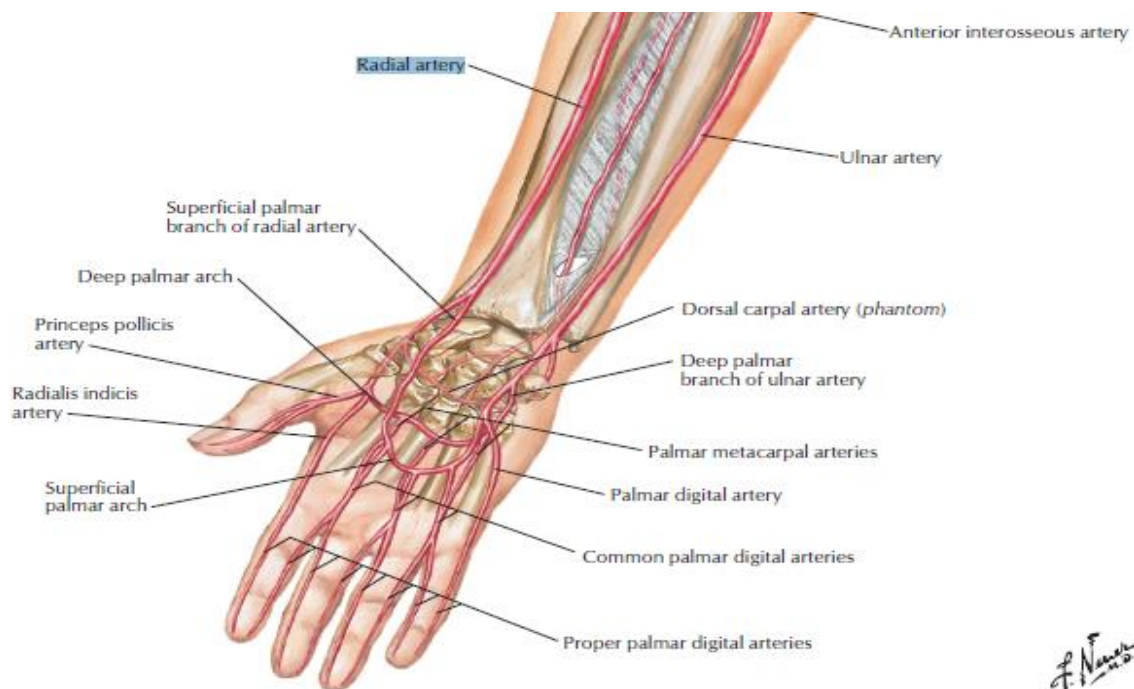


Figure 6 Arteries of forearm (Netter, 2014)

The veins of upper extremity are divided into superficial and deep vessels. The superficial starts on the posterior part of hand and they divided into cephalic vein, basilica vein.

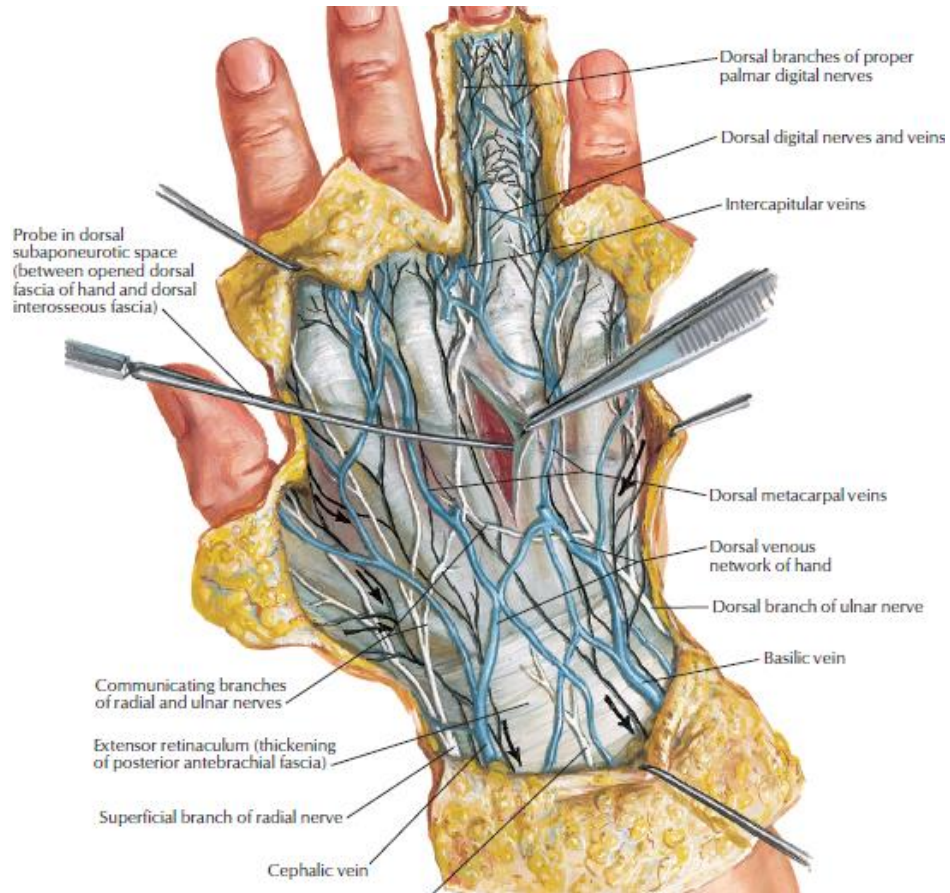


Figure 7 Wrist and hand: superficial dorsal dissection (Netter, 2014)

Cephalic vein: starts at the radial extremity of arc, ascends along the lateral aspect of the arm and pierces the deep fascia to enter the axillary vein

Basilic vein: ascend to the medial aspect of forearm, pierces the deep fascia at elbow and ends in brachial artery.

Median vein: ascend on the ulnar side of forearm and ends in the basic vein.

Digital vein: ascend along the sides of fingers and are joined to other branches and form three dorsal metacarpal veins that end in the dorsal venous net-work.

2.2 Kinesiology of wrist joint

The wrist and hand allow you to provide a few movements which are under voluntary control. The main movements of the carpal complex are in the direction of flexion, extension, radial and ulnar deviation and with the combination of all those movements create another movement which is called circumduction. Finally supination and pronation of hand can be mentioned here.

Flexion and extension: those movements arise basically in the radiocarpal articulation with an exception of distal carpal row cooperation. During extension the movement arises between radius-scapoid and lunate-radius. Lunate and capitate are rotating during flexion but lunate is also shifted dorsally. Finally flexion occurs at radiocarpal joint and extension in the midcarpal joint. The normal range of motion for flexion of wrist is 60-80° and extension 40-60°.

Ulnar and radial deviation: it occurs in midcarpal articulation. When a person provides radial duction, at the same time the proximal carpal row is moving in ulnar duction and the distal carpal row in radial direction. The opposite situation appears for ulnar duction. Moreover it extends the capitate (during radial deviation) and flexes the proximal row. The physiological range of motion in the direction of radial deviation is 15-20° and 45° for ulnar deviation.

Circumduction: it can be described as a circular movement of the wrist and as I mentioned in the beginning of this chapter is the combination of flexion, extension, radial and ulnar deviation.

Pronation and supination: is the rotation of the hand upward and downward. It occurs in the proximal and distal radioulnar joints. Moreover it is related with radial and ulnar deviation of the wrist. For example during the radial duction of the wrist there are other movements such as extension of wrist and pronation. On the other hand during ulnar duction, functionally, there is also slight flexion and supination of the hand (Kolar, 2013).

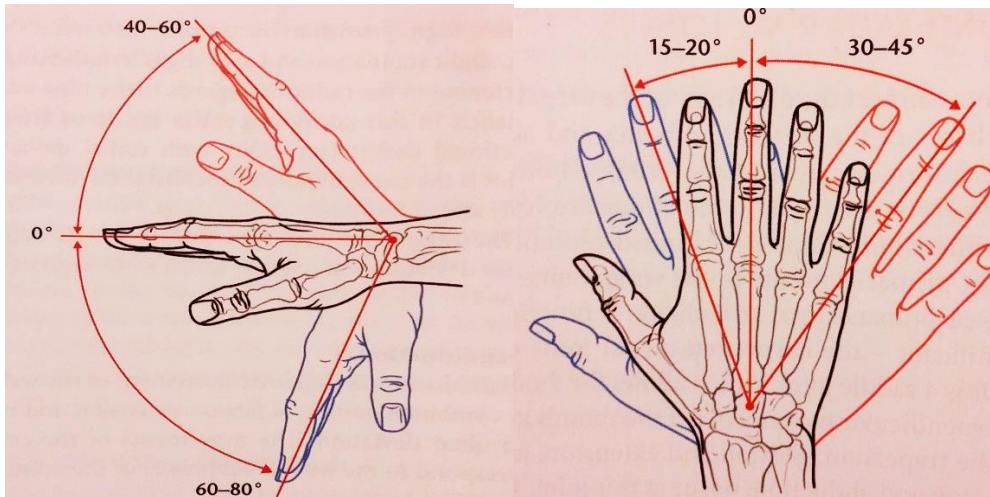


Figure 8 Ranger of motion of wrist into flexion (blue-left picture), extension (red-left picture), lateral (blue-right picture) and ulnar deviation (red-right picture). (Kolar, 2013)

2.3 Biomechanics of wrist joint

The wrist joint is a complex joint of human body and is connecting with the forearm and hand. This joint is created by several other joints and those are radioulnar joint, radiocarpal joint, ulnocarpal joint, the midcarpal joints and the intercarpal joints. With the assistance of wrist joint we are able to provide an impressive arc of motion that maintains the stability. It is primarily responsible for flexion, extension, radial and ulnar deviation. Combination of those movements produces circumduction. During pain, muscle weakness of wrist flexors and extensors or even after an injury the result will be instability of wrist and lack of motion followed by inherent motor imbalance between the six wrist motors (Volz, 1980).

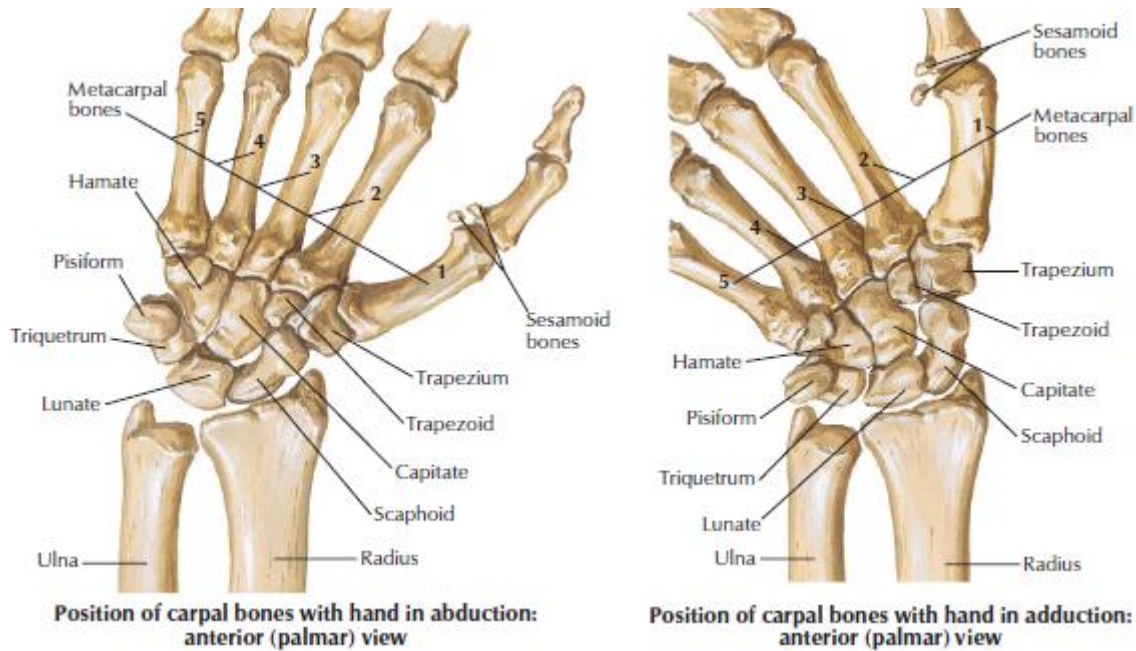


Figure 9 Movements of Wrist (Netter, 2014)

In the proximal and palmar pole of capitate bone is the main center of motion for these planes movements. The dart-throw has been characterized as the principal functional axis and produces motion from extension-radial deviation to flexion-ulnar deviation. The rotation of forearm in longitudinal axis provides supination and pronation of wrist comparative to the forearm. If there will be torque across the wrist, rotation approximately 10° between the wrist and forearm. In a relax position, 40° of rotation can be appear in radiocarpal and midcarpal joints. This type of constrained rotation is critical to the function of the wrist in transmitting torque and allowing as much motion as possible in the remaining planes. After flexion of the third metacarpal, the distal row of carpal bones are also flexed and relatively during extension of third metacarpal simultaneously there will be extension in distal row of carpal bones. The relationship is maintained for the direction and magnitude of motion. When a person provides dorsi-flexion of wrist, the scaphoid has tendency to supinate and lunate to pronate. The opposite situation appears during wrist flexion (Palmer, 1985, Berger, 1996).

As we provide radial-ulnar deviation, the proximal row bones are characterized as reciprocal pattern. More specific the proximal row bones firstly provide flexion and secondary counter rotate toward the ulnar during radial deviation of wrist.

Some investigators discovered that the palmar capsular ligaments (like radiolunate ligaments) can resist approximately 100 newtons, the intrinsic ligaments can defy till 300 newtons which make it stronger. The strain at failure of these ligaments exceeding 50% compared with 10-35% respectively. The radioscapholunate ligament is quite weak compare with the rest ligaments of wrist, studies have shown that can resist till 50 newtons (Berger, 1996).

2.4 Arthrosis of the wrist joints

Arthrosis is a disease of the various tissues inside joints. There is a possibility after an injury, in the chronic state the patient will suffer from pain, most often during loading can be result of instability. Arthrosis can be developed as a result of instability. Another reason is after an acute or chronic inflammation of a joint and its surrounding soft tissues. It constitute by 100 and more different rheumatic diseases and conditions (Stoppler, 2015).

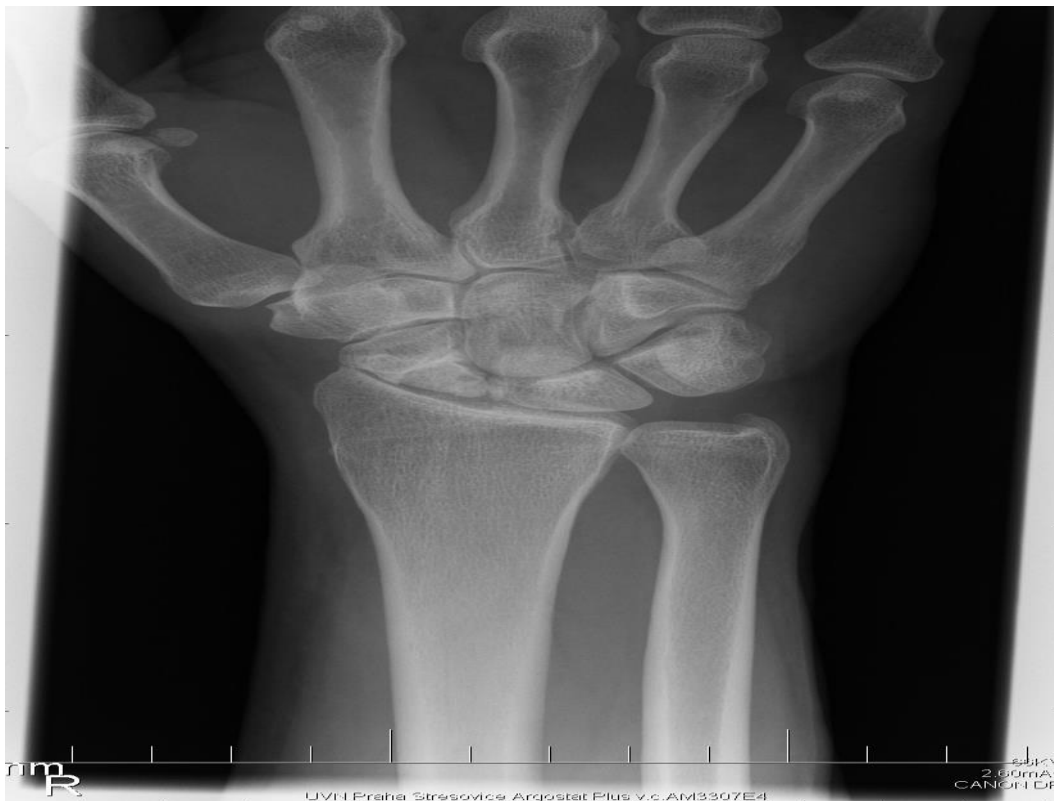

Figure 10 X-ray of right wrist in superior view (Personal image of my patient's wrist)

The main symptoms of arthrosis are pain, stiffness, decrease range of motion and swelling in the area of affected joints and in our case the edema was located in the ventral aspect of wrist. Arthrosis appears usually the adults in the age of 65 but all the people in every age of their lives can be affected. Furthermore it is more common to women (24.4%) compare with men (18.1%).

The risky complications of arthrosis is that provoke the people from physical activities. Moreover it is connecting with some other disease like diabetes or heart disease (half of them suffer from arthrosis). Studies showed that pain, fear of worsening symptoms, damage of joints or lack of information how to exercise safely may prevent the people to being active (Marks, 2009).

2.4.2 Etiopathogenesis

A kinematic analysis of the movement of lunate, triquetrum and scaphoid has shown that their turning axes do not correspond with each other. The ligaments are getting high load when a person suffers from arthritis. The scapho-lunatum and lunato-triquetrum ligaments are usually affected simultaneously (Sennwald, 1993).

Any damage of your hand can lead to pain and disable the person to provide any motion of the wrist and hand. After a sudden impact the result can be a fracture of bone in the wrist or even sprains. Moreover during repetitive wrist motion, like playing tennis, can flame the tissues around the joints (Mayo, 2014).

A joint is consist of two smooth surfaces, the cartilage and covered bone surfaces and when those surfaces become unreliable can lead to arthritis and in chronic state to arthrosis. Osteoarthritis and rheumatoid arthritis are the most common forms of arthritis. The cushioning cartilage, which covers the bone surface of joint, starts to wear out. The first changes can be degeneration of hyaline cartilage of articular surface, then the cartilage will be thinner and overgrowth of opposing joint surface and in some advance cases there will be synovial hyperplasia with lymphoid follicles (Shankar, 2014).

2.4.3 Clinical image

The clinical image of the patient with arthrosis in the wrist will be characterized as pain in the affected joint. It will appear usually during overloading but the pain will be relieved during rest. Moreover as the arthritis is getting in an advanced level there will be loss of motion in the affected joint. Maybe there will be swelling in the affected area and often become red and tender to the touch. This shows us some damage to the tissues surrounding the joint. Usually the patient suffers from muscle weakness which developed after pain, lack of motion and joint deformity (Kolar, 2013).

2.4.4 Diagnosis

To get in the correct diagnosis, the doctor will apply some physical examination such as observation, palpation etc. and ask for the patient history and by blood tests. Some special tests can be performed for the correct diagnosis of patient as Tinel's sign, carpal compression test, scaphoid shift test and Finkelstein test. Moreover we can use X-rays as imaging test, CT, MRI, US to detail picture of the bone, ligaments, tendons, soft tissue and cartilage (Jennings, 2011).

2.5 Physiotherapists examinations

Anamnesis

The main task of the patient is to answer in some questions about his history. According to the answers, we can get proper information about the current state of the patient and his/her main problem. The patient will give us information when his/her main problem started, when the main complications arise during the day and how it influenced the patient's ADL. Furthermore the patient will inform us about his previous injuries or surgeries, allergies, hobbies, medications, previous rehabilitation, his/her family anamnesis and about his/her occupation and social anamnesis. With the proper information, the therapist can create his/her therapeutic plan without provoke any complication or some undesirable effects by using an inappropriate modality (Čemusová, 2012)

Posture examination

We will observe both upper extremities and compare them, if there are any deformities or asymmetries, even the muscles if they are hypotrophic or hypertrophic. Moreover we are able to check the edema. Generally with the posture examination we check the patient's structure in three views (anterior, lateral side [both sides] and posterior view) (Kendall, 2013).

Palpation and muscle tone examination according to Lewit

We can palpate both upper extremities and compare them, if there is any difference in the muscle tone, swelling or pain. Some muscles that we can check are biceps brachii, triceps brachii, brachioradialis, supinator, pronator teres-quadratus, flexor carpi radialis longus, pmaris longus and general all the muscles that insert, originate, or passing through the wrist. Also we can palpate medial-lateral epicondyle, olecranon, radial head (Lewit, 2010).

Dynamic examination

The patient will be in standing position and will provide extension, flexion and lateral flexion (both sides) of the trunk and at the same time the physiotherapist will observe the motion of the spine segments (Jalovcová, 2012).

Anthropometric measurements of upper extremities

The physiotherapist will measure the length and circumference of the upper extremities. The patient is able to be in sitting or lying position, but at the same time he/she has to be in totally relaxed position. Moreover the physiotherapist has to measure both sides and compare them in case of any asymmetry, swelling etc. (Jalovcová, 2012).

Range of motion examination

With the ROM examination we will observe the amount of motion which is available in a joint. Goniometer is used to verify the results of range of motion. The physiotherapist will observe any limitation of motion for both sides. The ROM is classified as limited, physiological or excessive. The examination will be performed with active and passive

movements of the patient. We will examine the ROM of wrist, elbow, shoulder and neck (Jalovcová, 2012).

Soft tissue examination

The therapist will examine the fasciae of both forearms and by placing both hands on each forearm, with simultaneously opposite rotation forces, will be able to find any restriction of fasciae in both sides (Lewit, 2010).

Muscle strength test

The muscle strength is characterized as a physical force exerted by muscle and those can be isometric, concentric or eccentric contractions. The therapist will examine the strength of muscles around the fingers, wrist, forearm and shoulder. Robert Lovett evaluated the strength of the muscle into six grades:

- 0- Gone (no contraction)
- 1- Trace
- 2- Poor
- 3- Fair
- 4- Good
- 5- Normal (Kendall, 2013).

Muscle length examination

The muscle length examination is used to analyze the range of muscle length. The physiotherapist is looking for any shortness of surrounding muscles and is classified as normal, limited or excessive. Mr. Janda evaluated this test into three grades:

- 0- No shortness
- 1- Moderate shortness
- 2- Marked shortness (Jalovcová, 2012).

Joint play examination

This examination is used to examine the joint's mobility (distinguish any blockage) but even to restore them. It consists by two types of manipulation; mobilization and thrust. The physiotherapist is performing this examination in fingers, wrist, elbow and shoulder in both directions.

Neurological examination

The physiotherapist will examine the deep tendon reflex of Biceps brachii (C5-6), Triceps brachii (C7), flexors of wrist (C8). Furthermore stereognosia and kinesthesia are indicated to examine in this type of diagnosis (Pánek, 2013).

2.6 Treatment

During overworked or have excessive weight-bearing activities, some changes of arthrosis will be appear. According to studies exercises are indicated to control the pain and even improve the function of the patient. Glucosamine is indicated to decrease the pain level of the patient due to Arthritis. The most common treatment methods that we can perform are gentle passive movement in all direction to increase the strength and the ROM, mobility and strengthening exercises (like PNF), massage, and acupuncture. The patient should get rest and prevent to overload the affected joint. Furthermore the patient can use, if it's suggested by the physician, supportive braces, splints, special shoes and other assistant devices. There is a big possibility of stiffness of fasciae in the forearm because of the inactivity of upper extremity. That's why we can perform soft tissue techniques to relax the stiffness of fasciae (Miller, 2015, Bernstein, 2011).

The treatment plan includes stretching of shorten muscles, myorelaxation of hypertonic muscles by using PIR. Self-therapy for myorelaxation of flexors and extensors of wrist can be educated to the patient. Another way to relax the hypertonic muscles or even to strength the weaken muscles the physiotherapist can apply taping on the affected area. The physiotherapist focus also in the restricted joints and for that mobilization is a necessary method that we can apply.

The patient will be educated how to use primarily his/her abilities of motion without overload the affected joint. Another important role of the treatment is the nutrition of the patient. According to studies by Roy Altman, the people who lost weight have a result of lack of symptoms in Arthritis. Physical activities and more specific aerobic exercises are indicated for treatment like walking, swimming and cycling for those who are in better shape. By the physical's therapy point of view electrotherapy, laser, magnetotherapy include the heat can applied to the patient (Kolar, 2013, Crook, 2011).

I would like to mention some strengthening exercises for wrist joint in more detail. The first exercise which is mention as 'make a fist', you start by holding your affective hand up straight. Then start to bend it and make a fist and finally open your hand again gently. Repeat this exercise 10 times. A second exercise for the beginning is called make an 'O'. You start with straight fingers, then curve all of your fingers inward until they touch. Keep that position for 10 seconds. Next exercise is the finger lift. In that exercise you place your hand on the table from the palmar side. Start to extend your fingers one by one and for each finger you will hold the extended position for 5 seconds (Krucik, 2013).

Follow this therapeutic plan the patient will increase his strength and prevent any complication as pain for their rest of their lives but he/she will never be treated totally.

3. Special Part (Case Study)

3.1. Methodology

The clinical work practice was done in U.V.N (Ústřední Vojenská Nemocnice). It started on Monday 12th of January 2015 and finished on Friday 20th of January 2015. It was an eight hours timetable daily with a total of eighty hours for the whole two weeks practice.

My clinical practice was supervised by Mgr. Romana Kozderková. The diagnosis of my patient was arthritis of the wrist joints. I had the possibility to have six sessions with my patient and it was scheduled on the same time starting from 12th on January with my initial kinesiology examination. The final kinesiology examination was provided during the last session on 23rd of January.

The therapeutic procedures took place mainly in the individual therapy room. Mainly I used my hands for the examinations and therapy but I used also some instruments like neurologic hammer, goniometer, measurement tape and Thera-band.

Finally I would like to mention that my patient and I signed an acquiescence form. In addition my clinical practice was approved from the Ethics Committee of the Faculty of Physical Education and Sport at Charles University, with the approval number 041/2015.

3.2. Anamnesis

Patient: F.L, 58 years old (male)

Diagnosis: Arthrosis of the wrist joints

Code: M1904

3.2.1. Present State

Height: 1.90cm

Weight: 95kg

BMI: 26.3

The patient after an accident during cycling, which happened on 9 of February 2014, feels pain on the ventral-medial side of the right wrist and sometimes he feels pain on his neck. My patient mentioned that the pain in the wrist appears after some activities such as tennis and more specific when he provides extension and adduction of the wrist. I asked my patient to describe the pain from the scale 0 to 10 (10 characterized as the maximum pain level and 0 as the minimum pain level) for the wrist and neck and for both computes as 5 to 10. I observe an edema on his ventral part of wrist and the patient informed me that the swelling area was bigger one week ago. Mr. F.L. claimed also that he has problem with writing (he is right handed). The first time that he came in U.V.N (Ústřední Vojenská Nemocnice) hospital was in 14th of May.

3.2.2. Personal Anamnesis

The patient had a broken wrist 10 years ago during skiing. Furthermore the patient had all common childhood diseases.

3.2.3. Family anamnesis

The patient has one younger sister, who is healthy, his father and mother suffers from osteoporosis.

3.2.4. Operation Anamnesis

He had no operations.

3.2.5. Medication

He used to take collagen infusion by a doctor for pain relief but the swelling and pain appear again after a couple of hours.

3.2.6. Allergy Anamnesis

The patient doesn't suffer from any allergies

3.2.7. Social Anamnesis

He is married and has three children with a flat in the center of Prague.

3.2.8. Occupation Anamnesis

The patient owns four restaurants.

3.2.9. Hobbies

The patient likes to play tennis, go for jogging, skiing and cycling. He mentioned that loves sport activities and used to play also football, handball and volleyball.

3.2.10. Abuses

Occasionally the patient drinks beer and smokes cigarettes (five per day).

3.2.11. Previous Rehabilitation

After the accident in February 2014, he had 15 sessions of physiotherapy on June 2014 and more 15 sessions on September.

3.2.12. Statement from the patient's medical documentation

At January 2015 the patient did an X-ray examination in order to check if there was any fracture deformity in his wrist. The results showed arthrosis of the wrist but because of some technical problems of my opponent supervisor's computer, I wasn't able to see it.

3.2.13. Indication of rehabilitation

The doctor suggested a physiotherapeutic programme that includes active movements of the wrist in all directions to increase the range of motion and strengthening of the surrounding muscles of forearm and wrist. Mobilization of hands, wrists, elbows and neck joints to improve range of motion, decrease pain and unblock the restrictions. Massage will help the patient to relax, decrease the edema and improve the blood circulation. Magnetotherapy is indicated according to the doctor for stimulation of osteoblasts and therefore regeneration of bone tissues.

3.2.14. Differential Diagnosis

Concerning the anamnesis the patient is suffers from arthrosis of the wrist. He feels pain on the ventral aspect of the right wrist due to overload his upper extremities (sport activities) on his daily living. My opponent supervisor informed me that he felt pain especially during strengthening exercises with limitation of ROM in wrist. That can be due to muscle weakness, compression of radial-ulnar nerve. Furthermore the ROM is decreased because of limited motion of upper extremity due to pain or even shortens muscles of the forearm and hand. According to the diagnosis we expect to observe blockages of wrist joints due to some damage of ligaments. Finally we can expect some sensory deficit of the right arm due to any compression of radial, ulnar or median nerve by bones.

3.3. Initial Kinesiology Examination

3.3.1 Observation:

- Slight edema on the ventral aspect of the wrist.
- Protraction of the head (forward).

- Protraction of both shoulders (forward).
- Slight supination of the right wrist compare with the other.
- Slight flexion of right elbow compare with the other.

3.3.2 Posture evaluation in standing

Posterior view

Normal base of foot.
Slight valgosity of Achilles tendon in the right leg.
Popliteal line is in slight external rotation of right knee joints.
Both calf muscles are hypertrophic.
Both thighs are hypertrophic.
Posterior iliac spines are in the same level.
Posterior iliac crests are in the same level.
Slight abducted of the left scapula.
The right thoraco-axillar triangular space is bigger that the left one.
The left shoulder was slightly higher than the other one.

Table 5:Initial postural examination in posterior view

Anterior view

Slight external rotation of the right foot.
Slight valgosity of the right knee.
Hypertrophy of both Quadriceps.

Normal trophy of both transverse abdominalis and rectus abdominalis.
Left shoulder is slight higher but both are protracted.
He seems to put the same weight on both side.
Both clavicles look symmetrical.
Thoraco-axillar triangle space in the right side is bigger.
Protraction of the head.

Table 6 Initial postural examination in anterior view

Lateral view (right side)

He places more weight on the medial aspect of foot and metatarsal heads.
Right knee is extended.
Slight flexion of hip.
Slight anterior tilt of pelvis.
Slight lordosis in the lumbar region.
Slight kyphosis in thoracic region.
Slight lordosis in cervical region.
Slight protraction of the shoulder.
Protraction of the head.

Table 7 Initial postural examination in lateral view (right side)

Lateral view (left side)

He places more weight on the lateral aspect of foot.
Left knee is extended.
Slight flexion of the hip.
Slight anterior tilt of pelvis.
Slight lordosis of lumbar region.
Slight kyphosis of thoracic region.
Slight lordosis of cervical region.
Slight protraction of the shoulder.
Protraction of the head.

Table 8 Initial postural examination in lateral side (left side).

3.3.3 Dynamic examination

Extension: With good instructions the patient is able to provide the movement in physiological range of motion without pain and with properly movements of thoracic and lumber area.

Flexion: The patient is able to provide flexion of the trunk without pain but with some range of motion deficit because he wasn't able to touch the floor.

Lateral flexion: The patient was able to provide lateral flexion of the trunk without pain. I can say that the range of motion of the left side was higher and the movement was more fluent.

3.3.4 Anthropometric measurements of upper extremities

Length	Right arm	Left arm

Circumference of the upper arm	32	32
Circumference of the forearm	27	27
The length of whole upper extremity	84	84
The length of the humerus	38	39
The length of the forearm	30	29
The length of the hand	22	22.5

Table 9 Initial examination of Anthropometry measurement of upper extremities

3.3.5 Range of motion examination according to Kendall

Shoulder joint					
Active	Right	Left	Passive	Right	Left
Flexion	160	165	Flexion	165	165
Extension	30	30	Extension	30	30
Abduction	165	170	Abduction	170	170
External rotation	80	80	External rotation	80	85
Internal rotation	55	60	Internal rotation	60	60

Table 10 Initial examination of ROM of Shoulder joint

Elbow joint					
Active	Right	Left	Passive	Right	Left
Flexion	140	140	Flexion	140	140

Table 11 Initial examination of ROM of Elbow joint

Radioulnar joint					
Active	Right	Left	Passive	Right	Left
Supination	75	75	Supination	75	75
Pronation	75	75	Pronation	75	75

Table 12 Initial examination of ROM of Radioulnar joint

Wrist joint					
Active	Right	Left	Passive	Right	Left
Dorsal Flexion	65	75	Dorsal Flexion	65	75
Palmar Flexion	65	75	Plantar Flexion	65	75
Ulnar duction	35	40	Ulnar duction	35	40

Radial duction	10	20	Radial duction	10	20
---------------------------	----	----	---------------------------	----	----

Table 13 Initial examination of ROM of Wrist joint

*The patient felt slight pain in his maximal dorsal flexion of wrist.

3.3.6 Muscle tone examination

Muscles	Right	Left
Upper trapezius	Hypertone	Hypertone
Middle trapezius	Normal tone	Normal tone
Lower trapezius	Normal tone	Normal tone
Deltoid Anterior	Normal tone	Normal tone
Deltoid Posterior	Normal tone	Normal tone
Pectoralis Major	Hypertone	Hypertone
Latissimus Dorsi	Hypertone	Hypertone
Biceps Brachii	Normal tone	Normal tone
Triceps	Hypertone	Hypertone
Flexors of forearm	Normal tone	Normal tone
Extensors of forearm	Normal tone	Normal tone
Sternocleidomastoid	Hypertone	Hypertone
Scalene muscles	Hypertone	Hypertone

Longus colli	Hypertone	Hypertone
Longus capitis	Hypertone	Hypertone

Table 14 Initial examination of muscle tone of upper extremity

3.3.7 Soft tissue examination according to Lewit

Examination of fasciae: By placing both hands on each forearm and with simultaneous opposite rotation forces and I find restriction in both directions (medial-lateral).

3.3.8 Muscle strength test according to Kendall

Upper extremities		
Muscles	Right	Left
Upper trapezius	5	5
Middle trapezius	4	4
Lower trapezius	4	4
Levator scapulae	4	4
Latissimus dorsi	4	4
Teres major	4	4
Pectoralis major upper fibres	5	5
Pectoralis major lower fibres	4	4

Pectoralis minor	4	4
Deltoid anterior	4	4
Deltoid medius	4	4
Deltoid posterior	4	4
Coracobrachialis	4	4
Triceps brachii + Anconeus	4	4
Biceps brachii + brachialis	4	4
Supinator	3	3
Pronator quadratus	3	3
Extensor carpi ulnaris	3+	4
Extensor carpi radialis longus + brevis	3	4
Flexor carpi radialis	3	4
Flexor carpi ulnaris	4	4
Flexor digitorum	4	4
Extensor digitorum	3	4
Palmaris longus	4	4
Palmar interossei 1st-4th	3	4
Dorsal interossei 1st-4th	4	4

Flexor digiti minimi	3	4
Abductor digiti minimi	3	4
Abductor pollicis longus	3	4
Extensor pollicis longus	3	3
Extensor pollicis brevis	3	3
Flexor pollicis longus	3	3
Flexor pollicis brevis	3	3
Opponens digiti minimi	3	3

Table 15 Initial examination of muscle strength in upper extremities

3.3.9 Muscle length examination according to Lewit

Upper extremities		
Muscles	Right	Left
Scalene muscles	1	1
Upper trapezius	1	1
Levator scapulae	0	0
Sternocleidomastoid	1	1

Table 16 Initial examination of muscle length of upper extremities.

3.3.10 Joint play examination according to Lewit

I applied examination of joint play on the fingers, wrists, elbows and shoulders joints in both sides.

Wrist joint:

Right hand

Examination in direction of dorsal flexion: There was blockage.

Examination in direction of palmar flexion: There wasn't any blockage.

Examination in direction of ulnar duction: There was blockage.

Examination in direction of radial duction: There was blockage.

Left hand

Examination in direction of dorsal flexion: There wasn't any blockage

Examination in direction of palmar flexion: There wasn't any blockage.

Examination in direction of ulnar duction: There wasn't any blockage.

Examination in direction of radial duction: There wasn't any blockage.

Elbow joint:

Right elbow

Examination in direction of lateral side: There wasn't any restriction.

Examination in direction of medial side: There wasn't any restriction.

Left elbow

Examination in direction of lateral side: There wasn't any restriction.

Examination in direction of medial side: There wasn't any restriction.

Shoulder joint

Right shoulder

Examination of glenohumeral joint in ventral direction: There was a blockage.

Examination of glenohumeral joint in lateral direction: There wasn't any blockage.

Examination of glenohumeral joint in dorsal direction: There was a blockage.

Examination of glenohumeral joint in caudal direction: There was a blockage.

Left shoulder

Examination of glenohumeral joint in ventral direction: There wasn't any blockage.

Examination of glenohumeral joint in lateral direction: There wasn't any blockage.

Examination of glenohumeral joint in dorsal direction: There wasn't any blockage.

Examination of glenohumeral joint in caudal direction: There wasn't any blockage.

Fingers

Examination of metacarpophalangeal joint in all directions: There were limitations of joint play.

Examination of carpometacarpal joint in all directions: There were limitations of joint play.

Examination of interphalangeal joint in all directions: There were limitations of joint play.

3.3.11 Neurological examination

Deep tendon reflex:

Biceps brachii (C5-6): physiological reaction in both sides, grade 2.

Triceps brachii (C7): physiological reaction in both sides, grade 2.

Flexors of wrist (C8): physiological reaction in both sides, grade 2.

Deep sensation:

Stereognosis: physiological reaction.

Kinesthesia: physiological reaction.

Superficial sensation:

Light touch: physiological in both sides.

3.3.12 Conclusion of initial kinesiology examination

After the initial kinesiology examination I observe that my patient has:

- Higher location of left shoulder compare with the right one, higher thoraco-axillar triangular space of the right side and protracted head from postural examination.
- The patient had an Xray which happened in January 2015 and the doctor came to the conclusion of arthrosis of small joints in the wrist.
- After dynamic examination I can say that the patient is able to provide all examinations in flexion, extension and lateral flexion without pain but there was decrease ROM during flexion and higher ROM in lateral flexion of the left side with more fluent movement.
- The patient has decreased ROM of the wrist in direction of radial duction and he felt slight pain during the dorsal flexion of wrist when it was performed passively.
- Higher tonicity of neck flexors and trapezius was found during muscle tone examination.
- Restriction of the fasciae in forearm in medial-lateral direction.

- Furthermore after the muscle strength test I came to the conclusion that the patient had some weak muscles on the wrist and fingers especially to the right hand and he felt pain during the test for extensor digitorum and extensor carpi radialis.
- Shortness of scalene muscles, trapezius, sternocleidomastoid and triceps brachii.
- There were restrictions of joint play and more specific to the right wrist in dorsal flexion, ulnar and radial duction. Moreover there were restrictions in glenohumeral joint in the direction of caudal, dorsal and ventral. Carpometacarpal joint, metacarpophalangeal joint and interphalangeal joints in the right hand was restricted in all directions.
- There weren't any complications after neurological examination. Due to wrist fracture, which happened after a ski accident, and maybe bad protection of the wrist during the rehabilitation the patient suffers from arthrosis of the wrist joint.

3.4 Short-term and long-term rehabilitation plan

3.4.1 Short-term rehabilitation plan

- Pain relief
- Relaxation of hypertone muscles
- Increase the Range of motion of restricted joints such as in wrist joint in the direction of dorsal flexion, ulnar and radial duction.
- Decrease edema in the ventral aspect of the wrist
- Regain mobility of restricted joints
- Release the tension of fasciae in forearm
- Increase proprioception by using ProprioMed
- Stretching of shortened muscles
- Strengthening of weak muscles
- Improve bone tissues by using magnetotherapy

3.4.2 Long-term rehabilitation plan

- Maintain the goals of the short rehabilitation plan
- Improve the condition of musculoskeletal system with advanced strengthening exercises
- Education of self-therapy
- Education of patient for prevention of complications
- Improve the ADL activities

3.4.3 Therapy proposal

- Active exercises of hand and wrist
- Improve proprioception by using ProprioMed (Flexi-bar)
- Soft tissue techniques according to Lewit on forearm
- PIR according to Lewit for myorelaxation of hypertone muscles (neck flexors, trapezius)
- Joint play techniques according to Lewit to increase the mobility and release the blockage of joints (joints of hand, wrist and shoulder).
- Strengthening exercises for weak muscles (hand flexors, extensors, abductors)
- Lymphatic drainage to decrease edema using exteroceptor ball
- Taping for myorelaxation of short muscles which was performed by my opponent supervisor
- Education of self-therapy for myorelaxation of hyperone muscles such as levator scapulae, sternocleidomastoid, upper trapezius.
- Strengthening exercises with elastic band for hand, wrist and shoulder
- Advanced close-chain strengthening exercises will be mention later.
- Magnetotherapy to improve bone tissues

3.5 Therapy progress

3.5.1. Session 1st Monday on 12.1.2015

Objective: In the first session the patient was feeling pain in the right wrist and neck. He was ready to work with me with confidence.

Subjective: Decrease ROM was been noticed for the wrist and pain during dorsi-flexion of wrist.

Goals of today's therapeutic unit

- Reduce pain with active movements of fingers, wrist and neck
- Increase the Range of motion with active exercises of fingers and wrist.
- With active exercises of fingers and wrist and also using the exteroceptor ball will be able to decrease edema
- Release the tension of fasciae in forearm
- Increase proprioception by using ProprioMed
- Myorelaxation of hypertone muscles
- Improve bone tissues by using magnetotherapy
- Restore joint play

Execution

1. Soft tissue techniques according to Lewit:

In supine position: We place both hands on each forearm and with simultaneous opposite rotation forces we reach the barrier of restricted fasciae, ask the patient to take a breath and breath out and we wait for the release.

2. Active movements of fingers and wrist to increase ROM and strength:

Sitting position: The patient provides active movements of fingers in flexion,

extension, abduction and adduction and all the property movements for wrist and neck. For every direction 15 repetitions will be indicate.

3. Lymphatic drainage using exteroceptor ball:

Sitting position: We apply lymphatic massage by using an exteroceptor ball in caudal-cranial direction.

4. Joint play techniques according to Lewit:

The therapist apply joint play techniques to glenohumeral joint in the direction of caudal, dorsal and ventral and also cervical spine in direction of lateral flexion in both sides. Moreover in carpometacarpal, interphalangeal and metacarpophalangeal joints were performed joint play in all directions.

5. Improve proprioception with Propriomed:

Standing position: By using a Propriomed the patient will start to provide quick repeated movements (only by the shoulder) in ventral and dorsal direction.

6. Post isometric relaxation techniques according to Lewit:

We apply PIR for myorelaxation of hypertone muscles and more specific for upper trapezius, sternocleidomastoid, levator scapulae, pectoralis major and triceps brachii in both sides.

7. Physical therapy:

Magnetotherapy was indicated for the bone tissues of the right wrist. The duration of this therapy is 25 min.

Results:

After the first session the patient was still feeling the pain, especially when he was providing maximal dorsal flexion of the wrist but the pain level was less. As concerns the pain of the neck, was disappeared. I would like to mention here that PNF for strengthening the

weak muscles of the hand was performed but the patient complained for pain. Increase slight ROM was been noticed for the wrist in the direction of dorsal flexion (approximately 5 degrees). The swelling was slightly decreased after the therapy and the hypertone muscles were totally relaxed.

Self-therapy:

PIR of upper trapezius: The patient can be in sitting or standing position, he will place the left hand on the upper part of head and provide lateral flexion of the head to the left. When the patient reaches the barrier, will provide pressure with his left hand to lateral flexion on the left while the head is moving to the opposite side. Take a breath and hold for 5 seconds and then relax. Repeat this technique for 3-4 times. These instructions are for myorelaxation of right trapezius. With the same principles the patient will perform for the left trapezius which was hypertone also.

PIR of triceps brachii: The patient is in sitting position, with maximal flexion of right elbow (going to the barrier) and the left hand is placed around the distal part of radius-ulnar. While the patient tries to extend the right elbow he puts resistance with the opposite hand. Take a breath and hold it for 5 second and then relax. Repeat this technique for 3-4 times for both triceps.

Active movements of fingers and wrist to increase ROM and strength:

I mentioned those exercises before but we have to advise our patient to repeat them for 15 repetitions every 1 hour at home for each day.

3.5.2. Session 2nd Wednesday on 14.01.2015

Objective: In the second session the patient was feeling pain in the right wrist. He was ready to continue with our therapy. Finally my patient informed me that he didn't provide the exercises that I recommended to him.

Subjective: Slightly decreased the edema, I observed limitation of ROM in radial duction during the examination.

Goals of today's therapeutic uni:

- Reduce pain with active movements of fingers and wrist
- Increase the Range of motion with active exercises of fingers and wrist
- With active exercises of fingers and wrist and also using the exteroceptor ball will be able to decrease edema
- Release the tension of fasciae in forearm
- Increase proprioception by using Propriomed
- Myorelaxation of hypertonic muscles
- Improve bone tissues by using magnetotherapy
- Strengthening exercise with Thera-band in the fingers and wrist
- Decrease the blockage of restricted joints

Execution

1. Soft tissue techniques according to Lewit:

In supine position: We apply simultaneous opposite rotation forces on forearm to release the tension of fasciae

2. Active movements of fingers and wrist to increase ROM and strength:

Sitting position: The patient provides active movements of fingers in flexion, extension, abduction and adduction and all the property movements for wrist and neck. For every direction 15 repetitions will be indicate.

3. Lymphatic drainage using exteroceptor ball:

Sitting position: We apply lymphatic massage by using an exteroceptor ball in caudal-cranial direction.

4. Joint play techniques according to Lewit:

The therapist apply joint play techniques to glenohumeral joint in the direction of caudal, dorsal and ventral and also cervical spine in direction of lateral flexion in both

sides. Moreover in carpometacarpal, interphalangeal and metacarpophalangeal joints were performed joint play in all directions.

5. Improve proprioception with Propriomed:

Standing position: By using a Propriomed the patient will start to provide quick repeated movements (only by the shoulder) in ventral and dorsal direction.

6. Post isometric relaxation techniques according to Lewit:

We apply PIR for myorelaxation of hypertone muscles and more specific for upper trapezius, sternocleidomastoid, levator scapulae, pectoralis major and triceps brachii in both sides.

7. Strengthening exercise for fingers and wrist with Thera-band:

The patient places the Thera-band in palmar side of the fingers and starts to provide extension and abduction of the fingers. Then the shaft part of the Thera-band is located around the palm and the patient provides dorsal-plantar flexion. For every direction 15 repetitions will be indicate.

8. Physical therapy:

Magnetotherapy was indicated for the bone tissues of the right wrist. The duration of this therapy is 25 min.

Results:

In second session the patient was still feeling the pain, when he was providing maximal dorsal flexion of the wrist as before but the pain level was even less. When I examined the ROM of the wrist in the beginning of session I observed limitation of ROM in radial duction but at the end of the today's therapy the ROM was returned as in the first session. The ROM was the same as the first session and the swelling was decreased even more but it was still visible. PIR was recommended because of the appearance of hypertone muscles.

Self-therapy:

PIR for triceps brachii and upper trapezius: The patient has already be informed by the therapist how to provide them.

Active movements of fingers and wrist to increase ROM and strength:

I advised my patient from now on to repeat those exercises for 15 repetitions every 1 hour per day at home.

3.5.3. Session 3rd Friday on 16.01.2015

Objective: In the third session the patient was feeling slightly pain in the right wrist. He was ready to continue with our therapy. My patient informed me that he provided the exercises that I suggest to him and the pain was appearing rarely on Thursday (specific date: 15.01.2015).

Subjective: Slightly decreased the edema, I observed limitation of ROM in radial duction during the examination.

Goals of today's therapeutic unti:

- Reduce pain with active movements of fingers and wrist.
- Increase the Range of motion with active exercises of fingers and wrist
- With active exercises of fingers and wrist and also using the exteroceptor ball will be able to decrease edema
- Increase proprioception by using Propriomed
- Strengthening exercises with Thera-band in the fingers and wrist
- Improve bone tissues by using magnetotherapy
- Unblock restricted joints
- Strengthening exercise for the muscles of hand and forearm using a ball.

Execution

1. **Active movements of fingers and wrist to increase ROM and strength:**

Sitting position: The patient provides active movements of fingers in flexion, extension, abduction and adduction and all the property movements for wrist and neck. For every direction 15 repetitions will be indicate.

2. **Lymphatic drainage using exteroceptor ball:**

Sitting position: We apply lymphatic massage by using an exteroceptor ball in caudal-cranial direction.

3. **Joint play techniques according to Lewit:**

The therapist apply joint play techniques to glenohumeral joint in the direction of caudal, dorsal and ventral and also cervical spine in direction of lateral flexion in both sides. Moreover in carpometacarpal, interphalangeal and metacarpophalangeal joints were performed joint play in all directions.

4. **Improve proprioception with Propriomed:**

Standing position: By using a Propriomed the patient will start to provide quick repeated movements (only by the shoulder) in ventral and dorsal direction.

5. **Strengthening exercise for fingers and wrist with Thera-band:**

The patient places the Thera-band in palmar side of the fingers and starts to provide extension and abduction of the fingers. Then the shaft part of the Thera-band is located around the palm and the patient provides dorsal-plantar flexion. For every direction 15 repetitions will be indicate.

6. **Strengthening exercise for hand and forearm muscles by using a small plastic ball:**

The patient will try to squeeze it a couple of times (15-20) so the extensors and flexors of hand and forearm will be activate and even increase their strength.

7. Physical therapy:

Magnetotherapy was indicated for the bone tissues of the right wrist. The duration of this therapy is 25 min.

Results:

In third session the patient was still feeling the pain, when he was providing maximal dorsal flexion of the wrist as before but the pain level was even less. There wasn't any improvement in ROM of the wrist. The ROM was still the same but the swelling was decreased even more but it was still visible. I can say that we are able for our patient to start more advance strengthening exercise for his wrist.

Self-therapy:

Active movements of fingers and wrist to increase ROM and strength:

I advised my patient from now on to repeat those exercises for 15 repetitions every 1 hour per day at home.

Strengthening exercise for hand and forearm muscles by using a small plastic ball:

The patient had a similar plastic ball so he will be able to repeat this exercise at home.

3.5.4. Session 4th Monday 19.01.2015

Objective: In fourth session the patient was still feeling slightly pain in the right wrist. There was slight improvement in ROM of the wrist in direction of dorsal flexion for 5° more (70° degrees).

Subjective: There was slight improvement in ROM of the wrist in direction of dorsal flexion for 5° more (70° degrees). The edema was decreased even more but it was still visible. The patient was able to put load to his right wrist without so much pain as before.

Goals of today's therapeutic unit:

- Reduce pain with active movements of fingers and wrist
- Increase the Range of motion with active exercises of fingers and wrist

- With active exercises of fingers and wrist and also using the exteroceptor ball will be able to decrease edema
- Increase proprioception by using Propriomed
- Strengthening exercises with Thera-band in the fingers and wrist
- Improve bone tissues by using magnetotherapy
- Unblock restricted joints
- Strengthening exercise for the muscles of hand and forearm using a ball
- Strengthening exercise for both arms and shoulders muscles.

Execution

1. **Active movements of fingers and wrist to increase ROM and strength:**

Sitting position: The patient provides active movements of fingers in flexion, extension, abduction and adduction and all the property movements for wrist and neck. For every direction 15 repetitions will be indicate.

2. **Lymphatic drainage using exteroceptor ball:**

Sitting position: We apply lymphatic massage by using an exteroceptor ball in caudal-cranial direction.

3. **Joint play techniques according to Lewit:**

The therapist apply joint play techniques to glenohumeral joint in the direction of caudal, dorsal and ventral and also cervical spine in direction of lateral flexion in both sides. Moreover in carpometacarpal, interphalangeal and metacarpophalangeal joints were performed joint play in all directions.

4. **Improve proprioception with Propriomed:**

Standing position: By using a Propriomed the patient will start to provide quick repeated movements (only by the shoulder) in ventral and dorsal direction.

5. **Strengthening exercise for fingers and wrist with Thera-band:**

The patient places the Thera-band in palmar side of the fingers and starts to provide

extension and abduction of the fingers. Then the shaft part of the Thera-band is located around the palm and the patient provides dorsal-plantar flexion. For every direction 15 repetitions will be indicate.

6. Strengthening exercise for hand and forearm muscles by using a small plastic ball:

The patient will try to squeeze it a couple of times (15-20) so the extensors and flexors of hand and forearm will be activate and even increase their strength.

7. Push-ups against the wall:

We gave correct instructions to our patient for the properly posture that he has to have with 10 repetitions in 2 sets for the first day.

8. Physical therapy:

Magnetotherapy was indicated for the bone tissues of the right wrist. The duration of this therapy is 25 min.

Results:

In fourth session the patient was still feeling the pain, when he was providing maximal dorsal flexion of the wrist but the pain level was decrease to minimum. There was slight improvement in ROM of the wrist in direction of dorsal flexion for 5° more (70° degrees).

As I mentioned before there was an improvement in ROM of wrist in the direction of dorsal flexion. The edema was decreased even more but it was still visible. The patient was able to put load to his right wrist without so much pain as before.

Self-therapy:

Active movements of fingers and wrist to increase ROM and strength:

I advised my patient from now on to repeat those exercises for 15 repetitions every 1 hour per day at home.

Strengthening exercise for hand and forearm muscles by using a small plastic ball:

The patient had a similar plastic ball so he will be able to repeat this exercise at home.

Push-ups against the wall:

The patient should provide 10 push-ups against the wall for 2 sets in the first day.

3.5.5. Session 5th Wednesday on 21.01.2015

Objective: In fifth session the pain threshold and the ROM were the same as the previous time but he was feeling much more confident.

Subjective: The edema was almost disappeared, hypertonicity of upper trapezius, sternocleidomastoids and the right triceps brachii were noticed.

Goals of today's therapeutic unit:

- Reduce pain with active movements of fingers and wrist
- Increase the Range of motion with active exercises of fingers, wrist and neck
- With active exercises of fingers and wrist and also using the exteroceptor ball will be able to decrease edema
- Increase proprioception by using Propriomed
- Myorelaxation of hypertone muscles
- Improve bone tissues by using magnetotherapy
- Unblock restricted joints
- Strengthening exercise for the muscles of hand and forearm using a ball
- Strengthening exercise for both arms and shoulders muscles.

Execution

1. Active movements of fingers and wrist to increase ROM and strength:

Sitting position: The patient provides active movements of fingers in flexion, extension, abduction and adduction and all the property movements for wrist and neck.

For every direction 15 repetitions will be indicate.

2. Lymphatic drainage using exteroceptor ball:

Sitting position: We apply lymphatic massage by using an exteroceptor ball in caudal-cranial direction.

3. Joint play techniques according to Lewit:

The therapist apply joint play techniques to glenohumeral joint in the direction of caudal, dorsal and ventral and also cervical spine in direction of lateral flexion in both sides. Moreover in carpometacarpal, interphalangeal and metacarpophalangeal joints were performed joint play in all directions.

4. Improve proprioception with Propriomed:

Standing position: By using a Propriomed the patient will start to provide quick repeated movements (only by the shoulder) in ventral and dorsal direction.

5. Post isometric relaxation techniques according to Lewit:

We apply PIR for myorelaxation of hypertone muscles and more specific for upper trapezius, sternocleidomastoid in both sides and triceps brachii in the right side.

6. Strengthening exercise for hand and forearm muscles by using a small plastic ball:

The patient will try to squeeze it a couple of times (15-20) so the extensors and flexors of hand and forearm will increase their strength.

7. Push-ups against the floor:

We gave correct instructions to our patient for the properly posture that he has to have with 10 repetitions in 2 sets but the knees should touch the floor, we don't want to overload the wrist by the whole weight of body.

8. Physical therapy:

Magnetotherapy was indicated for the bone tissues of the right wrist. The duration of this therapy is 25 min.

Results:

In fifth session the pain threshold and the ROM were the same as the previous time but he was feeling much more confident and impressed with his muscle strength improvement and reduction of pain during the exercises. The patient was able to put even more load to his right wrist with a slight disturbance as he described it. The edema was finally disappeared and the myorelaxation of the hypertone upper trapezius, sternocleidomastoids and the right triceps brachii were been successful.

Self-therapy:

Active movements of fingers and wrist to increase ROM and strength:

I advised my patient from now on to repeat those exercises for 15 repetitions every 1 hour per day at home.

Strengthening exercise for hand and forearm muscles by using a small plastic ball:

The patient had a similar plastic ball so he will be able to repeat this exercise at home.

Push-ups against the floor:

The patient should provide 10 push-ups against the wall for 2 sets per day.

3.5.6. Session 6th Friday on 23.01.2015

Objective: In six and last session the pain threshold and ROM of the wrist were same as the previous time. He felt stronger from the previous session and confident with his situation.

Subjective: I can say that the patient expressed his happiness with a smile for the improvement of those few days of physiotherapies but he needs to continue the training to prevent any deformity or complication.

- Increase the Range of motion and decrease the pain in the wrist with active exercises of fingers and wrist
- Increase proprioception by using Propriomed
- Improve bone tissues by using magnetotherapy
- Unblock restricted joints
- Strengthening exercise for the muscles of hand and forearm using a ball
- Strengthening exercise for the weak muscles of the hand using PNF.

Execution

1. **Active movements of fingers and wrist to increase ROM and strength:**

Sitting position: The patient provides active movements of fingers in flexion, extension, abduction and adduction and all the property movements for wrist and neck. For every direction 15 repetitions will be indicate.

2. **Joint play techniques according to Lewit:**

The therapist apply joint play techniques to glenohumeral joint in the direction of caudal, dorsal and ventral and also cervical spine in direction of lateral flexion in both sides. Moreover in carpometacarpal, interphalangeal and metacarpophalangeal joints were performed joint play in all directions.

3. **Improve proprioception with Propriomed:**

Standing position: By using a Propriomed the patient will start to provide quick repeated movements (only by the shoulder) in ventral and dorsal direction.

4. **Strengthening exercise for hand and forearm muscles by using a small plastic ball:**

The patient will try to squeeze it a couple of times (15-20) so the extensors and flexors of hand and forearm will increase their strength.

5. Push-ups against the floor:

We gave correct instructions to our patient for the properly posture that he has to have with 10 repetitions in 2 sets but the knees should touch the floor, we don't want to overload the wrist by the whole weight of body.

6. PNF for strengthening the weak muscles of the hand:

We apply slow reversal technique in the 1st flexion-extension and 2nd flexion-extension diagonal for strengthening the weak muscles of the hand.

7. Physical therapy:

Magnetotherapy was indicated for the bone tissues of the right wrist. The duration of this therapy is 25 min.

Results:

In six and last session the pain threshold was the same as the previous time but the ROM of the wrist in radial duction was slightly increase for 5° degrees. Even he felt stronger from the previous session. The patient expressed his happiness with a smile for the improvement of those few days of physiotherapies but he needs to continue the training to prevent any deformity or complication. Using PNF in the last session I observe that the patient was able to provide it without pain.

Self-therapy:

Active movements of fingers and wrist to increase ROM and strength:

I advised my patient from now on to repeat those exercises for 15 repetitions every 1 hour per day at home.

Strengthening exercise for hand and forearm muscles by using a small plastic ball:

The patient had a similar plastic ball so he will be able to repeat this exercise at home.

Push-ups against the floor:

The patient should provide 10 push-ups against the wall for 2 sets per day.

3.6 Final Kinesiology Examination

3.6.1 Final Observation

- The edema in ventral aspect of the wrist was totally decreased.
- Both wrists are now symmetrical.
- Increase the ROM of the right elbow.
- Decrease slightly the protraction of the head

3.6.2 Final Postural examination

Posterior view

Normal base of foot.
Slight valgosity of Achilles tendon in the right leg.
Popliteal line is in slight external rotation of right knee joints.
Both calf muscles are hypertrophic.
Both thighs are hypertrophic.
Posterior iliac spines are in the same level.
Posterior iliac crests are in the same level.
Slight abducted of the left scapula.
The right thoraco-axillar triangular space is bigger that the left one.
The left shoulder was less higher than before.

Table 17 Final postural examination in posterior view.

Anterior view

Slight external rotation of the right foot.
Slight valgosity of the right knee.
Hypertrophy of both Quadriceps.
Normal trophy of both transverse abdominalis and rectus abdominalis.
Left shoulder is less higher and there was reduction of protraction in both shoulders
He seems to put the same weight on both side.
Both clavicles look symmetrical.
Thoraco-axillar triangle space in the right side is bigger.
Slight decrease the protraction of the head.

Table 18 Final postural examination in anterior view

Lateral view (right side)

He places more weight on the medial aspect of foot and metatarsal heads.
Right knee is extended.
Slight flexion of hip.
Slight anterior tilt of pelvis.
Slight lordosis in the lumbar region.

Slight kyphosis in thoracic region.
Slight decrease the lordosis in cervical region.
Slight decrease the protraction of the shoulder.
Slightly decrease the protraction of the head.

Table 19 Initial postural examination in lateral view (right side).

Lateral view (left side)

He places more weight on the lateral aspect of foot.
Left knee is extended.
Slight flexion of the hip.
Slight anterior tilt of pelvis.
Slight lordosis of lumbar region.
Slight kyphosis of thoracic region.
Slight decrease the lordosis of cervical region.
Slight decrease the protraction of the shoulder.
Slight decrease the protraction of the head.

Table 20 Final postural examination in lateral side (left side).

3.6.3 Final Dynamic examination

Extension: The patient is able to provide the movement in physiological range of motion without pain and with properly movements of thoracic and lumber area.

Flexion: The patient is able to provide flexion of the trunk without pain and the ROM was increased but he couldn't touch the floor

Lateral flexion: The patient was able to provide lateral flexion of the trunk in both sides without pain and looked more symmetrical.

3.6.4 Final Anthropometric measurements of upper extremities

Length	Right arm	Left arm
Circumference of the upper arm	32	32
Circumference of the forearm	27	27
The length of whole upper extremity	84	84
The length of the humerus	38	39
The length of the forearm	30	29
The length of the hand	22	22.5

Table 21 Final examination of Anthropometry measurement of upper extremities

3.6.5 Final Range of motion examination according to Kendall

Shoulder joint					
Active	Right	Left	Passive	Right	Left
Flexion	160	165	Flexion	165	165

Extension	30	30	Extension	30	30
Abduction	170	170	Abduction	170	170
External rotation	80	80	External rotation	80	85
Internal rotation	55	60	Internal rotation	60	60

Table 22 Final examination of ROM in shoulder

Elbow joint					
Active	Right	Left	Passive	Right	Left
Flexion	150	150	Flexion	150	150

Table 23 Final examination of ROM of Elbow joint

Radioulnar joint					
Active	Right	Left	Passive	Right	Left
Supination	75	75	Supination	75	75
Pronation	75	75	Pronation	75	75

Table 24 Final examination of ROM of Radioulnar joint

Wrist joint					
Active	Right	Left	Passive	Right	Left
Dorsal Flexion	70	75	Dorsal Flexion	75	75
Palmar Flexion	65	75	Plantar Flexion	65	75
Ulnar duction	35	40	Ulnar duction	35	40
Radial duction	15	20	Radial duction	15	20

Table 25 Final examination of ROM of Wrist joint

The patient felt slight pain in his maximal dorsal flexion of wrist.

3.6.6 Final Muscle tone examination

Muscles	Right	Left
Upper trapezius	Normal tone	Normal tone
Middle trapezius	Normal tone	Normal tone
Lower trapezius	Normal tone	Normal tone
Deltoid Anterior	Normal tone	Normal tone

Deltoid Posterior	Normal tone	Normal tone
Pectoralis Major	Normal tone	Normal tone
Latissimus Dorsi	Normal tone	Normal tone
Biceps Brachii	Normal tone	Normal tone
Triceps Brachii	Normal tone	Normal tone
Flexors of forearm	Normal tone	Normal tone
Extensors of forearm	Normal tone	Normal tone
Sternocleidomastoid	Hypertone	Hypertone
Scalene muscles	Hypertone	Hypertone
Longus colli	Hypertone	Hypertone
Longus capitis	Hypertone	Hypertone

Table 26 Final examination of muscle tone of upper extremity

3.6.7 Soft tissue examination according to Lewit

Examination of fasciae: By placing both hands on each forearm and with simultaneous opposite rotation forces and I find restriction in both directions (medial-lateral). Improve the elasticity of fasciae.

3.6.8 Muscle strength test according to Kendall

Upper extremities		
Muscles	Right	Left
Upper trapezius	5	5

Middle trapezius	4+	4+
Lower trapezius	4+	4+
Levator scapulae	4+	4+
Latissimus dorsi	4+	4+
Teres major	4	4
Pectoralis major upper fibres	5	5
Pectoralis major lower fibres	4	4
Pectoralis minor	4+	4+
Deltoid anterior	4+	4+
Deltoid medius	4+	4+
Deltoid posterior	4+	4+
Coracobrachialis	4	4
Triceps brachii + Anconeus	4+	4+
Biceps brachii + brachialis	4+	4+
Supinator	3+	3+
Pronator quadratus	3+	3+
Extensor carpi ulnaris	3+	4

Extensor carpi radialis longus + brevis	4	4+
Flexor carpi radialis	4	4
Flexor carpi ulnaris	4+	4+
Flexor digitorum superficialis	4	4
Extensor digitorum	3+	4
Palmaris longus	4	4
Palmar interossei 1st-4th	3+	4
Dorsal interossei 1st-4th	4+	4
Flexor digiti minimi	3+	4
Abductor digiti minimi	3+	4
Abductor pollicis longus	3+	4
Extensor pollicis longus	3	3
Extensor pollicis brevis	3+	3
Flexor pollicis longus	3+	3
Flexor pollicis brevis	3	3
Opponens digiti minimi	3	3

Table 27 Final examination of muscle strength in upper extremities

3.6.9 Final Muscle length examination according to Lewit

Upper extremities		
Muscles	Right	Left
Scalene muscles	1	1
Upper trapezius	0	0
Levator scapulae	0	0
Sternocleidomastoid	0	0

Table 28 Final examination of muscle length of upper extremities.

3.6.10 Final Joint play examination according to Lewit

I applied examination of joint play on the fingers, wrists, elbows and shoulders joints in both sides.

Wrist joint:

Right hand

Examination in direction of dorsal flexion: There was limitation.

Examination in direction of palmar flexion: There wasn't any limitation.

Examination in direction of ulnar duction: There wasn't any limitation of joint play

Examination in direction of radial duction: There was limitation of joint play.

Left hand

Examination in direction of dorsal flexion: There wasn't any limitation of joint play.

Examination in direction of palmar flexion: There wasn't any limitation of joint play.

Examination in direction of ulnar duction: There wasn't any limitation of joint play.

Examination in direction of radial duction: There wasn't any limitation of joint play.

Elbow joint:

Right elbow

Examination in direction of lateral side: There wasn't any limitation of joint play.

Examination in direction of medial side: There wasn't any limitation of joint play.

Left elbow

Examination in direction of lateral side: There wasn't any limitation of joint play.

Examination in direction of medial side: There wasn't any restriction.

Shoulder joint

Right shoulder

Examination of glenohumeral joint in ventral direction: There was limitation of joint play.

Examination of glenohumeral joint in lateral direction: There wasn't any limitation of joint play.

Examination of glenohumeral joint in dorsal direction: There was limitation of joint play.

Examination of glenohumeral joint in caudal direction: There was limitation of joint play.

Left shoulder

Examination of glenohumeral joint in ventral direction: There wasn't limitation of joint play.

Examination of glenohumeral joint in lateral direction: There wasn't limitation of joint play.

Examination of glenohumeral joint in dorsal direction: There wasn't limitation of joint play.

Examination of glenohumeral joint in caudal direction: There wasn't limitation of joint play.

Fingers

Examination of metacarpophalangeal joint in all directions: There were limitations of joint play.

Examination of carpometacarpal joint in all directions: There were limitations of joint play.

Examination of interphalangeal joint in all directions: There were limitations of joint play.

3.6.11 Final Neurological examination

Deep tendon reflex:

Biceps brachii (C5-6): physiological reaction in both sides, grade 2.

Triceps brachii (C7): physiological reaction in both sides, grade 2.

Flexors of wrist (C8): physiological reaction in both sides, grade 2.

Deep sensation:

Stereognosis: physiological reaction.

Kinesthesia: physiological reaction.

Superficial sensation:

Light touch: physiological in both sides.

3.6.12 Conclusion of final kinesiology examination

After all the examination procedures I observe slight improvement in his posture, the

protraction of head and the elevated left shoulder were decreased. The ROM of elbows in flexion was increased in 150° and also there was improvement for the ROM of wrists in the directions of dorsal-flexion (left-75, right-70) and radial duction (15° both). Another goal of my therapy was to relax his hypertonic muscles as I successful did it excepting his neck muscles which are usually hypertonic due to over activity during the day. Improvement of his muscle strength was observed after the final muscle strength examination and some of them were; pectoralis minor-major, deltoids, triceps brachii, biceps brachii, supinator and some flexors and extensors of fingers. Moreover during the final muscle length examination I noticed improvement of upper trapezius and sternocleidomastoids in both sides. During the final joint play examination there was an improvement in right wrist joint in the direction of ulnar deviation that it was unblocked but the carpometacarpal, interphalangeal and metacarpophalangeal joints where still blocked.

3.7 Evaluation of the effect of the therapy

My first contact with the patient was on 12 of January at Ústřední Vojenská Nemocnice in which I informed from my opponent supervisor that the patient is suffering from arthrosis of the right wrist joint. The therapy which was applied in the patient was effective according to the results. More specifically during the whole sessions of the therapies there was pain relief of the wrist which I think was the most problematic part of the patient according to the examinations. Moreover some restrictions were found during the joint play examination especially in carpometacarpal, metacarpophalangel and interphalangeal joints in all directions of the right hand even I applied joint pay techniques.

Through the therapeutic procedures, there was retrieval of ROM in neck in the direction of flexion and rotation, in elbows in direction of flexion and in wrist in direction of dorsal flexion and radial duction. The active exercises and stretching helped the patient to achieve this improvement.

Furthermore the strengthening exercises were beneficial for the ROM of the patient. Active exercises combine with the Lymphatic massage helped for the reduction of edema in the ventral aspect of the wrist.

The fasciae in both forearms were totally got their elasticity after the therapy and via the strengthening exercises according the final muscles strength (according to Kendall), the patient had improvement of the strength in weak muscles.

Myorelaxation of the hypertonic muscles especially in the neck was the result after PIR techniques (According to Lewit) and moreover there was reduction of protraction of head and shoulders.

Finally I believe that the mentioned therapy for the rehabilitation of the patient had positive results if we take apart the goals of therapy. Except the therapeutic procedures it was very important the good cooperation of my patient. My opinion is that the patient should continue with those exercises that I mentioned to prevent any complication.

3.8 Prognosis

The patient had six rehabilitation sessions for his neck pain and arthrosis of the wrist joint. Almost all of our goals of my rehabilitation plan were achieved. I believe with my therapeutic program the patient will not be able to treat totally his disorder but he will prevent any complication as pain, decrease his ROM of wrist, fingers, and weakness of the muscles in upper extremity etc. That's why the patient has to follow the plan as we described it.

4. Conclusion

I came to the conclusion that the main problem my patient had, was the pain around the wrist joint and the limitation of carpometacarpal, metacarpophalangeal and interphalangeal joints in all directions. Then pain was responsible for the muscle weakness because there was limitation of loading of right hand. My patient was cooperative with positive thinking of achieving the goals of our therapy. Taking advantage of my knowledge that I gained from my studies at Charles University, I observe improvement of ROM, myorelaxation of hypertone muscles, increasing the strength of weak muscles so the patient can deal with his daily activities with more confidence and convenience. My clinical work practice took place at U.V.N (Ústřední Vojenská Nemocnice) on January 12-23 in 2015 under the supervised of Mgr

Romana Kozderková. The people in the hospital and more specific at U.V.N that work are organized with great attitude to treat the patients. Mrs Kozderková suggested me to deal with this diagnosis and I found it very interesting. A big challenge appeared to me to deal with Arthritis because is a common disease but at the same time difficult to cure it. I spend a lot of hours to investigate my topic and find the best solutions to treat it. In the end I can say that have got deple to the problematic point of view of the wrist. Finally I would like to express my gratitude to my supervisors, Mgr. Lenka Satrapová, PhD and Mgr. Romana Kozderková for their guidance and our cooperation.

5. Bibliography

Book references

1. Kendall, F. P. (2005). In *Muscles Testing and Function with Posture and Pain* (5th ed.). Philadelphia: Lippincott Williams & Wilkins
2. Kolář, P. (2013). In *Clinical Rehabilitation*. Prague: Rehabilitation Prague School.
3. Lewit, K. (2010). Therapeutic techniques. In *Manipulative Therapy Musculoskeletal Medicine*. Prague: Churchill Livingstone
4. Tank, P. W. (2009). The Upper Limb. In *Atlas of Anatomy*. Philadelphia: Lippincott Williams & Wilkins
5. Netter, F. (2006). *Atlas of Human Anatomy*. (6th ed.). United States of America: Saunders Elsevier
6. Feneis, H., & Dauber, W. (2000). *Pocket Atlas of Human Anatomy*. (4th ed.). New York: Thieme Stuttgart
7. Clemente, D. (2006). *A Regional Atlas of the Human Body*. (6th ed.). Germany: Lippincott Williams & Wilkins
8. Kaufman, JA. (2013). *Vascular and Interventional Radiology*. (2nd ed.). United States of America: Saunders Elsevier
9. Lee, SK. (2014). *Hand and Wrist Arthritis*. United States of America: AAOS.
10. Glickel, SZ., Bernstein, RA. (2011). *Arthritis of the Hand and Upper extremity: A Master Skills Publication*. United States of America: American Society for Surgery of the Hand.

Articles references

11. Sennwald, G., Kern, HP., Jacob, HA. (1993). Arthrosis of the wrist joint due to carpal instability. Therapeutic alternatives. *Pubmed*, 22, 65-71. Retrieved February 15, 2015, from
<http://www.ncbi.nlm.nih.gov/pubmed/8451052>
12. Marks, J. (2009). Arthritis: The Nation's Most Common Cause of Disability. *Arthritis meeting the challenge*. Retrieved on February 16, 2015 from
<http://www.cdc.gov/nccdphp/publications/aag/pdf/arthritis.pdf>
13. Stoppler, M. (2015). Wrist Pain. *Medicinenet*. Retrieved on February 16, 2015 from
http://www.medicinenet.com/wrist_pain/symptoms.htm
14. Berger, R. (1996). The Anatomy and Basic Biomechanics of the Wrist Joint. *Journal of Hand Therapy*. Retrieved on February 17, 2015 from
http://vompti.com/wp-content/uploads/2014/03/Biomechanics-of-the-Wrist_J-Hand-Ther-1996_Berger-RA.pdf
15. Volz, RG., Lieb, M., Benjamin, J. (1980). Biomechanics of the wrist. *Pubmed*. Retrieved on March 4, 2015 from
<http://www.ncbi.nlm.nih.gov/pubmed/7408289>
16. Palmer, AK., Werner, FW., Murphy, D., Glisson, R. (1985). Functional wrist motion: a biomechanical study. *The journal of Hand Surgery*, 10(1), 39-46. Retrieved on March 6, 2015 from
[http://www.jhandsurg.org/article/S0363-5023\(85\)80246-X/abstract](http://www.jhandsurg.org/article/S0363-5023(85)80246-X/abstract)
17. Crook, T., Warwick, D. (2011). Focus on Avoiding fusion in wrist arthritis. *The Journal of Bone & Joint Surgery*. Retrieved on March 5, 2015 from
http://www.boneandjoint.org.uk/sites/default/files/FocusOn_WristArthritis.pdf

18. Lewis, OJ., Hamshere, RJ., Bucknill, TM. (1970). The anatomy of the wrist joint. *Journal of Anatomy*, 106(3), 539-552. Retrieved on 9 March, 2015 from <http://www.ncbi.nlm.nih.gov/pmc/articles/PMC1233428/?page=1>
19. Krucik, GT. (2013) 7 Hand Exercises to ease Arthritis Pain. *Healthline*. Retrieved on March 15, 2015 from <http://www.healthline.com/health/osteoarthritis/arthritis-hand-exercises#Overview1>

Lectures

20. Jalovcová, M. (2012). *Examination and basic therapeutic methods I: Anthropometric measurements*. Lecture`s notes. Charles University in Prague
21. Čemusová, J. (2012). *Introduction to rehabilitation: Physiotherapist and patient`s past history*. Lecture`s notes. Charles University in Prague
22. Jalovcová, M. (2013). *Examination and basic therapeutic methods II: Goniometry*. Lecture`s notes. Charles University in Prague
23. Jalovcová, M. (2013). *Examination and basic therapeutic methods II: Muscle strength testing*. Lecture`s notes. Charles University in Prague
24. Pánek, D. (2013). *Basic Therapeutic Methods III: Neurological examination*. Lectures notes. Charles Univeristy in Prague.
25. Jalovcová, M. (2013). *Basic Therapeutic Methods III: palpation, changes of muscle tone, musculoskeletal dysfunction, according to Lewit*. Lectures notes. Charles University in Prague.
26. Jalovcová, M. (2013) *Basic Therapeutic Methods II: muscle length test, according to Janda*. Lectures notes. Charles Univeristy in Prague.

6. Supplements

- Application for Ethics Board Review
- INFORMOVANÝ SOUHLAS
- List of Tables
- List of Figures
- List of Abbreviation

6.1. Application for Ethics Board Review



CHARLES UNIVERSITY IN PRAGUE
FACULTY OF PHYSICAL EDUCATION AND SPORT
José Martího 31, 162 52 Praha 6-Vešelavín
tel. +420 2 2017 1111
<http://www.ftvs.cuni.cz/>

Application for Ethics Board Review

of the research project, doctoral research, master degree research, undergraduate research, involving human subjects

Project title: Case of study of a patient with diagnosis Arthritis of the wrist joints

Nature of the research project: Bachelor's Thesis

Author (chief investigator): Achilleas Liapis

Supervisor (in case of student research): Mgr. Lenka Satrapová, PhD.

Research project description: Case study of physiotherapy treatment of a patient with the diagnosis of Arthritis of the wrist joints will be conducted under the expert supervision of an experienced physiotherapist at Ústřední Vojenská Nemocnice.
Guaranteed safety to be judged by experts: No invasive methods will be used.
Ethical aspects of the research: Personal data obtained during the case study will not be published.
Informed consent (attached)

Date: 09.02.2015

Author's signature:

Faculty of Physical Education and Sport, Charles University in Prague ETHICS BOARD REVIEW

Ethics Board members: Prof. Ing. Václav Bunc, CSc.
Prof. PhDr. Pavel Slepíčka, DrSc.
Doc. MUDr. Jan Heller, CSc.

The Ethics Board at the Faculty of Physical Education and Sport, Charles University, approved the research project.

Approval number: 041/2015

Date: 10.2.2015

The Ethics Board at the Faculty of Physical Education and Sport, Charles University, reviewed the submitted research project and found no contradictions with valid principles, regulations and international guidelines for biomedical research involving human subjects.

The chief investigator of the project met the necessary requirements for receiving the Ethics Board approval.

Official school stamp

Signature, REB Chairman

UNIVERZITA KARLOVA v Praze
Fakulta tělesné výchovy a sportu
José Martího 31, 162 52, Praha 6

6.2 INFORMOVANÝ SOUHLAS

INFORMOVANÝ SOUHLAS

V souladu se Zákonem o péči o zdraví lidu (§ 23 odst. 2 zákona č.20/1966 Sb.) a Úmluvou o lidských právech a biomedicíně č. 96/2001, Vás žádám o souhlas k vyšetření a následné terapii. Dále Vás žádám o souhlas k nahlížení do Vaší dokumentace osobou získávající způsobilost k výkonu zdravotnického povolání v rámci praktické výuky a s uveřejněním výsledků terapie v rámci bakalářské práce na FTVS UK. Osobní data v této studii nebudou uvedena. Dnešního dne jsem byla odborným pracovníkem poučena o plánovaném vyšetření a následné terapii. Prohlašuji a svým dále uvedeným vlastnoručním podpisem potvrzuji, že odborný pracovník, který mi poskytl poučení, mi osobně vysvětlil vše, co je obsahem tohoto písemného informovaného souhlasu, a měla jsem možnost klást mu otázky, na které mi řádně odpověděl. Prohlašuji, že jsem shora uvedenému poučení plně porozuměla a výslovně souhlasím s provedením vyšetření a následnou terapií. Souhlasím s nahlížením níže jmenované osoby do mé dokumentace a s uveřejněním výsledků terapie v rámci studie.

Datum:.....

Osoba, která provedla poučení:.....

Podpis osoby, která provedla poučení:.....

Vlastnoruční podpis pacienta /tky:.....

6.3 List of tables

- Table 1: Flexors of the hand
- Table 2: Extensors muscles of the hand
- Table 3: Rotators of the forearm
- Table 4: Wrist and Palm of the Hand
- Table 5: Initial postural examination in posterior view
- Table 6: Initial postural examination in anterior view
- Table 7: Initial postural examination in lateral view (right side)
- Table 8: Initial postural examination in lateral side (left side).
- Table 9: Initial examination of Anthropometry measurement of upper extremities
- Table 10: Initial examination of ROM of Shoulder joint
- Table 11: Initial examination of ROM of Elbow joint
- Table 12: Initial examination of ROM of Radioulnar joint
- Table 13: Initial examination of ROM of Wrist joint
- Table 14: Initial examination of muscle tone of upper extremity
- Table 15: Initial examination of muscle strength in upper extremities
- Table 16: Initial examination of muscle length of upper extremities.
- Table 17: Final postural examination in posterior view.
- Table 18: Final postural examination in anterior view
- Table 19: Initial postural examination in lateral view (right side).
- Table 20: Final postural examination in lateral side (left side).
- Table 21: Final examination of Anthropometry measurement of upper extremities
- Table 22: Final examination of ROM of Shoulder joint
- Table 23: Final examination of ROM of Elbow joint
- Table 24: Final examination of ROM of Radioulnar joint
- Table 25: Final examination of ROM of Wrist joint
- Table 26: Final examination of muscle tone of upper extremity
- Table 27: Final examination of muscle strength in upper extremities
- Table 28: Final examination of muscle length of upper extremities.

6.4 List of Figures

- Figure 1: Skeleton of the Distal Upper Limb
- Figure 2: Ligaments of wrist in palmar and posterior view
- Figure 3: Individual muscles of forearm: flexors of wrist
- Figure 4: Muscles of forearm (superficial layer): posterior view
- Figure 5: Intrinsic muscles of hand
- Figure 6: Arteries of forearm
- Figure 7: Wrist and hand: superficial dorsal dissection
- Figure 8: Range of motion of wrist into flexion (blue-left picture), extension (red-left picture), lateral (blue-right picture) and ulnar deviation (red-right picture)
- Figure 9: Movements of Wrist
- Figure 10: X-ray of right wrist in anterior view

6.5 List of Abbreviation

- X-ray – Radiography
- CT – Computer Tomography
- MRI – Magnetic Resonance Image
- BMI – Body Mass Index
- ADL – Activities of Daily Living
- PIR – Post Isometric Relaxation technique, by Lewit
- PNF – Post Neuromuscular Facilitation technique, by Kabat
- U.V.N. - Ústřední Vojenská Nemocnice
- ROM – Range Of Motion