

CHARLES UNIVERSITY IN PRAGUE  
FACULTY OF PHYSICAL EDUCATION AND SPORT  
DEPARTMENT OF PHYSIOTHERAPY

**CASE STUDY: PHYSIOTHERAPY TREATMENT OF A PATIENT  
WITH BELL'S PALSÝ**

BACHELOR DEGREE OF PHYSIOTHERAPY

BACHELOR THESIS

Author: **Dominic Kalafatis**

Supervisor: **Mgr. Helena Vomáčková**

*April 2014, Prague*

## ABSTRACT

**Thesis title:** Physiotherapy treatment of a patient with Bell's palsy

**Author:** Dominic Kalafatis

**Work placement:** Ustředni Vojenská Nemocnice in Prague

### *Summary*

In this bachelor thesis, which was written and composed by myself, it is divided in two parts, the general part and the special part.

The general part mainly is the theoretical part in which it is included the whole anatomy of the face, the facial and neck muscles. The cranial nerves and specifically the facial nerve, the seventh cranial nerve. Kinesiology of the facial muscles for any facial expression. All these components will be described in this part. Secondly, the special part which is the most important part of the whole bachelor thesis, is the part of the case of my patient with Bell's palsy/ Facial paresis. There will be the whole anamnesis, the initial kinesiological examinations, therapy sessions, the final kinesiological examinations in which there are also the improvements of my patient and finally the evaluation of the therapies.

The last part of my bachelor thesis it is composed from my bibliography which contains the literature which I used to write the general part of my bachelor thesis. The list of figures and tables from the whole thesis. The abbreviations and finally the last thing is the ethics committee.

**Key words:** Facial paresis, Bell's palsy, facial nerve, physiotherapy, surgery, cold wind, herpes simplex virus and Lyme disease.

## DECLARATION

I declare that in this bachelor thesis, it was managed and composed by myself. I followed up the guidelines and advices of Mgr. Helena Vomáčková.

During my practice at Ustředni Vojenská Nemocnice in Prague (UVN) I was supervised by Bc. Michaela Stránská and the patient that I have chosen had ten (10) therapy sessions which were performed by myself as well.

I also declare that all the personal information, examinations, therapeutic sessions and procedures were applied based on my own knowledge which I gained in these 3 years of studying at Charles University of Prague at the Faculty of Physical Education and Sport, Department of Physiotherapy.

**Dominic Kalafatis**  
**Prague, April 2014**

## ACKNOWLEDGEMENT

I would like to thank my supervisor Mgr. Helena Vomáčková for helping me, instructing me and being cooperative with me. For all the special advices and guidelines to make this bachelor thesis as much possible perfect. Special thanks also goes to all my teachers of Charles University who taught me this science. Thank you in advance for all the advices, the knowledge and also the motivation for being a good and professional physiotherapist.

## DEDICATION

First of all, I would like to dedicate this bachelor thesis to my parents and my sister by giving me the chance to start my dream of being a good, supportive physiotherapist, my professional carrier and studying to the Charles University in Prague. Also I would like to thank them because always they were supporting me in any hard difficulty that I experienced not only during my studies in Prague but also in my whole life. I hope one day I would be able to do the same thing to my offsprings. I know that a simple ‘‘thank you’’ is not enough for all their help but I will say it in another way in the future. Achieving the goal of earning the diploma of bachelor thesis covers only the appreciation and the proudness from my parents.

Then I would like to thank all my colleagues who proved me with their actions of support and cooperation in these 3 years and especially in the last year that they’ll be very successful physiotherapists but not only known by their knowledge but also from their value of being a good and kind person. Also I would like to give special thanks to my two best colleagues Konstantinos Falidas and Emmanouil Kassakis who didn’t only stand by me for my studies but also stood by me as good friends as well.

Another thing I should say is that I am very thankful also for another person and I am really glad that I met him. Antonios Markantonakis have been one of my best teachers of life in these 3 years of studies in Prague. A big thank you for all the mistakes that you told me not to do and for the purest advices that you shared with me to make me a better person.

Finally, I would like from the purest part of my heart to give more special thanks also to my two best brother-like friends George Kezeris and Alex Lazaridis who however the long distance between Czech Republic and Rhodes island of Greece, they were supporting, encouraging and being proud of me.

## TABLE OF CONTENTS

1. Introduction .....	4
2. General part .....	5
2.1. Anatomy .....	5
2.1.1. Cranial bones .....	5
2.1.1.1. <i>Frontal bone</i> .....	5
2.1.1.2. <i>Parietal bone</i> .....	5
2.1.1.3. <i>Temporal bone</i> .....	6
2.1.1.4. <i>Occipital bone</i> .....	7
2.1.1.5. <i>Sphenoid bone</i> .....	8
2.1.1.6. <i>Ethmoid bone</i> .....	9
2.1.1.7. <i>Nasal bones</i> .....	9
2.1.1.8. <i>Lacrimal bones</i> .....	9
2.1.1.9. <i>Palatine bones</i> .....	10
2.1.1.10. <i>Maxillae</i> .....	10
2.1.1.11. <i>Zygomatic bones</i> .....	10
2.1.1.12. <i>Mandible</i> .....	10
2.1.2. The temporomandibular joint .....	11
2.1.3. Ligaments and connective tissues .....	12
2.1.3.1. <i>Sutures</i> .....	12
2.1.3.2. <i>Syndesmoses</i> .....	13
2.1.3.3. <i>Interosseous membranes</i> .....	13
2.1.4. Cranial nerves .....	13
2.1.5. Facial, masticatory muscles and fascia .....	17
2.2. Kinesiology of the facial expressions and the cervical spine .....	24
2.2.1.1. Functional anatomy of the face .....	24
2.2.1.2. Facial muscle control process .....	24
2.2.1.3. Dynamic facial images .....	25
2.2.1.4. Normal kinematics of the upper cervical spine .....	25
2.3. Bell's palsy .....	27
2.3.1.1. Classification of bell's palsy .....	27
2.3.1.2. Pathology .....	27
2.3.1.3. Etiology .....	28

2.3.1.4. Infectious and inflammatory origin .....	28
2.3.1.5. Other possible causes .....	29
2.3.1.6. Differential diagnosis .....	30
2.3.1.7. Symptoms .....	30
2.3.1.8. Examination methods.....	34
2.3.1.9. Treatment of peripheral facial nerve palsy .....	35
2.3.1.10. Activities of daily living (ADL) .....	37
3. Special part (case study).....	38
3.1. Methodology .....	38
3.2. Anamnesis .....	39
3.2.1.1. Present state .....	39
3.2.1.2. Personal anamnesis .....	40
3.2.1.3. Operational anamnesi.....	40
3.2.1.4. Family anamnesis.....	40
3.2.1.5. Social anamnesis .....	40
3.2.1.6. Occupational anamnesis.....	40
3.2.1.7. Hobbies - ADL.....	40
3.2.1.8. Allergic anamnesis .....	40
3.2.1.9. Pharmacological anamnesis .....	40
3.2.1.10. Abuses.....	40
3.2.1.11. Previous rehabilitation .....	41
3.2.1.12. Statement from the patient's medical documentation.....	41
3.2.1.13. Indication of rehabilitation.....	42
3.2.1.14. Differential balance.....	42
3.3. Initial kinesiological examination.....	43
3.3.1.1. Posture examination.....	43
3.3.1.2. Muscle tone testing (palpation) by lewit.....	44
3.3.1.3. Muscle strength test by kendall.....	45
3.3.1.4. Muscle length testing by janda .....	46
3.3.1.5. Rom evaluation in sftr method by russe and gerthard .....	46
3.3.1.6. Breathing examinatio .....	46
3.3.1.7. Movement patterns.....	46
3.3.1.8. Hypermobility examination (by sachse) .....	47
3.3.1.9. Stability examination .....	47
3.3.1.10. Facial expressions test (compared on both sides) .....	47

3.3.1.11. Neurological examination .....	48
3.3.1.12. Soft-tissue examination.....	49
3.3.1.13. Adl examination.....	49
3.3.1.14. Conclusion of examination .....	49
3.4. Short-term and long-term rehabilitation plan.....	50
3.5. Therapy sessions .....	52
<i>1<sup>st</sup> therapy: monday 3<sup>rd</sup> of february 2014 .....</i>	<i>52</i>
<i>2<sup>nd</sup> therapy: tuesday 4<sup>th</sup> of february 2014 .....</i>	<i>56</i>
<i>3<sup>rd</sup> therapy: wednesday 5<sup>th</sup> of february 2014 .....</i>	<i>61</i>
<i>4<sup>th</sup> therapy: thursday 6<sup>th</sup> of february 2014 .....</i>	<i>65</i>
<i>5<sup>th</sup> therapy: friday 7<sup>th</sup> of february 2014.....</i>	<i>68</i>
<i>6<sup>th</sup> therapy: monday 10<sup>th</sup> of february 2014 .....</i>	<i>72</i>
<i>7<sup>th</sup> therapy: tuesday 11<sup>th</sup> of february 2014 .....</i>	<i>76</i>
<i>8<sup>th</sup> therapy: wednesday 12<sup>th</sup> of february 2014.....</i>	<i>80</i>
<i>9<sup>th</sup> therapy: thursday 13<sup>th</sup> of february 2014 .....</i>	<i>84</i>
<i>10<sup>th</sup> therapy: friday 14<sup>th</sup> of february 2014.....</i>	<i>88</i>
3.6. Final kinesiologic examination .....	92
3.6.1.1. Posture examination.....	92
3.6.1.2. Muscle strength testing by kenda.....	92
3.6.1.3. Muscle length testing by janda .....	93
3.6.1.4. Facial expressions test (compared on both sides) .....	93
4. Conclusion .....	94
5. Bibliography.....	95
6. Supplements .....	99
6.1. List of tables.....	99
6.2. List of figures .....	99
6.3. Abbreviations.....	98
6.4. Application for ethics board review.....	101



# **1. INTRODUCTION**

This case of study was chosen by me because I found it quite interesting and I was happy to collaborate with this patient who was also very kind with me.

In this bachelor thesis my aim is to explain in details the injury of the facial nerve in all the possible ways.

I am going to talk about the diagnosis which was mentioned previously. The topic will be split into:

1. Theoretical in which it will be analyzed the anatomy of all the muscles of the head, masticatory muscles and neck. The muscles of the all the facial expressions. Then it will be analyzed the nervous system and specifically the 7<sup>th</sup> (seventh) cranial nerve which is the facial nerve which in this case is the one most affected. Any disorders of the peripheral nervous system, neuropraxia, axonotmesis, neurotmesis etc. Topographic distribution of lesions of the facial nerve, peripheral paralysis, central paralysis, nuclear palsy. The epidemiology of this case, etiopathogenesis of peripheral facial palsy. Infectious and inflammatory origin, tumor processes, traumas, other possible causes, the symptoms. Examination methods of the facial paresis, treatment procedures. And finally the lifestyle and home measures (ADL).

2. Special part or practical part (case study) in which it will be analyzed the part for the methodology, full anamnesis and examinations of my patient. All his therapies which were performed at Ustředni Vojenská Nemocnice in Prague during the period of Monday 3<sup>rd</sup> (third) of February 2014 till Friday 14<sup>th</sup> (fourteenth) of February 2014. The initial and final kinesiological examination and finally the conclusion and evaluation of the physiotherapeutic rehabilitation.

3. Bibliography of the rest of this bachelor thesis retrieved from any other sources (books, journal, magazines, World Wide Web).

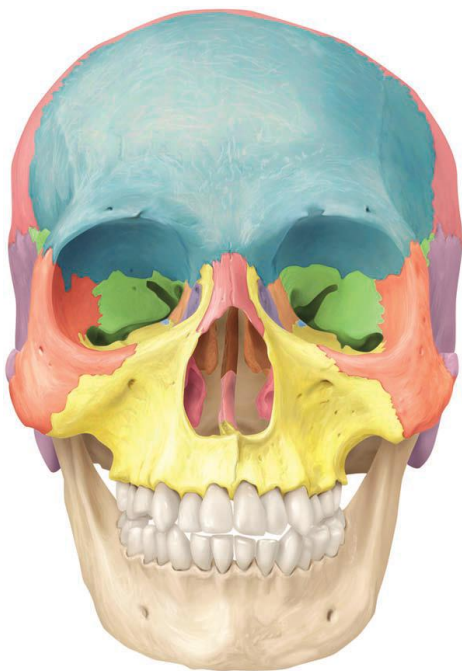
## **2. GENERAL PART**

### **2.1. ANATOMY**

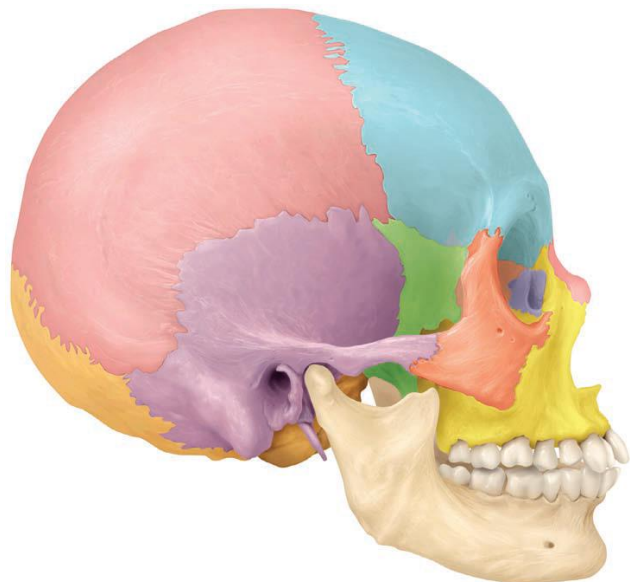
#### **2.1.1. Cranial Bones**

##### *2.1.1.1. Frontal Bone*

The frontal bone forms the forehead (the anterior part of the cranium) the top of the orbits (eye sockets) and most of the anterior part of the cranial floor. Soon after birth, the left and right sides of the frontal bone are united by the *metopic suture*, which usually between at the ages of six and eight disappears. [28]



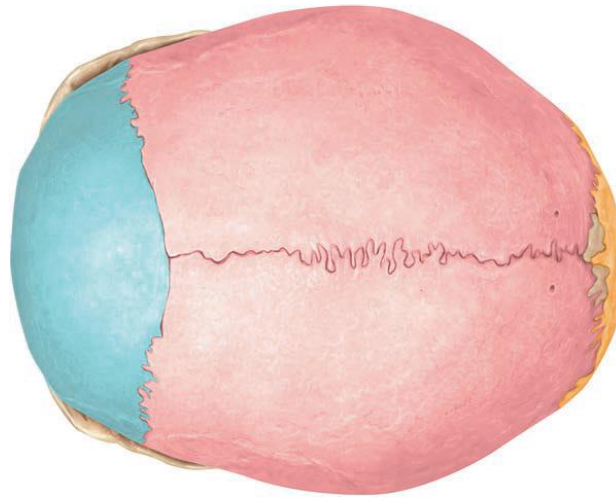
**Figure No 1:** Anterior view of the skull [28]



**Figure No 2:** Lateral view of the skull [28]

##### *2.1.1.2. Parietal Bone*

The human body is composed by two parietal bones form the greater portion of the sides and roof of the cranial cavity. The internal surfaces of the parietal bones contain many protrusions and depressions that accommodate the blood vessels supplying the dura mater, the superficial connective tissue (meninx) covering of the brain. [28]



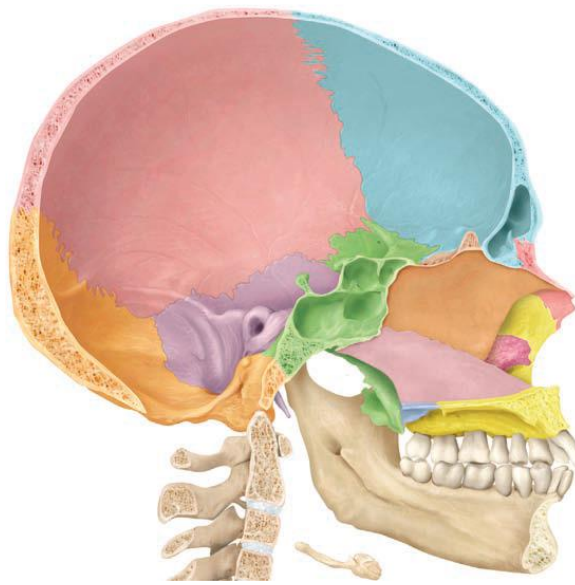
**Figure No 3:** Superior view of the skull [28]

### 2.1.1.3. Temporal Bone

The two paired temporal bones form the inferior lateral aspects of the cranium and part of the cranial floor. In the *Figure No 1*, we can notice the *temporal squama*, the thin, flat part of the temporal bone which forms the anterior and superior part of the *temple* (the region of the skull around the ear). Observing the cranium from the inferior portion of the temporal squama is the *zygomatic process*, which articulates (forms a joint) with the temporal process of the zygomatic (cheek) bone. The zygomatic process of the temporal bone and the temporal process of the zygomatic bone together form the *zygomatic arch*. [28]

A socket called the *mandibular fossa* is located on the inferior posterior surface of the zygomatic process of each temporal bone. Anteriorly to the mandibular fossa is a rounded elevation, the *articular tubercle* (See *Figure No 2*). The mandibular fossa and articular tubercle articulates with the mandible (lower jawbone) to form the *temporomandibular joint*. [28]

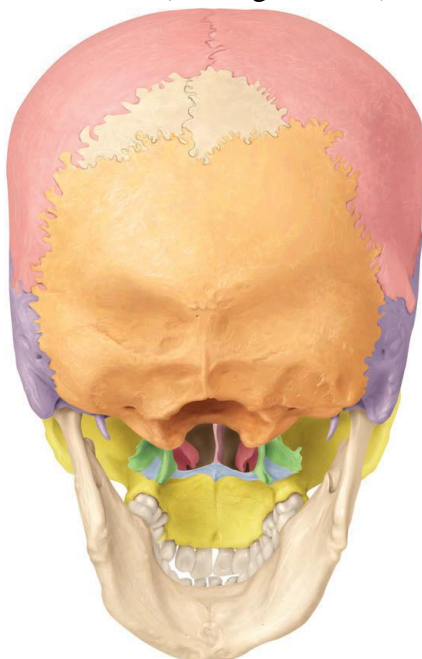
The *mastoid portion* of the temporal bone is located posteriorly and inferiorly to the *external auditory meatus*, or ear canal, that directs sound waves into the ear. In an adults, this portion of the bone contains several *mastoid air cells* that communicates with the hollow space of the middle ear. The *mastoid process* is a rounded projection of the mastoid portion of the temporal bone posteriorly and inferiorly to the external auditory meatus. This is the point of the origin of several neck muscles. In the *Figure No 4*, it is noticed the *internal auditory meatus* which is the opening through which the facial nerve (VII) and vestibulocochlear (VIII) nerve pass. [28]



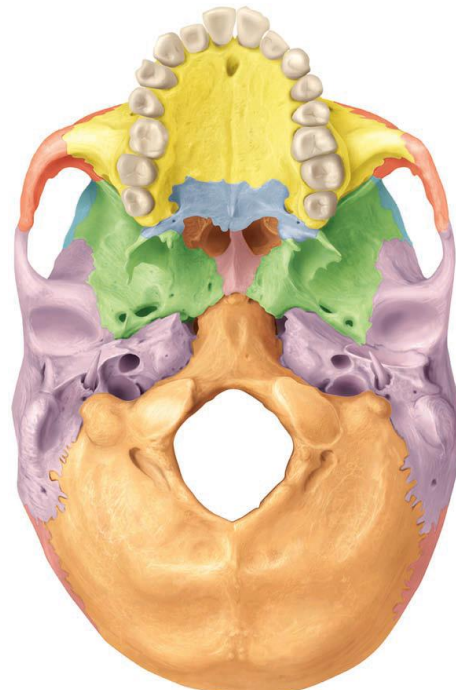
**Figure No 4:** Medial View of Sagittal section of the skull [28]

#### 2.1.1.4. Occipital bone

The posterior portion of the cranium is called occipital bone which also forms the base of the cranium. The *foramen magnum* is in the inferior part of the bone which from this foramen travels the medulla oblongata which connects with the spinal cord, the vertebral and the spinal arteries. Also through it passes the accessory (XI) nerve. The *occipital condyles*, oval processes with convex surfaces on either side of the foramen magnum (See Figure No 6), articulates with depressions on the first cervical vertebra (atlas) to form the *atlanto-occipital joint*, which allows us to nod “yes” with our head. Superior to each occipital condyle on the inferior surface of the skull is the *hypoglossal canal* (See Figure No 4). [28]



**Figure No 5:** Posteroinferior view of the skull [28]

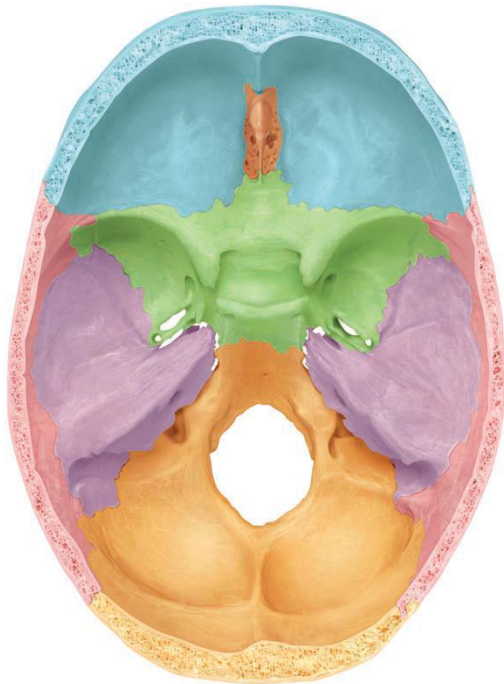


**Figure No 6:** Inferior view of the skull [28]

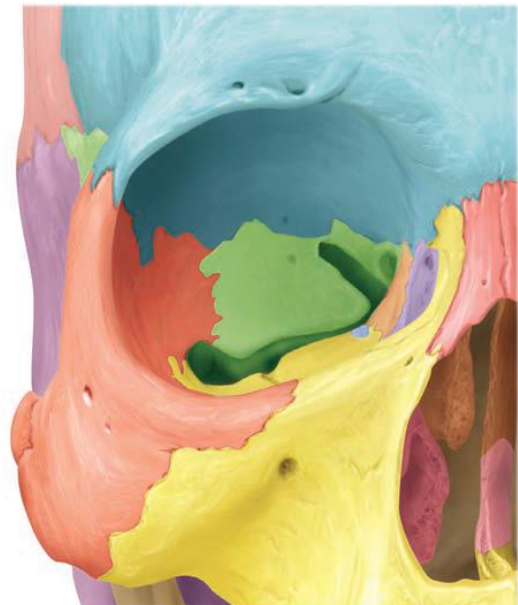#### 2.1.1.5. Sphenoid bone

The sphenoid bone lies at the middle part of the base of the cranium. It articulates with all the other cranial bones, holding them together. In the Figure No 7, we can notice the floor of the cranium superiorly and note the sphenoid articulations. The sphenoid bone articulates anteriorly with the frontal and ethmoid bones, laterally with the temporal bone and posteriorly with the occipital bone. The sphenoid bone lies posteriorly and slightly superior to the nasal cavity and forms part of the floor, side walls and rear wall of the orbit (See Figure No 8). [28]

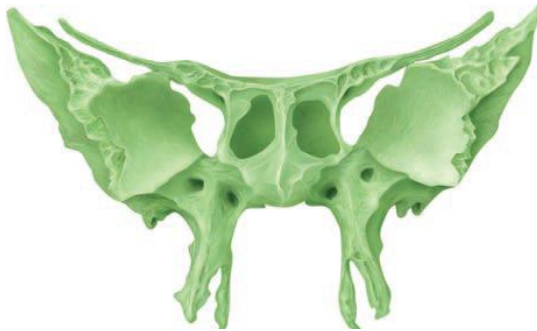The shape of the sphenoid resembles a butterfly with outstretched wings (See Figure No 9). The *sella turcica* is a bony saddle-shaped structure on the superior surface of the body of the sphenoid (See Figure No 7). [28]



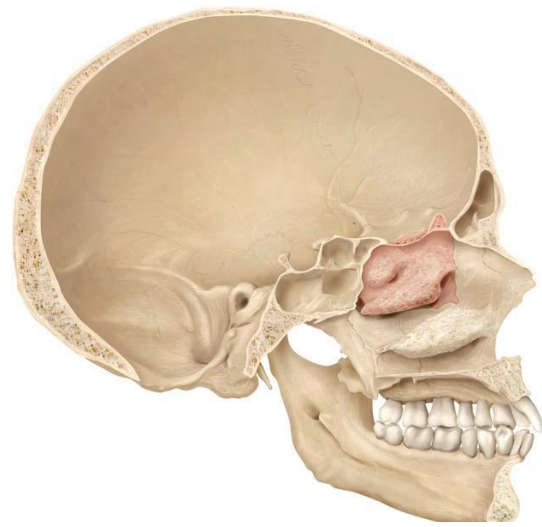
**Figure No 7:** Superior view of sphenoid bone in floor of cranium [28]



**Figure No 8:** Anterior view showing the bones of the right orbit [28]



**Figure No 9:** Anterior view of sphenoid bone [28]



**Figure No 10:** Medial view of sagittal section [28]

#### 2.1.1.6. *Ethmoid bone*

The ethmoid bone is a delicate bone located in the anterior part of the cranial floor medial to the orbits and is sponge-like in appearance (See Figure No 10). The superior portion of the ethmoid bone forms the nasal septum, the medial wall of the orbits and part of the anterior portion of the cranial floor. [28]

The ethmoid bone is a major superior supporting structure of the nasal cavity and forms an extensive surface area in the nasal cavity. The *cribriform plate* of the ethmoid bone lies in the anterior floor of the cranium and forms the roof of the nasal cavity.

The cribriform plate contains the *olfactory foramina* through which the olfactory nerves pass. From a superior view, the cribriform plate is a triangular process that is called the *crista galli*, which serves as a point of attachment for the falx cerebri which mainly is a membrane that separates the two sides of the brain. [28]

#### 2.1.1.7. *Nasal bones*

The nasal bones are small, flattened, rectangular-shaped bones that form the bridge of the nose. These small bones protect the upper entry to the nasal cavity and provide attachment for a couple of thin muscles of facial expression. [28]

#### 2.1.1.8. *Lacrimal bones*

The lacrimal bones are thin and roughly resemble a fingernail in size and shape (See Figure No 8). These bones, that are the smallest bones of the face, are posterior and lateral to the nasal bones and form a part of the medial wall of each orbit. [28]

The lacrimal bones each contain a *lacrima fossa*, a vertical tunnel formed with the maxilla, the houses the lacrimal sac, a structure that gathers tears and passes them into the nasal cavity (See Figure No 8). [28]

#### 2.1.1.9. *Palatine bones*

The palatine bones have an L-shape form which form the posterior portion of the hard palate, part of the floor and lateral wall of the nasal cavity, and a small portion of the floors of the orbits. Its posterior portion of the hard palate is formed by the *horizontal plates* of the palatine bones (See Figures No 5, 6). [28]

#### 2.1.1.10. *Maxillae*

The maxillae are the upper jawbone. They articulate with every bone of the face except the mandible which is the lower jawbone (See Figures No1, 2, 6). The maxillae form part of the floors of the orbits, part of the lateral walls and floor of the nasal cavity and most of the hard palate which is a bony roof of the mouth and is formed by the palatine processes of the maxillae and horizontal plates of the palatine bones. The hard palate separates the nasal cavity from the oral cavity. [28]

#### 2.1.1.11. *Zygomatic bones*

The two zygomatic bones are mainly also called cheek-bones, which form the prominences of the cheeks and part of the lateral wall and floor of each orbit (See Figure No 8). They articulate with the frontal, maxilla, sphenoid and temporal bones.

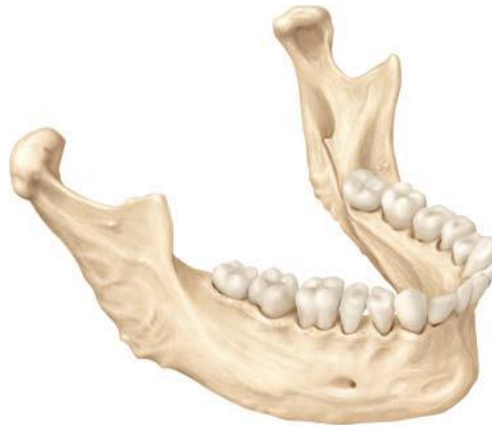The *temporal process* of the zygomatic bone projects posteriorly and articulates with the zygomatic process of the temporal bone to form the *zygomatic arch* (See Figure No 2). [28]

#### 2.1.1.12. *Mandible*

The mandible or called also lower jawbone, is the largest and strongest facial bone (See Figure No 11). It is the only movable skull bone. In the lateral view, you can see that the mandible consists of a curved, horizontal portion, the body and two perpendicular portions, the rami. The *angle* of the mandible is the area where each *ramus* meets the body.

Each ramus has a posterior *condylar process* that articulates with the mandibular fossa and articular tubercle of the temporal bone to form the *temporomandibular joint (TMJ)* and an anterior *coronoid process* to which the temporalis muscle attaches. [28]

The depression between the coronoid and condylar processes is called the *mandibular notch*. The *alveolar process* is the ridge-like arch containing the alveoli for the mandibular teeth.

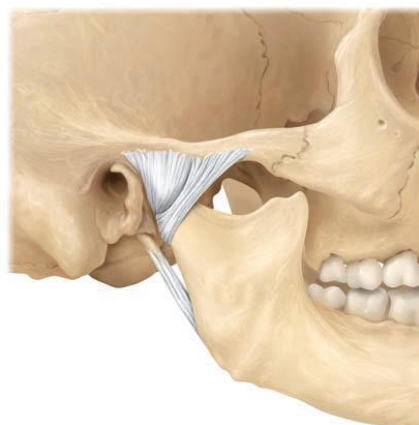


**Figure No 11:** Right lateral view of the mandible [28]

### **2.1.2. The temporomandibular joint**

The temporomandibular joint (TMJ) is a combined hinge and planer joint formed by the condylar process of the mandible and the mandibular fossa and articular tubercle of the temporal bone. This joint is the only freely movable joint between cranial bones, all the other skull joints are sutures and therefore immovable or slightly movable (See Figure No 12). [28]

The movements of the TMJ are mainly depression of the jawbone or opening of the mouth and elevation of the jawbone or closing of the mouth. This occurs in the inferior compartment and protraction, retraction, lateral displacement and slight rotation which occur in the superior compartment. [28]



**Figure No 12:** Right lateral view of the TMJ [28]

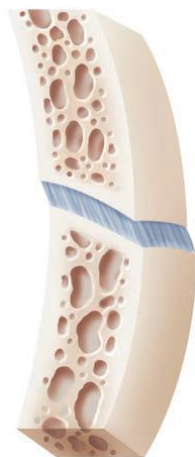


### 2.1.3. Ligaments and connective tissues

The human body is consisted of ligaments and connective tissues in every part of it. Specifically in the cranium there are three types of ligaments which are called fibrous joints. Its function mainly is to keep strongly attached all the parts of the cranial bones together. These three parts are the *sutures*, *syndesmoses* and *interosseous membranes*. [28]

#### 2.1.3.1. Sutures:

A suture is a fibrous joint which is composed from a thin layer of dense irregular connective tissue. It occurs only between bones of the skull. E.g. about the coronal suture between the parietal and frontal bones (See Figure No 14). The irregular, interlocking edges of sutures give them added strength and decrease their change of fracturing. During development, the suture joints are closing. Usually, the suture joints are immovable and slightly movable. [28]



**Figure No 13:** Slight movement at suture [28]



**Figure No 14:** Coronal suture [28]

#### 2.1.3.2. *Syndesmoses*

A syndesmoses is a fibrous joint in which there is a greater distance between the articulating surfaces and denser irregular connective tissue than in a suture. The dense irregular connective tissue is typically arranged as a bundle (ligament), allowing the joint to permit limited movement. E.g. the distal tibiofibular joint, where the anterior tibiofibular ligament connects the tibia and fibula. It permits slight movement. [28]

#### 2.1.3.3. *Interosseous membranes*

The final category of fibrous joint is the interosseous membrane, which is a substantial sheet of dense irregular connective tissue which binds neighboring long bones and permits slight movement. There are two principal interosseous membrane joints in the human body. One occurs between the radius and ulna in the forearm and the other occurs between tibia and fibula in the leg. [28]

### **2.1.4. Cranial nerves**

There are 12 pairs of cranial nerves. Are so named due to the fact that they pass through the various foramina in the bones of the cranium and arise from the brain inside the cranial cavity. [28]

Three cranial nerves (I, II and VIII) carry axons of sensory neurons and thus are called special sensory nerves. These nerves are unique to the head and are associated with the special senses of smelling, seeing and hearing. [28]

Five cranial nerves (III, IV, V, VI and XII) are classified as motor nerves because they contain only axons of motor neurons as they leave the brain stem.

The remaining four cranial nerves (V, VII, IX and X) are mixed nerves which means that they contain axons of both sensory neurons entering the brain stem and motor neurons leaving the brain stem. [28]

#### 2.1.4.1. *Olfactory nerve – 1st Cranial Nerve*

It's entirely sensory which contains axons that conduct nerve impulses for olfaction or the sense of smell. The olfactory epithelium occupies the superior part of the nasal cavity, covering the inferior surface of the cribriform plate and extending down along the superior nasal concha. Its receptors within the olfactory epithelium are bipolar neurons. [28]

#### 2.1.4.2. *Optic nerve – 2nd Cranial Nerve*

It's entirely sensory and specifically for the visual sense. In the retina, rod and cones initiate visual signals and relay them to bipolar cells, which transmit the signals to ganglion cells in the retina of each eye join to form an optic nerve, which passes through the optic foramen. About 10 mm posteriorly to the eyeball, the two optic nerves merge to form the optic chiasm. [28]

#### 2.1.4.3. *Oculomotor, trochlear and abducens nerves – 3rd, 4th and 6th Cranial Nerves*

These three cranial nerves are the nerves which control the muscles which move the eyeballs. These nerves are all motor nerves which contain only motor axons as they exit the brain stem. Sensory axons from the extrinsic eyeball muscles begin their course towards the brain in each of these nerves, but in the end these sensory axons leave these nerves to join the ophthalmic branch of the trigeminal nerve. The sensory axons do not return back to the brain in the Oculomotor, trochlear or abducens nerves. [28]

The Oculomotor nerve has its motor nucleus in the anterior part of the midbrain. It extends anteriorly and divides into superior orbital fissure into the orbit. Axons in the inferior branch supply the medial rectus, inferior rectus and inferior oblique muscle. [28]

The trochlear nerve is the smallest of the 12 pairs of cranial nerves and is the only one that arises posteriorly of the brain stem. The somatic motor neurons originate in a muscles in the midbrain and axons from the nucleus cross to the opposite side as they exit the brain on its posterior aspect. These somatic motor axons innervate the superior oblique muscle of the eyeball, another extrinsic eyeball muscle that control movement of the eyeball. [28]

From a nucleus in the pons originate the neurons of the abducens nerve. Somatic motor axons extend from the nucleus to the lateral rectus muscle of the eyeball, an extrinsic eyeball, muscle, through the superior orbital fissure of the orbit. Its name is from the nerve impulses cause abduction of the eyeball. [28]

#### 2.1.4.4. *Trigeminal nerve – 5th Cranial Nerve*

It's a mixed cranial nerve and the largest of all the 12 cranial nerves. The trigeminal nerve initiates from two roots on the anterolateral surface of the pons. The large sensory root has a swelling called the trigeminal ganglion that is located in a fossa on the inner surface of the petrous portion of the temporal bone. The ganglion contains cell bodies of most of the primary sensory neurons. Neurons of the smallest motor root originate in a nucleus in the pons. The trigeminal nerve has three main branches. The ophthalmic which is the smallest branch and passes into the orbit via the superior orbital fissure, the maxillary branch which intermediates in size between the ophthalmic and mandibular nerves and passes through the foramen rotundum and finally the mandibular branch which is the largest of all the three branches. It passes through the foramen ovale. [28]

#### 2.1.4.5. *Facial nerve – 7th Cranial Nerve*

It's a mixed cranial nerve with sensory axons that extend from the taste buds of the anterior two-thirds of the tongue, which enter the temporal bone to join the facial nerve. From here the sensory axons pass to the geniculate ganglion, a cluster of cell bodies of sensory neurons of the facial nerve within the temporal bone and ends in the pons. From the pons, axons extend to the thalamus and then toward the gustatory areas of the cerebral cortex. The facial's nerve sensory portion also contains axons from the skin in the ear canal that relay touch, pain and thermal sensations. Additionally, proprioceptors from muscles of the face and scalp relay information through their cell bodies in a nucleus in the mesencephalic nucleus. [28, 13]

#### 2.1.4.6. *Vestibulocochlear nerve – 8th Cranial Nerve*

It's also called the acoustic or auditory nerve. It is a sensory cranial nerve and has two branches, the vestibular branch and the cochlear branch. It carries impulses for equilibrium and the cochlear branch carries impulses for hearing. [28]

Sensory axons in the vestibular branch extend from the semicircular canals, the saccule and the utricle of the inner ear to the vestibular ganglion, where the cell bodies of the neurons are located and end in the vestibular nuclei in the pons and cerebellum. Some sensory axons also enter the cerebellum via the inferior cerebellar peduncle. [28]

#### 2.1.4.7. *Glossopharyngeal nerve – 9th Cranial Nerve*

It's a mixed nerve in which the sensory axons arise from the taste buds on the posterior one-third of the tongue, the proprioceptors from some swallowing muscles supplied by the motor portion, the baroreceptors in the carotid sinus that monitor blood pressure, the chemoreceptors in the carotid bodies near the carotid arteries and aortic bodies near the arch of the aorta and finally the external ear to convey touch, pain and thermal sensations. The cell bodies of these sensory neurons are located in the superior and inferior ganglia. From the ganglia, sensory axons pass through the jugular foramen and end in the medulla oblongata. [28]

#### 2.1.4.8. *Vagus nerve – 10th Cranial Nerve*

It's a mixed cranial nerve which is distributed from the head and neck into the thorax and abdomen. The nerve derives its name from its wide distribution. In the neck, it lies medial and posterior to the internal jugular vein and common carotid artery.

The sensory axons of the vagus nerve arise from the skin of the external ear for touch, pain and thermal sensations. Also sensory axons come from baroreceptors in the carotid sinus and chemoreceptors in the carotid and aortic bodies. [28]

The majority of the sensory neurons come from visceral sensory receptors in most organs of the thoracic and abdomen. The nerve derives its name from its name from its wide distribution. In the neck, it lies medial and posterior to the internal jugular vein and common carotid artery. [28]

#### 2.1.4.9. *Accessory nerve – 11th Cranial Nerve*

It's a motor cranial nerve. The cranial accessory nerve actually is a part of the vagus nerve. It's been divided into two parts, a cranial accessory nerve and a spinal accessory nerve. The cranial accessory nerve actually is a part of the vagus nerve. Its motor axons arise in the anterior gray horn of the first five segments of the cervical portion of the spinal cord. The axons from the segments exit the spinal cord laterally and come together, ascend through the foramen magnum and then exit through the jugular foramen along with the vagus and glossopharyngeal nerves. [28]

The accessory nerve conveys motor impulses to the sternocleidomastoid and trapezius muscles, begin their course toward the brain in the accessory nerve, but eventually leave the nerve to join nerves of the cervical plexus. [28]

#### 2.1.4.10. *Hypoglossal nerve -12th Cranial Nerve*

It's a motor cranial nerve which its somatic motor axons originate in a nucleus in the medulla oblongata and exit the medulla on its anterior surface and pass through the hypoglossal canal to supply the muscles of the tongue. These axons conduct nerve impulses for speech and swallowing. The sensory axons do not return to the brain in the hypoglossal nerve. Instead, sensory axons that originate from proprioceptors in the tongue muscles begin their course toward the brain in the hypoglossal nerve but they leave the nerve to join cervical spinal nerves, and end in the medulla oblongata, again entering the central nervous system through the posterior roots of the cervical spinal nerves. [28]

### 2.1.5. Facial, masticatory muscles and fascia

#### 2.1.5.1. *Muscles of the head that produce facial expressions*

The facial muscles lie within the subcutaneous layer. Usually these muscles originate from the fascia or bones of the skull and are inserted into the skin. We have two important categories for the facial muscles. [28]

The *sphincters* which are the muscles that close the openings e.g. eyes, nose and mouth.

The *dilators* which are the muscles that dilate or open the orifices. E.g. the muscle to close the eye is called orbicularis oculi and the muscle that open the eye is called palpebrae superioris. [28]

There is a usual muscle on the face of the human body which is called occipitofrontalis which can be divided in two parts; the frontal belly or frontalis which is superficial to the frontal bone and a posterior part called the occipital belly or occipitalis which is superficial to the occipital bone. These two muscular portions are held together by a strong aponeurosis which is mainly a sheet-like tendon which it's given the name of epicranial aponeurosis. It's called galea aponeurotica as well. It

covers the superior and lateral surfaces of the skull. The major muscular portion of the cheek is covered mainly from the buccinator muscle. It's called like this because of it compresses the cheeks during blowing. Also it functions in whistling, blowing and sucking and assists in chewing. [28]

The movement of the mandible or lower jawbone is done at the temporomandibular joint (TMJ). Of the four pairs of muscles involved in mastication, three are powerful closers of the jaw and account for the strength of the bite which are the masseter, temporalis and medial pterygoid. The strongest muscle of the mastication is the masseter. The medial and lateral pterygoid muscles assist in the mastication by moving the mandible from side to side on helping grind the food. Furthermore, the lateral pterygoid muscles protract the mandible. [28]

<u>Scalp muscles</u>	<u>Origin</u>	<u>Insertion</u>	<u>Action</u>	<u>Innervation</u>
<i>Occipitofrontalis</i>				
<i>Frontal belly</i>	Epicranial aponeurosis	Skin superior to supraorbital margin	Draws scalp anteriorly, raises eyebrows and make the face-surprised expression.	Facial (VII) nerve
<i>Occipital belly</i>	Occipital bone and mastoid process of temporal bone.	Epicranial aponeurosis	Draws scalp posteriorly	Facial (VII) nerve

**Table No 1:** Scalp muscles [28]

<u>Muscles of the mouth</u>	<u>Origin</u>	<u>Insertion</u>	<u>Action</u>	<u>Innervation</u>
<i>Orbicularis oris</i>	Muscle fibers surrounding opening of mouth	Skin at corner of mouth	Closes and protrudes lips, as in kissing	Facial (VII) nerve
<i>Zygomaticus major</i>	Zygomatic bone.	Skin at angle of	Draws angle of mouth superiorly	Facial (VII) nerve

		mouth and orbicularis oris	and laterally, as in smiling.	
<i>Zygomaticus minor</i>	Zygomatic bone.	Upper lip	Raises upper lip, exposing maxillary teeth	Facial (VII) nerve
<i>Levator labii superioris</i>	Superior to infraorbital foramen of maxilla.	Skin at angle of mouth and orbicularis oris	Raises upper lip.	Facial (VII) nerve
<i>Depressor labii inferioris</i>	Mandible.	Skin of lower lip.	Depresses lower lip.	Facial (VII) nerve
<i>Depressor anguli oris</i>	Mandible	Angle of mouth	Draws angle of mouth laterally and inferiorly, as in opening mouth.	Facial (VII) nerve
<i>Levator anguli oris</i>	Inferior to infraorbital foramen.	Skin of lower lip and orbicularis oris.	Draws angle of mouth laterally and superiorly.	Facial (VII) nerve
<i>Buccinator</i>	Alveolar processes of maxilla, mandible and pterygomandibular raphe.	Orbicularis oris	Presses cheeks against teeth and lips as in whistling, blowing and sucking and assists on chewing.	Facial (VII) nerve
<i>Risorius</i>	Fascia over parotid gland	Skin at angle of mouth	Draws angle of mouth laterally, like smiling.	Facial (VII) nerve



<i>Mentalis</i>	Mandible	Skin of chin	Elevates and protrudes the lower lip	Facial (VII) nerve
-----------------	----------	--------------	--------------------------------------	--------------------

**Table No 2:** Muscles of the mouth [28]

<u>Neck muscles</u>	<u>Origin</u>	<u>Insertion</u>	<u>Action</u>	<u>Innervation</u>
<i>Platysma</i>	Fascia over deltoid and pectoralis major m.	Mandible	Depresses mandible	Facial (VII) nerve
<i>Sternocleidomastoid</i>	Manubrium of sternum and medial third of clavicle	Mastoid process of temporal bone and lateral half of superior nuchal line of occipital bone	Flexion and rotation of cervical spine	Accessory (XI) nerve, C2 and C3

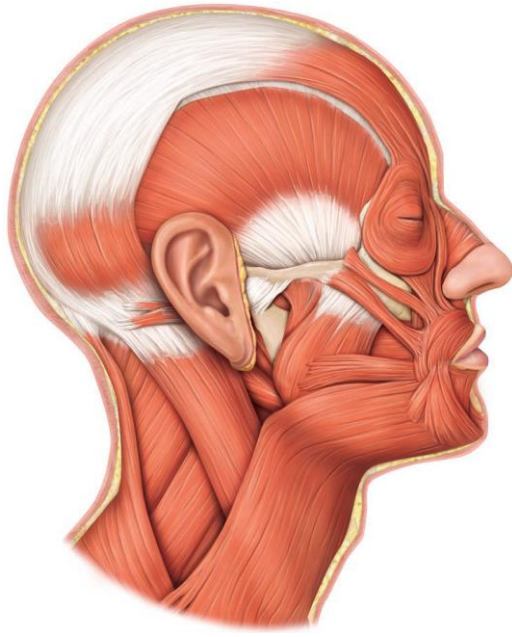
**Table No 3:** Neck muscles [28]

<u>Orbit and eyebrow muscle</u>	<u>Origin</u>	<u>Insertion</u>	<u>Action</u>	<u>Innervation</u>
<i>Orbicularis oculi</i>	Medial wall of orbit	Circular path around orbit	Closes eye	Facial (VII) nerve
<i>Corrugator supercilii</i>	Medial end of superciliary arch of frontal bone.	Skin of eyebrow	Draws eyebrow inferiorly and wrinkles skin of forehead vertically as in frowning.	Facial (VII) nerve

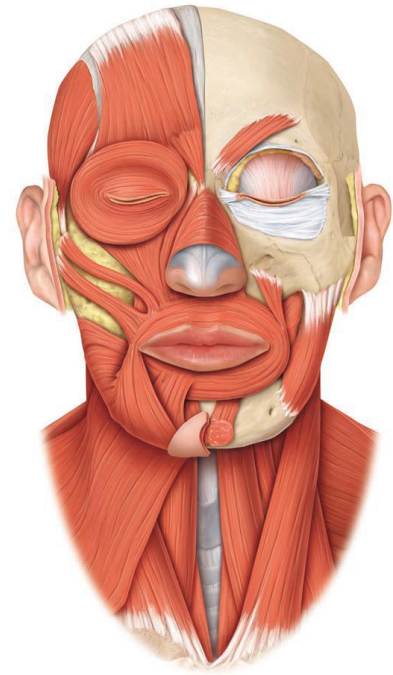
**Table No 4:** Orbit and eyebrows muscles [28]

<b><u>Masticatory muscles</u></b>	<b><u>Origin</u></b>	<b><u>Insertion</u></b>	<b><u>Action</u></b>	<b><u>Innervation</u></b>
<i>Masseter</i>	Maxilla and zygomatic arch	Angle and ramus of mandible.	Elevates mandible, as in closing mouth.	Mandibular division of trigeminal (V) nerve
<i>Temporalis</i>	Temporal bone	Coronoid process and ramus of mandible.	Elevates and retracts mandible	Mandibular division of trigeminal (V) nerve
<i>M. pterygoid</i>	Medial surface of lateral portion of pterygoid process of sphenoid bone; maxilla	Angle and ramus of mandible.	Elevates and protracts mandible and moves mandible from side to side.	Mandibular division of trigeminal (V) nerve
<i>L. pterygoid</i>	Greater wing and lateral surface of lateral portion of pterygoid process of sphenoid bone.	Condyle of mandible; Temporomandibular joint	Protracts mandible, depresses mandible as in opening mouth and moves mandible from side to side.	Mandibular division of trigeminal (V) nerve

**Table No 5:** Masticatory muscles [28]



**Figure No 16:** Anterior superficial and deep view of the face [28]



**Figure No 17:** Right lateral superficial view of the face [28]

The tongue is a highly mobile structure that is vital to digestive functions such as mastication, detection of taste and deglutition. Another very important roll plays during the speech. Its mobility is greatly aided by its attachment to the mandible, styloid process of the temporal bone and the hyoid bone.

It is divided into lateral halves by a median fibrous septum. The septum extends throughout the length of the tongue. Inferiorly, the septum attaches to the hyoid bone. The tongue has two principal types of muscles. The extrinsic and intrinsic which means that the extrinsic originates from outside the tongue and inserts into it and the intrinsic originates and inserts within the tongue. These muscles change the shape of the tongue instead of moving it. [28]

## **2.1.5.2. The head and neck in general**

### **2.1.5.2.1. *Functional aspects of the head, neck and facial expressions***

#### *2.1.5.2.1.1. The head and neck of the human body*

The skull as a structure the main function is to protect the brain and all the receptor systems associated with the special senses as the nasal cavities associated with the sense of smell, the orbits with the sense of vision, the ears with the hearing and balancing and finally the oral cavity with the sense of taste. [1]

The nasal and oral cavities are the two upper parts of the respiratory and digestive systems of the human body. With these two parts it is possible to have structural features for modifying the air or food passing into each system. [1]

#### *2.1.5.2.1.2. Communication*

In the field of the communication activity, are involved the head and neck. The larynx produces sounds which later will be modified in the pharynx and oral cavity to produce speech. Moreover, the muscles of the facial expression adjust the shape of the face to relay nonverbal signals. [1]

#### *2.1.5.2.1.3. Position of the head*

The position of the head comes from the neck. Important roll plays in the individual position which is done by the sensory systems in the head relative to environmental cues without moving the entire body. [1]

#### *2.1.5.2.1.4. "Communication" between the head and neck*

The pharynx and larynx are two special parts of the neck which connect the upper parts of the digestive and respiratory tracts in the head, with the esophagus and trachea, which begin relatively low in the neck and then pass into the thorax. [1]

#### *2.1.5.2.1.5. Relationship to other regions*

The base of the neck is called superior thoracic aperture which through there structures are passing between the head and thorax. At the base of the neck, the trachea is immediately anterior to the esophagus, which is directly anterior to the vertebral column. Anteriorly and laterally to the trachea, furthermore, there are major veins, arteries and nerves. [1]

#### *2.1.5.2.1.6. Upper limbs*

There is an axillary canal on each side of the superior thoracic aperture at the base of the neck that blood vessels pass over the first rib when passing between the axillary inlet and thorax. In addition, cervical components of the brachial plexus pass directly from the neck though the axillary canals to enter the upper limb. [1]

## **2.2. KINESIOLOGY OF THE FACIAL EXPRESSIONS AND THE CERVICAL SPINE**

### **2.2.1. Functional anatomy of the face**

The complexity and expressiveness of the human face makes it a challenging subject for automated visual interpretation and recognition. The human face has attracted much attention in several disciplines, including psychology, computer vision and computer graphics. Psychophysical investigations clearly indicate that faces are very special visual stimuli. [17, 1]

### **2.2.2. Facial muscle control process**

Not only the facial muscles but all the muscles are bundles of muscle fibers working in unison. The shape of the fiber bundle determines the muscle type and its functionality. There are three main types of facial muscles: linear, sphincter and sheet. Linear muscle, such as the zygomaticus major consists of a bundle of fibers that share a common emergence point in bone. Sheet muscles, such as the occipito frontalis is a broad, flat sheet of muscle fiber strands without a localized emergence point. Sphincter muscle consists of fibers that loop around facial orifices and can draw toward a virtual center.

In the human face, more than 200 voluntary muscles can exert traction on the facial tissue to create expressions. [17, 1]

When the muscles contract, they pull the facial soft tissue to which they attach toward the place where they emerge from the underlying bony framework of the skull. [17, 1]

### 2.2.3. Dynamic facial images

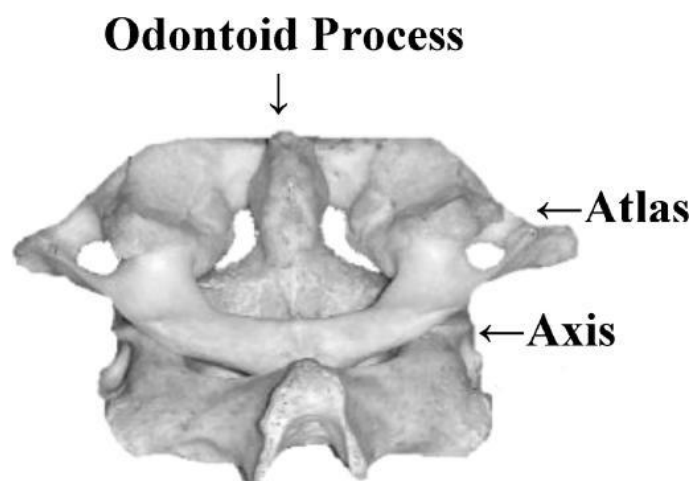
The analysis of images of expressive faces is quite confusing because it requires the reliable estimation of quantitative information about extended facial features that are moving non rigidly. [3, 26]

Through straightforward image processing, it's converted into 2-D potential functions whose ravines correspond to salient facial features such as the eyebrows, mouth and chin. [3, 26]

The ROM of the cervical spine is approximately 80 to 90 degrees of flexion and 70 degrees of extension, 20 to 30 degrees of lateral flexion and up to 90 degrees of rotation on both sides. However, the movement of the cervical spine is complicated because of pure uniplanar movement does not accurately portray the motion between cervical levels and movement into any range is not the simple sum of equal motion from one vertebra to the next one. [3, 26]

### 2.2.4. Normal kinematics of the upper cervical spine

The first cervical vertebra, the atlas or C1, has often been labeled the cradle, because of its articulation with the occiput of the skull provides a cradle for supporting the head (See Figure No 18). [20]



**Figure No 18:** Posterior view of C1 and C2 (atlas and axis) [20]

The atlas is articulated with the occipital condyles and its primary motions are flexion and extension. Normal flexion to hyperextension at the atlanto-occipital joint ranges from approximately 15 to 20 degrees. Rotation and lateral flexion between the occiput and atlas are not possible due to the depth of the atlantal sockets, in which the occipital condyles rest. Rotation to one side causes the contralateral occipital condyle to contact the anterior wall of its atlantal socket and the ipsilateral condyle to contact the posterior wall of its respective atlantal socket. Similarly, lateral flexion requires the contralateral occipital condyle to lift out of its socket, a movement that is restrained by the tight atlanto-occipital joint capsule. [20]

The weight of the head is transferred to the cervical spine through the lateral atlanto-axial articulations of C2 the axis (See Figure No 18). The superiorly directed odontoid process extending from its body rests within a facet on the atlas that is created by the anterior arch and allows the atlas and head to rotate from side to side as one unit. The normal range of motion of C1 and C2 are reported to be 50 degrees to each side. However, it results on being varied and 43 degrees using computed tomography scanning. Nevertheless, this rotational ability of the atlanto-axial joint is possible due to the stabilizing function of the 3 primary ligaments which act to hold the dens as a ‘‘fixed post’’ on which the atlas can rotate. [20]

## **2.3. BELL'S PALSY**

### **2.3.1. Classification of Bell's palsy**

Bell's palsy has been classified into the following 5 categories according to the clinical course of disease: [3]

- Unilateral non-recurrent
- Unilateral recurrent
- Simultaneous bilateral
- Alternating bilateral or recurrent bilateral

Bell's palsy is also termed as idiopathic facial paralysis, which is an acute, unilateral, peripheral, lower-motor-neuron facial nerve paralysis that gradually resolves over time in 80-90% of all cases. [24]

### **2.3.2. Pathology**

Bell's palsy is the sudden paralysis of the muscles on one side of the face of an individual due to dysfunction of the seventh (7<sup>th</sup>) cranial nerve which is the facial nerve. Its name is from the Scottish surgeon Sir Charles Bell, who first described the function of the facial nerve in 1829. [7]

The facial nerve supplies the muscles of movement and expression of the face. It also has sensory components that supply taste to the anterior two-thirds of the tongue and sensation in a small area around the ear. Moreover, a small nerve extends to a muscle attached to one of the bones of the middle ear and autonomic fibers extend to salivary and tear glands. A person with Bell's palsy may notice pain around the ear. There would be some alterations in the taste, sensitivity to sound and inability to use the facial muscles. Closing the eye is also a problem, wrinkling the forehead and pulling up the corners of the mouth. Food tends to accumulate in the affected side of the mouth. The face has an ironed-out appearance. [7]



### **2.3.3. Etiology**

The exact cause of Bell's palsy has been debated for many years. It is believed that the disease is viral in origin, with resulting edema and secondary demyelination of the nerve. Herpes simplex virus is the suspected guilty based on serological evidence.

Currently, polymerase chain reaction DNA testing supports the diagnosis of a reactivated virus and herpes simplex virus-1 DNA has been found in approximately 79% of Bell's palsy patients. [11]

Although this proves the presence of the virus, it does not necessarily link causation of Bell's palsy. It should be noticed that other viruses have been cultured from patients with Bell's palsy, including cytomegalovirus, Epstein-Barr virus, adenovirus, rubella, mumps and coxsackievirus. [11]

### **2.3.4. Infectious and inflammatory origin**

Infections from herpes simplex virus and lyme disease have also been linked to Bell's palsy. Furthermore, trauma to the head can be caused. In fact, some babies are born with this disorder. [9, 15]

#### **2.3.4.1. *Herpes simplex virus***

The HSV is human transmissible with ease. It's passed from one person to another by close, direct contact. The most common mode is the sexual activity. [9, 15]

When a person got the HSV, due to the fact that its symptoms are very slight, he will not know that he has it.

Its symptoms are:

- Pain while urinating
- Fever
- Feeling unwell
- Cold sores around the mouth

#### 2.3.4.2. *Chicken-pox*

Also known as *varicella* which is a contagious infection caused by the *varicella zoster virus*. The chicken pox spreads easily and rapidly through sneezing and coughing, as well as direct contact with the secretions from the blisters.

Varicella has an incubation period of between 10 and 21 days. [9, 16]

A few symptoms are:

- Fever
- Aching muscles
- Loss of appetite
- Nausea
- Red small spots which day by day are becoming even itchier from the day before. They appear usually behind the ears, on the face, scalp, limbs, chest, and stomach and under the arms. [9]

#### 2.3.4.3. *Lyme disease*

Also known as borreliosis which is a *Borrelia burgdorferi* bacterium infection. The bacterium is transmitted to humans when they are bitten by an infected blacklegged tick. Lyme disease is also a transmitted disease. [9, 19]

### **2.3.5. Other possible causes**

Other infections and inflammatory disorders account for 3.5% of facial paralysis patients. In addition, bacterial infections of the middle ear account for over ½ (one-half) of the infectious disease cases. Physical examination of the tympanic membrane and middle ear etiology. [11]

Lyme disease, can cause cranial neuropathy with associated facial paralysis that often resolves within two months. Treatment consists of antibiotic therapy with doxycycline or erythromycin. HIV infection can also directly cause facial palsy, usually at the time of seroconversion when a cerebrospinal fluid lymphocytosis is present. In addition, in the later stages of AIDS, paralysis is more often due to opportunistic infections. Sarcoidosis should also be considered in patients with bilateral facial palsy. [11]

### **2.3.6. Differential diagnosis**

MD Tiemstra and Khatkhate believed that the main cause of Bell's palsy is an inflammation of the facial nerve at the geniculate ganglion, thus leads to compression and possible ischemia and demyelination. The geniculate ganglion lies in the facial canal at the junction of the labyrinthine and tympanic segments, where the nerve curves sharply toward the stylomastoid foramen. [27]

Bell's palsy, has been defined as idiopathic and still the cause remains unknown about how this inflammatory process in the facial nerve is caused. According to some researches, herpes simplex virus type – 1 could be the cause of this diagnosis, because it was found elevated the HSV-1 titers in affected patients. [3, 5, 27]

Many conditions can produce isolated facial nerve palsy identical to Bell's palsy. Structural lesions in the ear or parotid gland can produce facial nerve compression and paralysis. Other causes of peripheral nerve palsies include Guillain-Barre syndrome, Lyme disease, otitis media, Ramsay Hunt syndrome, sarcoidosis and some influenza vaccines. [3, 5, 27]

These conditions can be present as isolated facial nerve palsies, they usually have additional features that distinguish them from Bell's palsy.

Lyme neuroborreliosis, the spirochete *Borrelia burgdorferi* can affect central nervous system tissues. Lyme neuroborreliosis should be suspected in a patient who presents with isolated facial weakness and who has a history of tick bite with rash or who lives in an area where Lyme disease is endemic. Tumors involving the facial nerve account for fewer than 5% of all cases of facial nerve paralysis. A tumor should be suspected if weakness progress over weeks, if a mass is present in the ear, neck or parotid gland and if no functional improvement is seen within 4 to 6 weeks. [27]

### **2.3.7. Symptoms**

Bell's palsy typically occurs on one side of the face and comes on suddenly, sometimes overnight. The diagnosis for Bell's palsy is an exclusion which means that this diagnosis is made when all the potential other causes of nerve damage have been ruled out. There are three symptoms commonly noted by the patient.

1. Epiphora due to lack of tone in the lower eyelid and consequent failure of the punctum to make contact with the globe of the eye is often present.


2. Pain which sometimes is a frequent complaint by the patient that is usually present in the ear, down the neck or into the eye. 3. Tenderness over the styломastoid foramen may be presented. [23, 18, 2]

Some of the Bell's palsy symptoms are:

- Paralysis of all the muscles on one side of the face of the patient. Which as result is presented some abnormal facial expressions, difficulties with drinking, eating etc.
- Drop of the face, difficulties on closing the eye of the affected side.
- There is numbness on the face, tongue etc.
- Could appear some changes in hearing sensitivity which will be increased (hyperacusis).
- Twitching of the face, dryness of the mouth or eyes, drooling or some changes in the taste perception as well. [18, 23, 22]

Bell's palsy tends to occur more frequently with age and is over three times more common in pregnant women than in the general population. [18, 2, 22]

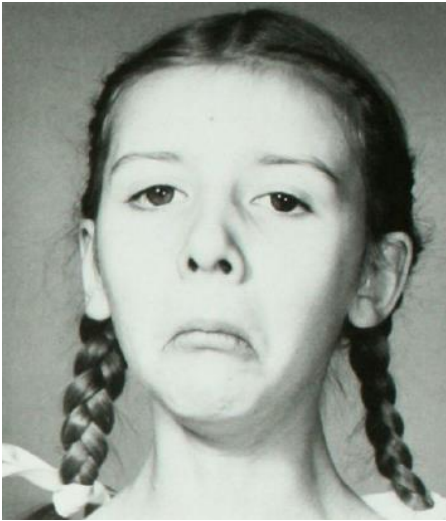#### 2.3.7.1. *Figures of the possible affected muscles on Bell's palsy*



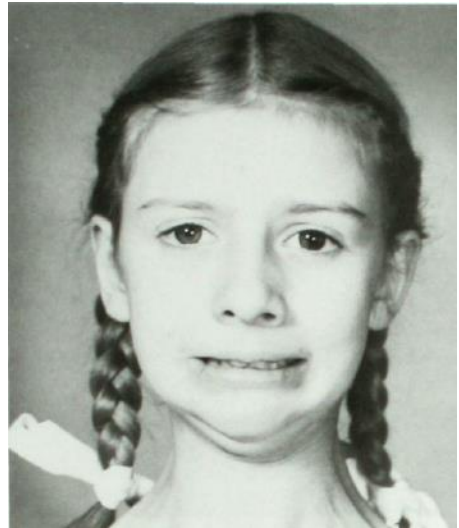**Figure No 19** – Buccinator [8]



**Figure No 20** – Corrugator supercilii [8]



**Figure No 21** – Depressor anguli oris [8]



**Figure No 22** – Depressor labii inferioris and platysma [8]



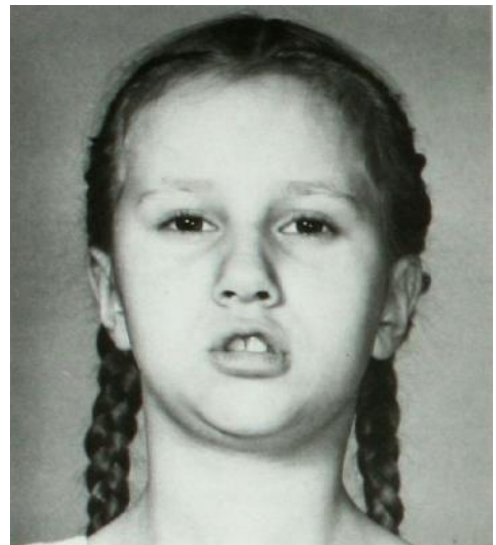
**Figure No 23** – Depressor septi [8]



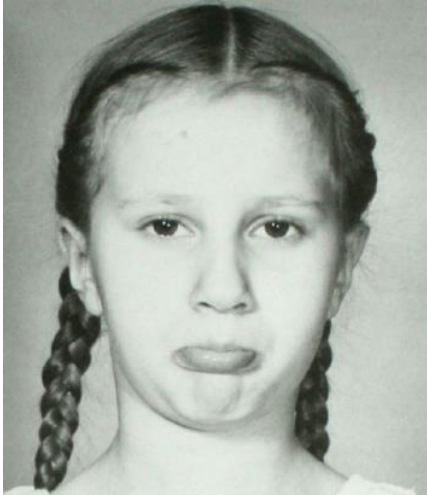**Figure No 24** – Frontalis [8]



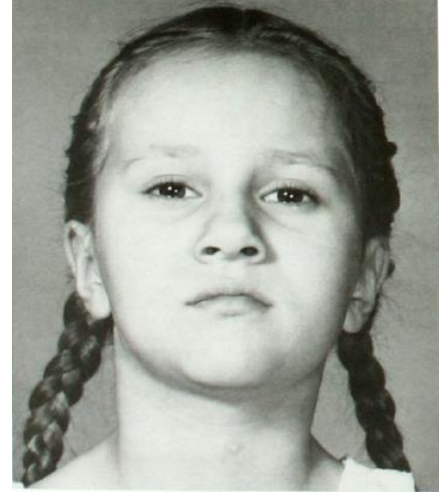**Figure No 25** – Levator anguli oris [8]



**Figure No 26** – Levator labii [8]



**Figure No 27 – Mentalis [8]**




**Figure No 28 – Nasalis [8]**



**Figure No 29 – Orbicularis oculi [8]**



**Figure No 30 – Orbicularis oris [8]**



**Figure No 31 – Procerus [8]**



**Figure No 32 – Risorius [8]**



**Figure No 33 – Zygomaticus major and minor [8]**

#### **2.3.8. Examination methods**

Bell's palsy can be examined with several methods. The most important thing is the proper history of the patient and physical examination. Patients with persistent weakness without significant improvement requires further investigation such as CT, or MRI is indicated in case that the patient hasn't any improvements with his diagnosis even after 1 month of rehabilitation, hearing loss, multiple cranial nerve deficits and signs of limb paresis or sensory loss. [16]

Another and important examination is the hearing testing which is tested if the patient has any losses of the hearing sense. Through the audiologic testing can be diagnosed if there is any acoustic neuroma. [16]

If the patient has signs of systemic involvement without significant improvement over more than 4 weeks, its necessary the laboratory testing. Through the blood testing could be tested if it is present some lymphoreticular malignancy which is the first manifestation that can prove the peripheral facial palsy. Sometimes cerebrospinal fluid testing could be helpful if there is an infection or malignancy. [16]

Electro diagnostic testing is not routinely done in Bell's palsy. It is not very reliable when this disorder is in the initial stages. However, after 2 weeks, it may detect denervation and demonstrate nerve regeneration. [16]

#### 2.3.8.1. *Ocular examination*

From the diagnosis, it is known that there is weakness or paralysis of the orbicularis oculi muscle and normal function of the levator muscle and Mueller muscle. The patient frequently is not able to close the eye completely of the affected side. While the patient is examined in this test and he is unable to do it, his eye rolls upward and inward on the affected side. Sometimes the patient may have decreased tearing and susceptibility to corneal abrasion and dryness of the eye due to these reasons. [24]

#### 2.3.8.2. *Oral examination*

Taste and salivation are affected in many patients with Bell's palsy. Taste may be assessed by holding the tongue with gauze and testing each side of the tongue independently with salt. Sugar and vinegar. After this examination the mouth should be washed with different substances. The affected side has decreased taste compared with the normal side. [24]

#### 2.3.8.3. *Neurologic examination*

In this examination, it is included the complete examination of the cranial nerves, sensory and motor testing and cerebellar testing. A neurologic abnormality warrants neurologic referral and further testing, such as MRI of the brain, lumbar puncture and EMG where appropriate. [24]

### **2.3.9. Treatment of peripheral facial nerve palsy**

There isn't any cure that treat completely Bell's palsy, but there are some treatments that could help the patient to get better faster, especially if the treatment of the patient starts within the first days of his first symptoms of his diagnosis.

#### 2.3.9.1. *Eye care*

If the patient cannot close his eye, he will need eye treatments. If the cornea of the eye becomes overly dry, there is a risk of permanent eye damage. A good treatment could be to use some eye drops to keep the eye moist. [25]

Use them every hour during the day. The use of glasses to protect the eye from the sun when the patient is outside, could be a good treatment as well. Over the night is better to use a patch over the eye. [25]



### 2.3.9.2. *Medications*

People who are diagnosed with Bell's palsy usually the quickest way to be treated with medications are steroids for one week. Steroids or glucocorticoids, can reduce swelling and improve your chances of recovering completely. These medicines work best for the patient when started to be used early. Antiviral medicines such as valacyclovir, Valtrex etc. are sometimes used in conjunction with glucocorticoids, especially when the facial weakness is severe. Some controlled trials have found an added benefit from the use of these agents. [21]

Steroids can be used with antibiotics but there isn't any proof that steroids are of benefit when Lyme disease is the cause of the facial weakness.

A variety of non-pharmacologic measures have been used to treat Bell's palsy including physical therapy such as facial exercises, neuromuscular retraining and acupuncture. [21]

### 2.3.9.3. *Surgery*

Surgical options for Bell's palsy include the following:

- Facial nerve decompression
- Subocularis oculi fat lift
- Implantable devices placed into the eyelid
- Tarsorrhaphy
- Transposition devices placed into the eyelid
- Facial nerve grafting
- Direct brow lift

Anecdotal evidence suggests that surgical repair by using a combination of procedures tailored to the patients' clinical findings works well for improving symptoms and exposure. [14]

Most patients who have had severe corneal exposure from lagophthalmus with or without paralytic ectropion have received a combination of lateral tarsal strip placement and gold-weight implantation. Patients without severe exposure have received a single procedure or combinations of procedures. [14]

### **2.3.10. Activities of daily living (ADL)**

The patient should be aware of some important complications which are turned up with Bell's palsy. Should be aware of the heat changes by covering the affected side of the face with a heat-covering. While speaking is better to hold the healthy side and try to use at least the less movements of the healthy side because while speaking, the paralyzed muscles drag the unaffected side. Avoiding the big bites and chewing gums. Limitation of laughing and expressing mimic. The patient should be sleeping on the healthy side. Avoiding watching television or staying on the computer or reading for too long. About the drying out of the cornea of the eye is better to cover the eye with an eye-patch and applying some ointments. [6]

### **3. SPECIAL PART (CASE STUDY)**

#### **3.1. METHODOLOGY**

The clinical work practice was done in Ustředni Vojenská Nemocnice in Prague. My practice started on Monday 3<sup>rd</sup> (third) of February 2014 and finished on Friday 14<sup>th</sup> (fourteenth) of February 2014. Every day I had practice which lasted for 8 hours. The total amount of hours of my practice was 80 hours.

My clinical work placement was supervised by Bc. Michaela Stránská. The sessions with my patient were 10 (ten). In the very first day of my practice, on Monday 3<sup>rd</sup> of February 2014, I performed my first therapy and every day I did therapies to my patient until my last day of my practice on Friday 14<sup>th</sup> of February 2014.

The therapeutic methods that I used were, soft-tissue techniques, Sister Kenny method, electrostimulation and facial expressions exercise together by giving guidelines to my patient.

My work has been approved by the Ethics Committee of the Faculty of Physical Education and Sport at Charles University in Prague.

**Supervisor:** Mgr. Helena Vomáčková

**Date and duration of practice:** 3.2.2014 – 14.2.2014

**Examined person:** A. K., Male

**Code:** G51.0

**Patient's age:** 73 years old.

**Year of birth:** 1941

**Diagnosis:** Bell's Palsy/Facial paralysis

---

### **3.2. ANAMNESIS**

**Weight:** 96 K.g.

**Height:** 1.76 m

**BMI:** 31

#### **3.2.1. Present state**

- Mr. A. K. was in the underground station and then a strong cold wind hit him on the face and that's how his problem begun. His current problem begun on January 18<sup>th</sup> 2014 by having some problems as he had 5 years ago when he had the same symptoms on the right side of his face. Immediately, on Monday he went to the doctor.
- On Tuesday 21<sup>st</sup> of January 2014 he did his 1<sup>st</sup> therapy on Ústřední vojenské nemocnice in Prague in which his therapies for the treatment of his previous case he did were provided in the same hospital.
- Generally his mood was not so good lately because of his diagnosis that he is experiencing for the second time but to the opposite side of his face.
- He didn't have any pain but only inability to perform facial movements/expressions.
- My 1<sup>st</sup> therapy with Mr. A. K. was on Monday 3<sup>rd</sup> of February 2014 which was his 9<sup>th</sup> therapy. With my patient, I am going to do 10 therapies which the first one was on Monday 3<sup>rd</sup> of February 2014 and the last which was on Friday 14<sup>th</sup> of February 2014.
- He had already a facial paresis but to the other side (right) on October 2008 and he was completely treated on January 2009 (exact date wasn't mentioned).
- He doesn't have any pain but he feels uncomfortable with his situation.
- His mood in the very late days isn't so good.

### **3.2.2. Personal anamnesis**

- He had all the common childhood diseases (chicken pox etc.)

### **3.2.3. Operational anamnesis**

- None

### **3.2.4. Family anamnesis**

- No children.
- He has one brother who is healthy.
- Mother 2<sup>nd</sup> type of Diabetes mellitus

### **3.2.5. Social anamnesis**

- He lives by himself in a flat.
- Divorced.

### **3.2.6. Occupational anamnesis**

- Retired
- He used to be an Office manager in a bank in Prague.

### **3.2.7. Hobbies - ADL**

- He takes care about himself.
- None problems with his ADL, only in the beginning of his problem, he had some problems with drinking and chewing.

### **3.2.8. Allergic anamnesis**

- None

### **3.2.9. Pharmacological anamnesis**

- 3 pills in the morning and 2 pills in the evening for his heart. He doesn't remember the name of the medication.

### **3.2.10. Abuses**

- He doesn't smoke.
- He doesn't drink.

### 3.2.11. Previous Rehabilitation

- Bell's palsy on the right side which started on October 2008 and ended on January 2009.
- None other rehabilitation except Bell's palsy.

### 3.2.12. Statement from the patient's medical documentation

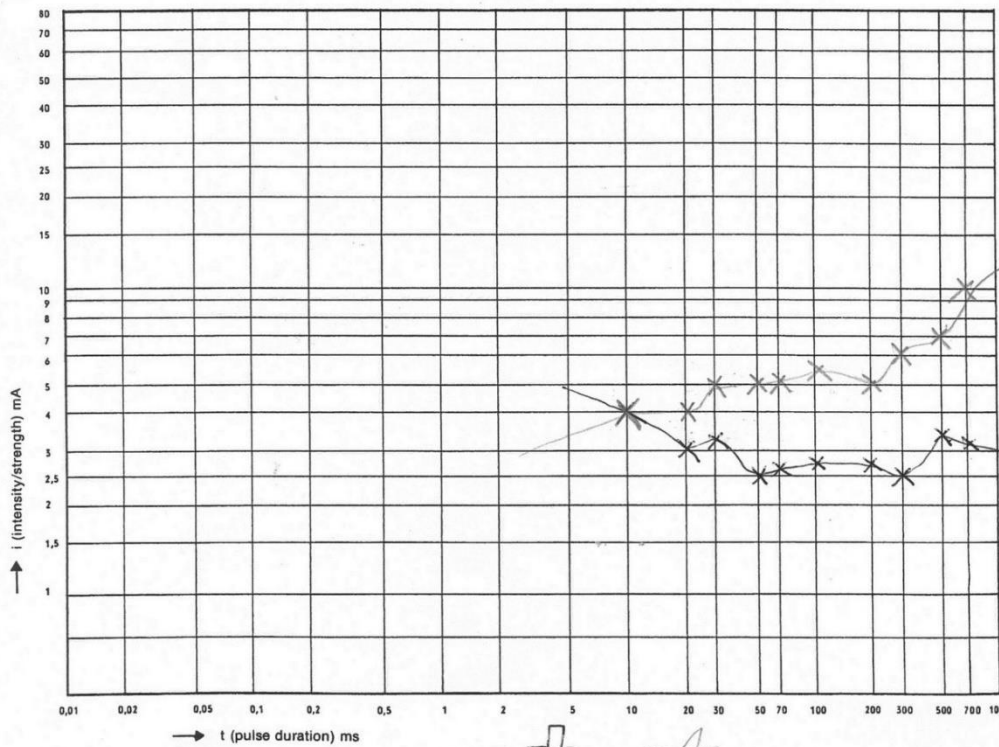
- I/t curve documentation



Strength/duration plotting form

Patient: <i>K A</i>	Examiner: <i>STRANSKY MICHAELA</i>
Date of birth: <i>11 01 17 11 13</i>	Date:
Anamnesis:	
Diagnosis:	
Conclusion:	
Muscle or nerve:	
Rheobase: <i>10,1</i> mA	Chronaxie: <i>30</i> ms
Faradic excitable: <input checked="" type="radio"/> yes / no	
Accommodation quotient: <i>3,1</i>	

*m. frontalis sivo*



### **3.2.13. Indication of rehabilitation**

- Daily individual physiotherapy of a peripheral paresis on the neurological basement.
- Electro stimulation.
- None information about the doctor's name.

### **3.2.14. Differential balance**

Even though that the diagnosis of this patient is found, I don't know if for sure the problem is originated from the brain (central) or from the nerve (peripheral). If the problem is central that means that the patient except the typical symptoms of the facial paresis, he will have also some vestibular dysfunctions such as disorientation, inability to balance body, limbs, head even the eyes in standing, sitting position or in lying position. Also some hearing asymmetry could be found. This can be tested during the neurological examination. If he doesn't have any hearing problems so that means that our patient is suffering from a facial peripheral paresis. Mentioning that 5 years ago when he had the facial paresis on his right side, was peripheral as well.

Also according the soft tissue of the patient's face could be restricted in skin and subcutaneous. Specifically, around the area of the forehead, around the zygomatic bone and around the chin. There will be some weakness of the facial muscles on the left side and asymmetries of the facial expressions comparing both sides. Lagophthalmos there will be present on the left side. There will be some drop of the left corner of the eye and mouth, loss of the eyelids reflex or palpebral reflex in which the eyelid should blink, dropping of the eyebrows, making some grins, pooch expression and whistle will be unable. There will be difficulties in fill the mouth with air because of weakness on the muscles of the lips trying not to be any leakage of air between the lips. About the muscles of the lips are the buccinator, orbicularis oris, modiolus, risorius, depressor anguli oris, depressor labii inferioris and mentalis. During the drinking activity, there would be some oozing of the fluid from the lips caused again from the mentioned weak muscles around the lips. Further, more comparing the both sides, the main symptom will be the asymmetry and maybe the right side (good side) could be affected after some time. So, it is necessary to work on the right as well as on the left side of course. The joints on the face, specifically on the left side the temporomandibular joint I suppose that there would be some blockage.

### **3.3. INITIAL KINESIOLOGIC EXAMINATION**

#### **3.3.1. Posture examination**

##### *3.3.1.1. Front side*

- External rotation of the right foot.
- Left side of the pelvis lower than the right one.
- Body is leaning to the left.
- Left shoulder lower than the right one.
- Head is leaning slightly to the left.

##### *3.3.1.2. Posterior side*

- External rotation of the right foot.
- Left side of the pelvis lower than the right one.
- Right scapula/shoulder blade has bigger space from the spine comparing the other side.
- Left shoulder lower than the right one.
- Head is leaning slightly to the left.

##### *3.3.1.3. Lateral side (both sides – comparing)*

- Right foot in external rotation
- Right knee more extended than the left one.
- Anterior tilt of pelvis
- Lordosis of lumbar spine
- Left shoulder lower than the right one.
- Head neutral position.

##### *3.3.1.4. Facial aspect (both sides – comparing)*

- Left eye is less wide open than the right one.
- Left cheek is lower than the right one.
- Left lower corner of the mouth is lower.
- Left eyebrow is lower than the right one.



### 3.3.2. Muscle tone testing (palpation) by Lewit

<u>Muscle palpated – Inn. Facial</u> <u>Nerve</u>	<u>Left Side</u>	<u>Right Side</u>
<i>Frontalis</i>	Not hypertonic	Not hypertonic
<i>Corrugator Supercilii</i>	Not hypertonic	Not hypertonic
<i>Nasalis</i>	Not hypertonic	Not hypertonic
<i>Depressor septi</i>	Not hypertonic	Not hypertonic
<i>Procerus</i>	Not hypertonic	Not hypertonic
<i>Levator anguli oris</i>	Not hypertonic	Not hypertonic
<i>Risorius</i>	Not hypertonic	Not hypertonic
<i>Zygomaticus Major</i>	Not hypertonic	Not hypertonic
<i>Zygomaticus Minor</i>	Not hypertonic	Not hypertonic
<i>Levator labii</i>	Not hypertonic	Not hypertonic
<i>Depressor labii inferior</i>	Not hypertonic	Not hypertonic
<i>Orbicularis oris</i>	Not hypertonic	Not hypertonic
<i>Buccinator</i>	Not hypertonic	Not hypertonic
<i>Mentalis</i>	Not hypertonic	Not hypertonic
<i>Depressor anguli oris</i>	Not hypertonic	Not hypertonic
<i>Orbicularis oculi</i>	Not hypertonic	Not hypertonic
<i>Sternocleidomastroideus m.</i>	Not hypertonic	Not hypertonic
<i>Platysma</i>	Not hypertonic	Not hypertonic
<i>Trapezius m. group.</i>	Not hypertonic	Not hypertonic

Table No6: – Initial examination

Muscle tone examination [12]

### 3.3.3. Muscle strength test by Kendall

<u>Muscle tested – Inn. Facial</u> <u>Nerve</u>	<u>Left Side</u>	<u>Right Side</u>
<i>Frontalis</i>	1	4
<i>Corrugator Supercilii</i>	1	4-
<i>Nasalis</i>	0	3
<i>Depressor septi</i>	1	3-
<i>Procerus</i>	1	3
<i>Levator anguli oris</i>	1	4-
<i>Risorius</i>	2	4+
<i>Zygomaticus Major</i>	1	4-
<i>Zygomaticus Minor</i>	1	4-
<i>Levator labii</i>	2	4+
<i>Depressor labii inferior</i>	2	4-
<i>Orbicularis oris</i>	1	4+
<i>Buccinator</i>	0	3-
<i>Mentalis</i>	0	3-
<i>Depressor anguli oris</i>	0	3-
<i>Orbicularis oculi</i>	2-	4+

Table No7 – Initial kinesiological examination

Muscle strength test [8]

0 = none contraction

1= none movement but the contraction can be felt by palpating the tendon.

2= movement through partial range of motion (ROM)

3= can move and hold against the gravity but cannot hold it if even slight pressure is applied.

4= can hold the test position against moderate pressure.

5= can hold the test position against strong pressure.

### 3.3.4. Muscle length testing by Janda

<u>Muscle tested</u>	<u>Left side</u>	<u>Right side</u>
<i>Levator Scapulae m.</i>	0	1
<i>Trapezius m. (Upper part)</i>	0	1
<i>Sternocleidomastoid m.</i>	0	1
<i>Scalene m.</i>	0	1

Table No8 – Initial kinesiological examination

#### Muscle length testing

0 = No shortness

1 = Moderate shortness

2 = Marked shortness

### 3.3.5. ROM evaluation in SFTR method by Russe and Gerthard

<u>Cervical Spine - ROM</u>	<u>Active Movement</u>	<u>Passive Movement</u>
<i>Sagittal plane</i>	45 – 0 – 40	50 – 0 – 45
<i>Coronal plane (frontal)</i>	45 – 0 – 45	50 – 0 – 50
<i>Transverse plane</i>	50 – 0 – 48	55 – 0 - 53

Table No9 – Initial kinesiological examination

#### ROM evaluation

### 3.3.6. Breathing examination

*Observation of the breathing pattern focused on the chest and ribs*

- The patient is breathing with an abdominal breathing way.

### 3.3.7. Movement patterns

*Neck flexion*

The patient is providing neck flexion in a physiological way. The deep neck flexors and sternocleidomastoid muscle are starting the movement. None altered movement is observed.

### **3.3.8. Hypermobility examination (by Sachse)**

Rotation of cervical spine

- Left side: Grade B - 90 degrees
- Right side: Grade B – 90 degrees

### **3.3.9. Stability examination**

#### *3.3.9.1. Romberg test*

- Romberg I: with heels together – negative
- Romberg II: with feet together – negative
- Romberg III: with eyes closed and feet standing normally – negative

#### *3.3.9.2. Scale test*

- Left scale: 53 K.g.
- Right scale: 45 K.g.

**Result:** Physiological

#### *3.3.9.3. Trendelenburg*

- Left side: Positive
- Right side: Negative

### **3.3.10. Facial expressions test (compared on both sides)**

- Happy face: Not symmetrical
- Sad face: Not symmetrical
- Fear expression: Not symmetrical
- Nasal opening: Not symmetrical
- Surprised face: Not symmetrical
- Angered face: Not symmetrical

### 3.3.11. Neurological examination

- Vestibular analyzer
  - Hautant's test normal and modification by Lewit: negative both

- Hearing test

Hearing the clipping sound of the fingers in both sides on the same level

- Symmetrical

- Nasopalpebral reflex

- Negative

#### 3.3.11.1. Cranial nerves examination

*I. Nervus olfactorius:* negative

*II. Nervus ophthalmicus:* negative

*III. Nervus oculomotorius:* negative

*IV. Nervus trochlearis:* negative

*V. Nervus trigeminus:* negative

*VI. Nervus abducens:* negative

*VII. Nervus facialis:* positive

*VIII. Nervus vestibulocochlearis:* negative

*IX. Nervus glossopharyngeus:* negative

*X. Nervus vagus:* negative

*XI. Nervus accessorius:* negative

*XII. Nervus hypoglossus:* negative

#### 3.3.11.2. Examination of superficial sensory information

<u>Sensory examination</u>	<u>Neck</u>	<u>(C4)Shoulder/ Upper arm</u>	<u>(C6-T1)Forearm/ (C6-C8) Wrist</u>
	<i>Non-cortical sensory system</i>		
<i>Light touch</i>	S + P	S + P	S + P
<i>Heat</i>	S + P	S + P	S + P
<i>Cold</i>	S + P	S + P	S + P
<i>Vibration</i>	S + P	S + P	S + P
<i>Pain</i>	S + P	S + P	S + P

Table No10 – Initial examination - Neurological examination

*S= symmetrical, A= asymmetrical, P=positive, N= negative*

### **3.3.12. Soft-tissue examination by Lewit [12]**

- Skin was tested with two fingers and it was performed a skin separation, which was physiological.

Specifically, it was tested on the areas of the forehead, around the eyes, cheek area, chin and lip area in both side.

- The subcutaneous layer was tested in the same way but with bigger pressure on the patient's skin to reach the subcutaneous layer. Also this layer was physiological.

The tested areas are the same with the skin-tissue examination.

### **3.3.13. ADL examination**

Examination of the 5 basic activities of the daily living of the patient

- Drinking from a glass/ straw: positive/ negative
- Eat something: positive
- Dress up: positive
- Cleaning himself (not examined): it was examined only by movement-like take a shower e.g., the test is positive
- Taking care of his environment in which he lives in: positive

*Positive: he is able to this action*

*Negative: he is unable to this action*

### **3.3.14. Conclusion of examination**

As I saw from the first day that I met and examine Mr. A. K., I found some symptoms that I was expecting for his diagnosis. Such as inability to provide some facial movements/ expressions correctly which are elevation of eyebrows, close of the affected eye (left) completely and with strength, tooth smile, simple smile, kiss face, bringing down the chin, inflate face, opening of the nostrils. The sensory information was physiological and symmetrical. About the neurological examination in general, the examination of the cranial nerves were negative all except the 7<sup>th</sup> cranial nerve/facial n. which is responsible for the problem of my patient. The sensory examination with the light touch, heat, cold and pitching or a sharp object (pain) was symmetrical and positive which means that is physiological and there aren't any problems in that area.

It was applied on the face, neck, shoulder, upper arm, forearm and wrist of the patient (in all the sides of each area). The soft-tissue was also normal with none restrictions. The muscle strength of the affected muscles is not so good because the patient is unable to perform to full movement due to the fact that the facial nerve is not working properly due to his problem. Also there are a lot of weak muscles such as frontalis, corrugator supercilii, nasalis, depressor septi, procerus, levator anguli oris, zygomaticus major, zygomaticus minor, orbicularis oris, buccinator, mentalis, and depressor anguli oris.

His mood as well was neither good but neither bad.

The main concept is that the patient is unable to provide correctly and without any problems the facial expressions which are used for his ADL. For the full recovery for this patient I believe that it will be required at least 1 month of rehabilitation and of course with the cooperation of the patient by providing the exercise program at home which it would be given by his physiotherapist.

### **3.4. SHORT-TERM AND LONG-TERM REHABILITATION PLAN**

#### ***3.4.1. Short- term plan***

- 1) Improve the look of the state of the patient's face
- 2) Stimulation of the affected/uncontrollable muscles
- 3) Normal speech, drinking and eating activity. (Important ADL)
- 4) Instruct the patient how he could manage his state (emotionally) by talking to him
- 5) Explain to the patient how he should protect himself for a better treatment of his diagnosis

#### ***3.4.2. Long-term plan***

- 1) Reinforce the affected muscles
- 2) Be able to provide all the difficult movements which were impossible to provide before
- 3) Regain the original ADL/original state

### **Therapy proposal**

**a.** Thermal treatments

- Hot rolls in all the affected parts of the patient's face

**b.** Soft-tissue techniques

**c.** Kinesiologic exercise

- Active movements with semi-passive movements

**d.** Acupuncture

- Application of the acupuncture method in all the trigger points of the affected area of the patient's face

**e.** Physical therapy

- Electrostimulation

**f.** Psychotherapy

*End of Examinations*

---



### **3.5. THERAPY SESSIONS**

*1<sup>st</sup> therapy: Monday 3<sup>rd</sup> of February 2014*

#### **Today's present state**

- The patient's mood was normal.
- None pain.
- Some ADL problems which are the drinking with straw, a little bit by drinking from the glass and chewing the food on the left side of the mouth.

#### **Today's therapy proposal**

- Hot rolls in all the affected parts of the patient's face.
- Parafingo/ parafango in all the affected parts of the patient's face.
- Active movements with semi-passive movements
- Soft-tissue massage
- Kenny method.
- Electrostimulation
- Facial expressions exercises.

#### **Goal of today's therapy**

- Take the whole anamnesis of Mr A. K.
- Initial kinesiologic examination.
- Stimulate the affected part of the patient's face.
- Stretch the non-affected part of the patient's face.
- Improve the ADL of the patient.

## **Procedure**

- **Taking anamnesis**

- i. Personal, operational, family, social, occupational, hobbies-ADL, allergic, pharmacological and abuses anamnesis
- ii. Previous rehabilitation
- iii. Medical documentation

- **Initial kinesiological examination**

- i. Posture examination
- ii. Muscle tone testing by Lewit
- iii. Muscle strength testing by Kendall
- iv. Facial expressions examination
- v. Neurological examination
- vi. Soft-tissue examination

- **Soft-tissue techniques**

Relaxing/therapeutic massage around the left side of the face in the direction of the contraction of the muscles. This procedure it was applied starting from the area of the forehead on the frontalis m., corrugator supercilii m., nasalis m., depressor septi m., procerus m., levator anguli oris m., risorius m., zygomaticus major, minor m., levator labii m., depressor labii inferior m., orbicularis oris m., buccinator m., mentalis m., depressor anguli oris m., orbicularis oculi m. and finishing on the area of the mouth and specifically on the chin.

Time: 5-7 minutes

- **Kenny method**

*Objective of today's therapeutic unit:* First it is instructed to the patient what kind of movements I would like that Mr. A. K. achieves. The application of Kenny method around the left side of the patient's face. Specifically, on the forehead, eyebrows, left side of the eye, around the eye, below the eye area, on all the parts of the left of the cheek, right near of the nose, upper lips, end of the lip and below the lower lip. The patient's position was in supine lying position with a comfortable pillow beneath his head. My position as a physiotherapist was above his face.

The specific muscles in which this method was applied were

- *Forehead:* Frontalis m
- *Eyebrows:* Frontalis m. Corrugator supercilii m., levator anguli oris m
- *Close of the eye:* Orbicularis oculi m
- *Cheek's area:* risorius, zygomaticus major, minor m. buccinator
- *Near to the nose area:* procerus m., nasalis m., levator anguli oris, depressor septi and transverse portion nasalis m
- *Lips area:* levator labii superioris m., depressor labii inferioris and platysma, orbicularis oris m., mentalis m., depressor anguli oris m

*Draft therapy:* The Kenny method is started with stretching of the part of the face that I would like to stimulate. Then after the stretching of this part, it's provided passive vibratory movement in the direction that the muscle in which Kenny method is applied, goes. After the passive movement, the patient is asked to try to provide the movement by saying to him, elevate your eyebrows and simultaneously me as a physiotherapist I am stimulating the frontalis m. in a cranial direction to help the patient providing this movement. All this process it was done for about 2 times in each part of the patient's face where Kenny method was applied.

As I mentioned, first it was applied on the forehead. Stretching of the frontalis m. in a caudal direction and then passive vibratory movement cranially. Then active movement with a passive stimulation by me in a cranial direction. In the same way it was applied in the rest of the forehead. Then it continues to the eyebrows, on the side of the left eye, around the eye, all the way around the cheeks, lips and mouth. All this process works as a very good implementation to assist the patient on regaining his controlling of the affected muscles.

The time of the whole application on the left side of the patient's face lasted for about 10-15 minutes.

- **Electro stimulation**

The electrostimulation was applied in all the parts of the left side of the patient's face. Specifically, it was used the pen-like head of the electrostimulation machine that covers only one point of the muscle in which it is applied. The patient's position was in supine lying position. My position as a physiotherapist was above of the patient's face. Starting from the forehead towards the area below the lower lip. In each part of the forehead, the electrostimulation was applied on one point at the time waiting for 3 contractions in each separated point the area applied. The intensity of the electrostimulation was 5-10 mA, with length of impulse 20 ms and 3 sec of pause between the contraction. Duration of the whole application lasted for about 5 minutes.

The muscles that were stimulated and applied this therapy were frontalis, corrugator supercilii, nasalis, depressor septi, procerus, levator anguli oris, risorius, zygomaticus major, minor, levator labii, depressor labii inferior, orbicularis oris, buccinator, mentalis, depressor anguli oris, orbicularis oculi.

- **Kinesio-tape**

The tape was applied from the area of the zygomaticus bone and then the tape splitted into 3 parts which each part was applied into the lower, middle and upper part of the left cheek respectively. The patient had it for 2, 3 days.

Kinesio-tape mainly is a technique based on the body's own natural healing process. It is a latex free material with acrylic adhesive, which is heat activated. The main therapy effect is to assist and give support or to prevent over-contraction.

### **Results**

The patient didn't have some many results but therapy after therapy and day by day, the results will appear soon.

*I was told that because this therapy is the 9<sup>th</sup> therapy of the patient and comparing this result with the patient's 1<sup>st</sup> therapy the results are very good. His face looks much different than the first time. Also, my supervisor at the hospital told me that his improvement since now from the 1<sup>st</sup> therapy of the patient by my supervisor was approximately about 45%.*

## **Self-therapy**

The self-therapy that I recommend to my patient is to perform some exercises which each of these exercises should be provided every day by 3 times, 1 time in the morning, 1 time in the midday and 1 time in the evening.

### **Monday 3<sup>rd</sup> of February 2014 Self therapy schedule No 1**

#### **1<sup>st</sup> exercise**

Fill in the mouth with air and trying to keep the air inside that the air couldn't get away by pushing both cheeks with both hands.

#### **2<sup>nd</sup> exercise**

Stretch the affected side using one hand from inside towards outside.

#### **3<sup>rd</sup> exercise**

Stretch the affected and the non-affected side using a spoon from the inner surface of the cheek

#### **4<sup>th</sup> exercise**

Stand in front of the mirror. Slowly and as much as clearly possible say out loud all the vocals of the alphabet. Perform this exercise for 3-5 minutes.

#### **5<sup>th</sup> exercise**

Take a glass of water and try to drink using a straw but do not let your lips to let the water come out of the mouth. Try to use the muscles of the lips to keep the water in the mouth while drinking with the straw.

***1<sup>st</sup> Therapy***

---

### ***2<sup>nd</sup> therapy: Tuesday 4<sup>th</sup> of February 2014***

#### **Today's present state**

- The patient's mood was normal
- None pain
- Still some ADL problems which are the drinking with straw, a little bit by drinking from the glass and chewing the food on the left side of the mouth

### **Today's therapy proposal**

- Hot rolls in all the affected parts of the patient's face
- Parafango/ parafango in all the affected parts of the patient's face
- Active movements with semi-passive movements
- Soft-tissue massage
- Kenny method
- Electrostimulation
- Facial expressions exercises

### **Goal of today's therapy**

- Stimulate the affected part of the patient's face
- Stretch the non-affected part of the patient's face
- Improve the state of the patient's face
- Improve the ADL of the patient

### **Procedure**

- **Soft-tissue techniques**

Relaxing/therapeutic massage around the left side of the face in the direction of the contraction of the muscles. This procedure it was applied starting from the area of the forehead on the frontalis m., corrugator supercilii m., nasalis m., depressor septi m., procerus m., levator anguli oris m., risorius m., zygomaticus major, minor m., levator labii m., depressor labii inferior m., orbicularis oris m., buccinator m., mentalis m., depressor anguli oris m., orbicularis oculi m. and finishing on the area of the mouth and specifically on the chin.

Time: 5-7 minutes.

- **Kenny method**

*Objective of today's therapeutic unit:* First it is instructed to the patient what kind of movements I would like that Mr. A. K. achieves. The application of Kenny method around the left side of the patient's face. Specifically, on the forehead, eyebrows, left side of the eye, around the eye, below the eye area, on all the parts of the left of the cheek, right near of the nose, upper lips, end of the lip and below the lower lip. The patient's position was in supine lying position with a comfortable pillow beneath his head. My position as a physiotherapist was above his face.

The specific muscles in which this method was applied were:

- *Forehead:* Frontalis m
- *Eyebrows:* Frontalis m. Corrugator supercilii m., levator anguli oris m
- *Close of the eye:* Orbicularis oculi m
- *Cheek's area:* risorius, zygomaticus major, minor m. buccinator
- *Near to the nose area:* procerus m., nasalis m., levator anguli oris, depressor septi and transverse portion nasalis m
- *Lips area:* levator labii superioris m., depressor labii inferioris and platysma, orbicularis oris m., mentalis m., depressor anguli oris m

*Draft therapy:* The Kenny method is started with stretching of the part of the face that I would like to stimulate. Then after the stretching of this part, it's provided passive vibratory movement in the direction that the muscle in which Kenny method is applied, goes.

After the passive movement, the patient is asked to try of provide the movement by saying to him, elevate your eyebrows and simultaneously me as a physiotherapist I am stimulating the frontalis m. in a cranial direction to help the patient providing this movement. All this process it was done for about 2 times in each part of the patient's face where Kenny method was applied.

As I mentioned, first it was applied on the forehead. Stretching of the frontalis m. in a caudal direction and then passive vibratory movement cranially. Then active movement with a passive stimulation by me in a cranial direction. In the same way it was applied in the rest of the forehead. Then it continues to the eyebrows, on the side of the left eye, around the eye, all the way around the cheeks, lips and mouth.

All this process works as a very good implementation to assist the patient on regaining his controlling of the affected muscles.

The time of the whole application on the left side of the patient's face lasted for about 10-15 minutes.

- **Electro stimulation**

The electrostimulation was applied in all the parts of the left side of the patient's face. Specifically, it was used the pen-like head of the electrostimulation machine that covers only one point of the muscle in which it is applied. The patient's position was in supine lying position. My position as a physiotherapist was above of the patient's face. Starting from the forehead towards the area below the lower lip. In each part of the forehead, the electrostimulation was applied on one point at the time waiting for 3 contractions in each separated point the area applied. The intensity of the electrostimulation was 5-10 mA, with length of impulse 20 ms and 3 sec of pause between the contraction. Duration of the whole application lasted for about 5 minutes.

The muscles that were stimulated and applied this therapy were frontalis, corrugator supercilii, nasalis, depressor septi, procerus, levator anguli oris, risorius, zygomaticus major, minor, levator labii, depressor labii inferior, orbicularis oris, buccinator, mentalis, depressor anguli oris, orbicularis oculi.

### **Results**

The patient didn't have some many results but therapy after therapy and day by day, the results will appear soon. Still his improvement remains at 45%.



## **Self-therapy**

The self-therapy that I recommend to my patient is to perform some exercises which each of these exercises should be provided every day by 3 times, 1 time in the morning, 1 time in the midday and 1 time in the evening.

### *Tuesday 4<sup>th</sup> of February 2014 Self therapy schedule No 2*

#### 1<sup>st</sup> exercise

Grab a glass of water, a straw and start blowing air through the straw to the glass against the water. Notice to keep your lips tight not letting the air coming out from the straw. The air that is blowing from your mouth should pass through the straw and with that the lips muscles are exercising. Blow the air until the last blow and repeat it again.

#### 2<sup>nd</sup> exercise

Hot-roll therapy. Grab a towel and twist it. From one side of the twisted towel fill it with hot water. Then, with gentle and swiping movements use it on the healthy side because the desired effect is the myorelaxation and is needed the relaxation of the hypertone area of the face.

Otherwise, if the patient does not feel comfortable he could grab an extended towel and fill it with lukewarm or warm but on under threshold on the patient and just keep the towel on the healthy side until the towel is not warm any more.

#### 3<sup>rd</sup> exercise

Stand in front of the mirror and start providing the main facial expressions. Expressions like smiling, sad face, angry face, send a kiss, bad smell-like face. Provide all these facial expressions slowly and while providing each movement motivate and focus on the muscle respectively, it will help the exercise to be more effective in the end.

#### 4<sup>th</sup> exercise

Stand in front of the mirror and start trying to whistle. Using your lip muscles try to whistle as much as possible loudly. This exercise will help you because it will make you to keep trying again and again until you will whistle.

#### 5<sup>th</sup> exercise

Stand in front of the mirror and using your thumb or index finger, start stretching the corner of your lips toward the mandible under the ear of the affected side.

***2<sup>nd</sup> Therapy***

---

**Today's present state**

- The patient's mood was quite better. He was trying to smile when he entered the therapeutic room
- None pain
- Still some ADL problems which are the drinking with straw, a little bit by drinking from the glass and chewing the food on the left side of the mouth

**Today's therapy proposal**

- Hot rolls in all the affected parts of the patient's face
- Parafango/ parafango in all the affected parts of the patient's face
- Active movements with semi-passive movements
- Soft-tissue massage
- Kenny method
- Electrostimulation
- Facial expressions exercises

**Goal of today's therapy**

- Stimulate the affected part of the patient's face
- Stretch the non-affected part of the patient's face
- Improve the state of the patient's face
- Improve the ADL of the patient

**Procedure**

• **Soft-tissue techniques**

Relaxing/therapeutic massage around the left side of the face in the direction of the contraction of the muscles. This procedure it was applied starting from the area of the forehead on the frontalis m., corrugator supercilii m., nasalis m., depressor septi m., procerus m., levator anguli oris m., risorius m., zygomaticus major, minor m., levator labii m., depressor labii inferior m., orbicularis oris m., buccinator m., mentalis m., depressor anguli oris m., orbicularis oculi m. and finishing on the area of the mouth and specifically on the chin.

Time: 5-7 minutes

- **Kenny method**

*Objective of today's therapeutic unit:* First it is instructed to the patient what kind of movements I would like that Mr. A. K. achieves. The application of Kenny method around the left side of the patient's face. Specifically, on the forehead, eyebrows, left side of the eye, around the eye, below the eye area, on all the parts of the left of the cheek, right near of the nose, upper lips, end of the lip and below the lower lip. The patient's position was in supine lying position with a comfortable pillow beneath his head. My position as a physiotherapist was above his face.

The specific muscles in which this method was applied were:

- *Forehead:* Frontalis m
- *Eyebrows:* Frontalis m. Corrugator supercilii m., levator anguli oris m
- *Close of the eye:* Orbicularis oculi m
- *Cheek's area:* risorius, zygomaticus major, minor m. buccinator
- *Near to the nose area:* procerus m., nasalis m., levator anguli oris, depressor septi and transverse portion nasalis m
- *Lips area:* levator labii superioris m., depressor labii inferioris and platysma, orbicularis oris m., mentalis m., depressor anguli oris m

*Draft therapy:* The Kenny method is started with stretching of the part of the face that I would like to stimulate. Then after the stretching of this part, it's provided passive vibratory movement in the direction that the muscle in which Kenny method is applied, goes.

After the passive movement, the patient is asked to try of provide the movement by saying to him, elevate your eyebrows and simultaneously me as a physiotherapist I am stimulating the frontalis m. in a cranial direction to help the patient providing this movement. All this process it was done for about 2 times in each part of the patient's face where Kenny method was applied.

As I mentioned, first it was applied on the forehead. Stretching of the frontalis m. in a caudal direction and then passive vibratory movement cranially. Then active movement with a passive stimulation by me in a cranial direction. In the same way it was applied in the rest of the forehead.

Then it continues to the eyebrows, on the side of the left eye, around the eye, all the way around the cheeks, lips and mouth. All this process works as a very good implementation to assist the patient on regaining his controlling of the affected muscles.

The time of the whole application on the left side of the patient's face lasted for about 10-15 minutes.

- **Electro stimulation**

The electrostimulation was applied in all the parts of the left side of the patient's face. Specifically, it was used the pen-like head of the electrostimulation machine that covers only one point of the muscle in which it is applied. The patient's position was in supine lying position. My position as a physiotherapist was above of the patient's face. Starting from the forehead towards the area below the lower lip. In each part of the forehead, the electrostimulation was applied on one point at the time waiting for 3 contractions in each separated point the area applied.

The intensity of the electrostimulation was 5-10 mA, with length of impulse 20 ms and 3 sec of pause between the contraction. Duration of the whole application lasted for about 5 minutes.

The muscles that were stimulated and applied this therapy were frontalis, corrugator supercilii, nasalis, depressor septi, procerus, levator anguli oris, risorius, zygomaticus major, minor, levator labii, depressor labii inferior, orbicularis oris, buccinator, mentalis, depressor anguli oris, orbicularis oculi.

## **Results**

The patient had some improvements according to some facial expressions but some expressions; he is not able to provide them yet. I also should say that Mr. A. K. respects his self-therapy and that's why we can see faster results. I could say that his improvement is about 50% because now he's able to do some movements that he was unable to do them before.

## **Self-therapy**

The self-therapy that I recommend to my patient is to perform some exercises which each of these exercises should be provided every day by 3 times, 1 time in the morning, 1 time in the midday and 1 time in the evening.

### Wednesday 5<sup>th</sup> of February 2014 Self therapy schedule No 3

#### 1<sup>st</sup> exercise

Stand in front of the mirror. Slowly and as much as clearly possible say out loud all the vocals of the alphabet. Perform this exercise for 3-5 minutes.

#### 2<sup>nd</sup> exercise

Take a glass of water and try to drink using a straw but do not let your lips to let the water come out of the mouth. Try to use the muscles of the lips to keep the water in the mouth while drinking with the straw.

#### 3<sup>rd</sup> exercise

Stand in front of the mirror and try to elevate your eye brows for about 10-15 seconds each time, then pause and repeat again.

#### 4<sup>th</sup> exercise

Stand in front of the mirror and try to open widely your eyes but without using your eyebrows muscles.

#### 5<sup>th</sup> exercise

Stand in front of the mirror and try to close your eye of the affected side, slowly and gently but without letting your eyebrows decrease or your mouth pulled up.

*3<sup>rd</sup> Therapy*

---

**Today's present state**

- The patient's mood was the same as yesterday
- None pain
- Still some ADL problems which are the drinking with straw, a little bit by drinking from the glass and chewing the food on the left side of the mouth

**Today's therapy proposal**

- Hot rolls in all the affected parts of the patient's face
- Parafingo/ parafango in all the affected parts of the patient's face
- Active movements with semi-passive movements
- Soft-tissue massage
- Kenny method
- Electrostimulation
- Facial expressions exercises

**Goal of today's therapy**

- Stimulate the affected part of the patient's face
- Stretch the non-affected part of the patient's face
- Improve the state of the patient's face
- Improve the ADL of the patient

**Procedure**

• **Soft-tissue techniques**

Relaxing/therapeutic massage around the left side of the face in the direction of the contraction of the muscles. This procedure it was applied starting from the area of the forehead on the frontalis m., corrugator supercilii m., nasalis m., depressor septi m., procerus m., levator anguli oris m., risorius m., zygomaticus major, minor m., levator labii m., depressor labii inferior m., orbicularis oris m., buccinator m., mentalis m., depressor anguli oris m., orbicularis oculi m. and finishing on the area of the mouth and specifically on the chin.

Time: 5-7 minutes

- **Kenny method**

*Objective of today's therapeutic unit:* First it is instructed to the patient what kind of movements I would like that Mr. A. K. achieves. The application of Kenny method around the left side of the patient's face. Specifically, on the forehead, eyebrows, left side of the eye, around the eye, below the eye area, on all the parts of the left of the cheek, right near of the nose, upper lips, end of the lip and below the lower lip. The patient's position was in supine lying position with a comfortable pillow beneath his head. My position as a physiotherapist was above his face.

The specific muscles in which this method was applied were:

- *Forehead:* Frontalis m
- *Eyebrows:* Frontalis m., Corrugator supercilii m., levator anguli oris m
- *Close of the eye:* Orbicularis oculi m
- *Cheek's area:* risorius, zygomaticus major, minor m. buccinator
- *Near to the nose area:* procerus m., nasalis m., levator anguli oris, depressor septi and transverse portion nasalis m
- *Lips area:* levator labii superioris m., depressor labii inferioris and platysma, orbicularis oris m., mentalis m., depressor anguli oris m

*Draft therapy:* The Kenny method is started with stretching of the part of the face that I would like to stimulate. Then after the stretching of this part, it's provided passive vibratory movement in the direction that the muscle in which Kenny method is applied, goes. After the passive movement, the patient is asked to try of provide the movement by saying to him, elevate your eyebrows and simultaneously me as a physiotherapist I am stimulating the frontalis m. in a cranial direction to help the patient providing this movement. All this process it was done for about 2 times in each part of the patient's face where Kenny method was applied.

As I mentioned, first it was applied on the forehead. Stretching of the frontalis m. in a caudal direction and then passive vibratory movement cranially. Then active movement with a passive stimulation by me in a cranial direction. In the same way it was applied in the rest of the forehead. Then it continues to the eyebrows, on the side of the left eye, around the eye, all the way around the cheeks, lips and mouth.

All this process works as a very good implementation to assist the patient on regaining his controlling of the affected muscles. The time of the whole application on the left side of the patient's face lasted for about 10-15 minutes.

- **Electro stimulation**

The electrostimulation was applied in all the parts of the left side of the patient's face. Specifically, it was used the pen-like head of the electrostimulation machine that covers only one point of the muscle in which it is applied. The patient's position was in supine lying position. My position as a physiotherapist was above of the patient's face. Starting from the forehead towards the area below the lower lip. In each part of the forehead, the electrostimulation was applied on one point at the time waiting for 3 contractions in each separated point the area applied. The intensity of the electrostimulation was 5-10 mA, with length of impulse 20 ms and 3 sec of pause between the contraction. Duration of the whole application lasted for about 5 minutes.

The muscles that were stimulated and applied this therapy were frontalis, corrugator supercilii, nasalis, depressor septi, procerus, levator anguli oris, risorius, zygomaticus major, minor, levator labii, depressor labii inferior, orbicularis oris, buccinator, mentalis, depressor anguli oris, orbicularis oculi.

### **Results**

The patient had some improvements according to some facial expressions but some expressions; he is not able to provide them yet. Improvement still at 50%.

### **Self-therapy**

The self-therapy that I recommend to my patient is to perform some exercises which each of these exercises should be provided every day by 3 times, 1 time in the morning, 1 time in the midday and 1 time in the evening.

*Thursday 6<sup>th</sup> of February 2014 Self therapy schedule No 4*

#### 1<sup>st</sup> exercise

Stand in front of the mirror and start trying to whistle. Using your lip muscles try to whistle as much as possible loudly. This exercise will help you because it will make you to keep trying again and again until you will whistle.

#### 2<sup>nd</sup> exercise

Stand in front of the mirror, slowly and as much as clearly possible say out loud all the vocals of the alphabet. Perform this exercise for 3-5 minutes.

#### 3<sup>rd</sup> exercise

Stand in front of the mirror, fill in your mouth with air and trying to keep the air inside that the air couldn't get away by pushing both cheeks with both hands.



#### 4<sup>th</sup> exercise

Stand in front of the mirror and using your thumb or index finger, start stretching the corner of your lips toward the mandible under the ear of the affected side.

#### 5<sup>th</sup> exercise

Hot-roll therapy. Grab a towel and twist it. From one side of the twisted towel fill it with hot water. Then, with gentle and swiping movements use it on the healthy side because the desired effect is the myorelaxation and is needed the relaxation of the hypertone area of the face. Otherwise, if the patient does not feel comfortable he could grab an extended towel and fill it with lukewarm or warm but on under threshold on the patient and just keep the towel on the healthy side until the towel is not warm any more.

*4<sup>th</sup> Therapy*

---

<p><i>5<sup>th</sup> therapy: Friday 7<sup>th</sup> of February 2014</i></p>
--

#### **Today's present state**

- The patient's mood was the same as yesterday
- None pain
- Still some ADL problems which are the drinking with straw, a little bit by drinking from the glass and chewing the food on the left side of the mouth

#### **Today's therapy proposal**

- Hot rolls in all the affected parts of the patient's face
- Parafingo/ parafango in all the affected parts of the patient's face
- Active movements with semi-passive movements
- Soft-tissue massage
- Kenny method
- Electrostimulation
- Facial expressions exercises

#### **Goal of today's therapy**

- Stimulate the affected part of the patient's face
- Stretch the non-affected part of the patient's face
- Improve the state of the patient's face
- Improve the ADL of the patient

## **Procedure**

- **Soft-tissue techniques**

Relaxing/therapeutic massage around the left side of the face in the direction of the contraction of the muscles. This procedure it was applied starting from the area of the forehead on the frontalis m., corrugator supercilii m., nasalis m., depressor septi m., procerus m., levator anguli oris m., risorius m., zygomaticus major, minor m., levator labii m., depressor labii inferior m., orbicularis oris m., buccinator m., mentalis m., depressor anguli oris m., orbicularis oculi m. and finishing on the area of the mouth and specifically on the chin.

Time: 5-7 minutes

- **Kenny method**

*Objective of today's therapeutic unit:* First it is instructed to the patient what kind of movements I would like that Mr. A. K. achieves. The application of Kenny method around the left side of the patient's face. Specifically, on the forehead, eyebrows, left side of the eye, around the eye, below the eye area, on all the parts of the left of the cheek, right near of the nose, upper lips, end of the lip and below the lower lip. The patient's position was in supine lying position with a comfortable pillow beneath his head. My position as a physiotherapist was above his face. The specific muscles in which this method was applied were:

- *Forehead:* Frontalis m
- *Eyebrows:* Frontalis m. Corrugator supercilii m., levator anguli oris m
- *Close of the eye:* Orbicularis oculi m
- *Cheek's area:* risorius, zygomaticus major, minor m. buccinator
- *Near to the nose area:* procerus m., nasalis m., levator anguli oris, depressor septi and transverse portion nasalis m
- *Lips area:* levator labii superioris m., depressor labii inferioris and platysma, orbicularis oris m., mentalis m., depressor anguli oris m

*Draft therapy:* The Kenny method is started with stretching of the part of the face that I would like to stimulate. Then after the stretching of this part, it's provided passive vibratory movement in the direction that the muscle in which Kenny method is applied, goes. After the passive movement, the patient is asked to try of provide the movement by saying to him, elevate your eyebrows and simultaneously me as a physiotherapist I am stimulating the frontalis m. in a cranial direction to help the patient providing this movement. All this process it was done for about 2 times in each part of the patient's face where Kenny method was applied.

As I mentioned, first it was applied on the forehead. Stretching of the frontalis m. in a caudal direction and then passive vibratory movement cranially. Then active movement with a passive stimulation by me in a cranial direction. In the same way it was applied in the rest of the forehead. Then it continues to the eyebrows, on the side of the left eye, around the eye, all the way around the cheeks, lips and mouth. All this process works as a very good implementation to assist the patient on regaining his controlling of the affected muscles.

The time of the whole application on the left side of the patient's face lasted for about 10-15 minutes.

- **Electro stimulation**

The electrostimulation was applied in all the parts of the left side of the patient's face. Specifically, it was used the pen-like head of the electrostimulation machine that covers only one point of the muscle in which it is applied. The patient's position was in supine lying position. My position as a physiotherapist was above of the patient's face. Starting from the forehead towards the area below the lower lip. In each part of the forehead, the electrostimulation was applied on one point at the time waiting for 3 contractions in each separated point the area applied. The intensity of the electrostimulation was 5-10 mA, with length of impulse 20 ms and 3 sec of pause between the contraction. Duration of the whole application lasted for about 5 minutes.

The muscles that were stimulated and applied this therapy were frontalis, corrugator supercillii, nasalis, depressor septi, procerus, levator anguli oris, risorius, zygomaticus major, minor, levator labii, depressor labii inferior, orbicularis oris, buccinator, mentalis, depressor anguli oris, orbicularis oculi.

- **Kinesio-tape**

The tape was applied from the area of the zygomaticus bone and then the tape split into 3 parts which each part was applied into the lower, middle and upper part of the left cheek respectively. The patient had it for 2, 3 days.

Kinesio-tape mainly is a technique based on the body's own natural healing process. It is a latex free material with acrylic adhesive, which is heat activated. The main therapy effect is to assist and give support or to prevent over-contraction.

### **Results**

The patient had some improvements according to some facial expressions but some expressions; he is not able to provide them yet. Improvement is still 50%.

### **Self-therapy**

The self-therapy that I recommend to my patient is to perform some exercises which each of these exercises should be provided every day by 3 times, 1 time in the morning, 1 time in the midday and 1 time in the evening.

*Friday 7<sup>th</sup> of February 2014 Self therapy schedule No 5*

#### 1<sup>st</sup> exercise

Take a glass of water and try to drink using a straw but do not let your lips to let the water come out of the mouth. Try to use the muscles of the lips to keep the water in the mouth while drinking with the straw.

#### 2<sup>nd</sup> exercise

Stretch the affected and the non-affected side using a spoon from the inner surface of the cheek.

#### 3<sup>rd</sup> exercise

Stand in front of the mirror and start providing the main facial expressions. Expressions like smiling, sad face, angry face, send a kiss, bad smell-like face. Provide all these facial expressions slowly and while providing each movement motivate and focus on the muscle respectively, it will help the exercise to be more effective in the end.

#### 4<sup>th</sup> exercise

Stand in front of the mirror and try to open widely your eyes but without using your eyebrows muscles.

### 5<sup>th</sup> exercise

Stand in front of the mirror and gently wink with just one eye trying avoiding other activation of other facial muscles. Repeat the same to the other side.

*5<sup>th</sup> therapy*

---

<b><i>6<sup>th</sup> therapy: Monday 10<sup>th</sup> of February 2014</i></b>
---

### **Today's present state**

- The patient's mood was the same as yesterday
- None pain
- Still some ADL problems which are the drinking with straw, a little bit by drinking from the glass and chewing the food on the left side of the mouth

### **Today's therapy proposal**

- Hot rolls in all the affected parts of the patient's face
- Parafingo/ parafango in all the affected parts of the patient's face
- Active movements with semi-passive movements
- Soft-tissue massage
- Kenny method
- Electrostimulation
- Facial expressions exercises

### **Goal of today's therapy**

- Stimulate the affected part of the patient's face
- Stretch the non-affected part of the patient's face
- Improve the state of the patient's face
- Improve the ADL of the patient

## **Procedure**

- **Soft-tissue techniques**

Relaxing/therapeutic massage around the left side of the face in the direction of the contraction of the muscles. This procedure it was applied starting from the area of the forehead on the frontalis m., corrugator supercilii m., nasalis m., depressor septi m., procerus m., levator anguli oris m., risorius m., zygomaticus major, minor m., levator labii m., depressor labii inferior m., orbicularis oris m., buccinator m., mentalis m., depressor anguli oris m., orbicularis oculi m. and finishing on the area of the mouth and specifically on the chin.

Time: 5-7 minutes

- **Kenny method**

*Objective of today's therapeutic unit:* First it is instructed to the patient what kind of movements I would like that Mr. A. K. achieves. The application of Kenny method around the left side of the patient's face. Specifically, on the forehead, eyebrows, left side of the eye, around the eye, below the eye area, on all the parts of the left of the cheek, right near of the nose, upper lips, end of the lip and below the lower lip. The patient's position was in supine lying position with a comfortable pillow beneath his head. My position as a physiotherapist was above his face. The specific muscles in which this method was applied were:

- *Forehead:* Frontalis m
- *Eyebrows:* Frontalis m. Corrugator supercilii m., levator anguli oris m
- *Close of the eye:* Orbicularis oculi m
- *Cheek's area:* risorius, zygomaticus major, minor m. buccinator
- *Near to the nose area:* procerus m., nasalis m., levator anguli oris, depressor septi and transverse portion nasalis m
- *Lips area:* levator labii superioris m., depressor labii inferioris and platysma, orbicularis oris m., mentalis m., depressor anguli oris m

*Draft therapy:* The Kenny method is started with stretching of the part of the face that I would like to stimulate. Then after the stretching of this part, it's provided passive vibratory movement in the direction that the muscle in which Kenny method is applied, goes.

After the passive movement, the patient is asked to try of provide the movement by saying to him, elevate your eyebrows and simultaneously me as a physiotherapist I am stimulating the frontalis m. in a cranial direction to help the patient providing this movement. All this process it was done for about 2 times in each part of the patient's face where Kenny method was applied.

As I mentioned, first it was applied on the forehead. Stretching of the frontalis m. in a caudal direction and then passive vibratory movement cranially. Then active movement with a passive stimulation by me in a cranial direction. In the same way it was applied in the rest of the forehead. Then it continues to the eyebrows, on the side of the left eye, around the eye, all the way around the cheeks, lips and mouth.

All this process works as a very good implementation to assist the patient on regaining his controlling of the affected muscles.

The time of the whole application on the left side of the patient's face lasted for about 10-15 minutes.

- **Electro stimulation**

The electrostimulation was applied in all the parts of the left side of the patient's face. Specifically, it was used the pen-like head of the electrostimulation machine that covers only one point of the muscle in which it is applied. The patient's position was in supine lying position. My position as a physiotherapist was above of the patient's face. Starting from the forehead towards the area below the lower lip. In each part of the forehead, the electrostimulation was applied on one point at the time waiting for 3 contractions in each separated point the area applied. The intensity of the electrostimulation was 5-10 mA, with length of impulse 20 ms and 3 sec of pause between the contraction. Duration of the whole application lasted for about 5 minutes.

The muscles that were stimulated and applied this therapy were frontalis, corrugator supercilii, nasalis, depressor septi, procerus, levator anguli oris, risorius, zygomaticus major, minor, levator labii, depressor labii inferior, orbicularis oris, buccinator, mentalis, depressor anguli oris, orbicularis oculi.

### **Results**

The patient had some improvements according to some facial expressions but some expressions; he is not able to provide them yet. Improvement is still 50%.

### **Self-therapy**

The self-therapy that I recommend to my patient is to perform some exercises which each of these exercises should be provided every day by 3 times, 1 time in the morning, 1 time in the midday and 1 time in the evening.

#### *Monday 10<sup>th</sup> of February 2014 Self therapy schedule No 6*

##### 1<sup>st</sup> exercise

Stand in front of the mirror and using your thumb or index finger, start stretching the corner of your lips toward the mandible under the ear of the affected side.

##### 2<sup>nd</sup> exercise

Stand in front of the mirror and try to close your eye of the affected side, slowly and gently but without letting your eyebrows decrease or your mouth pulled up.

##### 3<sup>rd</sup> exercise

Grab a glass of water and try to drink using a straw but do not let your lips to let the water come out of the mouth. Try to use the muscles of the lips to keep the water in the mouth while drinking with the straw.

##### 4<sup>th</sup> exercise

Stand in front of the mirror and start trying to whistle. Using your lip muscles try to whistle as much as possible loudly. This exercise will help you because it will make you to keep trying again and again until you will whistle.

##### 5<sup>th</sup> exercise

Stretch the affected side using one hand from inside towards outside.

***6<sup>th</sup> therapy***

---



**Today's present state**

- The patient's mood was better. He was happy because he saw some improvement on his facial expressions and aspect. He was very satisfied
- None pain
- Still some ADL problems which are the drinking with straw, a little bit by drinking from the glass and chewing the food on the left side of the mouth

**Today's therapy proposal**

- Hot rolls in all the affected parts of the patient's face
- Parafango/ parafango in all the affected parts of the patient's face
- Active movements with semi-passive movements
- Soft-tissue massage
- Kenny method
- Electrostimulation
- Facial expressions exercises

**Goal of today's therapy**

- Stimulate the affected part of the patient's face
- Stretch the non-affected part of the patient's face
- Reinforce the weak areas of the patient's face
- Improve the state of the patient's face
- Improve the ADL of the patient

## **Procedure**

- **Soft-tissue techniques**

Relaxing/therapeutic massage around the left side of the face in the direction of the contraction of the muscles. This procedure it was applied starting from the area of the forehead on the frontalis m., corrugator supercilii m., nasalis m., depressor septi m., procerus m., levator anguli oris m., risorius m., zygomaticus major, minor m., levator labii m., depressor labii inferior m., orbicularis oris m., buccinator m., mentalis m., depressor anguli oris m., orbicularis oculi m. and finishing on the area of the mouth and specifically on the chin.

Time: 5-7 minutes

- **Kenny method**

*Objective of today's therapeutic unit:* First it is instructed to the patient what kind of movements I would like that Mr. A. K. achieves. The application of Kenny method around the left side of the patient's face. Specifically, on the forehead, eyebrows, left side of the eye, around the eye, below the eye area, on all the parts of the left of the cheek, right near of the nose, upper lips, end of the lip and below the lower lip. The patient's position was in supine lying position with a comfortable pillow beneath his head. My position as a physiotherapist was above his face. The specific muscles in which this method was applied were:

- *Forehead:* Frontalis m
- *Eyebrows:* Frontalis m. Corrugator supercilii m., levator anguli oris m
- *Close of the eye:* Orbicularis oculi m
- *Cheek's area:* risorius, zygomaticus major, minor m. buccinator
- *Near to the nose area:* procerus m., nasalis m., levator anguli oris, depressor septi and transverse portion nasalis m
- *Lips area:* levator labii superioris m., depressor labii inferioris and platysma, orbicularis oris m., mentalis m., depressor anguli oris m

*Draft therapy:* The Kenny method is started with stretching of the part of the face that I would like to stimulate. Then after the stretching of this part, it's provided passive vibratory movement in the direction that the muscle in which Kenny method is applied, goes. After the passive movement, the patient is asked to try of provide the movement by saying to him, elevate your eyebrows and simultaneously me as a physiotherapist I am stimulating the frontalis m. in a cranial direction to help the patient providing this movement. All this process it was done for about 2 times in each part of the patient's face where Kenny method was applied.

As I mentioned, first it was applied on the forehead. Stretching of the frontalis m. in a caudal direction and then passive vibratory movement cranially. Then active movement with a passive stimulation by me in a cranial direction. In the same way it was applied in the rest of the forehead. Then it continues to the eyebrows, on the side of the left eye, around the eye, all the way around the cheeks, lips and mouth. All this process works as a very good implementation to assist the patient on regaining his controlling of the affected muscles.

The time of the whole application on the left side of the patient's face lasted for about 10-15 minutes.

- **Electro stimulation**

The electrostimulation was applied in all the parts of the left side of the patient's face. Specifically, it was used the pen-like head of the electrostimulation machine that covers only one point of the muscle in which it is applied. The patient's position was in supine lying position. My position as a physiotherapist was above of the patient's face. Starting from the forehead towards the area below the lower lip. In each part of the forehead, the electrostimulation was applied on one point at the time waiting for 3 contractions in each separated point the area applied. The intensity of the electrostimulation was 5-10 mA, with length of impulse 20 ms and 3 sec of pause between the contraction. Duration of the whole application lasted for about 5 minutes.

The muscles that were stimulated and applied this therapy were frontalis, corrugator supercilii, nasalis, depressor septi, procerus, levator anguli oris, risorius, zygomaticus major, minor, levator labii, depressor labii inferior, orbicularis oris, buccinator, mentalis, depressor anguli oris, orbicularis oculi.

## **Results**

The patient had some improvements according to some facial expressions which now he is providing better with greater strength as well. Improvement is now 60%.

## **Self-therapy**

The self-therapy that I recommend to my patient is to perform some exercises which each of these exercises should be provided every day by 3 times, 1 time in the morning, 1 time in the midday and 1 time in the evening.

### *Tuesday 11<sup>th</sup> of February 2014 Self therapy schedule No 7*

#### 1<sup>st</sup> exercise

Stand in front of the mirror. Slowly and as much as clearly possible say out loud all the vocals of the alphabet. Perform this exercise for 3-5 minutes.

#### 2<sup>nd</sup> exercise

Hot-roll therapy. Grab a towel and twist it. From one side of the twisted towel fill it with hot water. Then, with gentle and swiping movements use it on the healthy side because the desired effect is the myorelaxation and is needed the relaxation of the hypertone area of the face. Otherwise, if the patient does not feel comfortable he could grab an extended towel and fill it with lukewarm or warm but on under threshold on the patient and just keep the towel on the healthy side until the towel is not warm any more.

#### 3<sup>rd</sup> exercise

Stand in front of the mirror and start trying to whistle. Using your lip muscles try to whistle as much as possible loudly. This exercise will help you because it will make you to keep trying again and again until you will whistle.

#### 4<sup>th</sup> exercise

Stand in front of the mirror and start providing the main facial expressions. Expressions like smiling, sad face, angry face, send a kiss, bad smell-like face. Provide all these facial expressions slowly and while providing each movement motivate and focus on the muscle respectively, it will help the exercise to be more effective in the end.

#### 5<sup>th</sup> exercise

Stand in front of the mirror and try to elevate your eye brows for about 10-15 seconds each time, then pause and repeat again.

*7<sup>th</sup> therapy*

---

**Today's present state**

- The patient's mood was still better and he told me that now is more motivated because yesterday he saw his big improvement and at home he is trying more with his self-therapy.
- None pain
- Still some ADL problems which are the drinking with straw, a little bit by drinking from the glass and chewing the food on the left side of the mouth.

**Today's therapy proposal**

- Hot rolls in all the affected parts of the patient's face
- Parafingo/ parafango in all the affected parts of the patient's face.
- Active movements with semi-passive movements
- Soft-tissue massage
- Kenny method
- Electrostimulation
- Facial expressions exercises

**Goal of today's therapy**

- Stimulate the affected part of the patient's face
- Stretch the non-affected part of the patient's face
- Reinforce the weak areas of the patient's face
- Improve the state of the patient's face
- Improve the ADL of the patient

## **Procedure**

- **Soft-tissue techniques**

Relaxing/therapeutic massage around the left side of the face in the direction of the contraction of the muscles. This procedure it was applied starting from the area of the forehead on the frontalis m., corrugator supercilii m., nasalis m., depressor septi m., procerus m., levator anguli oris m., risorius m., zygomaticus major, minor m., levator labii m., depressor labii inferior m., orbicularis oris m., buccinator m., mentalis m., depressor anguli oris m., orbicularis oculi m. and finishing on the area of the mouth and specifically on the chin.

Time: 5-7 minutes

- **Kenny method**

*Objective of today's therapeutic unit:* First it is instructed to the patient what kind of movements I would like that Mr. A. K. achieves. The application of Kenny method around the left side of the patient's face. Specifically, on the forehead, eyebrows, left side of the eye, around the eye, below the eye area, on all the parts of the left of the cheek, right near of the nose, upper lips, end of the lip and below the lower lip. The patient's position was in supine lying position with a comfortable pillow beneath his head. My position as a physiotherapist was above his face. The specific muscles in which this method was applied were:

- *Forehead:* Frontalis m
- *Eyebrows:* Frontalis m. Corrugator supercilii m., levator anguli oris m
- *Close of the eye:* Orbicularis oculi m
- *Cheek's area:* risorius, zygomaticus major, minor m. buccinator
- *Near to the nose area:* procerus m., nasalis m., levator anguli oris, depressor septi and transverse portion nasalis m
- *Lips area:* levator labii superioris m., depressor labii inferioris and platysma, orbicularis oris m., mentalis m., depressor anguli oris m

*Draft therapy:* The Kenny method is started with stretching of the part of the face that I would like to stimulate. Then after the stretching of this part, it's provided passive vibratory movement in the direction that the muscle in which Kenny method is applied, goes. After the passive movement, the patient is asked to try of provide the movement by saying to him, elevate your eyebrows and simultaneously me as a physiotherapist I am stimulating the frontalis m. in a cranial direction to help the patient providing this movement. All this process it was done for about 2 times in each part of the patient's face where Kenny method was applied.

As I mentioned, first it was applied on the forehead. Stretching of the frontalis m. in a caudal direction and then passive vibratory movement cranially. Then active movement with a passive stimulation by me in a cranial direction. In the same way it was applied in the rest of the forehead. Then it continues to the eyebrows, on the side of the left eye, around the eye, all the way around the cheeks, lips and mouth.

All this process works as a very good implementation to assist the patient on regaining his controlling of the affected muscles.

The time of the whole application on the left side of the patient's face lasted for about 10-15 minutes.

- **Electro stimulation**

The electrostimulation was applied in all the parts of the left side of the patient's face. Specifically, it was used the pen-like head of the electrostimulation machine that covers only one point of the muscle in which it is applied. The patient's position was in supine lying position. My position as a physiotherapist was above of the patient's face. Starting from the forehead towards the area below the lower lip. In each part of the forehead, the electrostimulation was applied on one point at the time waiting for 3 contractions in each separated point the area applied. The intensity of the electrostimulation was 5-10 mA, with length of impulse 20 ms and 3 sec of pause between the contraction. Duration of the whole application lasted for about 5 minutes.

The muscles that were stimulated and applied this therapy were frontalis, corrugator supercillii, nasalis, depressor septi, procerus, levator anguli oris, risorius, zygomaticus major, minor, levator labii, depressor labii inferior, orbicularis oris, buccinator, mentalis, depressor anguli oris, orbicularis oculi.

## **Results**

The patient had some improvements according to some facial expressions which now he is providing better with greater strength as well. Improvement is now 70%.

## **Self-therapy**

The self-therapy that I recommend to my patient is to perform some exercises which each of these exercises should be provided every day by 3 times, 1 time in the morning, 1 time in the midday and 1 time in the evening.

*Wednesday 12<sup>th</sup> of February 2014 Self therapy schedule No 8*

### **1<sup>st</sup> exercise**

Take a glass of water and try to drink using a straw but do not let your lips to let the water come out of the mouth. Try to use the muscles of the lips to keep the water in the mouth while drinking with the straw.

### **2<sup>nd</sup> exercise**

Stand in front of the mirror and try to open widely your eyes but without using your eyebrows muscles.

### **3<sup>rd</sup> exercise**

Stand in front of the mirror and try to elevate your eye brows for about 10-15 seconds each time, then pause and repeat again.

### **4<sup>th</sup> exercise**

Stretch the affected and the non-affected side using a spoon from the inner surface of the cheek.

### **5<sup>th</sup> exercise**

Stand in front of the mirror of the bathroom and grab a glass water and take a draught and start spitting the water like a “fountain” by keeping your lips tight.

***8<sup>th</sup> therapy***

---



**Today's present state**

- The patient's mood was still better and still with a better motivation. He respects his self-therapy now even more.
- Mr A. K. yesterday in the afternoon he visited his cardiologist and he applied on mr's A. K. chest a pulse meter for his heart for an examination of his heart.
- None pain.
- Still some ADL problems which are the drinking with straw, a little bit by drinking from the glass and chewing the food on the left side of the mouth.

**Today's therapy proposal**

- Hot rolls in all the affected parts of the patient's face
- Parafingo/ parafango in all the affected parts of the patient's face
- Active movements with semi-passive movements
- Soft-tissue massage
- Kenny method
- Electrostimulation
- Facial expressions exercises

**Goal of today's therapy**

- Stimulate the affected part of the patient's face
- Stretch the non-affected part of the patient's face
- Reinforce the weak areas of the patient's face
- Improve the state of the patient's face
- Improve the ADL of the patient

## **Procedure**

### **• Soft-tissue techniques**

Relaxing/therapeutic massage around the left side of the face in the direction of the contraction of the muscles. This procedure it was applied starting from the area of the forehead on the frontalis m., corrugator supercilii m., nasalis m., depressor septi m., procerus m., levator anguli oris m., risorius m., zygomaticus major, minor m., levator labii m., depressor labii inferior m., orbicularis oris m., buccinator m., mentalis m., depressor anguli oris m., orbicularis oculi m. and finishing on the area of the mouth and specifically on the chin.

Time: 5-7 minutes

### **• Kenny method**

*Objective of today's therapeutic unit:* First it is instructed to the patient what kind of movements I would like that Mr. A. K. achieves. The application of Kenny method around the left side of the patient's face. Specifically, on the forehead, eyebrows, left side of the eye, around the eye, below the eye area, on all the parts of the left of the cheek, right near of the nose, upper lips, end of the lip and below the lower lip. The patient's position was in supine lying position with a comfortable pillow beneath his head. My position as a physiotherapist was above his face.

The specific muscles in which this method was applied were:

- *Forehead:* Frontalis m
- *Eyebrows:* Frontalis m. Corrugator supercilii m., levator anguli oris m
- *Close of the eye:* Orbicularis oculi m
- *Cheek's area:* risorius, zygomaticus major, minor m. buccinator
- *Near to the nose area:* procerus m., nasalis m., levator anguli oris, depressor septi and transverse portion nasalis m
- *Lips area:* levator labii superioris m., depressor labii inferioris and platysma, orbicularis oris m., mentalis m., depressor anguli oris m

*Draft therapy:* The Kenny method is started with stretching of the part of the face that I would like to stimulate. Then after the stretching of this part, it's provided passive vibratory movement in the direction that the muscle in which Kenny method is applied, goes.

After the passive movement, the patient is asked to try of provide the movement by saying to him, elevate your eyebrows and simultaneously me as a physiotherapist I am stimulating the frontalis m. in a cranial direction to help the patient providing this movement. All this process it was done for about 2 times in each part of the patient's face where Kenny method was applied.

As I mentioned, first it was applied on the forehead. Stretching of the frontalis m. in a caudal direction and then passive vibratory movement cranially. Then active movement with a passive stimulation by me in a cranial direction. In the same way it was applied in the rest of the forehead. Then it continues to the eyebrows, on the side of the left eye, around the eye, all the way around the cheeks, lips and mouth.

All this process works as a very good implementation to assist the patient on regaining his controlling of the affected muscles.

The time of the whole application on the left side of the patient's face lasted for about 10-15 minutes.

- **Facial expressions training**

The patient was asked to provide the most frequent facial expressions for few times. Were provided the happy face, sad face, angry face, kiss, wondering face, express surprise.

The vocals also were provided to train most of the mouth muscles.

*These expressions were provided as well as by me and my supervisor to instructed and help the patient.*

*The electro stimulation won't be provided today due to the fact that Mr. A. K. has on his chest the cardio pulse meter for his heart for a day. It is an examination by his doctor. Tomorrow, his doctor will take it off.*

## **Results**

The patient had some improvements according to some facial expressions which now he is providing better with greater strength as well. Improvement is now 70%.

## **Self-therapy**

The self-therapy that I recommend to my patient is to perform some exercises which each of these exercises should be provided every day by 3 times, 1 time in the morning, 1 time in the midday and 1 time in the evening.

*Thursday 13<sup>th</sup> of February 2014 Self therapy schedule No 9*

### **1st exercise**

Stand in front of the mirror and start providing the main facial expressions. Expressions like smiling, sad face, angry face, send a kiss, bad smell-like face. Provide all these facial expressions slowly and while providing each movement motivate and focus on the muscle respectively, it will help the exercise to be more effective in the end.

### **2nd exercise**

Stand in front of the mirror and gently wink with just one eye trying avoiding other activations of other facial muscles. Repeat the same to the other side.

### **3rd exercise**

Grab a glass of water, a straw and start blowing air through the straw to the glass against the water. Notice to keep your lips tight not letting the air coming out from the straw. The air that is blowing from your mouth should pass through the straw and with that the lips muscles are exercising. Blow the air until the last blow and repeat it again.

### **4th exercise**

Stand in front of the mirror and using your thumb or index finger, start stretching the corner of your lips toward the mandible under the ear of the affected side.

### **5th exercise**

Stand in front of the mirror and gently wink with just one eye trying avoiding other activations of other facial muscles. Repeat the same to the other side.

*9<sup>th</sup> therapy*

---

**Today's present state**

- The patient's mood was still better and still with a better motivation. He respects his self-therapy now even more
- Mr A. K.'s cardiologist removed the pulse meter from the chest of my patient
- None pain
- Still some ADL problems which are the drinking with straw, a little bit by drinking from the glass and chewing the food on the left side of the mouth

**Today's therapy proposal**

- Hot rolls in all the affected parts of the patient's face
- Parafingo/ parafango in all the affected parts of the patient's face
- Active movements with semi-passive movements
- Soft-tissue massage
- Kenny method
- Electrostimulation
- Facial expressions exercises

**Goal of today's therapy**

- Final kinesiologic examination
- Stimulate the affected part of the patient's face
- Stretch the non-affected part of the patient's face
- Reinforce the weak areas of the patient's face
- Improve the state of the patient's face
- Improve the ADL of the patient

**Procedure**

- **Final kinesiologic examination**
  - i. Posture examination
  - ii. Muscle strength testing by Kendall
  - iii. Muscle length testing by Janda
  - iv. Facial expressions examination

- **Soft-tissue techniques**

Relaxing/therapeutic massage around the left side of the face in the direction of the contraction of the muscles. This procedure it was applied starting from the area of the forehead on the frontalis m., corrugator supercilii m., nasalis m., depressor septi m., procerus m., levator anguli oris m., risorius m., zygomaticus major, minor m., levator labii m., depressor labii inferior m., orbicularis oris m., buccinator m., mentalis m., depressor anguli oris m., orbicularis oculi m. and finishing on the area of the mouth and specifically on the chin

Time: 5-7 minutes

- **Kenny method**

*Objective of today's therapeutic unit:* First it is instructed to the patient what kind of movements I would like that Mr. A. K. achieves. The application of Kenny method around the left side of the patient's face. Specifically, on the forehead, eyebrows, left side of the eye, around the eye, below the eye area, on all the parts of the left of the cheek, right near of the nose, upper lips, end of the lip and below the lower lip. The patient's position was in supine lying position with a comfortable pillow beneath his head. My position as a physiotherapist was above his face.

The specific muscles in which this method was applied were:

- *Forehead:* Frontalis m
- *Eyebrows:* Frontalis m. Corrugator supercilii m., levator anguli oris m
- *Close of the eye:* Orbicularis oculi m
- *Cheek's area:* risorius, zygomaticus major, minor m. buccinator
- *Near to the nose area:* procerus m., nasalis m., levator anguli oris, depressor septi and transverse portion nasalis m
- *Lips area:* levator labii superioris m., depressor labii inferioris and platysma, orbicularis oris m., mentalis m., depressor anguli oris m

*Draft therapy:* The Kenny method is started with stretching of the part of the face that I would like to stimulate. Then after the stretching of this part, it's provided passive vibratory movement in the direction that the muscle in which Kenny method is applied, goes.

After the passive movement, the patient is asked to try of provide the movement by saying to him, elevate your eyebrows and simultaneously me as a physiotherapist I am stimulating the frontalis m. in a cranial direction to help the patient providing this movement. All this process it was done for about 2 times in each part of the patient's face where Kenny method was applied. As I mentioned, first it was applied on the forehead. Stretching of the frontalis m. in a caudal direction and then passive vibratory movement cranially. Then active movement with a passive stimulation by me in a cranial direction. In the same way it was applied in the rest of the forehead. Then it continues to the eyebrows, on the side of the left eye, around the eye, all the way around the cheeks, lips and mouth. All this process works as a very good implementation to assist the patient on regaining his controlling of the affected muscles.

The time of the whole application on the left side of the patient's face lasted for about 10-15 minutes.

- **Electro stimulation**

The electrostimulation was applied in all the parts of the left side of the patient's face. Specifically, it was used the pen-like head of the electrostimulation machine that covers only one point of the muscle in which it is applied. The patient's position was in supine lying position.

My position as a physiotherapist was above of the patient's face. Starting from the forehead towards the area below the lower lip. In each part of the forehead, the electrostimulation was applied on one point at the time waiting for 3 contractions in each separated point the area applied. The intensity of the electrostimulation was 5-10 mA, with length of impulse 20 ms and 3 sec of pause between the contraction. Duration of the whole application lasted for about 5 minutes.

The muscles that were stimulated and applied this therapy were frontalis, corrugator supercilii, nasalis, depressor septi, procerus, levator anguli oris, risorius, zygomaticus major, minor, levator labii, depressor labii inferior, orbicularis oris, buccinator, mentalis, depressor anguli oris, orbicularis oculi.

- **Facial expressions training**

The patient was asked to provide the most frequent facial expressions for few times. Were provided the happy face, sad face, angry face, kiss, wondering face, express surprise.

The vocals also were provided to train most of the mouth muscles.  
*These expressions were provided as well as by me and my supervisor to instructed and help the patient.*

### **Results**

The patient had some improvements according to some facial expressions which now he is providing better with greater strength as well. Improvement is now 70-75%.

### **Self-therapy**

The self-therapy that I recommend to my patient is to perform some exercises which each of these exercises should be provided every day by 3 times, 1 time in the morning, 1 time in the midday and 1 time in the evening.

*Friday 14<sup>th</sup> of February 2014 Self therapy schedule No 10*

#### **1st exercise**

Stand in front of the mirror and try to elevate your eye brows for about 10-15 seconds each time, then pause and repeat again.

#### **2nd exercise**

Stand in front of the mirror and try to close your eye of the affected side, slowly and gently but without letting your eyebrows decrease or your mouth pulled up.

#### **3rd exercise**

Stand in front of the mirror and start providing the main facial expressions. Expressions like smiling, sad face, angry face, send a kiss, bad smell-like face. Provide all these facial expressions slowly and while providing each movement motivate and focus on the muscle respectively, it will help the exercise to be more effective in the end.

#### **4th exercise**

Take a glass of water and try to drink using a straw but do not let your lips to let the water come out of the mouth. Try to use the muscles of the lips to keep the water in the mouth while drinking with the straw.



### 5th exercise

Stretch the affected and the non-affected side using a spoon from the inner surface of the cheek.

*10<sup>th</sup> therapy*

## **3.6. FINAL KINESIOLOGIC EXAMINATION**

### **3.6.1. Posture examination**

*Front side focused on his face*

- Eyes: left is less wide open comparing the initial examination.
- Cheeks: left side slightly lower than the right side
- Mouth: left side slightly lower, lips on the both sides are even more symmetrical
- Eyebrows: Aligned

### **3.6.2. Muscle strength testing by Kendall**

<b><u>Muscle tested – Inn. Facial Nerve</u></b>	<b><u>Left Side</u></b>	<b><u>Right Side</u></b>
<i>Frontalis</i>	<b>3+</b>	4
<i>Corrugator Supercilii</i>	<b>3+</b>	4-
<i>Nasalis</i>	<b>2+</b>	3
<i>Depressor septi</i>	<b>2+</b>	3-
<i>Procerus</i>	<b>3</b>	3
<i>Levator anguli oris</i>	<b>2+</b>	4-
<i>Risorius</i>	<b>3</b>	4+
<i>Zygomaticus Major</i>	<b>3-</b>	4-
<i>Zygomaticus Minor</i>	<b>3-</b>	4-
<i>Levator labii</i>	<b>2+</b>	4+
<i>Depressor labii inferior</i>	<b>2+</b>	4-
<i>Orbicularis oris</i>	<b>2-</b>	4+
<i>Buccinator</i>	<b>2</b>	3-
<i>Mentalis</i>	<b>2-</b>	3-
<i>Depressor anguli oris</i>	<b>2-</b>	3-
<i>Orbicularis oculi</i>	<b>3</b>	4+

Table No11 – Final kinesiologic examination

Muscle strength test

### 3.6.3. Muscle length testing by Janda

<u>Muscle tested</u>	<u>Left side</u>	<u>Right side</u>
<i>Levator Scapulae m.</i>	0	<b>0</b>
<i>Trapezius m. (Upper part)</i>	0	<b>0</b>
<i>Sternocleidomastoid m.</i>	0	<b>0</b>
<i>Scalene m.</i>	0	<b>0</b>

Table No12 - Final kinesiologic examination

#### Muscle length test

0 = No shortness

1 = Moderate shortness

2 = Marked shortness

### 3.6.4. Facial expressions test (compared on both sides)

- Happy face: Symmetrical
- Sad face: Symmetrical
- Fear expression: Slightly symmetrical
- Nasal opening: Slightly symmetrical
- Surprised face: Symmetrical
- Angered face: Symmetrical

### 3.7. Evaluation of the effect of the therapy

Checking the day by day results, there is a general improvement about 70-75%. The most improvement was found in the muscles: frontalis, procerus, nasalis, zygomaticus major/minor, depressor anguli oris, mentalis, buccinator and corrugator supercillii muscles according the strength test which were provided with some specific facial expressions and then passively was checked the strength. In these muscles there is about an 80% improvement comparing them with the initial examination. A 70% improvement I can tell there was in the aspect of the patient's face. The evaluation of this improvement was done by comparing the symmetry with the right side. Now the affected side has a closer look with the right side.

#### **4. CONCLUSION**

During my practice, my experience was very important not only for now to learn how to have a very important communication with the patient but also for my professional career.

Mr. A. K. told on my last day of practice that he is very happy for his results. My supervisor was also very kind and helped me a lot. She corrected me in every therapy session and that made me glad because I knew that I could learn something new and actually I learned a lot.

As a physiotherapist, I am satisfied with these results, because the patient mainly hasn't any problems with his ADL which in his life is the first thing that counts. The secondary and important results as well would be the aspect of the face of the patient and the perfection of his speech using his mouth muscles to provide clearly all the vocals etc.

Mr. A. K. after that the 10th therapy session was done, I performed to him the final kinesiologic examination to check the before and the after results. The most improvement was observed mainly in the face aspect and the strength of the patient's face. Specifically, in the strength test the most improvements were found in the frontalis, procerus, nasalis, zygomaticus major/minor, depressor anguli oris, mentalis and buccinator and corrugator supercilii. Also the rest of the other muscles had a very important improvement as well. Talking about the facial aspect of the patient, there isn't any comparison.

I remember the patient's face on the very first day that I examined him and I can tell that the improvements are very good. Also the patient told that he is able to eat, drink etc. (ADL) much easier than before. He confronted his before state according his ADL and he told me that he had some problems on eating and on drinking; he couldn't bring his lips on the glass. But now, he doesn't have any problems with that.

Now, the only thing that remains to treat 100% this patient is not only to provide all the movements with great strength but also to be symmetrical with the other side.

## **5. BIBLIOGRAPHY**

1. Drake, R. L., Vogl, A. W. & Mitchell, A. W. M. (2010). *Gray's anatomy for students*. (2<sup>nd</sup> ed.). Churchill Livingstone.
2. Finsterer, J. (2008, March). Management of peripheral facial nerve palsy. *National center for biotechnology information*. Retrieved March 15, 2014 from <http://www.ncbi.nlm.nih.gov>.
3. Garg, K. N., Gupta, K., Singh, S., & Chaudhary, S. (2012). Bell's palsy: Aetiology, Classification, Differential Diagnosis and Treatment Consideration: A Review. *Journal of dentofacial sciences*, 1(1), 8.
4. Gross, M. (n.d.). Multimodal expression in the face and body. *U-m school of kinesiology*. Retrieved 8 March, 2014 from <http://www.kines.umich.edu>.
5. Jain, V., Deshmukh, A. & Gollomp S. (2006, July). Bilateral Facial Paralysis Case Presentation and Discussion of Differential Diagnosis. *National center for biotechnology information*. Retrieved March 15, 2014 from <http://www.ncbi.nlm.nih.gov>
6. Jelinkova, I. *Basic Therapeutic Methods II: facial muscles, according to Kendall*. Prague, 2012. Lectures notes. Charles University in Prague.
7. Joynt, R. (2014, January). Bell palsy. *Encyclopedia britannica*. Retrieved March 15, 2014 from <http://www.britannica.com>.
8. Kendall, F. P., McCreary, E. K., & Provance, P. G. (1993). *Muscles testing and function with posture and pain* (4th ed.). Philadelphia: Lippincott Williams and Wilkins.

9. Kietzman, S. (2014, March). What Are Different Types of Palsy? *Wisegeek: clear answers for common questions*. Retrieved March 22, 2014 from <http://www.wisegeek.com>.
10. Kim, J., Lee, H. R., Jeong, J. H. & Lee, W. S. (2010, November). Features of Facial Asymmetry Following Incomplete Recovery from Facial Paralysis. *National center for biotechnology information*. Retrieved March 22, 2014 from <http://www.ncbi.nlm.nih.gov>.
11. Kosins, A. M., Hurvitz, K. A., Evans, G. E. & Wirth, G. A. (2007). Facial paralysis for the plastic surgeon. *National center for biotechnology information*. Retrieved March 15, 2014 from <http://www.ncbi.nlm.nih.gov>.
12. Lewit, K. (2010). *Manipulative therapy: musculoskeletal medicine*. Edinburgh: Churchill Livingstone/Elsevier.
13. May, M. & Schaitkin, B. (2000). *The facial nerve: May's second edition*. New York: Thieme.
14. Minovi, A., Vosschulte, R., Hofmann, E., Draf, W. & Bockmuhl U. (2004, November). Facial Nerve Neuroma: Surgical Concept and Functional Results. *National center for biotechnology information*. Retrieved March 15, 2014 from <http://www.ncbi.nlm.nih.gov>.
15. Nordqvist, C. (2009, May). What Is Herpes? What Is Genital Herpes? *Medical news today: the latest health news*. Retrieved March 20, 2014 from <http://www.medicalnewstoday.com>.
16. Nordqvist, C. (2011, December). What Is Chickenpox (Varicella)? What Causes Chickenpox? *Medical news today: the latest health news*. Retrieved March 14, 2014 from <http://www.medicalnewstoday.com>.

17. Oatis, Carol A. (2004). *Kinesiology: the mechanics and pathomechanics of human movement*. Philadelphia: Lippincott Williams & Wilkins.
18. Ronthal, M. (2013, August). Patient information: Bell's palsy (Beyond the Basics). *Evidence based clinical decision support at the point of care*. Retrieved March 15, 2014 from <http://www.uptodate.com>.
19. Stoppler, M. C. & Davis, C. P. (2012, March). Bell's Palsy Symptoms. *Medicinenet – Health and medical information produced by doctors*. Retrieved March 16, 2014 from <http://www.medicalnewstoday.com>.
20. Swartz, E. E., Floyd, R. T. & Cendoma, M. (2005, July). Cervical Spine Functional Anatomy and the Biomechanics of Injury Due to Compressive Loading. *National center for biotechnology information*. Retrieved March 8, 2014 from <http://www.ncbi.nlm.nih.gov>.
21. Taylor, D. (2013, November). Bell Palsy Treatment & Management. *Latest medical news, clinical trials, guidelines*. Retrieved March 21, 2014 from <http://www.medscape.com>.
22. Taylor, D. C. (2012, July). Facial nerve problems and Bell's palsy – medicinenet. *Medicinenet – Health and medical information produced by doctors* Retrieved March 8, 2014 from <http://www.medicinenet.com>.
23. Taylor, D. C. (2013, November). Bell Palsy Clinical Presentation. *Latest medical news, clinical trials, guidelines*. Retrieved March 21, 2014 from <http://www.medscape.com>.
24. Taylor, D. C. (2013, November). Bell Palsy. *Latest medical news, clinical trials, guidelines*. Retrieved March 22, 2014 from <http://emedicine.medscape.com>.

25. Teixeira, L. J., Valbuza, J. S. & Prado, G. F. (2008). Physical therapy for Bell's palsy (idiopathic facial paralysis). *National center for biotechnology information*. Retrieved March 22, 2014 from <http://www.ncbi.nlm.nih.gov>.
26. Terzopoulos, D. (1993, June) Analysis and synthesis of facial image sequences using physical and anatomical models. *Transactions on pattern analysis and machine intelligence vol. 15* Retrieved March 15, 2014.
27. Tiemstra, J. D. & Khatkhate, N. (2007, October). Bell's palsy: Diagnosis and Management. *American family physician*. Retrieved March 16, 2014 from <http://www.aafp.org/journals/afp.html>.
28. Tortora, G. J. & Derrickson B. H. (2011). *Principles of Anatomy and Physiology*. (12<sup>th</sup> ed.). New York: Wiley.

## **6. SUPPLEMENTS**

### **6.1. LIST OF TABLES**

**Table No 1:** Scalp muscles

**Table No 2:** Muscles of the mouth

**Table No 3:** Neck muscles

**Table No 4:** Orbit and eyebrows muscles

**Table No 5:** Masticatory muscles

**Table No 6:** Initial examination: Muscle tone examination

**Table No 7:** Initial kinesiologic examination: Muscle strength test

**Table No 8:** Initial kinesiologic examination: Muscle length testing

**Table No 9:** Initial kinesiologic examination: ROM evaluation

**Table No 10:** Initial examination: Neurological examination

**Table No 11:** Final kinesiologic examination: Muscle strength test

**Table No 12:** Final kinesiologic examination: Muscle length test

### **6.2. LIST OF FIGURES**

**Figure No 1:** Anterior view of the skull

**Figure No 2:** Lateral view of the skull

**Figure No 3:** Superior view of the skull

**Figure No 4:** Medial View of Sagittal section of the skull

**Figure No 5:** Posteroinferior view of the skull

**Figure No 6:** Inferior view of the skull

**Figure No 7:** Superior view of sphenoid bone in floor of cranium

**Figure No 8:** Anterior view showing the bones of the right orbit.

**Figure No 9:** Anterior view of sphenoid bone.

**Figure No 10:** Medial view of sagittal section

**Figure No 11:** Right lateral view of the mandible

**Figure No 13:** Right lateral view of the TMJ

**Figure No 13:** Slight movement at suture

**Figure No 14:** Coronal suture



**Figure No 16:** Anterior superficial and deep view of the face

**Figure No 17:** Right lateral superficial view of the face

**Figure No 18:** Posterior view of C1 and C2 (atlas and axis)

**Figure No 19** – Buccinator

**Figure No 20** – Corrugator supercilii

**Figure No 21** – Depressor anguli oris

**Figure No 22** – Depressor labii inferior and platysma

**Figure No 23** – Depressor septi

**Figure No 24** - Frontalis

**Figure No 25** – Levator anguli oris

**Figure No 26** – Levator labii

**Figure No 27** – Mentalis

**Figure No 28** - Nasalis

**Figure No 29** – Orbicularis oculi

**Figure No 30** – Orbicularis oris

**Figure No 31** – Procerus

**Figure No 32** - Risorius

**Figure No 33** – Zygomaticus major and minor

### **6.3. ABBREVIATIONS**

**ADL** = Activities of daily living

**TMJ** = Temporomandibular joint

**DNA** = Deoxyribonucleic Acid

**AIDS** = Acquired Immunodeficiency Syndrome

**No.** = Number

**ROM** = Range of motion/movement

**BMI** = Body mass index

**STFR** = Sagittal, transverse, frontal, rotation method.

**CT** = Computer Tomography

**MRI** =Magnetic resonance imaging

**EMG** = Electromyography

## 6.4. APPLICATION FOR ETHICS BOARD REVIEW



CHARLES UNIVERSITY IN PRAGUE  
FACULTY OF PHYSICAL EDUCATION AND SPORT  
Josef Martího 31, 162 52 Praha 6-Vešelavín  
tel. +420 2 2017 1111  
http://www.ftvs.cuni.cz/

### Application for Ethics Board Review

of the research project, doctoral research, master degree research, undergraduate research, involving human subjects

**Project title:** Case study of a patient with diagnosis Bell's palsy

**Nature of the research project:** Bachelor's Thesis

**Author** (chief investigator): Dominic Kalafatis

**Supervisor** (in case of student research): Mgr. Helena Vomackova


**Research project description** Case study of physiotherapy treatment of a patient with the diagnosis of Bell's palsy will be conducted under the expert supervision of an experienced physiotherapist Ústřední Vojenská Nemocnice

**Guaranteed safety to be judged by experts:** safety to be judged by experts: No invasive methods will be used

**Ethical aspects of the research:** Personal data obtained during the investigation will not be published, draft informed consent (enclosed)

**Informed consent** (attached)

Date: 11.2.2014

Author's signature: 

### Faculty of Physical Education and Sport, Charles University in Prague ETHICS BOARD REVIEW

**Ethics Board members:** Doc. MUDr. Staša Bartůňková, CSc.  
Prof. Ing. Václav Bunc, CSc.  
Prof. PhDr. Pavel Slepíčka, DrSc.  
Doc. MUDr. Jan Heller, CSc.

The Ethics Board at the Faculty of Physical Education and Sport, Charles University, approved the research project.

Approval number: ..... 084/2014 .....  
Date: ..... 17.2.2014 .....

The Ethics Board at the Faculty of Physical Education and Sport, Charles University, reviewed the submitted research project and **found no contradictions with valid principles**, regulations and international guidelines for biomedical research involving human subjects.

**The chief investigator of the project met the necessary requirements for receiving the Ethics Board approval.**

Official school stamp

  
Signature, REB Chairman

UNIVERZITA KARLOVA v Praze  
Fakulta tělesné výchovy a sportu  
Josef Martího 31, 162 52, Praha 6

## INFORMOVANÝ SOUHLAS

V souladu se Zákonem o péči o zdraví lidu (§ 23 odst. 2 zákona č.20/1966 Sb.) a Úmluvou o lidských právech a biomedicíně č. 96/2001, Vás žádám o souhlas k vyšetření a následné terapii. Dále Vás žádám o souhlas k nahlížení do Vaší dokumentace osobou získávající způsobilost k výkonu zdravotnického povolání v rámci

praktické výuky a s uveřejněním výsledků terapie v rámci bakalářské práce na FTVS UK. Osobní data v této studii nebudou uvedena.

Dnešního dne jsem byla odborným pracovníkem poučena o plánovaném vyšetření a následné terapii. Prohlašuji a svým dále uvedeným vlastnoručním podpisem potvrzuji,

že odborný pracovník, který mi poskytl poučení, mi osobně vysvětlil vše, co je obsahem tohoto písemného informovaného souhlasu, a měla jsem možnost klást mu

otázky, na které mi řádně odpověděl.

Prohlašuji, že jsem shora uvedenému poučení plně porozuměla a výslovně souhlasím

s provedením vyšetření a následnou terapií.

Souhlasím s nahlížením níže jmenované osoby do mé dokumentace a s uveřejněním

výsledků terapie v rámci studie.

Datum:.....

Osoba, která provedla poučení:.....

Podpis osoby, která provedla poučení:.....

Vlastnoruční podpis pacienta /tky:.....