

CHARLES UNIVERSITY
FACULTY OF PHYSICAL EDUCATION AND SPORT
DEPARTMENT OF PHYSIOTHERAPY

**Case Study of Physiotherapy: Treatment of a patient after
Arthroscopic Bankart Repair
Bachelor Thesis**

Supervisor:

Mgr. Michaela Stupková

Author:

**Désirée Ginger
Bertron-Simpson**

Prague, May 2020

Declaration

I declare that this thesis has been written by myself, based on the clinical work placement. The writing was done according to the theoretical and practical knowledge that I have gained during my studies at the Faculty of Sport and Physical Education in Charles University, Prague. The additional theoretical knowledge learned whilst writing this dissertation is referenced at the end of the thesis.

I declare that no invasive methods were used during the clinical work placement in Centrum Léčby Pohybového Aparátu and the patient was fully aware of all procedures.

Prague, May 2020

**Désirée Ginger
Bertron-Simpson**

Acknowledgments

I am deeply grateful towards my parents that have always supported me under any circumstances. Thank you for providing me this opportunity to study in Prague and for all your help achieving those years.

I would like to express my appreciation towards my supervisor Mgr. Michaela Stupková for guiding me during the writing of this bachelor thesis and these years of teaching and patience. Deepest gratitude also goes to my practice supervisor in C.L.P.A, Mgr. Martina Damborová. Thank you for your enthusiasm, understanding and your trust. Also, I would like to thank all our teachers during these three years, for sharing their knowledge and their help.

Finally, many thanks to all my classmates and friends for your support and for making this time in Prague very so unique.

Abstract

Author: Désirée Ginger Bertron-Simpson

Title: Case Study of Physiotherapy: Treatment of a patient after Arthroscopic Bankart Repair.

Objectives: This thesis is divided in two general parts. The first one consists of overiewing the shoulder anatomy, kinesiology, and biomechanics. The patient's diagnosis is also presented, including the underwent surgery. The second part presents the case study, with respective examinations provided, treatments and results after providing all the therapies.

Clinical findings: The patient is a 16 years old female rugby athlete, 5 weeks after undergoing an Arthroscopic Bankart repair, performed on the 18th of December 2019 on her right shoulder. Her range of motion is limited in all directions with slight muscle atrophy around her right deltoid area, movement pattern in abduction is altered, constant hypertonicity on the upper trapezius area, bilaterally.

Methods: All examination and treatment are based of the knowledge I have acquired in the Faculty of Sport and Physical Education of Charles University, in Prague. These include postural examination, ARoM and PRoM, muscle length and strength test, PIR, joint mobilization, soft tissue techniques, and physical activity programs adapted the patient's need. The goals of the therapies are to control existing range of motion and regain muscle strength, to prevent further shoulder instability.

Results: The patient underwent seven therapies, where significant improvement on scapular stabilizers were noticed and abduction pattern. The range of motion also improved. The recurrent hypertonicity did not significantly improve.

Conclusion: The therapies were effective, except the attempts of relaxation of the upper trapezius. This negative finding leads to the hypothesis of requiring more physiotherapy sessions working on the global picture of the patient.

Keywords: Bankart lesion, Hill-Sachs lesion, Arthroscopic Bankart repair, glenohumeral joint, dislocation.

Abstrakt

Název: Kazuistika fyzioterapeutické péče o pacienta po Bankartově operaci.

Cíle: Tato práce je rozdělena do dvou obecných částí. První sestává z přehledu anatomie ramene, kineziologie a biomechaniky. Je také uvedena diagnóza pacienta, včetně podstoupeného chirurgického zákroku. Druhá část představuje případovou studii s příslušnými vyšetřeními, léčbami a výsledky po poskytnutí všech terapií.

Klinické nálezy: Pacientka je 16 letá ragbyová atletka, 5 týdnů po provedení artroskopické opravy Bankartu, provedená 18. prosince 2019 na jejím pravém rameni. Její rozsah pohybu je omezen ve všech směrech s mírnou svalovou atrofií kolem její pravé deltoidní oblasti, pohybový vzorec v abdukci je změněn, konstantní hypertonicita v horní oblasti trapézového svalu, bilaterálně.

Metody: Všechny vyšetření a léčba jsou založeny na znalostech, které jsem získal na Fakultě sportu a tělesné výchovy Univerzity Karlovy v Praze. Patří mezi ně posturální vyšetření, ARoM a PRoM, zkouška délky a síly svalů, PIR, mobilizace kloubů, techniky měkkých tkání a programy fyzické aktivity přizpůsobené potřebám pacienta. Cílem terapií je kontrolovat existující rozsah pohybu a znovu získat sílu svalů, aby se zabránilo další nestabilitě ramene.

Výsledky: Pacient podstoupil sedm terapií, kde bylo zaznamenáno výrazné zlepšení lopatkových stabilizátorů a způsobu abdukce. Rozsah pohybu se také zlepšil. Opakující se hypertonicita se významně nezlepšila.

Závěr: Terapie byla účinná, kromě pokusů o relaxaci horního trapézového svalu. Toto negativní zjištění vede k hypotéze vyžadující více fyzioterapeutických sezení pracujících na globálním obrazu pacienta.

Klíčová slova: Bankartova léze, Hill-Sachsova léze, artroskopická Bankartova oprava, glenohumerální kloub, dislokace.

Table of content

1. Introduction.....	9
2. Theoretical Part.....	10
2.1 Anatomy.....	10
2.1.1 Bone Structure.....	10
2.1.1.1 Clavicula.....	10
2.1.1.2 Scapula	10
2.1.1.3 Humerus	13
2.1.2 Joints	14
2.1.2.1 Sternoclavicular joint.....	14
2.1.2.2 Acromioclavicular joint.....	14
2.1.2.3 Glenohumeral joint.....	15
2.1.3 Muscles	17
2.1.4. Brachial Plexus.....	21
2.1.4.1 Musculocutaneous nerve	22
2.1.4.2 Axillary nerve	22
2.1.4.3 Median nerve	22
2.1.4.4 Radial nerve.....	23
2.1.4.5 Ulnar nerve	23
2.2 Kinesiology of the shoulder	26
2.2.1 Shoulder active range of motion and its mechanism	26
2.2.1.1 Movements of scapula	29
2.2.1.2 Scapulohumeral rhythm.....	30
2.2.2 Biomechanics of the shoulder	31
2.2.2.1 Loads on the shoulder.....	33
2.2.2.2 Force Couples.....	34
2.3 Rugby tackle – biomechanics and kinesiology	35
2.4 Shoulder instability – Anterior dislocation	37
2.4.1 Bankart lesion.....	38
2.4.1.1 Epidemiology	39
2.4.1.2 Etiology	39
2.4.2 Hill-Sachs lesion	40
2.4.2.1 Epidemiology, relation between Bankart and Hill-Sachs lesions	40

2.4.3 Diagnostic procedures	41
2.4.4 Treatment	42
2.4.4.1 Conservative treatment according to Kolář (18)	42
2.4.4.2 Arthroscopic Bankart repair	43
2.4.4.3 Clinical picture post-surgery	44
2.4.4.4 Post-surgery physiotherapy	45
3. Case study	46
3.1 Methodology	46
3.2 Anamnesis	47
3.2.1 Status present.....	47
3.2.2 History Anamnesis	47
3.2.3 Injury Anamnesis:	48
3.2.4 Surgery anamnesis:.....	48
3.2.5 Medical anamnesis:	48
3.2.6 Family anamnesis:	48
3.2.7 Social anamnesis:	48
3.2.8 Occupational anamnesis:	48
3.2.9 Allergy anamnesis:	48
3.2.10 Pharmacological anamnesis:	48
3.2.11 Hobbies:.....	48
3.2.12 Abuses:	49
3.2.13 Prior rehabilitation:.....	49
3.2.14 Excerpt from patient's health file:	49
3.2.15 RHB indications:	49
3.3 Kinesiological Examination	50
3.3.1 Static Postural examination	50
3.3.2 Dynamic Spine examination.....	51
3.3.3 Passive and active range of motion	51
3.3.4 Active ROM against resistance:	52
3.3.5 Movement pattern according to Janda.....	52
3.3.6 Gait Examination.....	52
3.3.7 Palpation	53
3.3.8 Pelvis Examination.....	54

3.3.9 Length test according to Janda and Kendall.....	54
3.3.10 Strength test according to Kendall:	55
3.3.11 Fascia examination by Lewit.....	56
3.3.12 Joint play examination.....	56
3.3.13 Anthropometrics upper extremity.....	57
3.3.14 Breathing stereotype	57
3.3.15 Two scale test	57
3.3.16 Neurological Examination.....	58
3.3.17 Conclusion.....	59
3.4 Short-term rehabilitation plan	60
3.5 Long-term rehabilitation plan	60
3.6 Day to day therapies.....	60
3.6.1 First therapeutic unit (20.01.2020)	60
3.6.2 Second therapeutic unit (22.01.2020) – 5 weeks after surgery	61
3.6.3 Third therapeutic unit (24.01.2020).....	64
3.6.4 Fourth therapeutic unit (27.01.2020).....	68
3.6.5. Fifth therapeutic unit (29.01.2020) – 6 weeks after surgery	71
3.6.6 Sixth therapeutic unit (31.01.2020)	73
3.6.7 Seventh therapeutic unit (03.02.2020).....	75
3.7 Final kinesiological examination	77
3.7.1 Static Postural examination	77
3.7.2 Dynamic Spine examination.....	77
3.7.3 Passive and Active Range of Motion	78
3.7.4 Active RoM against resistance	78
3.7.5 Movement pattern according to Janda.....	79
3.7.6 Gait Examination.....	79
3.7.7 Palpation	80
3.7.8 Pelvis Examination.....	81
3.7.9 Length test according to Janda and Kendall.....	81
3.7.10 Strength test according to Kendall:	82
3.7.11 Fascia examination by Lewit.....	83
3.7.12 Joint play examination.....	83
3.7.13 Anthropometrics upper extremity.....	84

3.7.14 Breathing stereotype	84
3.7.15 Two scale test	84
3.7.16 Neurological Examination.....	85
3.7.17 All-four positioning:	85
3.7.18 Conclusion of final kinesiological examination:	86
3.8 Evaluation of effectiveness of therapy	87
4. Conclusion	91
5. Bibliography	92
6. Supplements.....	95
6.1 Abbreviations	95
6.2 List of figures	96
6.3 List of tables.....	96
6.4 Ethics Committee Agreement	98
6.5 Informed consent.....	99

1. Introduction

The clinical work placement took place at Centrum léčby pohybového aparátu (C.L.P.A), started on Monday 13th of January 2020 and ended on Friday 7th of February 2020 with a total of 80 hours.

I was assigned a 16 years old female rugby athlete, who underwent an arthroscopic Bankart surgery because of repetitive anterior shoulder dislocations. I chose this diagnosis because of my high interest in rugby and the remarkable frequency of shoulder injuries in rugby players. Also, working with athletes in the future is part of my interest in this patient.

The first part of the thesis contains the theoretical part of the shoulder, including anatomy, kinesiology, and biomechanics. Mechanism of injury are presented, especially under a rugby point of view. Moreover, the process of such surgery is explained. The second part is practical, transcript of the examinations and daily therapies applied to the patient in C.L.P.A. during the work placement. All therapeutic procedures and exercising are explained.

2. Theoretical Part

2.1 Anatomy

2.1.1 Bone Structure

2.1.1.1 Clavicula

The clavicle is an “S” shaped bone, also known as collar bone, taking part of the pectoral girdle. It extends from the acromion of scapula to the manubrium of sternum. The collar bone is part of the sternoclavicular joint and acromioclavicular joint, which will be presented below with its respective ligaments. (12;29)

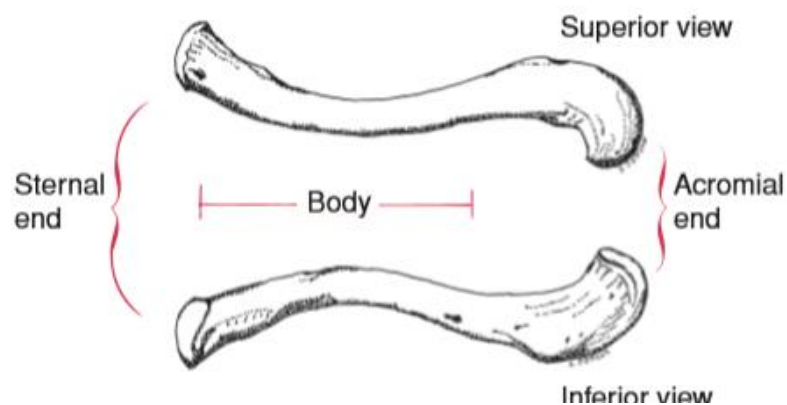


Figure 1: Superior and Inferior view of the clavicle (20)

2.1.1.2 Scapula

The scapula is a remarkable bone, as it serves at insertion of several muscles. It is a flat bone, in a triangle shape also named shoulder blade. We find a connection with the humerus with the glenohumeral joint and with the acromion with the acromioclavicular joint, it is the connection of the upper limb to the trunk. The scapulothoracic “joint” is a term to describe the motion of the scapula over the rib cage, even though there is no static point. The following table resumes bony landmarks under each surface and respective characteristic. (12;29)

<i>Surfaces</i>	<i>Bony landmarks and characteristics</i>
Anterior surface	Subscapular fossa: <ul style="list-style-type: none"> - Origin of subscapularis muscle.
	Coracoid process: <ul style="list-style-type: none"> - Pectoralis minor attachment. - Origin of the coracobrachialis and short head of biceps brachii.
Medial surface	Defined in between angulus superior and inferior, both anatomical landmarks for orientation upon palpation. Superior angle at Th1 and inferior Th7.
Lateral surface	Glenoid fossa: <ul style="list-style-type: none"> - Articulates with head of humerus, forming the glenohumeral joint.
	Supraglenoid tubercle: <ul style="list-style-type: none"> - Long head of biceps brachii attachment.
	Infraglenoid tubercle: <ul style="list-style-type: none"> - Long head of triceps brachii attachment.
Posterior surface	Spina scapulae: <ul style="list-style-type: none"> - Most prominent landmark on posterior surface. - Divides the surface in two.
	Acromion: <ul style="list-style-type: none"> - Forms acromioclavicular joint with the clavicle.
	Supraspinatus fossa: <ul style="list-style-type: none"> - Origin of supraspinatus muscle.
	Infraspinatus fossa: <ul style="list-style-type: none"> - Origin of infraspinatus muscle.

Table 1: Scapula's anatomical landmarks.

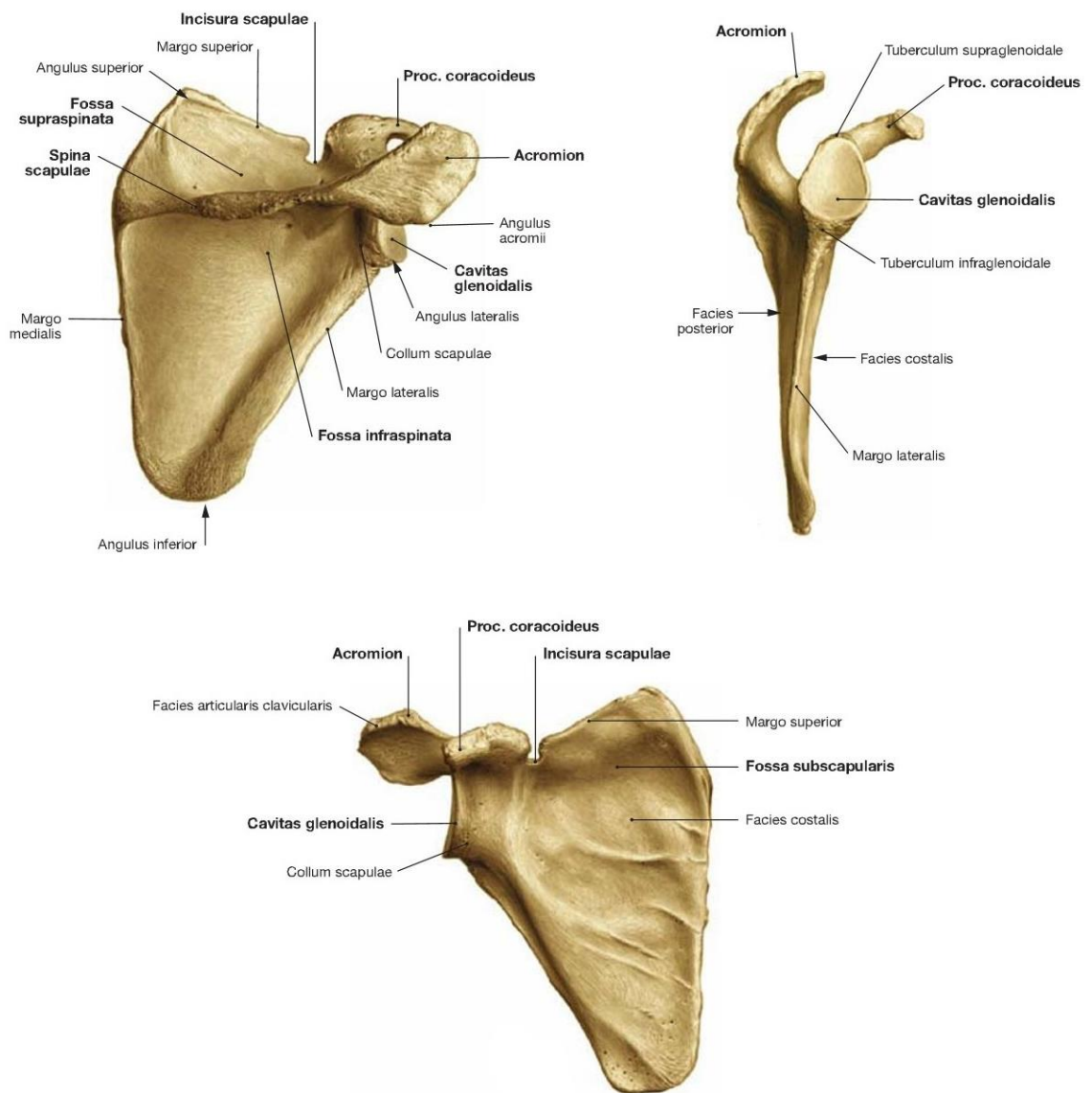


Figure 2: The scapula and anatomical landmarks; posterior, lateral and anterior view.
(29)

2.1.1.3 Humerus

The humerus is a long bone that connects the lower arm (elbow, wrist and hand) to the shoulder. Proximally, in junction with the glenoid cavity of the scapula, it forms the glenohumeral joint. Distally, the humerus forms the elbow joint in junction with the radius and ulna. (12;29)

The proximal part of this bone is named head of humerus, followed by the anatomical neck and two tubercles (greater and lesser) separated by the intertubercular sulcus where the tendon of the long head of biceps brachii runs through. Below those, we find the surgical neck, a frequent site of fracture. (12;29)

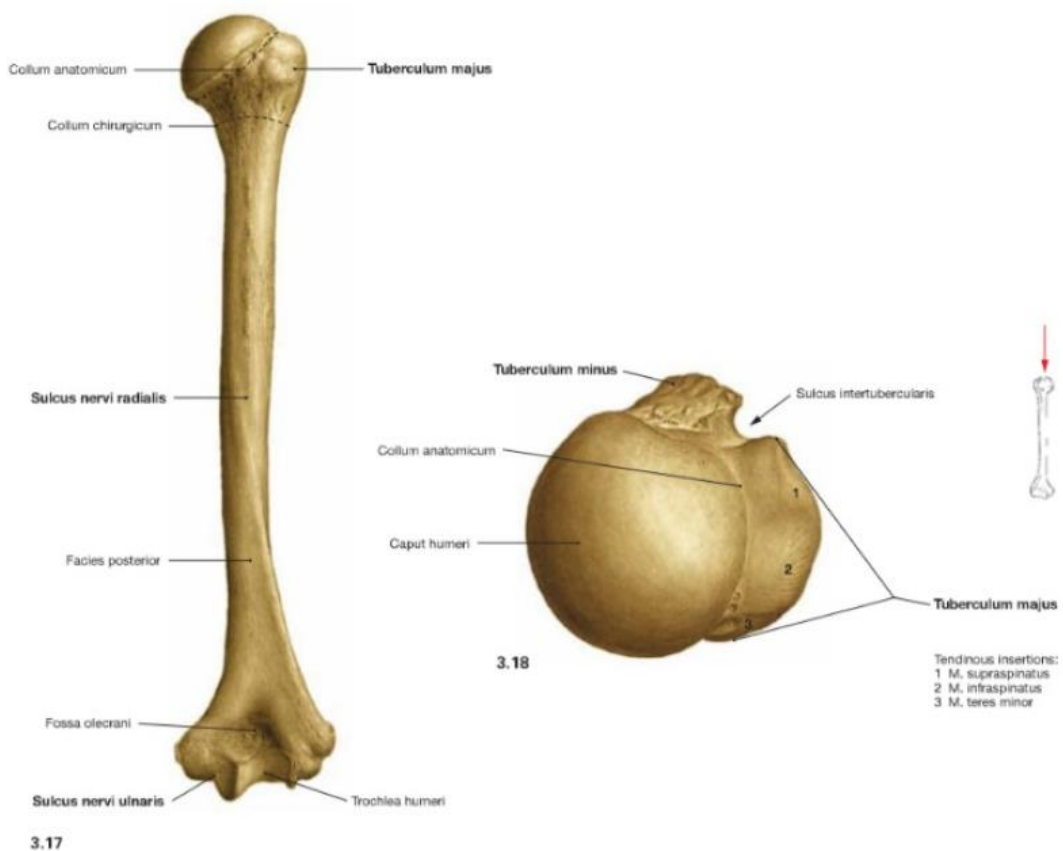


Figure 3: Anterior view of humeral bone and superior view of the humeral head (34)

2.1.2 Joints

The shoulder complex consists of three real joints, the sternoclavicular, acromioclavicular and biggest glenohumeral joint. We also consider two false joints: the scapulothoracic and subdeltoid joint. The following section will present each of the real joints, we will reserve the false joints in the kinesiological section, explained further on. (20)

2.1.2.1 Sternoclavicular joint

The sternal end forms in junction with the sternum the so called sternoclavicular joint. It is a complex joint in ball-and-socket shape that allows limited movements. The clavicle is capable of 45 degrees rotation around its fixed sternal end. (12;20)

2.1.2.2 Acromioclavicular joint

The acromial end forms in junction with the acromion the so called acromioclavicular joint. It is a plane synovial articulation. The articular ends are covered with fibrocartilage and separated by an articular disk. The joint is quite weak but is reinforced by the insertion of upper trapezius fibers. (12;29)

The acromioclavicular ligament goes from the acromion to clavicle and strengthens such joint superiorly (Cf. Figure 4). However, an other ligament is present which prevent the acromion to “slip” under the clavicle; the coracoclavicular ligament, divided into the conoid and trapezoid ligaments. (12;29)

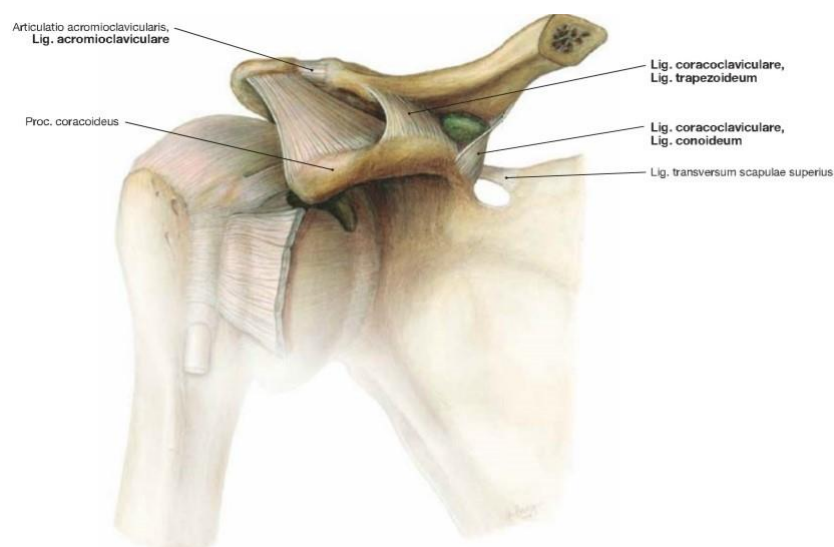


Figure 4: The acromioclavicular and coracoclavicular ligaments (29)

2.1.2.3 Glenohumeral joint

The shoulder joint is a ball and socket joint where the head of humerus articulates with the glenoid fossa of the scapula. It is the most mobile joint on the body. Due to its high mobility, it has a complex mechanism of muscle balance and ligaments to keep the stability of the joint. Also, this mobility makes the glenohumeral joint very prone to injuries due to instability. (20;29)

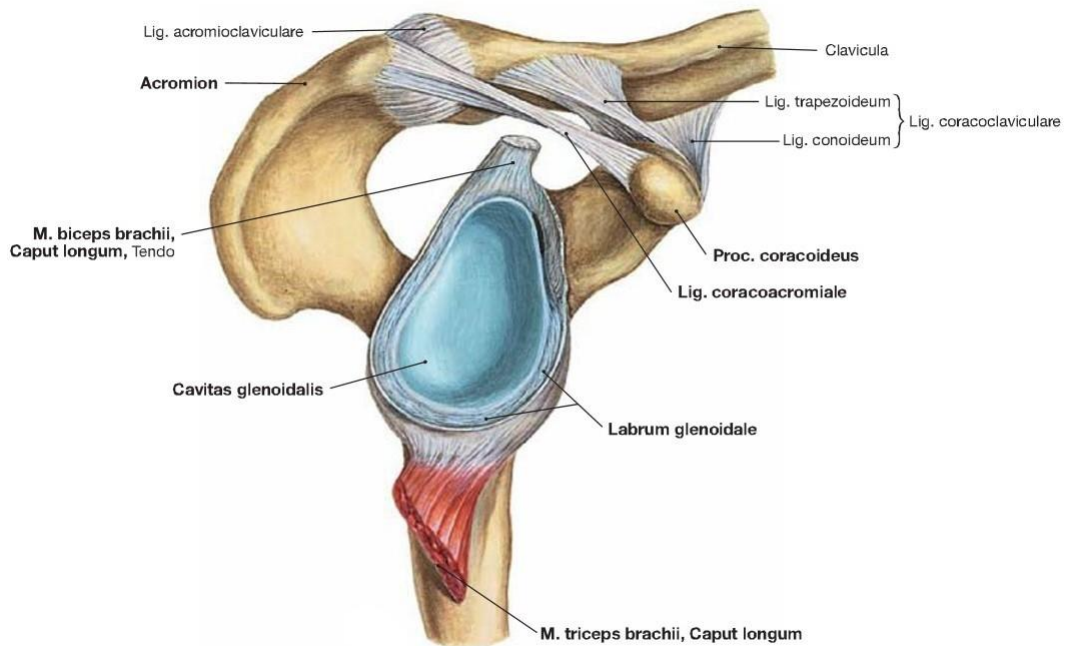


Figure 5: The shoulder joint according to Sobotta (29)

On the glenoid cavity, there is the so called glenoid labrum. This is a fibrocartilaginous structure that deepens the socket of the joint and extends the articular surface of the GH joint. Without the labrum, the glenoid cavity covers only a third of the humerus head. In other words, the glenoid labrum is the “socket” of the joint. However, the labrum itself has no major influence on the joint’s stability without the surrounding ligaments and tendons, except the deepening of the socket which automatically creates a seal to the head of humerus. (14;20;29)

The synovial joint capsule creates the shape of the shoulder joint. It attaches medially to the glenoid labrum and laterally to the anatomical neck of the humerus. There is a synovial membrane, producing synovial fluid, lining the inner joint capsule to prevent damaging friction between the scapula and head of humerus. Some synovial bursae are also present out of the articular capsule, to decrease friction between articular surfaces.

The subdeltoid bursa, located under the deltoid, the subacromial bursa under the acromion and the subtendinous bursa of subscapularis. These are the main bursae subject to common shoulder pathologies such as subacromial bursitis. (14;29)

As mentioned previously, the joint capsule is reinforced by ligaments and tendons, major components of the glenohumeral joint's stability.

The following table presents the present ligaments with their respective characteristics.

<i>Ligaments</i>	<i>Characteristics</i>
Glenohumeral ligaments	<ul style="list-style-type: none"> - Superior Glenohumeral - Middle Glenohumeral - Inferior Glenohumeral <p>All three ligaments run through the layers of the articular capsule.</p>
Coracohumeral	Runs through the coracoid process of the scapula to the greater tubercle of humerus.
Transverse Humeral	Goes between tuberculus major and minor of the humerus, covering the tendon of long head of biceps to maintain it in place.

Table 2: Glenohumeral ligaments and characteristics

Concerning the muscle tendons, there is a group of four muscles called “rotator cuff”, which all inserts on the greater and lesser tubercles of humerus, bringing stability to the glenohumeral joint and aiding in its rotation. (14) These are:

- Supraspinatus: inserts on the superior facet of greater tubercle.
- Infraspinatus: inserts on the middle facet of greater tubercle, posteriorly.
- Teres minor: inserts on the inferior facet of greater tubercle, posteroinferior.
- Subscapularis: inserts on lesser tubercle, ventrally.

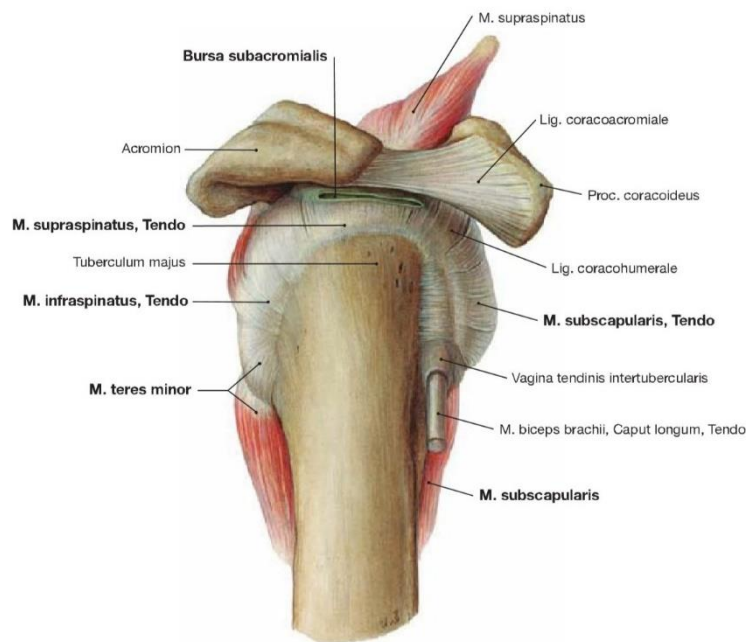


Figure 6: Rotator cuff muscles insertion according to Sobotta (29)

2.1.3 Muscles

As explained previously, the shoulder is the most mobile joint in the body, making it prone to injury when the complex mechanism of muscle forces, ligament constraints and bony articulations is not balanced. Other joints, like the elbow, are passively stabilized through the articular surfaces and joint capsule. It is not the case of the shoulder, where a complex mechanism between articular surfaces, ligaments and muscle forces must synergistically work together to reach optimal functionality. Thereby, we can refer the muscles as the dynamic stabilizers of the shoulder joint, they are active forces that provides a functional balance between mobility and stability. (10;25)

We will divide the shoulder muscles into three categories: the intrinsic and extrinsic group and the “secondary movers”. The intrinsic consists of muscles originating from the scapula and/or clavicle and inserting on the humerus. The extrinsic group are the muscles originating from the thorax and inserting on the shoulder complex, they tend to be more superficial and larger. The “secondary movers” are muscles that are part of pectoral region and upper arm but has a direct effect of the shoulder complex.

<i>Muscle</i>	<i>Origin</i>	<i>Insertion</i>	<i>Function</i>	<i>Innervation</i>
Supraspinatus	Supraspinatous fossa of scapula	Greater tubercle of humerus	Abduction	Suprascapular nerve
Infraspinatus	Infraspinatous fossa of scapula	Greater tubercle of humerus	External rotation	Suprascapular nerve
Subscapularis	Subscapularis fossa of scapula	Minor tubercle of humerus	Internal rotation	Subscapular nerve
Teres minor	Lateral margin of scapula	Greater tubercle of humerus	External rotation, weak adduction	Axillary nerve
Teres major	Inferior angle of scapula	Crest of lesser tubercle (humerus)	Internal rotation, adduction, extension	Subscapular nerve
Deltoid	Pars clavicularis	Deltoid tuberosity	Flexion, internal rotation, adduction	Axillary nerve
	Pars acromialis		Abduction	
	Pars spinalis		Extension, external rotation, adduction	

Table 3: Intrinsic muscle group of the shoulder

<i>Muscle</i>	<i>Origin</i>		<i>Insertion</i>	<i>Function</i>	<i>Innervation</i>
Trapezius	Pars ascendens (lower)	Th5 – Th12 spinous proc.	Spina scapulae	Draws scapula medially downwards	Accessory nerve and Cervical plexus C3-C4
	Pars transversa (middle)	Th1 – Th4 spinous proc.	Acromion	Draws scapula medially	
	Pars descendens (upper)	External occipital protuberance and C1- C7 spinous proc.	Clavicula (lateral one third)	Draws scapula obliquely upwards	
				Entire muscle steadies scapula on the thorax	
Latissimus Dorsi	Pars vertebralis	Spinous proc. Th7-Th12; thoracolumbar fascia	Intertubercular sulcus of humerus	Internal rotation, adduction, extension	Thoracodorsal nerve (C6-C8)
	Pars scapularis	Inferior angle of scapula			
	Pars costalis	Costa 9-12			
	Pars iliaca	Posterior one third of iliac crest			
Levator Scapulae	Transverse proc. C1-C4		Superior angle of scapula	Draws scapula medially upwards, move angulus inferior medially; ipsilateral inclination of the neck	Dorsal scapular nerve (C4-C5)
Rhomboid major	Spinous proc. Th1-Th4		Margo medialis below spina scapulae	Steadies scapula; draws scapula medially upwards	Dorsal scapular nerve (C4-C5)
Rhomboid minor	Spinous proc. C6-C7		Margo medialis above spina scapulae		Dorsal scapular nerve (C4-C5)

Table 4: Extrinsic muscle group of the shoulder

<i>Muscle</i>	<i>Origin</i>		<i>Insertion</i>	<i>Function</i>	<i>Innervation</i>
Pectoralis major	Pars clavicularis	Medial half of clavicle	Humerus, crest of greater tubercle	Adduction, internal rotation	Medial and lateral pectoral nerves (C5-T1)
	Pars sternocostalis	Sternum 1 st and 6 th rib's cartilage			
Pectoralis minor	Ribs: 3 rd to 5 th		Coracoid process	Draws scapula downward	Medial pectoral nerve (C8-Th1)
Serratus Anterior	Pars superior	Ribs: 1 st to 9 th	Medial margin of scapula	Draws scapula laterally forwards, lateral rotation of scapula	Long thoracic nerve (C5-C7)
	Pars intermedius				
	Pars inferior				
Subclavius	1 st rib		Inferior surface of clavicle	Steadies clavicle in sternoclavicular joint	Subclavius nerve (C5-C6)
Biceps brachii	Long head	Supraglenoid tubercle	Radial tuberosity	Flexion; stabilization of humeral head during deltoid contraction, internal rotation of humerus	Musculocutaneous nerve (C5-C6)
	Short head	Coracoid process			
Coracobrachialis	Coracoid process		Scapula, anteromedial	Flx, Add, Internal rotation	Musculocutaneous nerve (C5-C7)

Triceps brachii	Long head	Infraglenoid tubercle	Olecranon of the ulna	Extension and adduction	Radial nerve (C6-C8)
	Medial head	Humerus, inferior to radial groove			
	Lateral head	Superior to radial groove			
SCM*	Sternal head	Manubrium of sternum	Mastoid process and superior linea nuchae	Tilts head ipsilaterally, contralateral rotation	Accessory nerve
	Clavicular head	Medial one third of clavicle			

*The sternocleidomastoid is considered as a cervical muscle; however, it has a considerable influence on the shoulder complex if irritated.

Table 5: "Secondary movers" group of the shoulder

2.1.4. Brachial Plexus

The brachial plexus is of vital importance in physiotherapy. It innervates most of all the upper extremity muscles and is responsible for muscular and cutaneous innervation. To understand the configuration of the brachial plexus, we can divide the brachial plexus into five parts: (29)

- The roots originate from C5 to T1 ventral rami.
- Three trunks derive from these roots, named according to their localization: superior, middle, and inferior trunk. These converge into:
- Three anterior and three posterior divisions which all leads into again, three different cords, named among their localization:
- Lateral and medial cords, derived from the anterior division converging together, and the posterior cord which is the result of the three previous posterior divisions.
- Finally, we reach the five terminal branches, which each of their function will be explained in the next section. These are the musculocutaneous, axillary, radial, median, and ulnar nerves.

2.1.4.1 Musculocutaneous nerve

Nerve root: C5-C7

Motor: innervation of the muscles located in the anterior compartment of the arm; the biceps brachii, brachialis and coracobrachialis.

Sensory branches: Cutaneous antebrachia lateralis nerve

Clinical picture: an injury in this nerve results as poor supination, weakened elbow flexion and paresthesia on the lateral aspect of the forearm. The injuries are rare but includes dislocations.

2.1.4.2 Axillary nerve

Nerve root: C5-C6

Motor: innervation of deltoid muscle and teres minor.

Sensory branch: Nerve cutaneous brachii lateralis superior

Clinical picture: The axillary nerve tends to get damaged with a fracture of the surgical neck of humerus or shoulder dislocation, being the most common mechanism of injury. Damage of this nerve results in the inability of abducting the arm, possibly followed by an atrophy of corresponding area. Loss of sensation around the shoulder (Cf. figure 8 and 9) in respective cutaneous innervation.

2.1.4.3 Median nerve

Nerve root: C6-T1

Motor: Pronator teres, flexor carpi radialis, palmaris longus, flexor digitorum superficiales, pronator quadratus, flexor pollicis longus, flexor digitorum profundus (radial half), abductor pollicis brevis, flexor pollicis brevis (superficial head), opponens pollicis and lumbricales I,II muscles.

Sensory branches: the cutaneous distribution of the median nerve goes through the palmar surface of the hand, from the thumb to partial 4th digit. (Cf. figure 8 and 9)

Clinical picture: Fracture or dislocation of the elbow joint prone the median nerve to get damaged, resulting in the inability to grasp and sensory loss of the fingertips. Carpal Tunnel Syndrome is another diagnosis compromising the median nerve.

2.1.4.4 Radial nerve

Nerve root: C5-T1

Motor: Brachialis (partial), triceps brachii, anconeus, brachioradialis, extensor carpi radialis longus and brevis.

Sensory branches: Cutaneous brachii posterior, lateralis inferior and cutaneous antebrachii posterior. Superficial branches innervate the dorsum of the wrist and hand, from the thumb to the 3rd finger (Cf. figure 8 and 9).

Injury: the most common injury is due to chronic compression in the axilla, in the improper use of crutches, for example. This will cause loss in motor function in the hand, forearm and posterior arm. The commonly described characteristic of a radial nerve injury is “wrist-drop”.

2.1.4.5 Ulnar nerve

Nerve root: C7-T1

Motor function: flexor carpi ulnaris, flexor digitorum profundus, palmaris brevis, abductor digiti minimi, flexor digiti minimi brevis, opponens digiti minimi, lumbricales muscles III and IV, palmaris and interosseus dorsalis, adductor pollicis and flexor pollicis bevis (profound head) muscle.

Sensory branches: the cutaneous distribution of the ulnar nerve goes on the dorsal and palmar aspect of the hand, from the 5th and 4th digit, partially on the 3rd also. (Cf. figure 8 and 9)

Clinical picture: Paresis of ulnar nerve is the most common peripheral nerve damage. It is mostly due to compression or trauma in the elbow joint. The sensory loss is felt to the 5th finger. The typical holding of the hand with ulnar paresis is “claw hand”.

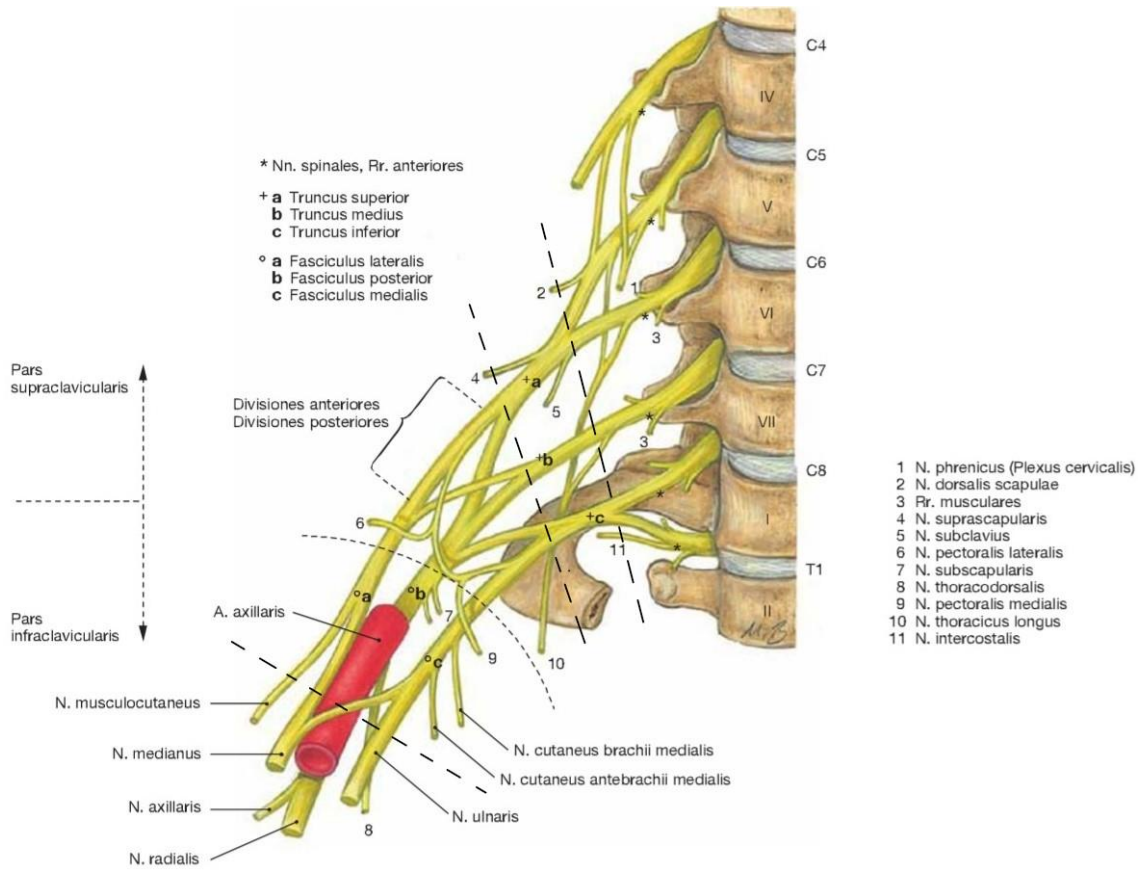


Figure 7: Brachial Plexus according to Sobotta. (29)

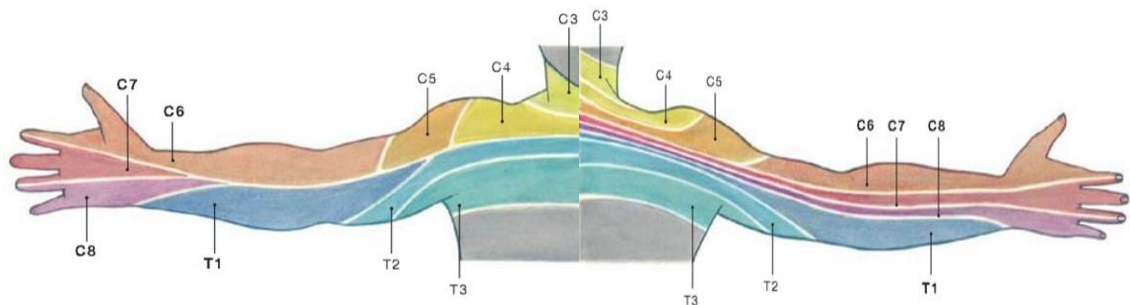


Figure 8: Dermatomes of the upper extremity according to Sobotta, anterior and posterior view. (29)

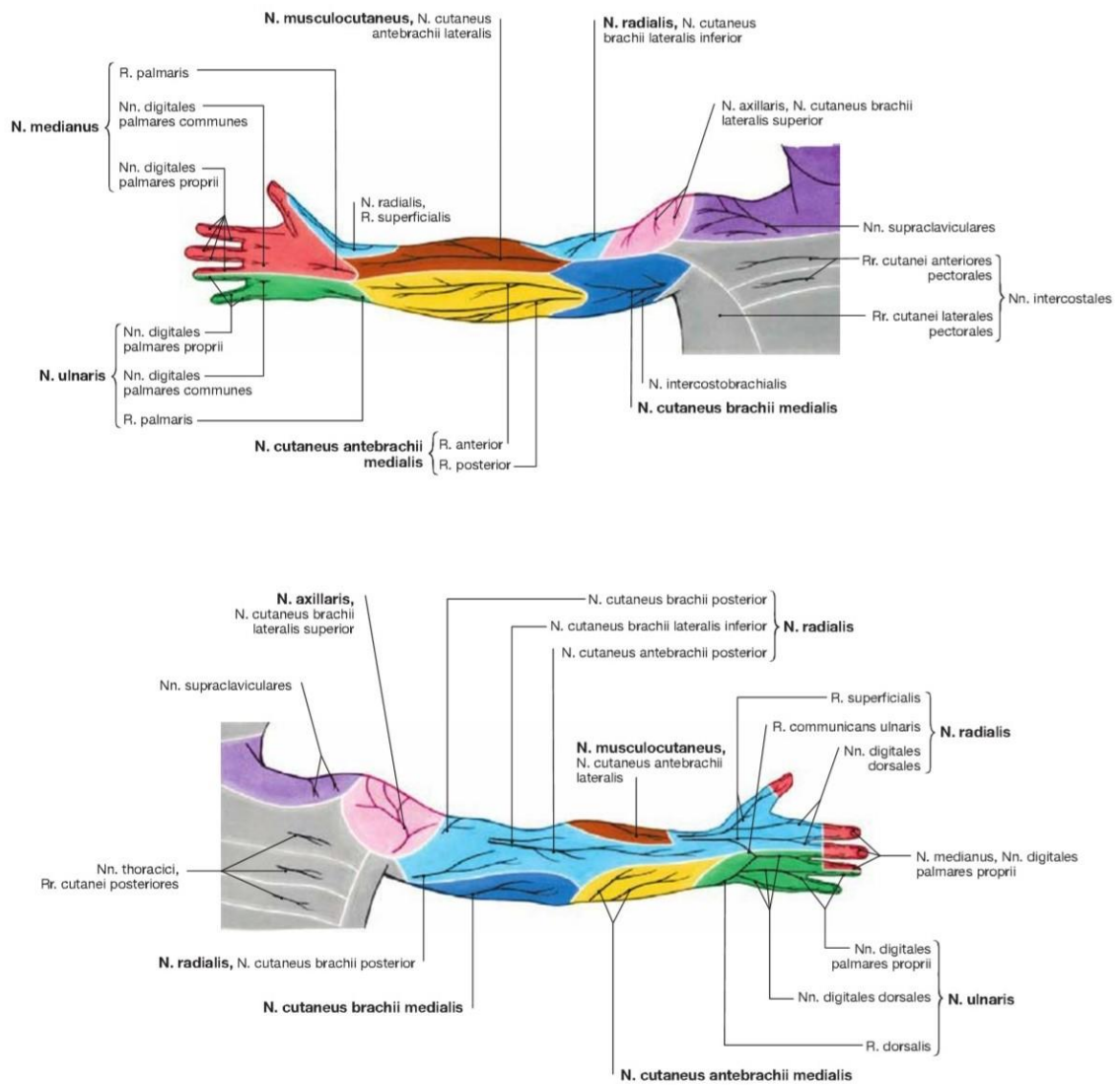


Figure 9: Cutaneous nerves of the upper extremity, ventral and dorsal view, according to Sobotta (29).

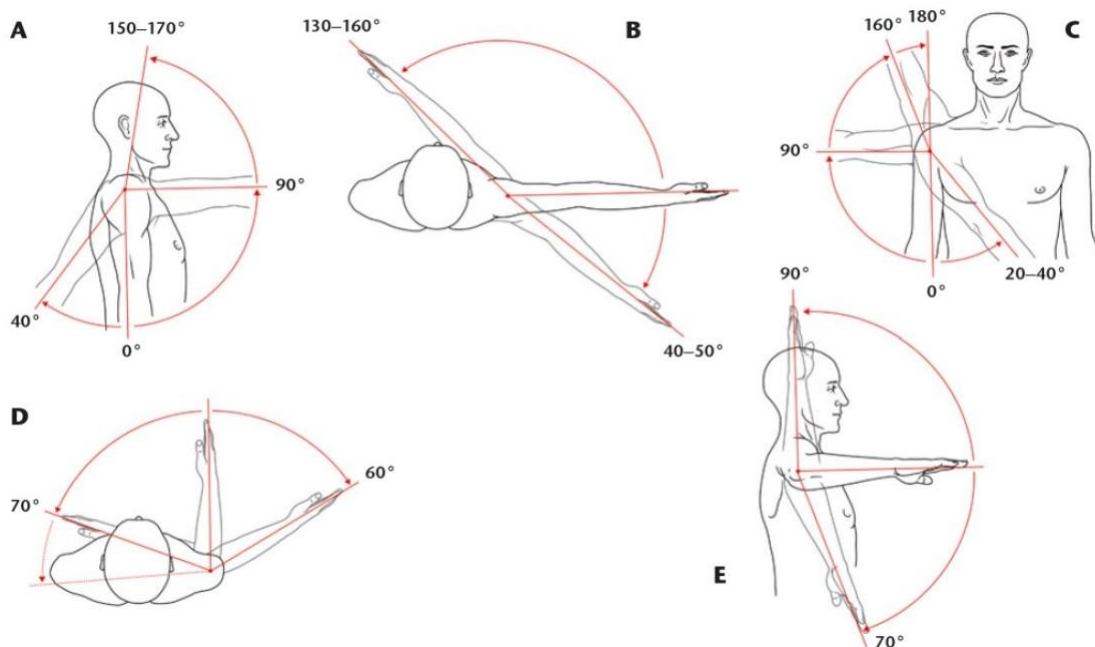
2.2 Kinesiology of the shoulder

Before going in depth concerning movement of the shoulder complex, it is important to remind the terms used when coming to shoulder. The shoulder girdle consists of the scapula, clavicle and to a lesser degree, the sternum. The shoulder joint consists of the scapula and humerus (glenohumeral joint). These two terms together form the shoulder complex, which are five separate articulations: the glenohumeral, sternoclavicular, acromioclavicular, coracoclavicular and scapulothoracic joint. The coracoclavicular joint is not always taken into consideration, differing from authors. (14;20)

The scapulothoracic articulation represents the movement of the scapula over the rib cage, it is not a “true” joint, as it does not have any fixed point, like other articulations (20).

The shoulder has three degrees of freedom along the vertical, horizontal, and transversal axes (18). The following part of this paper will present the motions of the shoulder complex with its mechanism, and an explanation of the forces acting on the shoulder to achieve its optimal stability.

2.2.1 Shoulder active range of motion and its mechanism



A: Flexion and extension; B: horizontal adduction and abduction; C: abduction and adduction; D: external and internal rotation with arm along the body; E: external and internal rotation at 90° of abduction

Figure 10: Shoulder girdle movement and range of motion according to Kolář (8)

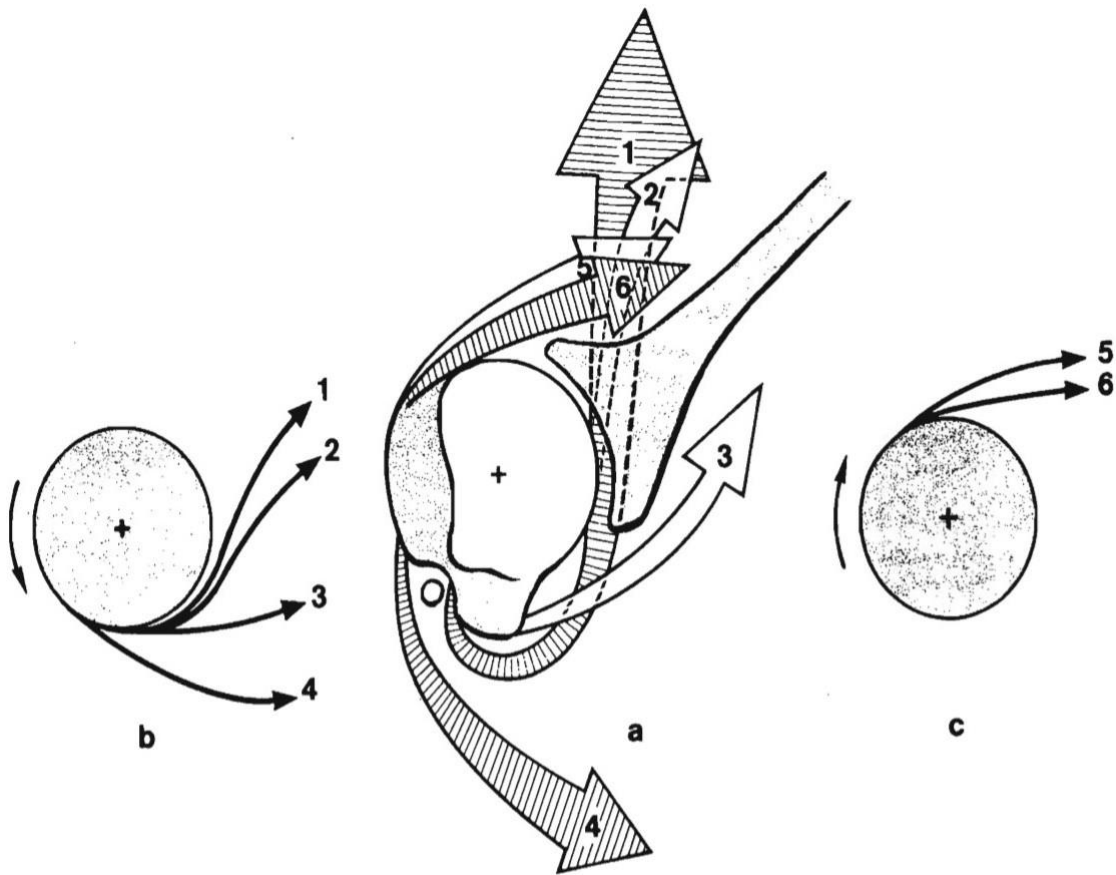
The figure 10 shows the range of motion of the shoulder on all his plans according to Kolář et al (18). However, Kapandji adds another measurement which is the internal rotation with the arm adducted and elbow flexed to 90 degrees (16). The norms of range of motion differs slightly according to the authors.

According to Kapandji (1971), flexion and abduction are divided into three stages:

<i>Flexion</i>	<i>Abduction</i>
<p><u>First phase:</u> 0° to 50°-60°</p> <p>Muscles involved are:</p> <ul style="list-style-type: none"> - Anterior Deltoid - Coracobrachialis - Clavicular part of pectoralis major <p>Limitation occurs due to:</p> <ul style="list-style-type: none"> - Coraco-humeral ligament tension - Resistance offered by teres minor, teres major and infraspinatus <p><u>Second phase:</u> 60° to 120°</p> <p>Muscles involved are:</p> <ul style="list-style-type: none"> - Trapezius - Serratus anterior <p>Limitation occurs due to resistance of latissimus dorsi and costosternal fibres of pectoralis major.</p> <p><u>Third phase:</u> 120° to 180°</p> <p>The movement of spinal column is necessary on the contralateral side. When flexing both shoulders simultaneously, it is accompanied by an increased lumbar lordosis, activating lumbar muscles.</p>	<p><u>First phase:</u> 0° to 90°</p> <p>Muscles involved are:</p> <ul style="list-style-type: none"> - Deltoid - Supraspinatus <p><u>Second phase:</u> 90° to 150°</p> <p>Muscle involved are:</p> <ul style="list-style-type: none"> - Trapezius - Serratus anterior <p><u>Third phase:</u> 150° to 180°</p> <p>When only one arm is abducting, there is a contralateral side bending of the trunk, produced by the contralateral spinal muscles.</p> <p>If both arms are abducting, the mentioned side bending converts into exaggerated lumbar lordosis.</p>

Table 6: Phases of flexion and abduction according to Kapandji (16)

Rotation mechanism



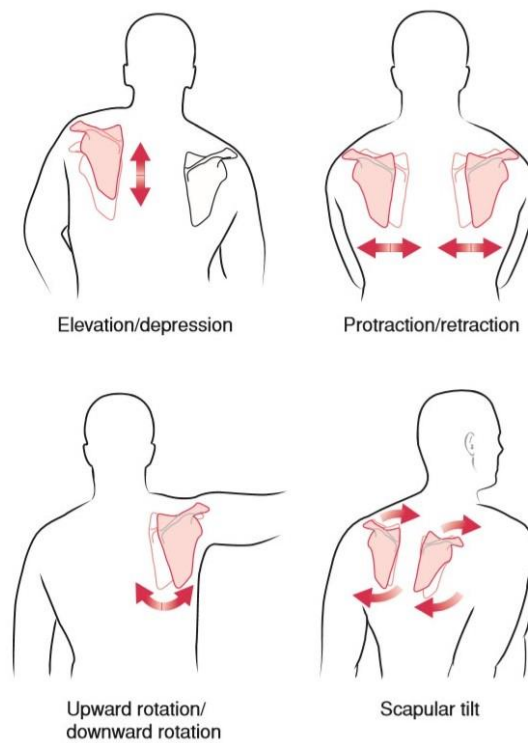
1- Latissimus dorsi; 2- Teres major; 3- Supraspinatus ; 4- Pectoralis major ; 5- Infraspinatus; 6- Teres minor. Diagram b) represents the forces generated by the medial rotators, Diagram c) represents the forces generated by the external rotators and Diagram a) represents the whole glenohumeral joint with the rotational forces included.

Figure 11: Diagram of the rotator muscles of the arm, according to Kapandji (16)

There are more medial rotators than external, which makes them stronger. However, there are complementary scapular muscles aiding external and internal rotation. The rhomboids and trapezius provide retraction of scapula, which accompanies the external rotation. Whilst the serratus anterior and pectoralis minor are the complementary muscles providing scapula protraction and aiding in medial rotation. (16)

This mechanism interestingly explains the relation between natural stronger medial rotators and the tendency of having protracted shoulders, resulting in hyperkyphosis and spinal complications.

2.2.1.1 Movements of scapula



- Elevation/Depression and protraction/retraction – Linear motions
- Upward and downward rotation of the scapula – Angular motion
- Scapular tilt – when shoulder joint goes in hyperextension

Figure 12: Movements of the scapula according to Lippert (20).

Even though there is a differentiation between shoulder girdle and shoulder joint, it is difficult to differentiate one to another when coming to motion. Each shoulder girdle movement is followed or is following the initial movement of shoulder joint. There for, there is a correlation between these two. The table 7 shows the motion of the shoulder joint and the following of shoulder girdle. (20)

<i>Shoulder joint</i>	<i>Shoulder Girdle</i>
Flexion	Upward rotation; protraction
Extension	Downward rotation; retraction
Hyperextension	Scapular tilt
Abduction	Upward rotation
Adduction	Downward rotation
Medial rotation	Protraction
Lateral rotation	Retraction
Horizontal abduction	Retraction
Horizontal adduction	Protraction

Table 7: Relation between the shoulder joint and girdle motion, Lippert (20)

2.2.1.2 Scapulohumeral rhythm

Continuing this connection between shoulder joint and shoulder girdle, for “the first 30 degrees of shoulder joint motion, it is purely shoulder joint. After that, for every 2 degrees of shoulder flexion or abduction that occurs, the scapula must upwardly rotate 1 degree.” (20) This is the 2:1 ration, known as scapulohumeral rhythm.

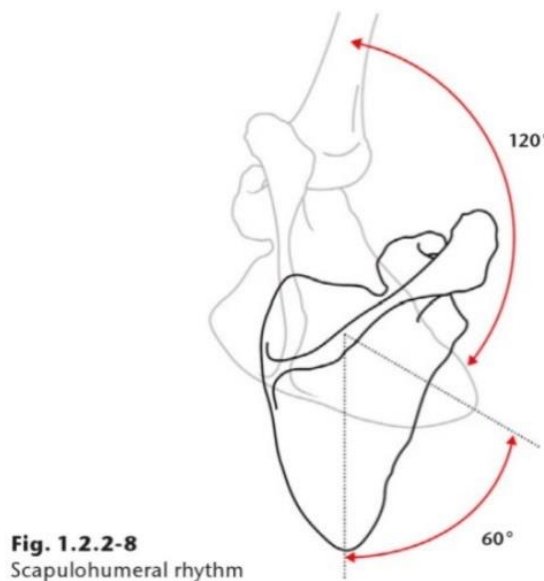


Figure 13: Scapulohumeral rhythm, according to Kolář (18)

This rhythm allows greater range of motion of the shoulder complex and its understanding is of vital importance for identifying certain shoulder pathologies.

2.2.2 Biomechanics of the shoulder

Sternoclavicular and acromioclavicular joint

The sternoclavicular joint provides a major axis of rotation of the shoulder girdle. It has two degrees of freedom, on the frontal and transverse plane. This joint also allows a slight forward and backward sagittal plane rotation. The articular disk of the sternoclavicular joint serves as shock absorber, especially during falls with outstretched hands.

Concerning the acromioclavicular joint, it rotates when the arm elevates, and its closed-pack position is in 90 degrees abduction of the arm. (14)

Scapulothoracic joint

The scapula moves in sagittal and frontal planes in respect to the trunk. Several muscles are attached to this bone and provides two functions:

- Stabilize the shoulder region: by a synergistic activation of muscles listed on figure 14. According to Myers, there are muscles chains contributing to such stabilization, the spiral line with its strong fascial connection with serratus anterior and rhomboids, and the superficial and deep, front, and back lines. (14;22)
- Facilitate movement of the upper extremity: Susan Hall gives as an example the overhand throw. The rhomboids contract to move the entire shoulder posteriorly as the humerus is horizontally abducted and in external rotation. The tension in rhomboids releases to allow the throwing motion coming from the GH joint. (14)

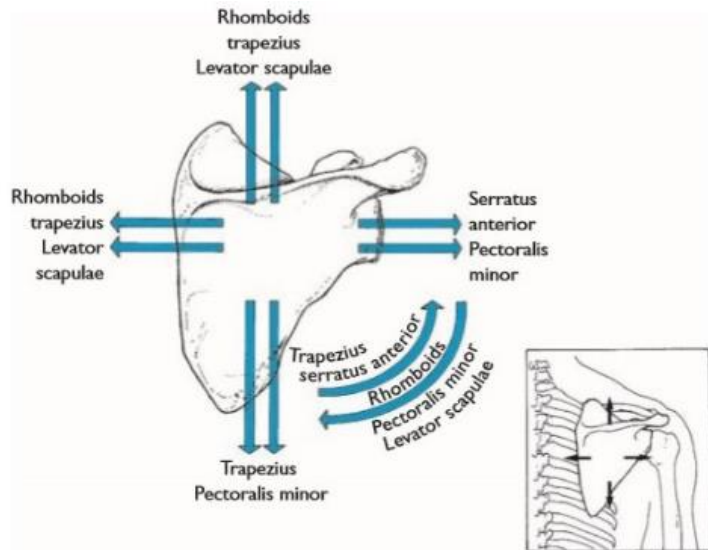


Figure 14: Action of scapular muscles according to Hall (14)

Glenohumeral joint

The glenoid fossa is less curved than the head of humerus surface, where the joint moves linearly across the glenoid fossa's surface, on top of the big rotational capability.(14) Having overviewed the structural components of the glenohumeral joint and its predisposition to instability, the stabilizing forces exerted on this joint will be explained.

Evan et al. presents the stabilizing mechanism in three groups: the static and dynamic stabilizers and “additional factors” affecting the stability of such joint (10).

- Concavity-compression mechanism: this belongs to both groups. The glenoid labrum increases the depth of the glenoid surface and surface area of articulation, whilst the rotator cuff dynamically compresses the head of humerus into the articulating surface.

- Capsuloligamentous structures: they prevent excessive translatory and rotational movements of the head of the humerus into the glenoid surface. Looking at the picture n.18, and taking the example of rotatory motion, one side will tighten under tensile forces whilst the opposite loosens. However, most stability comes from the RC and the long head of biceps tendon that actively keeps the humeral head into the glenoid. The shoulder ligaments share the loads with surrounding muscles and other stabilizing mechanisms. (10) Therefore, even though we could expect the glenohumeral ligaments to

tolerate a high number of external loads, they are not as strong as the knee ligaments for example, because of this “sharing load” mechanism.

- Rotator cuff: they have a major role in the concavity-compression mechanism. Also, the coordination of muscle contraction keeps the head of humerus into the articulating surface during active motion.

- Long head of biceps: it has a dynamic stabilizing role, preventing the anterior and superior excessive translation of humeral head.

- Negative Intra-articular pressure: due to the structural component of the joint, the concavity creates a sort of “vacuum” effect. The magnitude of such force is minimal if compared to the muscle contraction force. However, it remains vital to the joint when it is totally relaxed.

- Scapulothoracic motion:

- o If the rotation of scapula is abnormal, the glenoid does not stand properly with the rotating humeral head, increasing the chances of acquiring instability.

- o If there is a winging scapula, the coracoacromial arch descends and the probability of suffering from functional impingement is higher. (10)

2.2.2.1 Loads on the shoulder

The relation between the orientation of the scapula and scapulohumeral rhythm is altered when applying an external force by loading an object, for example. Carrying an object will automatically activate the shoulder muscular stabilization, which will reduce the scapulothoracic motion. (14) If we want to reach the normal range of motion of the GH joint in abduction, for example, the required force from the middle deltoid and supraspinatus would be much higher, adding the opposing vectors (from the held object and the gravity constant).

The shoulder complex is also a shock absorber, the sternoclavicular joint absorbs all shock when the arm is abducted and fully stretched.

2.2.2.2 Force Couples

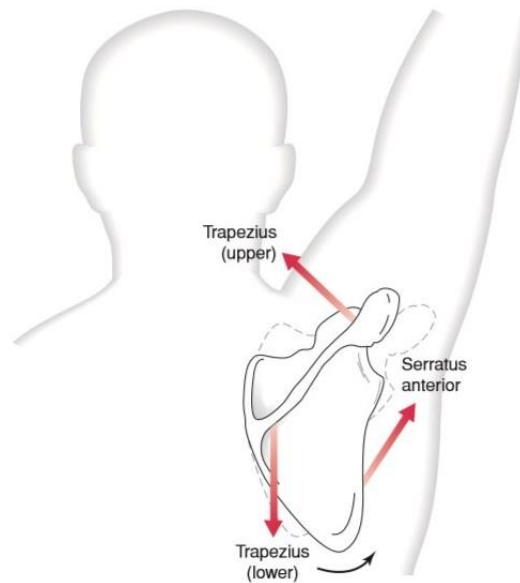


Figure 8-21. The muscular force couple produces upward rotation of the scapula.

Figure 15: Muscular force couple producing upward rotation of the scapula, according to Lippert (20).

A force couple is defined by Lippert as “muscles pulling in different directions to accomplish the same motion.” (20)

In the example of upwards rotation of the scapula, are working together the cranial trapezius, serratus anterior and lower trapezius.

Other force couples are the levator scapulae and lower trapezius, in the elevation and depression of scapula whilst serratus anterior and middle trapezius act together on the abduction and adduction of the scapula.

2.3 Rugby tackle – biomechanics and kinesiology



Figure 16: Typical rugby tackle (personal file)

Tackling is known to be the most prevalent contact event leading to shoulder injury. The most common tackling position is crouched with approximately 90° abduction and extended arms, trying to reach the opponent's waist on the antero-superior surface of shoulder and arm. This region is known to receive the highest pressure among tackle impact. There for, the clavicle, scapula and trapezius are the structures highly affected by such mechanism, consequently the acromioclavicular and glenohumeral joint also. The impact force, represented in the Figure 16, is directed antero-posteriorly.

From the crouched position, the tackler uses his lower extremity to generate a mechanical impulse from the foot strike, which increases the tackle efficiency and slightly decreases the impact force received upon the shoulder - notice the alignment between the left lower extremity and impacted shoulder in the figure 16. The forces encountered among the impact phase create leveraging forces over the glenohumeral joint, bringing the shoulder into excessive horizontal abduction and external rotation, which may lead to dislocations, labral tears, and numerous shoulder pathologies. (9;15)



The red arrow represents the direction of force from the opponent. The sectioned arrow represents the leveraging force acting upon the glenohumeral joint, as a resultant from the opponent's direction and localization of impact.

Figure 17: "Arm tackling", retrieved from article 15

result in anterior instability. (15)

Faria et al. (2017) have conducted an experiment explaining the tackle effects of the shoulder's muscles. It has been found that repetitive tackles would decrease the strength in external rotation but increase it in internal rotation. The explanation leads to two hypotheses; either, it is the result of a compensatory mechanism, where the anterior deltoid and latissimus dorsi claimed to be predominant in consecutive impacts, or, the repetitive tackling cumulates micro-damage on muscular structures where the neuromuscular system would be implied, affecting the time of muscle response during arm movement (muscle synergy). (9)

However, the major founding related to shoulder instability is that the repetitive tackles damage the rotator cuff and trapezius, with a special emphasis on cranial trapezius. The RC efficiency is decreased, inducing poorer stability, and increasing the probability of dislocation (9).

Finally, tackles abide to have a major impact on the shoulder complex, under biomechanical and physiological aspects. For these reasons, rugby players are required to have excellent dynamic shoulder stabilizers, defying all the external loads during rugby games and practices.

There are many methods when coming to tackling. However, one of them reveals to be highly propense to dislocations and consequences. The figure n.17 shows an "arm tackling", where the tackler intents to reach the opponent by outstretching one arm. Here, the GH joint is at high risk. Factors such as the speed and size of the opponent as well as the direction (in this case, posterior) will be exerted on the tackler's lower arm, bringing the humeral head anteriorly. Major stress is applied on the RC muscles and may

2.4 Shoulder instability – Anterior dislocation

Shoulder instability is defined as a symptomatic abnormal motion of the humeral head relative to the glenoid during active range of motion (10;25). The explanation of this statement can be made by reviewing the anatomy and kinesiological component of the shoulder joint mentioned previously.

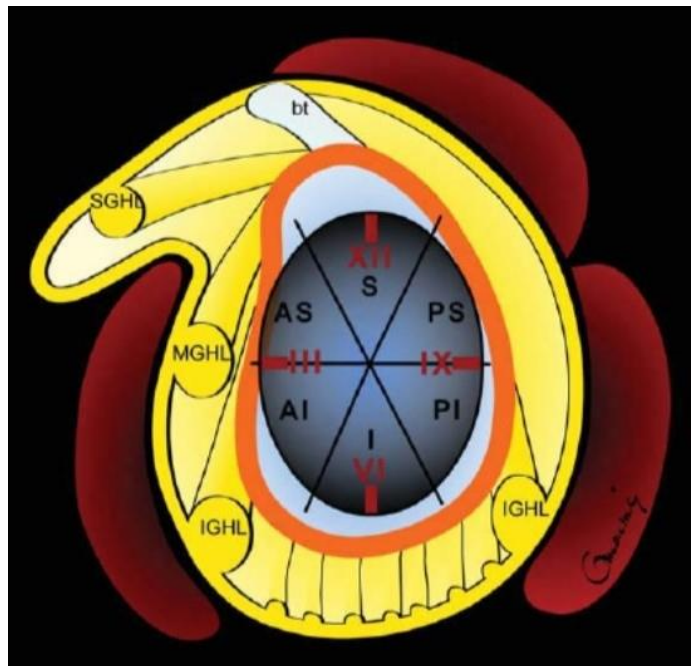

Figure 18: Diagram of glenohumeral ligaments in relation to the glenoid labrum and joint capsule (24).

Omoumi P, et al. (2011) mention as part of the stabilization mechanism of the shoulder joint, the static stabilizers. These are crucial when reaching the maximal range of motions. The picture n.18 shows the relation of the glenohumeral ligaments to the glenoid labrum and joint capsule, which may be a tool to understand part of the pathogenesis of shoulder instability, according to the same authors. Most instability lesions occur in abduction and external rotation. This position puts into tension the anterior band of IGHL, which in extreme tensile forces, can result in a tear therefore anterior dislocation of the shoulder joint. (24) There are several mechanisms explaining shoulder dislocations, but this paper will focus its attention on anterior dislocations and consequences.

2.4.1 Bankart lesion

Often due to repeated anterior shoulder luxations, Bankart lesion is a lesion of the anterior part of the glenoid labrum. Anterior shoulder dislocation can damage the connective tissue ring around the glenoid labrum. The recurrence of anterior dislocations causes damage, or poor reconstruction of GH ligaments.

According to Omoumi et al. (2011), 95% of all shoulders instabilities happens to be anteriorly. This high probability is because the scapula lies around 30 degrees to the frontal plane of the body. The mechanism of such injury is mostly to happen with the arm abducted in extension and external rotation. (24)

Bankart lesion is classified in two:

- *Soft-tissue Bankart lesion*: anteroinferior labrum avulsion, damage of the glenoid rim. The posterior capsule may be stretched with the inferior glenohumeral ligament torn.
- *Bony Bankart lesion*: it is like the soft-tissue injury, but is accompanied by the fracture of the anteroinferior glenoid rim (a. and b. of the picture below)

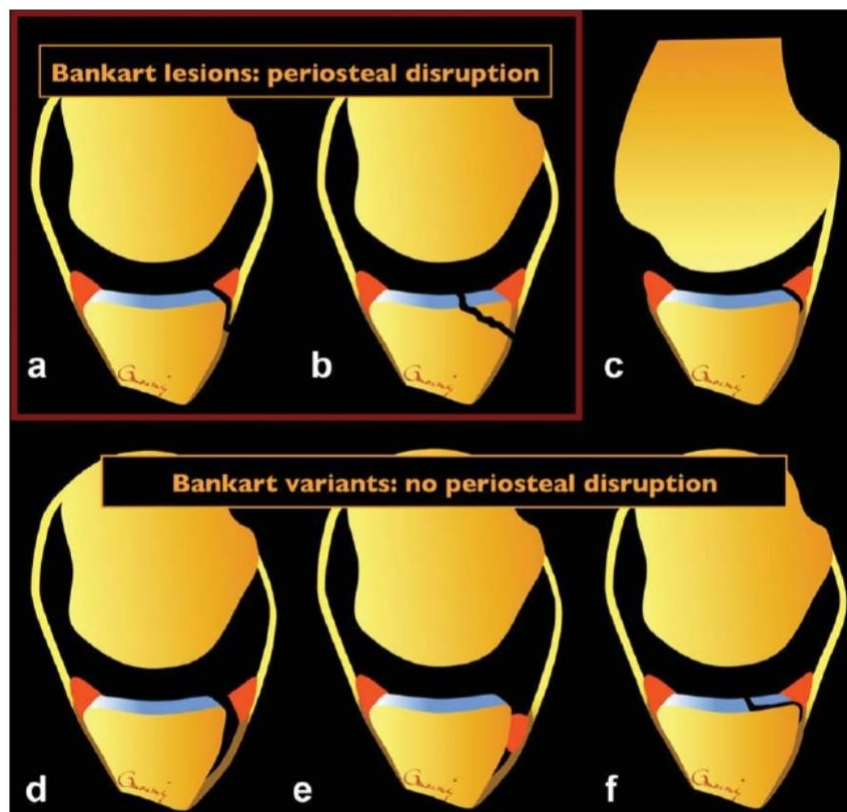


Figure 19: Diagram of Bankart lesion. (24)

2.4.1.1 Epidemiology

Most patients with recurrent anterior shoulder instability are subject to a Bankart lesion. Atef et al. (2014) have demonstrated that this lesion is one of the consequences of traumatic anterior glenohumeral dislocation. They have conducted an experiment with 240 patients with such condition and have studied the associated lesions. More than half of these patients had associated lesions (144 cases). Rotator cuff tear was the most common according to this study, following axillary nerve injury, great tuberosity fracture, Hill-Sachs and Bankart lesions always being combined. (2) However, another study conducted by Carrazzone et al., have shown other results.

Their study was conducted with 57 patients with traumatic anterior shoulder instability, with more than one episode of shoulder dislocation and at least six months since the first dislocation. They performed an arthroscopic inspection and the results showed that Bankart lesions were the most prevalent (100%), followed by Hill-Sachs lesions (71.9%), whilst the rotator cuff injuries (1.8%) were the least prevalent. (4)

The results of both studies are paradoxical, nonetheless, they show that despite the differences in the numeric results, the kind of associated injuries with anterior shoulder instability are the same and certainly include Bankart and Hill-Sachs lesion, being part of the most prevalent. There is a strong correlation between these two lesions, which will be presented in the chapter 2.4.2.1.

According to Antunes et al. (2016), shoulder dislocation involves a tear of the inferior capsuloligamentous complex and labrum from the anterior inferior glenoid 97% of the time. (1)

2.4.1.2 Etiology

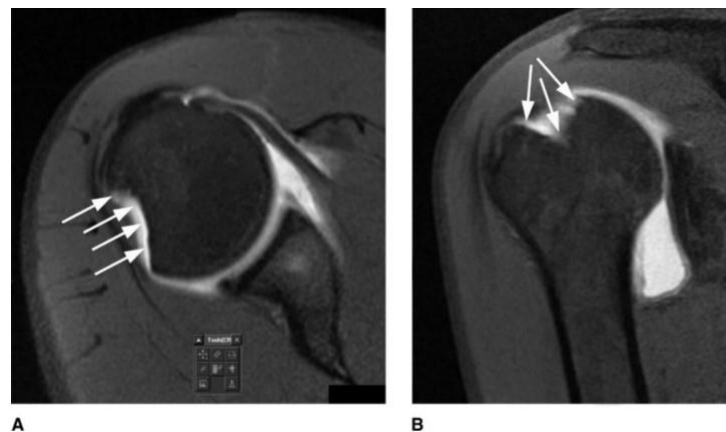
As mentioned previously, Bankart lesion is one of the possible results of recurrent anterior shoulder instability. Repeated anterior GH dislocation is the major risk factor of Bankart lesion. The shoulder dislocations are mostly due to traumatic injuries. Falling with the arm outstretched in abduction, extended, and externally rotated is the typical mechanism of injury.

According to Antunes et al. (2016), 90% of young patients with a dislocation of GH joint are accompanied with Bankart. (1) Age seems to be a risk factor, as the ligamentous structure have more laxity. (33)

2.4.2 Hill-Sachs lesion

Compression fracture of the posterosuperolateral humeral head. This injury has a remarkably close correlation with Bankart lesion. It also more common in recurrent dislocations. The mechanism of injury is the impact of the head against the glenoid rim whilst the dislocating motion will cause an impression fracture. (27)

The classification differs according to all authors, but the most important consideration is to determine if the H-S lesion is responsible for the patient's symptoms. Most commonly, treating the primary cause, is enough to treat the H-S lesion. (27) According to Rowe et al., H-S is classified in: Mild – Moderate – Deep – Severe according to the length and depth of the lesion, ranging from 2cm long, ≤ 0.3 cm deep to 4cm long and ≥ 1 cm deep.



Axial (A) and coronal (B) magnetic resonance arthrograms demonstrating a classic Hill-Sachs lesion (arrows).

Figure 20: MRA of Hill-Sachs lesion (27)

2.4.2.1 Epidemiology, relation between Bankart and Hill-Sachs lesions

According to Wilk et al. (2006), Hill-Sachs lesion has been reported in up to 80% of dislocations.

Widjaja et al. (2006) established a study about the correlation between Bankart and Hill-Sachs lesions in anterior shoulder dislocation. The selection of participating patients was made upon their medical history, having a traumatic anterior shoulder dislocation and the evaluation of respective MRI. The results lead to the conclusion that there are around 2.5 more chances of experiencing one another. The table n.6 justifies such result; we can see that in both cases, being primary or recurrent dislocation, the probability of having both pathologies are high (ranging from 64% to 81%). However,

there is a remarkable difference in recurrent dislocations, where the chances raise up to 81%. (33)

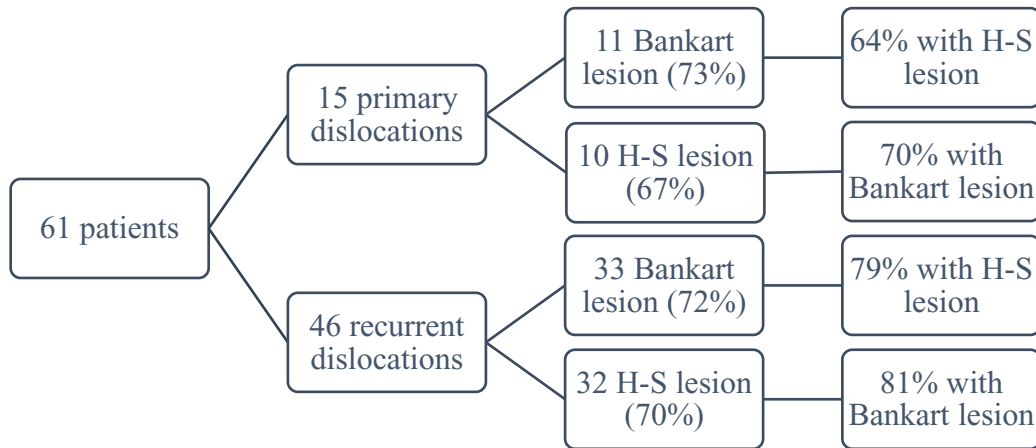


Table 8: Results summary of Widjaja et al. (2006)

2.4.3 Diagnostic procedures

Because the main etiology of such condition is traumatic, the primary dislocation should be visible on the moment of the incident. In this precise instant, it is of vital importance to perform a closed reduction procedure, if conditions allow to do so. This will prevent any further complications, such as muscle spasm, making the later process nearly impossible without sedation. Closed reduction procedure refers to the process of returning the shoulder joint into its “normal” position. It is to note that they are many techniques to achieve this technique.

Upon inspection of a suspected anterior dislocation, the humeral head should be palpable on the anterior side, with a prominent acromion, palpable fullness below the coracoid process and towards the axilla of the affected side. All movements are restricted and painful, the patient would resist all arm movement. The “Anterior Shoulder Apprehension Test” and the “Load and Shift test” claimed to be as reliable as imaging procedures diagnosing anterior shoulder instability, according to Bryan et al. (21; 32)

They are a few imaging procedures that have been recognized for Bankart and Hill-Sachs lesions. These includes X-Rays (antero-posterior, axillary and lateral views), Computed Tomography scans, useful in showing the orientation of the damage and very useful in preoperative planning, and among these, MRA and MRI are known to be the

most effective (21). When coming to X-rays, the Stryker notch view is known to be for Hill-Sachs lesion, allowing the direct view on the posterolateral defect of the head of humerus. Ultrasonography is also used and avers to be 100% specific for Hill-Sachs diagnosis. (8;21;,27)

2.4.4 Treatment

2.4.4.1 Conservative treatment according to Kolář (18)

Non-operative treatment after a shoulder dislocation consists of repositioning the GH joint followed by the strengthening of the shoulder girdle stabilizers. The shoulder must be immobilized in adduction and internal rotation for approximately 6 weeks. The length of immobilization differs according to authors, and various factors about the patient's injury.

Whilst the GH joint is immobilized during the acute stage, it is important to work on other segments such as the wrist, hand, cervical and thoracic spine. If omitted, these segments will be restricted, adding to the muscle atrophy due to poor activity. These will lead to further on complications and lead to a negative prognosis. Still in the acute stage, cryotherapy may be applied around the glenohumeral zone to induce soft tissue healing and improve the inflammatory state.

After 6 weeks of immobilization, isometric exercises with GH joint approximation may be performed. Flexion, extension, internal rotation, and abduction to 45° is allowed for the patient.

External rotation may be initiated from the 8th week after the injury, with active abduction to 90°. Exercising is focused on the activation of the rotator cuff muscles and lower scapular stabilizers.

Full range of abduction and external remain contraindicated 3rd month after the injury.

If the rehabilitation program is not performed correctly, it will lead to recurrent dislocation, leading to Bankart lesion. There for, it is highly recommended to consider an arthroscopic Bankart repair. (18)

There are several studies demonstrating the high recurrence rate of shoulder instability when approached with a conservative treatment. The recurrence rate is based on various factors, such as the age (recurrence rate of 92% in teenagers), activity level and arm dominance. (34) Concerning the age, the younger is the patient, higher is the risk

of having recurrent instability, due to the shoulder laxity matter. (10) Collision sport athletes have a remarkably high recurrence rate ranging between 86% and 94%. (34) There for the importance of considering an arthroscopic Bankart repair, according to each patient needs.

2.4.4.2 Arthroscopic Bankart repair

The goal of arthroscopic Bankart repair is to release, mobilize and tension the capsulolabral complex at the anteroinferior aspect of the glenoid. (7)

Procedure

The surgery begins with a diagnostic arthroscopy to confirm the presence of a Bankart lesion and possible associated pathologies. This diagnostic arthroscopy evaluates the labrum, capsular tissue, rotator cuff and biceps brachii tendons, the humeral head, assesses and measures any Hill-Sachs lesion. A “load-shift” test should be performed, to evaluate the anterior and posterior translations of the humeral head. (7)

After the diagnostic arthroscopy, it is important to “free” the Bankart lesion before fixation. To achieve this, clinician shave the debris, damaged tissue to improve the soft-tissue healing. They also mobilize the capsulolabral lesion. It is important to visualise the subscapularis muscle state for further rehabilitation. (7)

Finally, fixations are applied. They are many types of “anchors” used and respective debates, but the most common applied are suture anchors (Cf. picture n.20). This is in the aim of repairing the labral tissue back to the glenoid.

An interesting study have been carried evaluating the effectiveness of different techniques used in Bankart repair. By loading the different materials with 25 Newton force, Nho et al. examined differences in the biomechanics between repairs with simple stitch, suture anchor with horizontal mattress stitch, double-loaded suture anchor with simple stitch, and knotless suture anchors. (7;23) The testing by applying load has revealed to be especially important when applying the anchors to the patient, considering the daily tasks. However, the importance of loading to failure on contact athlete is as important to have a successful repair.

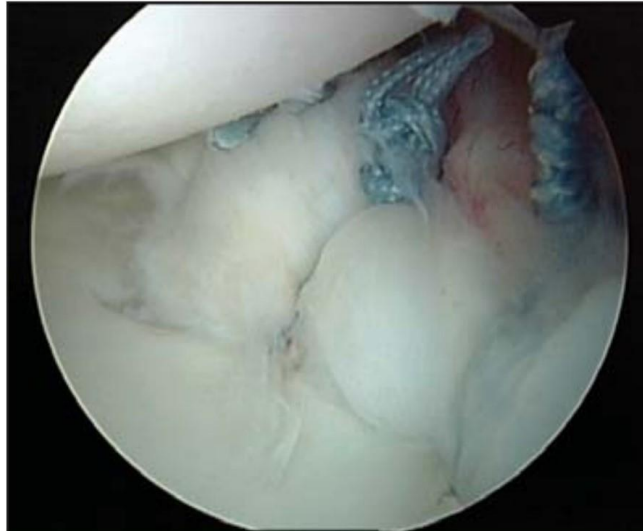


Figure 21: Arthroscopic view of a repaired Bankart lesion – 3 suture anchors (7)

2.4.4.3 Clinical picture post-surgery

Patients undergoing arthroscopic Bankart repair might experience pain after the treatment. They must be immobilized for 4 to 6 weeks, depending on the surgeon's indication.

Range of motion is decreased, and the patient's contraindication will be external rotation. As it is an arthroscopic surgery, the scar should be minimal, without complications. Arthroscopic Bankart repair is appreciated for not having major post operative pain, lower morbidity than open Bankart repair, maximal preservation of external rotation (in the long-term) and improved cosmesis. (1)

Complications may occur after surgery, if the suture anchors are not positioned correctly, the patient may experience significant pain and decreased range of motion. Long-term complications are also a possibility, leading to chondrolysis and osteoarthritis. It is important to check the integrity of the axillary nerve, as it is the one most at exposure during the surgery. (7)

2.4.4.4 Post-surgery physiotherapy

According to Kolář (2013), rehabilitation after surgery is divided into four phases (18):

- Phase I (0-2 weeks after surgery):
 - Immobilization of the shoulder complex
 - Soft-tissue techniques on the shoulder girdle
 - PRoM in 90° flexion is allowed
 - Contraindicated movements: external rotation, extension, internal rotation with the hand behind the back.
- Phase II (2-5 weeks after surgery):
 - The brace is gradually removed
 - Pendular movements, stabilization exercises and PRoM.
 - Week 3: initiation of internal rotation with the arm behind the back
 - External rotation to 30° from a neutral position and shoulder flexion with supination are tolerated
 - Contraindicated movements: external rotation in abduction and extension
- Phase III (5-8 weeks after surgery):
 - Initiation of ARoM with assistance approximating full RoM in the shoulder
 - Dynamic stabilization, PIR, stretching into flexion, internal rotation and horizontal adduction are implemented
 - Gradually increase the external rotation from neutral position
 - Contraindicated movement: external rotation in abduction
- Phase IV (8-12 weeks after surgery):
 - Strengthening is continued, with no contraindicated movements.

It is particularly important to educate the patient concerning his indicated and contraindicated movement and guide him into a correct rhythm of exercising.

It has been demonstrated that there might be a decrease in proprioception after surgery (34). There for, proprioceptive exercises are to be implemented in the therapies. As an example, an easy exercise combining strength and proprioception could be a simple ball-press against the wall with closed eyes, trying to reproduce simple movements.

3. Case study

3.1 Methodology

The clinical work placement was undertaken at Centrum Léčby Pohybového Aparátu, in Prague. This placement started on the 13.01.2020 and ended on the 07.02.2020 where I was attending 8h daily every Monday and Wednesday, 4h every Friday, with a total of 80 hours.

C.L.P.A. is a clinic receiving in and out-patients. I was placed in the in the out-patient department. The clinic counts with a room for hydrotherapy, another room for modalities such as ultrasound, electrotherapy, magnetotherapy, and a fully equipped gym.

My supervisor was Mgr. Martina Damborová. The first meeting with the patient was on the 20.01.20, one week after starting the work placement. The same day, I performed the initial kinesiological examination. Our time per session was ranging from 1 hour to 1 hour and 30 minutes. The therapies ended on the 05.02.20 were the final kinesiological assessment was driven.

The patient had access to the magnetotherapy room and hydrotherapy room, were I was not responsible for setting the parameters, either choice of physical modalities. We worked together in the gym, where a lot of tools were at disposal, such as gym balls, medicine balls, weights, Posturomed platform, Bosu balance board, and Therabands. We also had access to a private therapy room, which was mainly use for kinesiological assessments, but most of the therapies were realized in the gym, were therapeutical beds were also available. The patient was prescribed to have hydrotherapy and magnetotherapy 3 times a week, but because of patient's schedule, it was not possible. She then attended hydrotherapy and magnetotherapy twice a week.

The therapies were focused on regaining strength on shoulder complex stabilizer's and controlling existing range of motion. Concerning the kinesiological examination, tools were used such as plastic goniometer and measuring tape. I made sure the patient was fully aware of all procedures, at each session, the previous exercising was repeated, trying to set a daily program to perform at home.

3.2 Anamnesis

Examined person: J. D., female *Year:* 2003

Diagnosis: Arthroscopic Bankart repair, right shoulder.

3.2.1 Status present

Objective:

- Height: 170cm
- Weight: 70kg
- BMI: 24.2
- Right-handed

The patient has no problem in communication, use of shoulder brace out of home.

Subjective:

The patient has been operated on her right shoulder on the 18th of December 2019. She is now starting her rehabilitation process, 5 weeks after surgery. She complains about feeling a strong weakness around her shoulder. However, she does not have major restrictions in her ADL. She is looking forward to being able to play rugby again.

3.2.2 History Anamnesis

The patient anteriorly dislocated her right shoulder on the 6th of October on a rugby game, doing an “arm tackle”. It is her second dislocation in 3 months, both resulting from rugby tackles. On both incidents, she had an immediate repositioning of the GH joint. She performed an MRI which diagnosed a distension of the anterior part of the joint capsule with labral tear and mild Hill-Sachs lesion. Because of the recurrent dislocation in such short time, she has been advised to undergo an Arthroscopic Bankart repair.

3.2.3 Injury Anamnesis:

1st of April 2017 – fracture of the ulnar base. Use of cast for 5 weeks

25th of June 2017 – right clavicle fracture distal part. Rest and brace for 4 weeks.

August 2017 – lateral collateral ligament and ankle sprain – crutch use for 3 weeks. No exact information about the location on the ankle.

November 2018 – Concussion due to a hit in a rugby game. Short term memory loss.

End of June 2019 – right shoulder dislocation, 5 weeks brace.

6th of October 2019 – right shoulder dislocation. Underwent an MRI a month after, resulted in distension of the anterior part of the joint capsule with labral tear and mild Hill-Sachs lesion. Doctor then suggested Bankart repair.

3.2.4 Surgery anamnesis:

None. This is her first surgery (Arthroscopic Bankart repair).

3.2.5 Medical anamnesis:

Nothing to declare.

3.2.6 Family anamnesis:

Nothing to declare about her familiar health condition.

3.2.7 Social anamnesis:

The patient lives with her parents and her younger brothers. They are all highly active into sports, she helps with her younger brother's rugby training. She trains intensively, every day.

3.2.8 Occupational anamnesis:

The patient is a student and a high-level athlete. Rugby player for the Czech national team.

3.2.9 Allergy anamnesis:

None.

3.2.10 Pharmacological anamnesis:

None.

3.2.11 Hobbies:

Rugby-woman, she has played internationally.

3.2.12 Abuses:

None.

3.2.13 Prior rehabilitation:

According to her memories, rehabilitation for her knee and ankle, strengthening, proprioceptive exercises... Has attended also for her previous shoulder luxation, with the use of PT such as whirlpool and 4 poll interference, and strengthening exercises. As mentioned previously, use of orthotics.

3.2.14 Excerpt from patient's health file:

The first traumatic dislocation occurred at the end of June and the second dislocation occurred 3 months later, closed reduction was immediately done on both incidents. Both dislocations were treated with "Gilchrist" orthosis for 6 weeks.

3.2.15 RHB indications:

- Kinesiological assessment
- Soft tissue techniques and mobilization
- Magnetotherapy
- Hydrotherapy

3.3 Kinesiological Examination

3.3.1 Static Postural examination

- Anterior view: The feet are symmetrical, with an appropriate arch on both. The femur and knees are in appropriate alignment, symmetrical axis. Very slight deviation of umbilicus to the right leading to the supposition of having a rotated pelvis to the left. The right clavicle is shorter than the left with a visible predominant upper trapezius on the right. The shoulders are protracted, and the left is higher. The head is centered, following the spinal axis.

- Posterior view: No asymmetry in the foot or ankle, nor on the popliteal line. We can observe an asymmetry on the SIPS the left being higher, although it is only observation and will be confirmed in the pelvis palpation. The lateral curvature of the trunk is asymmetrical, the left side being more concave than the right. The lower angle of right scapula is dominant, and the medial edge is more visible than the left, leading to the supposition of having a weakened serratus anterior and the scapula in a slight external and upward rotation.

- Lateral view (left): The feet, knees and hip are in correct alignment. Shoulders are protracted accentuating the thoracic kyphotic curve. Neck and head are also protracted.

- Lateral view (right): We can observe the dominant lower angle of scapula. Shoulder is also protracted. Visible hypotrophy around the deltoid region (compared to the left side), even so she still is in good condition. It is important to consider her athletic background. Neck and head protracted.

3.3.2 Dynamic Spine examination

The patient can perform all movement (flexion, extension, latero-flexion) without any pain, nor restricted range of movement.

We can still observe that the motion happens in the lumbar spine and the upper thoracic spine tends to be immobile, represented by a straightened line, especially during latero-flexion.

The range of motion is slightly shorter to the right latero-flexion than the left and is followed by a rotation to the right of the trunk. It leads to the hypothesis of hypertonicity/overuse of contralateral quadratus lumborum, or fascia restriction.

3.3.3 Passive and active range of motion

<i>Shoulder</i>	Left		Right	
	AROM	PROM	AROM	PROM
Flexion	180	180	115	120
Extension	45	60	10	x
ABD	170	180	90	90
External rotation	85	90	5	x
Internal rotation	70	90	x	x

Table 9: Initial kinesiological examination – ARoM and PRoM

I did not passively test the extension as it was advised not to. Concerning the abduction, 90 degrees was the limit, respecting her time after surgery. External and internal rotation are both contraindicated movements, therefore it was not tested passively. She only showed her active range of motion until slight discomfort felt. Both internal and external rotations were tested in sitting position with 15 degrees abduction.

Neck: flexion, extension and rotation to both sides were not restricted, tested actively and passively. We can observe a slight restriction when side bending to the left. She declares feeling “tense” around the area on the right upper trapezius when performing the side bend.

3.3.4 Active ROM against resistance:

- No pain felt neither restriction when performing on the left upper extremity.
- Felt pain around the posterior deltoid zone when performing external rotation, internal rotation and flexion against resistance. The entire zone around deltoid is painful when abduction. No pain during extension.

3.3.5 Movement pattern according to Janda

Shoulder abduction:

- Right: Altered movement. There is a clear overuse of the cranial part of the trapezius, which results in a shoulder elevation. We can also observe a slight latero-flexion on the contralateral side of the trunk. The neck slightly rotates to the right during the abduction followed by a small rotation of upper trunk towards the same side.
- Left: The synchronicity of activated muscles is much better. We can mention that there is still a prominent activity on the upper trapezius, but it is minimal.

Neck flexion:

We primarily observe a dominance of sternocleidomastoid resulting in the head protraction when flexing the neck. But after verbal correction, the patient was able to flex the neck provoking a continuous arch, activating her deep neck flexors, without any sternocleidomastoid dominance, neither deviations.

3.3.6 Gait Examination

The knee and hip are in correct alignment. She tends to externally rotate the hip. In the lateral view, we can observe a slight head protraction, on top of the kyphosis of thoracic spine with protracted shoulder. There is no arm swinging, involving a major right rotation on the trunk.

3.3.7 Palpation

	Left	right
Trapezius upper/lower/middle	Hypertone	Hypertone
SCM	Normal	Normal Trp in origin
Scaleni	Hypertone	Hypertone
Levator Scapulae	Hypertone	Hypertone
Pectoralis major	Hypertone	Hypertone
Pectoralis minor	Hypertone	Hypertone
Supraspinatus	Hypertone	Hypotone
Infraspinatus	Normal	Hypotone
Rhomboid minor/major	Normal	Normal
Latissimus dorsi	Hypertone	Hypertone
Teres major	Normal	Hypertone
Teres minor	Normal	Hypotone
Deltoid	Normal	Hypotone
Biceps	Hypertone at insertion	Hypertone at insertion
Triceps	Normal	Hypotone
Paravertebrals	Hypertone thoracic zone	Hypertone thoracic zone
Quadratus Lumborum	Hypertone	Hypertone

Table 10: Initial kinesiological examination – Muscle Palpation

Sternocostal articulations: Not painful

Acromioclavicular: Not painful

Sternoclavicular: Not painful

3.3.8 Pelvis Examination

ASIS: left lower PSIS: left higher Crest: same level

3.3.9 Length test according to Janda and Kendall

	LEFT	RIGHT
Pectoralis major upper	1	X
Pectoralis major lower	1	X
Pectoralis minor	1	1
Teres major, lat. Dorsi, Rhomboids	0	x
Cranial trapezius	1	1
Levator scapulae	0	1
SCM (kendall)	No shortness	No shortness
Scaleni (kendall)	No shortness	No shortness

Table 11: Initial kinesiological examination – Muscle Length test (17;25)

3.3.10 Strength test according to Kendall:

	left	right
- Supinator and biceps:	- 5	- 3+
- Coracobrachialis:	- 5	- 3+
- Biceps brachii and brachialis:	- 5	- 3+
- Deltoid: anterior/posterior	- 5/5	- 3/3
- Pectoralis major lower fibers:	- 5	- 4-
- Pectoralis minor:	- 5	- 4-
- Latissimus dorsi:	- 5	- X
- Medial rotators:	- 5	- 4
- Teres minor:	- 5	- X
- Rhomboids and levator scapulae:	- 5	- 4-
- Serratus anterior:	- 5	- 3
- Triceps brachi	- 5	- 4-
- Supraspinatus	- 5	- 3+
- Teres major	- 5	- x
- Trapezius (middle fibers)	- 5	- x
- Upper trapezius	- 5	- 4+

Table 12: Initial kinesiological examination – Muscle Strength test (17)

Due to contraindicated external and internal rotation, it was not possible to test the latissimus dorsi, teres minor, teres major and mid portion of trapezius muscle.

3.3.11 Fascia examination by Lewit

- Neck area: restricted in both longitudinal axis (right/left)
- Thoracic: no restriction in dorsoventral direction. The upper trunk is restricted among its respective axis.
- Lumbar: restricted in caudal direction and laterally
- Lateral trunk: not able to perform on the right side. Left: slight restriction felt in craniocaudal direction, the end feel is still elastic.
- Upper extremity: arms and forearms fascia are not restricted. Slight limitation around the injured shoulder.
- Scar (on the right shoulder): slight restriction in all directions, but it does not cause limitations to surrounding soft tissues.

3.3.12 Joint play examination

- Spine: upper thoracic restricted (when springing)
- SI joint: left side blocked in ventrodorsal direction
- Acromioclavicular: there is a blockage on the right side in both directions: craniocaudal and ventrodorsal.
- Sternoclavicular: right side blockage
- Scapulothoracic: enhances muscle spasms, restricted the rotatory motion
- First rib: restricted on both sides
- Cervical spine: we can observe that during the flexion, the main movement happens in the cervicothoracic junction. The passive rotation on both sides is slightly restricted, soft end barrier felt, the movement is slightly restricted probably due to the fascia tightness, in the whole neck and upper trunk area.
- Atlantooccipital joint; free

3.3.13 Anthropometrics upper extremity

	LEFT	RIGHT
Width biacromial	32	32
Width bicristal	16	16
Width bispinal	37	37
Width bitrochanter	54	54
Whole arm	72	68
Humerus	31	30
Forearm	42	42
Hand	18	17
Circumference arm	27.5	25.5
Circumference forearm	24	23

Table 13: Initial kinesiological examination – Anthropometric measurements

3.3.14 Breathing stereotype

- Supine: abdominal breathing
- Standing: lower thoracic breathing

3.3.15 Two scale test

Negative, 50% load each lower extremity.

3.3.16 Neurological Examination

	Right	Left
C5 (biceps reflex)	Normal	Normal
C6 (radial reflex)	Normal	Normal
C7 (triceps reflex)	Normal	Normal
C8 (finger jerk)	Normal	Normal

Table 14: Initial kinesiological examination – Deep tendon reflexes

Dermatome	Right	Left
C4	Normal	Normal
C5	Normal	Normal
C6	Normal	Normal
C7	Normal	Normal
C8	Normal	Normal
Th1	Normal	Normal

Table 15: Initial kinesiological examination – Superficial sensation

3.3.17 Conclusion

In conclusion, the right shoulder's post-operative state shows a local global hypotrophy and weakness (right serratus anterior and deltoid). Compared to the contralateral side, the right scapula is elevated, and the medial border is more pronounced. On the contrary, both (in particular the right side) upper trapezius and levator scapulae are hypertonic and shortened.

From a structural point of view, the patient does not show any structural spinal deformity (e.g. scoliosis). An increased thoracic kyphosis is observed and is associated with left shoulder elevation, bilateral marked shoulder protraction (Cf. "static postural examination") and local paravertebral hypertonicity (Cf. "palpation").

From a functional point of view, first rib, acromio-clavicular, scapulo-thoracic joints play is restricted on the right side.

The trunk later shape appears more concave on the left side compared to the contralateral. This is associated with the left quadratus lumborum hypertonus and fascia restriction (caudal and lateral) (Cf. "palpation" and "fascia examination by Lewit").

The final dynamic result of the whole clinical picture can be observed in a wrong shoulder abduction pattern, showing an early activation of the right upper trapezius (and levator scapulae) combined with the trunk left side bending.

I would like to remind that she is a high-level rugby player, which explains the overuse and suspected hypertonicity of upper trapezius.

3.4 Short-term rehabilitation plan

- Decrease pain felt in right shoulder
- Fascia release
- Decrease hypertonicity
- Elongate shortened muscles
- Strengthening (focus on scapula stabilizers)
- Maintain ROM
- Joint play restoration
- Education on correct abduction pattern and gait

3.5 Long-term rehabilitation plan

- Maintain the goals of short-term rehabilitation plan
- Correct abduction pattern
- Strengthening of scapula stabilizers on both shoulders, to prevent any luxation on the left side.
- Improve external rotation, restore all range of motion on all plans and axis.
- Reintegrate shoulder into her rugby trainings
- Maintain the goals of short-term rehabilitation plan

3.6 Day to day therapies

3.6.1 First therapeutic unit (20.01.2020)

The patient came to the therapy for the first time. The initial kinesiology examination was performed, which took the length of most of the session.

Subjective: The patient is excited to start the rehabilitation process. She feels very weakened with restricted range of motion. She doesn't complain about any limitation in her ADL. She also says that she had to wear orthotics for her shoulder but felt better without it. She uses them in public transport but not at home.

Objective: In first sight, her physical condition is remarkable for her age (16 years old), she has a typical rugby player prototype; hypertonicity is found around the upper trapezius zone and most of the back area (especially in the lumbar fascia). Most importantly, the wrong shoulder abduction pattern is observed with weakened scapula stabilizers.

Goal of today's therapeutic unit:

- provide anamnesis and initial kinesiological examination
- educate the patient on self-scar therapy

Therapy proposal:

- Neck massage to release muscle tension around upper trapezius and levator scapulae.
- Scar therapy

Procedures:

Cf. Initial kinesiology examination

Massage of upper trapezius and levator scapulae on both sides.

Scar therapy (S-Shape and C-Shape), the patient was instructed about the self-therapy.

Subjective results: Cf. Initial kinesiology examination

The patient was enthusiastic about starting the physiotherapy treatments. She feels that her right shoulder is very weakened and is impatient to regain full strength.

Objective results: Decreased neck tension with visible hyperaemia.

Observations: The patient is already overusing her shoulder trying to regain full mobility and strength. Therefore, we have decided to focus on the scapula stabilizer's strengthening and to slow the rehabilitation process by avoiding working on the range of motion gain. I could not apply much therapy today, as the initial kinesiological examination took the whole session time. She was also instructed how to self-massage her scar on the right shoulder, she was already aware of it, the scar is in a very good condition, not restricting any surrounding.

Self-therapy: Scar therapy (S-shape and C-shape), after showering and before going to bed minimum.

3.6.2 Second therapeutic unit (22.01.2020) – 5 weeks after surgery

Subjective: J.D. felt a “nice release” around her neck after previous session. She stills complain about her weakened shoulder and is very enthusiastic to start the therapies and strengthening.

Objective: The hypertonicity around the neck area is still noticeable, despite previous therapy. It is a point to be worked on to allow more mobility in the whole shoulder complex, including neck and back. I would like to control the existing range of motion and start strengthening scapula stabilizers without involving any further range of motion. It is important to reduce the pace of physical activity, as the patient is already pushing herself too much.

Goal of today's therapeutic unit:

- Relaxation of hypertonic muscles
- Release of trigger points
- Maintain present range of motion, control active range of motion
- Strengthening of scapula stabilizers
- Scar cicatrisation (PT)
- Scar therapy

Therapy proposal:

- Hydrotherapy: whirlpool – 38°C ; duration : 15 minutes, whole body application.
- PIR of:
 - o Upper trapezius
 - o Levator Scapulae
 - o Scalenes
- STT: trigger point release on:
 - o Right SCM
 - o Upper trapezius bilaterally
 - o Levator Scapulae bilaterally
 - o Right Pectoralis major
 - o Right Latissimus dorsi
- ARoM and PRoM into flexion, extension and abduction of the arm, for muscle activation. PRoM may be performed with slight traction to prepare the joint for exercising.
- STT: scar therapy
- Physical exercising on scapula stabilizers
- Magnetotherapy

Procedures:

- 1) As the doctor's indications: the patient underwent some thermotherapy for 15 minutes in whirlpool at 30 degrees temperature. We are looking for an optimal relaxation of the whole body before starting the manual techniques.
- 2) Scar therapy (S-shape and C-shape). We again controlled the quality of the scar which is very good. The daily self-therapy on the scar is enough.
- 3) PIR of upper trapezius.
- 4) PIR of levator scapulae using Sachse's method. The patient is supine with the shoulder of the treated side fixed, her neck is passively brought into anteflexion and side-bending to the opposite side until tension is felt. She is then asked to look towards the side of tensed muscle, breath in, hold her breath, then breath out by relaxing totally. We repeated this sequence 3 times on both sides.
- 5) PIR of scalenes.
- 6) Trigger point release on respective muscles.
- 7) ARoM and PRoM: the patient is asked to actively perform FLX, EXT and ABD. She is then brought to do it passively, with a very slight traction of humerus. The traction is followed with rotatory motion "8 Shape" in the aim of stimulating joint receptors for better result once exercising.
- 8) Physical exercise:
 - ARoM against resistance: she is asked to perform isometric contractions against resistance in direction of abduction, flexion and extension.
 - Ball press against the wall. The patient is facing the wall, knees slightly bent aligned with knees and hip. Activation of deep stabilization system, not allowing opening of rib cage (coactivation of oblique, transverse and rectus abdominis). Small ball on the wall, patient is pressing with one hand (flexed shoulder), shoulder is down, no overuse of upper trapezius. She is asked to perform draw a small "o" on the wall, then a "8". Hold for 10 seconds and repeat the sequence until she shows some compensation signs.
- 9) Magnetotherapy:
 - Low frequency pulsed magnetic therapy
 - Intensity: 12 mT
 - Frequency: 10 Hz
 - Repetitions: 2 times a week

- Duration: 25 minutes
- Application: Flat application on the posterior side of the right shoulder, patient is supine.

Subjective results: The patient fully tolerated the therapy. She is complaining of weakness and gets tired quickly. Slight discomfort is felt when performing active range of motion against resistance.

Objective results: The hypertonicity of the scalenes and levator scapulae has decreased after applying PIR. The effect of PIR on the upper trapezius is slightly noticeable. Trigger point release was effective upon the right SCM, pectoralis major and latissimus dorsi but not on the levator scapulae and upper trapezius.

She is in a particularly good physical condition and already very educated about the re-education process. The scar is in a good condition, no sign of inflammation, either discomfort upon palpation, or roughness. As stated previously, her active range of motion is already very advanced and responds very well to all manual techniques.

Self-therapy:

- Scar therapy
- PIR of upper trapezius and levator scapulae: gravity induced PIR (according to Lewit). The patient is instructed to sit on a low back chair, put her arms down behind and let them hang. She then has to look up, raise her shoulders, breath in and hold, then breath out and relax her shoulders letting go. The procedure must be repeated 3 times or more, until she feels a release.
- Continue the press ball exercise, preferably in front of a mirror in order to visually control her own posture.

3.6.3 Third therapeutic unit (24.01.2020)

Subjective: The patient felt muscle fatigue hours after previous session.

Objective: Upon palpation, hypertonicity is found in the neck region with trigger points in upper trapezius bilaterally with a slight shortness of upper trapezius and levator scapulae (right side). There are also Trps findings in the right pectoralis major and latissimus dorsi. Restricted joint play in right acromioclavicular joint (in craniocaudal and ventrodorsal direction), right sternoclavicular joint and bilateral first rib.

As it was not tested during the initial kinesiological examination, we briefly examined the deep stabilization system by performing the hip extension test according to Prof. Kolář. There is no sign of clinical disturbances, correct activation of ischiocrural muscles, spinal extensors and lateral abdominal muscles. We also screened her DSS assessing the activity of deep stabilizers in supine position, 90 degrees flexion in the hip and knees, with a slight external rotation in both hips, shoulder flexed to 90 degrees with both hand palms facing each other, centered scapula. Even though it is correct, I would like to implement it in the strengthening of the shoulder complex in order to integrate the whole muscle chain and work on a more global picture.

Goal of today's therapeutic unit:

- Release of hypertonic muscles
- Lengthening of shortened muscles
- Release of trigger points
- Maintain range of motion
- Mobilization of restricted joint play
- Strengthening of whole upper extremity and shoulder girdle
- Strengthening and education about deep stabilization system

Therapy proposal:

- Combined PIR with stretching of:
 - o Upper trapezius
 - o Levator Scapulae (stretching component to be applied only on the right side)
 - o Scalenes (Only PIR)
- STT: trigger point release on:
 - o Pectoralis major
 - o Latissimus dorsi
- ARoM and PRoM
- Mobilization on:
 - o Acromioclavicular joint (dx)
 - o Sternoclavicular (dx)
 - o First ribs (bilateral)
- 1st flexion and extension PNF of upper extremity (on the right side)

- PNF on scapula:
 - Anterior elevation – serratus anterior
 - Posterior Depression – latissimus dorsi and rhomboids
 - Anterior Depression – pectoralis major and minor
 - Posterior Elevation – trapezius
- Scapula and shoulder muscles strengthening

Procedures:

- 1) PIR of upper trapezius, levator scapulae and scalenes. The respective techniques are the same as described in previous therapeutic unit (22.01.2020). For the upper trapezius and right levator scapulae, once the barrier was reached, we increased the tension into a stretch. The procedure was repeated 3 times for each muscle.
- 2) STT: trigger point release on:
 - Pectoralis major – the Trp was found upon palpation on the middle fibers of pectoralis major (coming from sternal head). Sustained pinch grip was performed on the trigger point until release was felt.
 - Latissimus Dorsi – Trp was found proximal to the insertion. Same method was applied as pectoralis major
- 3) ARoM and PRoM: the patient is asked to actively perform FLX, EXT and ABD. She was then brought to do it passively, combined with a slight traction of glenohumeral joint.
- 4) Mobilization of:
 - Acromioclavicular joint – patient is supine, fixation is made by holding the head of humerus and by the contact of the table on the shoulder blade. The thenar eminence is placed on her right clavicle, we take up the slack, then gently perform dorsoventral springing against acromion. Gentle springing is repeated until the release is felt. We then performed springing in craniocaudal direction by fixing her right bent elbow and places other hand's thenar eminence on the lateral end of right clavicle. The springing is repetitive without increasing pressure of both holdings.
 - Sternoclavicular – method of crossed hands, according to Lewit. The patient is supine, we place one pisiform against medial end of clavicle and the other on the sternal manubrium, we then perform springing into distraction.

- First ribs (bilateral) – we used the technique according to Lewit by isometric rhythmic contraction of the scalenes.
- 5) 1st flexion of upper extremity (PNF)
 - 6) 1st extension of upper extremity (PNF)
 - 7) Scapula PNF:
 - Anterior elevation
 - Posterior depression
 - Anterior depression
 - Posterior elevation
 - 8) Physical activity:
 - ARoM against resistance: she is asked to perform isometric contractions against resistance in direction of abduction, flexion and extension.
 - Ball press against the wall as described in previous session.
 - Stabilization exercise supine with big ball in between hands and knees: press knee and hands in diagonal successively, maintaining “shoulders down” and not allowing an increased lordosis neither rise of rib cage.
 - Stabilization exercise supine with big ball in between hands and knees: same position but no diagonal pattern, isometric contraction. The patient closes her eyes and tries to keep the position despite external stimulus coming from the therapist. This comes in the idea of adding a proprioceptive component, on top of working with the DSS.

Subjective results: She fully tolerated the therapy without pain.

Objective results: The mobilization of acromioclavicular and sternoclavicular joint was effective, whilst the mobilization of first ribs according to Lewit’s method wasn’t. It leads me to the idea of improving the hypertonicity on the SCM and scalenes in the next session.

Self-therapy:

- Continue with the scar therapy.
- Gravity induced PIR of levator scapulae, upper trapezius and scalenes, 3 repetitions.
- Stretching of upper trapezius and levator scapulae.
- Exercising:

- Start with supine position exercises, isometric press with closed eyes (hold 10 seconds), then combine “diagonal pressing” left/right (5 times). Repeat the session 3 times minimum. It is important to stop if she is losing the focus in holding the correct posture (coactivation of abdominal muscles and not letting the rib cage rise).
- Ball press exercise on the wall standing up.

3.6.4 Fourth therapeutic unit (27.01.2020)

Subjective: J.D. feels great, she didn’t feel any discomfort after exercising. She has been following the self-therapy plan as indicated.

Objective: The hypertonicity around the levator scapulae is not decreasing, among this I palpate a Trp on the origin of levator scapulae, around superior angle of right scapula. No major hypertonicity felt neither shortness of SCM nor scalenes, it seems that the self-therapy was effective. I would like to incorporate the global picture of the patient by releasing the whole back, it is important due to the poor mobility of upper extremity in the gait, it has created fascial restriction around the low back and joint play restriction on the thoracic spine. The Kibler fold test showed a restriction in the lumbar zone, which confirms the restriction on top of the initial kinesiological examination.

We would also like to start incorporating the activation of external rotators in the strengthening part. We are trying to settle a strengthening program by repeating sequences from the previous sessions and gradually add new exercises each time, for the patient to integrate a whole program by the end of the period.

Goal of today’s therapeutic unit:

- Restore normal mobility of all restricted back fascia
- Release of Trps
- Mobilization of restricted joints
- Release of hypertonic muscles
- Activation of external rotators
- Scar healing (magnetotherapy)

Therapy proposal:

- Hydrotherapy: whirlpool – 38°C ; duration : 15 minutes, whole body application.

- Back massage
- Shifting of deep fascia of the back, thorax and neck
- Trp release by sustained application pressure
- PIR of scalenes and SCM
- Mobilization of first ribs (bilateral)
- Mobilization of thoracic spine
- Cervical traction
- Strengthening, follow up to date procedure adding activation of external rotators in excentric.
- Magnetotherapy

Procedures:

- 1) As the doctor's indications: the patient underwent some thermotherapy for 15 minutes in whirlpool at 30 degrees temperature. We are looking for an optimal relaxation of the whole body before starting the manual techniques.
- 2) Back massage: the patient was prone. Around both quadratus lumborum areas, I applied the stretch of connective tissue fold according to Lewit, by creating a fold until tension was felt, turning into stretching respective area, then hold and wait for release. Also, sustained pressure was directly applied on quadratus lumborum, involving the use of my elbows to go into depth. Still in prone position, I continued the massage up to the cranial trapezius.
- 3) Shifting of deep lumbar fascia in caudal and cranial direction (dorsal fascia)
- 4) Crossed-hands technique on thoracic spine for mobilization. Starting from Th12 progressively moving into cranial direction, we spring each vertebra by placing one pisiform on the transverse process of the lower vertebra and the other pisiform on the transverse process of the upper vertebra.
- 5) Now in supine position, massage of deep neck extensors. Followed by a slight traction of cervical spine.
- 6) PIR of SCM
- 7) Sustained pressure on Trp found on levator scapulae.
- 8) First ribs mobilization bilaterally by repetitive isometric contraction of the scalenes
- 9) ARoM and PRoM with slight glenohumeral traction.

10) Mobilization of scapulothoracic articulation, in order to prepare the shoulder complex to strengthening

11) Exercising:

- Same sequence
- All four position
- Start of excentric external rotators strengthening (starting from umbilicus to 10 degrees of external rotation)
- Theraband exercises: rowing exercise in front of the mirror

12) Magnetotherapy:

- Low frequency pulsed magnetic therapy
- Intensity: 12 mT
- Frequency: 10 Hz
- Repetitions: 2 times a week
- Duration: 25 minutes
- Application: Flat application on the posterior side of the right shoulder, patient is supine.

Subjective results: The patient fully tolerated the therapy. She is a bit afraid of starting the isometric contraction of external rotators.

Objective results: She adapts very well and is very responsive. There is no compensatory mechanism when activating external rotators. The shoulder girdle is centrated and nice coactivation of muscles. The mobilization on the thoracic spine was effective, we can observe a greater curve during the dynamic spine examination. First ribs mobilization was also successful.

Self-therapy:

- Scar therapy
- Release with a tennis ball: she was instructed how to lean on the wall with a tennis ball in order to search for any Trp or tender points, any stiffness felt, then massage it with the tennis ball.
- Self PIR levator scapulae, upper trapezius, scalenes following a gentle stretch
- Exercising:
 - Start with supine position exercises, isometric press with closed eyes (hold 10 seconds), then combine “diagonal pressing” left/right (5 times). Repeat

the session 3 times minimum. It is important to stop if she is losing the focus in holding the correct posture (coactivation of abdominal muscles and not letting the rib cage rise).

- Turn into all four position, hold 15 seconds and relax, 4 series.
- Ball press exercise on the wall standing up.
- Rowing exercise with theraband

3.65. Fifth therapeutic unit (29.01.2020) – 6 weeks after surgery

Subjective: J.D. claims to feel more confident and have raised more “awareness” towards her right shoulder.

Objective: There is a noticeable improvement concerning the patient’s global hypertonicity around the shoulders and upper trunk. There is still a persisting Trp on the upper angle of right scapula. Her neck’s range of motion is smoother and claims to feel less tense. Concerning her shoulder abduction pattern, no sign of winging scapula neither compensation coming from upper trapezius. Testing her all four position, she can maintain the correct posture, but we can notice a difference with the left side, being worse than the right side. There is a slight winging of the left scapula. Even if it is minimal, it is an indicator that the rehabilitation of the operated shoulder is going well. I would like to control the movement pattern of the left shoulder on the strengthening program.

Goal of today’s therapeutic unit:

- Mobilization of the scapulothoracic joint
- Strengthening of scapula’s stabilizers and RC.
- Scar healing (magnetotherapy)
- Whole back release (hydrotherapy)

Therapy proposal:

- Hydrotherapy: whirlpool – 38°C ; duration : 15 minutes, whole body application.
- PRoM of both upper extremity with slight glenohumeral traction
- Scapulothoracic mobilization
- PNF of UE, 1st flexion and extension, within the existing range of motion.
- Strengthening program
- Magnetotherapy for the scar healing

Procedures:

- 1) As the doctor's indications: the patient underwent some thermotherapy for 15 minutes in whirlpool at 30 degrees temperature. We are looking for an optimal relaxation of the whole body before starting the manual techniques.
- 2) ARoM and PRoM in FLX, ABD, horizontal ADD.
- 3) Mobilization of scapulothoracic joint with the patient side lying position
- 4) PNF of scapula in all directions
- 5) PNF UE 1st flexion and extension
- 6) Strengthening program (repetition of previous exercises) + add external rotators activation: from total ADD to 0 degree + simulation of PNF diagonal with theraband (fixation from a low bar)
- 7) Magnetotherapy:
 - Low frequency pulsed magnetic therapy
 - Intensity: 12 mT
 - Frequency: 10 Hz
 - Repetitions: 2 times a week
 - Duration: 25 minutes
 - Application: Flat application on the posterior side of the right shoulder, patient is supine.

Subjective results: The therapy was fully tolerated, painless. She feels a slight stretch on the posterior pars of deltoid muscle and triceps when performing horizontal ADD. She isn't aware of the wrong positioning of the left scapula.

Objective results: The scapulothoracic joint mobilization doesn't enhance muscle spasms, as it used to do in the first therapeutic session. The patient is very responsive to the therapy and I can see her improvement with the strength and centralization of scapula. The ratio between left and right in exercising needs to be settled as 2:1.

Self-therapy:

- Scar therapy
- Release with a tennis ball

- Exercising:
 - Start with supine position exercises, isometric press with closed eyes (hold 10 seconds), then combine “diagonal pressing” left/right (5 times). Repeat the session 3 times minimum. It is important to stop if she is losing the focus in holding the correct posture (coactivation of abdominal muscles and not letting the rib cage rise).
 - Turn into all four position, hold 15 seconds and relax, 4 series.
 - Ball press exercise on the wall standing up.
 - Rowing exercise with theraband
 - External rotators exercise from total adduction to 0 degree external rotation
- Stretching of upper trapezius and levator scapulae.

3.6.6 Sixth therapeutic unit (31.01.2020)

Subjective: She has been working on the external rotation exercise and doesn't feel any restrictive matter. She claims feeling much more confident in her ADL and is very pleased about it.

Objective: Hypertonicity is found on the thorax and axilla region – there would be necessary to release all concerned muscles: pectoralis major and minor, latissimus dorsi, teres major, subscapularis, coracobrachialis, long head of biceps brachii.

Goal of today's therapeutic unit:

- Release hypertonic muscles
- Joint play of glenohumeral joint
- Strengthening of scapular muscles, rotator cuff, train the external rotation up to 15 degrees with 0 degree of abduction.

Therapy proposal:

- Axillary massage
- Thorax fascia release
- PIR of:
 - Biceps brachii
 - Pectoralis major
 - Latissimus dorsi
- Traction of glenohumeral joint + PRoM

- PNF scapula and UE.
- Usual Strengthening program, progressively adding to the external rotation exercise an extra 15 degrees.

Procedures:

- 1) ARoM and PRoM with slight glenohumeral traction.
- 2) PIR of:
 - Biceps brachii:
 - Pectoralis major:
 - Latissimus dorsi:
- 3) Axillary massage: with sustained pressure on latissimus dorsi and pectoralis major, performing the pincer grip.
- 4) Thorax fascia shifting
- 5) 1st flexion of upper extremity PNF
- 6) Scapula PNF in all directions, both sides.
- 7) Strengthening program:
 - All four position knees touching the ground: use of posturomed. She first finds the correct positioning with opened eyes, then closed eyes. She has to make little circles with both upper extremities keeping the correct all-four positioning.
 - All four position on the ground without the knees touching, closed eyes.
 - Theraband exercise: from total adduction to 10 degrees external rotation. We first did it without the theraband in order to check if there is any painful restrictions (which we want to avoid). Then we added slight resistance with the theraband, once 5 degrees reached, she loosens a little the tension on the theraband in order to reach the 10 degrees, then 15. Once 15 degrees reached, she is asked to hold the position with very slight resistance. Come back to total adduction in excentric.

Subjective results: Fully tolerated the therapy. She is happy about the results that are being noticed. She felt tired after all the exercising.

Objective results: She is very responsive to the therapy. I notice the difference in the strength by comparing the ability to “hold” given position during the PNF diagonal and resist again all external stimuli.

Self-therapy:

- Continue previous exercises.
- Stretch and self PIR of upper trapezius and levator scapulae.
- Stretch of pectoralis major

3.6.7 Seventh therapeutic unit (03.02.2020)

Subjective: patient doesn't have any complaints about her shoulder. She has been training the external rotation with Theraband and didn't feel any restriction.

Objective: After testing her external rotation, I see improvement in the quality of movement. Upon palpation, there is a remaining trigger point on the right levator scapulae, on the superior angle of scapula. Global hypertonicity around the neck region is still present. Fascia is restricted in all direction.

Goal of today's therapeutic unit:

- Control and feedback of ongoing therapies
- Release hypertonic muscles

Therapy proposal:

- Release of neck fascia
- Massage of the neck
- Trigger point release
- PIR of upper trapezius and levator scapulae
- Strengthening program: continue working on external rotators strengthening and scapula stabilizers.

Procedures:

- 1) As the doctor's indications: the patient underwent some thermotherapy for 15 minutes in whirlpool at 30 degrees temperature. We are looking for an optimal relaxation of the whole body before starting the manual techniques.
- 2) Neck fascia release: patient is in sitting position, apply pressure on fascia with one hand, reach barrier and wait for release. The other hand is fixing.
- 3) Neck massage with emphasis on cranial trapezius.
- 4) Trigger point release: sustained pressure on trigger point until release if felt
- 5) PIR of upper trapezius and levator scapulae.
- 6) Physical activity:

- Supine position, developmental positioning. Same procedure as previous therapies.
- Ball press on the wall with closed eyes and external stimulus.
- Ball press in between hands with 90 degrees flexion on the elbow, maintain that position and flex shoulder to 90 degrees and back, all the time sustaining pressure on the small ball.
- 1st flexion diagonal simulation in standing position with theraband fixed from the floor
- External rotation exercise to 15 degrees, excentric contraction.
- All four position on posturomed, maintain 5 seconds without knees touching the floor.

7) Magnetotherapy:

- Low frequency pulsed magnetic therapy
- Intensity: 12 mT
- Frequency: 10 Hz
- Repetitions: 2 times a week
- Duration: 25 minutes
- Application: Flat application on the posterior side of the right shoulder, patient is supine.

Subjective results: She is very pleased with the therapies and prescribed exercises as they are a little demanding.

Objective results: The results of exercising are showing their effect: the scapula is centralized without any sign of winging. Meanwhile on the contralateral shoulder, we can observe a slight scapula winging still which has to be corrected in the long-term plan in order to prevent any further injury once she will be back in rugby games. The trigger point on levator scapulae is recurrent, the therapy on it is momentaneous effective but after a few hours it becomes recurring.

Self-therapy:

- Integrate all physical exercises that have been done and repeated until today.
- Stretch of upper trapezius and pectoral muscles
- PIR of upper trapezius, levator scapulae, pectoralis major
- Auto massage with tennis ball on neck region

3.7 Final kinesiological examination

3.7.1 Static Postural examination

- Anterior view: The feet are symmetrical, with an appropriate arch on both. The femur and knees are in appropriate alignment, symmetrical axis. Very slight deviation of umbilicus to the right. The right clavicle is shorter than the left. The shoulders are protracted without any big difference on shoulder height. The head is centered, following the spinal axis.
- Posterior view: No asymmetry in the foot or ankle, nor on the popliteal line. We can observe an asymmetry on the SIPS the left being higher. The lateral curvature of the trunk is asymmetrical, the left side being slightly more concave than the right. The lower angle is not dominant neither the medial edge of right scapula, but I can see that when she loses focus on the examination, it tends to go back into slight external rotation with upward rotation.
- Lateral view (left): The feet, knees and hip are in correct alignment. Shoulders are protracted accentuating the thoracic kyphotic curve. Neck and head are also slightly protracted.
- Lateral view (right): The atrophy around the deltoid region has diminished. The shoulders remain protracted with the neck and head.

3.7.2 Dynamic Spine examination

The patient can perform all movement (flexion, extension, latero-flexion) without any pain, nor restricted range of movement.

3.7.3 Passive and Active Range of Motion

SHOULDER	Left		Right	
	AROM	PROM	AROM	PROM
Flexion	180	180	165	170
Extension	45	60	30	35
ABD	170	180	160	170
External rotation	85	90	30	45
Internal rotation	70	90	- *	- *

* this testing is not relevant, as it resumes the shoulder position when the patient was immobilized (90 degrees of flexion in the elbow, and internal rotation, bringing the forearm to the trunk).

Table 16: Final kinesiological examination – AROM and PROM

The external rotation was tested in sitting position with 15 degrees abduction in the shoulder.

The internal rotation was tested in sitting position with 90 degrees flexion at the elbow, it should be then considered that the patient had full range of motion on the right side, in this testing variation. The left side has been tested in supine position with 90 degrees of abduction and 90 degrees flexion at the elbow.

Neck: there are no restricted motion (we tested flexion, extension, rotation and side bending, actively and passively). She herself feels freer.

3.7.4 Active RoM against resistance

- No pain felt neither restriction when performing AROM against resistance on the left side neither on the right side.

3.7.5 Movement pattern according to Janda

Shoulder abduction:

- Right: The synchronicity of activated muscles has considerably improved. However, when the patient reaches around 85 degrees approximately, there is an overuse of cranial trapezius. It remains minimal compared to the initial assessment. No contralateral latero-flexion of the trunk.
- Left: The synchronicity of activated muscles is much better. We can mention that there is still a prominent activity on the upper trapezius, but it is minimal.

Neck flexion: As in the first assessment, we primarily observe a dominance of sternocleidomastoid resulting in the head protraction when flexing the neck. But after verbal correction, the patient was able to flex the neck provoking a continuous arch, activating her deep neck flexors, without any sternocleidomastoid dominance, neither deviations.

3.7.6 Gait Examination

The knee and hip are in correct alignment. She tends to externally rotate the hip. We can still observe the protraction of shoulders. The trunk rotation has decreased, as she is making use of her upper extremities (arm swinging).

3.7.7 Palpation

	Left	right
Trapezius upper/lower/middle	Hypertone	Hypertone
SCM	Normal	Normal
Scaleni	Normal	Normal
Levator Scapulae	Hypertone	Hypertone
Pectoralis major	Hypertone	Hypertone
Pectoralis minor	Hypertone	Hypertone
Supraspinatus	Normal	Normal
Infraspinatus	Normal	Normal
Rhomboid minor/major	Normal	Normal
Latissimus dorsi	Normal	Hypertone
Teres major	Normal	Normal
Teres minor	Normal	Normal
Deltoid	Normal	Normal
Biceps	Normal	Normal
Triceps	Normal	Normal
Paravertebrals	Hypertone thoracic zone	Hypertone thoracic zone
Quadratus Lumborum	Hypertone	Hypertone

Table 17: Final kinesiological examination – Muscle palpation

Sternocostal articulations: Not painful

Acromioclavicular: Not painful

Sternoclavicular: Not painful

3.7.8 Pelvis Examination

ASIS: same level

PSIS: left higher

Crest: same level

3.7.9 Length test according to Janda and Kendall

	LEFT	RIGHT
Pectoralis major upper (Kendall)	normal	normal
Pectoralis major lower	normal	normal
Pectoralis minor (Kendall)	Slight	slight
Teres major, lat. Dorsi, Rhomboids (Kendall)	0	slight
Cranial trapezius	0	0
Levator scapulae	0	0
SCM (kendall)	No shortness	No shortness
Scaleni (kendall)	No shortness	No shortness

Table 18: Final kinesiological examination – Muscle Length test (17;25)

3.7.10 Strength test according to Kendall:

	Left	Right
Supinator and biceps:	5	3+
Coracobrachialis:	5	3+
Biceps brachii and brachialis:	5	3+
Deltoid: anterior/posterior	5/5	3+/3+
Pectoralis major lower fibers:	5	4+
Pectoralis minor:	5	4+
Latisimus dorsi:	5	4
Medial rotators:	5	4
Teres minor:	5	X
Rhomboids and levator scapulae:	5	4
Serratus anterior:	5	3+
Triceps brachi	5	4-
Supraspinatus	5	4-
Teres major	5	x
Trapezius (middle fibers)	5	3+
Upper trapezius	5	4+

Table 19: Final kinesiological examination – Muscle strength test (17)

Teres major could not be tested due to the internal rotation and extension of shoulder which was not advised to realize.

3.7.11 Fascia examination by Lewit

- Neck area: no restriction in both longitudinal axis (right/left).
- Thoracic: no restriction in dorsoventral direction.
- Lumbar: restricted in caudal direction and laterally
- Lateral trunk: there is a slight restriction felt in craniocaudal direction on both sides, the end feel is still elastic.
- Upper extremity: arms and forearms fascia are not restricted. The limitation encountered in the initial assessment is gone. However, we can sense a slight restriction around the levator scapulae zone on the right side.
- Scar (on the right shoulder): slight restriction in all directions, but it does not cause limitations to surrounding soft tissues.

3.7.12 Joint play examination

- Spine: not restricted (springing)
- SI joint: left side blocked in ventrodorsal direction
- Acromioclavicular: free in craniocaudal and ventrodorsal direction
- Sternoclavicular: free
- Scapulothoracic: free, no more presence of muscle spasm
- First rib: free
- Cervical spine: we can observe that during the flexion, the main movement happens in the cervicothoracic junction. The passive rotation on both sides is not restricted with a soft-end barrier felt.
- Atlantooccipital joint; free

3.7.13 Anthropometrics upper extremity

	LEFT	RIGHT
Width biacromial	32	32
Width bicristal	16	16
Width bispinal	37	37
Width bitrochanter	54	54
Whole arm	72	68
Humerus	31	30
Forearm	42	42
Hand	18	17
Circumference arm	27.5	26
Circumference forearm	24	23

Table 20: Final kinesiological examination – Anthropometric measurements

3.7.14 Breathing stereotype

Supine: abdominal breathing

Standing: lower thoracic breathing

3.7.15 Two scale test

Negative, 50% load each lower extremity.

3.7.16 Neurological Examination

	Right	Left
C5 (biceps reflex)	Normal	Normal
C6 (radial reflex)	Normal	Normal
C7 (triceps reflex)	Normal	Normal
C8 (finger jerk)	Normal	Normal

Table 21: Final kinesiological examination – Deep tendon reflexes

Dermatome	Right	Left
C4	Normal	Normal
C5	Normal	Normal
C6	Normal	Normal
C7	Normal	Normal
C8	Normal	Normal
Th1	Normal	Normal

Table 22: Final kinesiological examination – Superficial sensation

3.7.17 All-four positioning:

This have not been tested initially but she is now able to do it and is necessary to evaluate the scapula positioning.

The patient has no sign of winging scapula on the right side.

3.7.18 Conclusion of final kinesiological examination:

The range of motion has considerably improved in ARoM and PRoM.

	ARoM	PRoM
Flexion	+ 50 degrees	+50 degrees
Extension	+20 degrees	35 degrees*
ABD	+70 degrees	+80 degrees
External rotation	+25 degrees	45 degrees*
Internal rotation	-	-

*The parameters have not been tested in the first assessment due to contraindication and pain.

Table 23: Range of motion gain in the right shoulder

The table above shows a considerable improvement.

The static postural examination shows us that her right scapula is more centrated. This is due to the muscle strengthening, but it needs more time before the scapula will fully acquire this change. It is noticeable because the scapula slightly returns to its initial external and upward rotation once she loses focus on her posture.

Concerning abduction movement pattern, no overuse of cranial trapezius neither latero-flexion on the contralateral side of the trunk is observed. We can conclude that she has gain a correct shoulder abduction pattern, which was one of the main goals of the session. The shoulder stabilizers have strengthened (Cf. “Strength test according to Kendall”), which is noticed in the scapula motion during abduction as well as all-four positioning, no sign of winging scapula. All this have led to the patient being more confident with her upper extremity, leading to an improved gait as she is now allowing her arm to swing, diminishing the compensation by trunk rotation.

The hypertonicity of the patient has mostly decreased (Cf. “Palpation”), but a remaining hypertonicity is noticed on the upper trapezius and levator scapulae area. There the joint play is not restricted anymore. We must remind that she has been playing rugby for 13 years now, which should be an explanation for this persistent hypertonicity. However, it has still decrease compared to the initial assessment, but not enough.

3.8 Evaluation of effectiveness of therapy

The following tables are in the aim to compare the most significant results during the time spent with the patient.

<i>Motion</i>	<i>Active/Passive RoM initial</i>	<i>Active/Passive RoM final</i>
Flexion	115/120	165/170
Extension	10/ -	30/35
Abduction	90/90	160/170
External rotation	5/ -	30/45
Internal rotation	-/-	-/-

Table 24: RoM changes in the right shoulder – Comparative table

Muscle:	Right initial	Right final
Deltoid: anterior/posterior	3/3	3+/3+
Pectoralis major lower fibers:	4-	4+
Pectoralis minor:	4-	4+
Latisimus dorsi:	-	4
Rhomboids and levator scapulae:	4-	4
Serratus anterior:	3	3+
Supraspinatus	3+	4-
Trapezius (middle fibers)	-	3+

Table 25: Muscle strength changes on the right side – Comparative table

Initial	Final
<p><u>Joint play:</u></p> <p>Restriction on:</p> <ul style="list-style-type: none"> - Upper thoracic vertebrae - Right Acromioclavicular and sternoclavicular - Scapulothoracic provokes muscle spasms - First rib bilaterally - Cervical spine passive RoM in rotation is restricted due to overall fascia tension 	<p><u>Joint play:</u></p> <ul style="list-style-type: none"> - Spine: not restricted (springing) - Acromioclavicular: free - Sternoclavicular: free - Scapulothoracic: free, no more presence of muscle spasm - First rib: free - Cervical spine: The passive rotation on both sides is not restricted with a soft-end barrier felt.
<p><u>Palpation:</u></p> <p>Hypertonicity is found on:</p> <ul style="list-style-type: none"> - Bilaterally: Trapezius, Scaleni, Levator Scapulae, Pectoralis major and minor, latissimus dorsi, biceps brachii, paravertebrals and quadratus lumborum. - Left: supraspinatus - Right: teres major <p>Hypotonicity is found only on the right side:</p> <ul style="list-style-type: none"> - Supraspinatus - Infraspinatus - Teres minor - Deltoid (all portions) - Triceps brachii 	<p><u>Palpation:</u></p> <p>Considerable improvement on all cited muscles, except:</p> <ul style="list-style-type: none"> - Upper trapezius - Levator Scapulae - Pectoralis major and minor - Right latissimus dorsi - Paravertebrals - Quadratus Lumborum <p>All cited above remain hypertonic.</p> <p>However, there is no remaining hypotonicity.</p>
<p><u>Muscle length:</u></p> <p>Left: slight shortness on pectoralis major and minor, cranial trapezius.</p> <p>Right: slight shortness on pectoralis minor, cranial trapezius and levator scapulae.</p>	<p><u>Muscle length:</u></p> <p>Left: pectoralis major and cranial trapezius have no shortness.</p> <p>Right: Cranial trapezius and levator are not shortened.</p>

<p><u>Fascia:</u></p> <ul style="list-style-type: none"> - Neck area: restricted in both longitudinal axis (right/left) - Thoracic: no restriction in dorsoventral direction. The upper trunk is restricted among it's respective axis. - Lumbar: restricted in caudal direction and laterally - Lateral trunk: not able to perform on the right side. Left: slight restriction felt in craniocaudal direction, the end feel is still elastic. - Upper extremity: arms and forearms fascia aren't restricted. Slight limitation around the injured shoulder. - Scar (on the right shoulder): slight restriction in all directions, but it doesn't cause limitations to surrounding soft tissues. 	<p><u>Fascia:</u></p> <ul style="list-style-type: none"> - Neck area: no restriction in both longitudinal axis (right/left). - Upper extremity: The limitation encountered in the initial assessment around the injured shoulder is gone.
<p><u>Shoulder abduction movement pattern:</u></p> <ul style="list-style-type: none"> - Right: Altered movement. There is a clear overuse of the cranial part of the trapezius, which results in a shoulder elevation. We can also observe a slight latero-flexion on the contralateral side of the trunk. The neck slightly rotates to the right during the abduction followed by a very small rotation of upper trunk towards the same side. 	<p><u>Shoulder abduction movement pattern:</u></p> <ul style="list-style-type: none"> - Right: The synchronicity of activated muscles has considerably improved. No overuse of cranial trapezius up to 85 degrees, where she starts to compensate with upper trapezius and contralateral trunk side bending.

Table 26: Comparative table between initial and final kinesiological examination

After 7 therapeutic units, the improvement of the patient is remarkable. We encountered no difficulties neither any complications during these sessions, the only restriction faced was muscle fatigue. This muscle fatigue was expected due to the loss of muscle strength during the 5 weeks of immobilization after surgery.

The patient started the therapies with restricted range of motion and loss of muscle strength. Looking at the comparative table of RoM, we can see that there is a considerable improvement in flexion, abduction, and external rotation. We have worked a lot on strengthening, and the patient have strictly followed the indications for self-therapy. Therefore, such improvements. I would like to remind that we have decided to not focus on the gain of RoM, but on the strengthening of scapula stabilizers. The reason is that the patient is young, very enthusiastic about getting back to her sport, and she has the tendency of pushing herself beyond the norm, which might result in a worst condition than initial. As mentioned previously, rugby is a contact sport with a high rate of shoulder injuries, especially shoulder dislocation, the players need to have an excellent scapular stability.

Concerning the overall tonicity, we have not achieved to reach the physiological tonicity on upper trapezius neither levator scapulae, despite the attempts of relaxation. In this case, I would say the therapy was not effective. The techniques used were not enough, these included: PIR, stretching, soft tissue technique, massage, deep fascia shifting and whirlpool. This recurrent hypertonicity led me to the thought of possible reactive changes in respective fascia, due to the recurrent dislocations that she has encountered. Her protracted shoulders could also possibly be part of the results of the reactive changes. There for, I suggest that approaching the patient on a global picture, improving her posture should also reduce this recurrent hypertonicity, on a long-term vision.

The general posture of the patient is also to be improved, as she remains with protracted shoulders with shortness of pectoralis minor, this follows by a slight protracted neck and head, even though it is less than initially. Coming back to the goals of short-term rehabilitation plan, we can say that the therapies were effective, as we have achieved most of them.

In conclusion, the therapy has reached its effectiveness in terms of range of motion, strength, and pain. However, I think that it could be improved by working more on the global picture of the patient. Being a rugby player, it is normal to find this recurring

hypertonicity on the upper trapezius zone and these have no major negative effect on the rehabilitation of shoulder. Again, it is important to keep these in terms of prevention once she will be back on the fields as soon as it does not become pathological.

Prognosis:

I strongly believe that the patient will regain her full RoM and strength without any difficulties, hence be able to pursue her ADL. However, I remain doubtful on her future in contact sports, because of her injury history and her young age. She has to remain patient about returning to the rugby practices and games, until her shoulder dynamic stabilizers will be in an impeccable state. She must continue her strengthening program on both shoulders to prevent recurrent instability.

4. Conclusion

During these four weeks at C.L.P.A, I had the opportunity to work with several types of patient in the common gym room or in the ambulance room of my supervisor, Mgr. Martina Damborova. This have improved my practical skills, especially in strengthening, relaxation and mobilization techniques, but most importantly, time management.

The communication between the patient and I was excellent, and her motivation was incredible. She was strictly following every instruction concerning the self-therapies, which helped a lot in her evolution. I would have liked to have more sessions with her, to be able to work on a more global picture and incorporate specific conditioning for her future in rugby. However, in parallel, I was in charge of another patient of the same age, same diagnosis, and also a rugby player, but in a much-advanced post-operative stage. There, we have implemented a lot of exercising incorporating rugby drills, which was remarkably interesting and fun. Being able to work with two patients with the same diagnostic but in different stages was great and allowed me to understand the post-operative treatment in more depth, on a longer picture.

Finally, I chose to work on a shoulder pathology because, before the work placement, I felt that I was lacking knowledge in such body segment. This was a great opportunity to improve my theoretical and practical knowledge about the shoulder complex.

5. Bibliography

1. Antunes, J. P., Mendes, A., Prado, M. H., Moro, O. P., & Miró, R. L. (2016). Arthroscopic Bankart repair for recurrent shoulder instability: a retrospective study of 86 cases. *Journal of orthopaedics*, 13(2), 95-99.
2. Atef, A., El-Tantawy, A., Gad, H., & Hefeda, M. (2016). Prevalence of associated injuries after anterior shoulder dislocation: a prospective study. *International orthopaedics*, 40(3), 519-524
3. Bushnell BD, Creighton, R.A., & Herring, M.M. Bony instability of the shoulder. *J Arthroscopy and Related Surgery*. 2008;24(9):1061-1073.
4. Carrazzone, O. L., Tamaoki, M. J. S., Ambra, L. F. M., Neto, N. A., Matsumoto, M. H., & Belloti, J. C. (2011). prevalence of lesions associated with traumatic recurrent shoulder dislocation. *Revista Brasileira de Ortopedia (English Edition)*, 46(3), 281-287.
5. Cetik O, Uslu M, Ozsar BK. The relationship between Hill-Sachs lesion and recurrent anterior shoulder dislocation. *Acta orthopaedica belgica* 2007;73(2):175-8.
6. Dal Maso, F., Raison, M., Lundberg, A., Arndt, A., Allard, P., & Begon, M. (2015). Glenohumeral translations during range-of-motion movements, activities of daily living, and sports activities in healthy participants. *Clinical Biomechanics*, 30(9), 1002-1007.
7. DeFroda, S., Bokshan, S., Stern, E., Sullivan, K., & Owens, B. D. (2017). Arthroscopic Bankart repair for the management of anterior shoulder instability: indications and outcomes. *Current reviews in musculoskeletal medicine*, 10(4), 442-451.
8. Douoguih, Wiemi. (2005). Treatment of traumatic anterior shoulder instability in the contact and collision athlete. *Current Opinion in Orthopaedics*, 16(2), 82-88.
9. Faria, L., Campos, B., & Jorge, R. N. (2017). Biomechanics of the shoulder girdle: a case study on the effects of union rugby tackles. *Acta of bioengineering and biomechanics*, 19(3).
10. Flatow EL, Warner JJP. Instructional Course Lectures, The American Academy of Orthopaedic Surgeons — Instability of the shoulder: complex problems and failed repairs. Part I. Relevant biomechanics, multidirectional instability, and severe loss of glenoid and humeral bone. *J Bone Joint Surg Am* 1998;80:122–140.

11. Galvin, J. W., Ernat, J. J., Waterman, B. R., Stadecker, M. J., & Parada, S. A. (2017). The epidemiology and natural history of anterior shoulder instability. *Current reviews in musculoskeletal medicine*, 10(4), 411-424
12. Gilroy, A., MacPherson, B., Ross, L., Voll, M., & Wesker, K. *Atlas of anatomy* (2nd ed.).
13. Guity, M. R., Akhlaghpour, S., & Yousefian, R. (2014). Determination of prevalence of glenoid bony lesions after recurrent anterior shoulder dislocation using the 3-D CT scan. *Medical journal of the Islamic Republic of Iran*, 28, 20.
14. Hall, S. (2014). *Basic biomechanics*. McGraw-Hill Higher Education.
15. Helgeson, K., & Stoneman, P. (2014). Shoulder injuries in rugby players: Mechanisms, examination, and rehabilitation. *Physical Therapy in Sport*, 15(4), 218-227.
16. Kapandji, I. A. (1971). The physiology of the joints, volume I, upper limb. *American Journal of Physical Medicine & Rehabilitation*, 50(2), 96.
17. Kendall, F. (2005). *Muscles, testing and functions with posture and pain* (5th ed.). Baltimore, MD: Lippincott Williams & Wilkins.
18. Kolář, P., & Andelova, V. (2013). *Clinical rehabilitation*. Prague: Rehabilitation Prague School.
19. Lewit, K. (2009). *Manipulative therapy: Musculoskeletal medicine*. Elsevier Health Sciences.
20. Lippert, L., 2006. *Clinical Kinesiology And Anatomy*. 4th ed. Philadelphia: Davis Company, F.A.
21. Loh, B., Lim, J. B. T., & Tan, A. H. C. (2016). Is clinical evaluation alone sufficient for the diagnosis of a Bankart lesion without the use of magnetic resonance imaging?. *Annals of translational medicine*, 4(21).
22. Myers, T. (2011). *Anatomy trains* (2nd ed.). Edinburgh: Elsevier.
23. Nho SJ, Frank RM, Van Thiel GS, Wang FC, Wang VM, Provencher MT, et al. A biomechanical analysis of anterior Bankart repair using suture anchors. *Am J Sports Med*. 2010;38(7):1405–12. Available from: <http://www.ncbi.nlm.nih.gov/pubmed/20360604>
24. Omoumi P, Teixeira P, Lecouvet F, Chung CB. Glenohumeral joint instability. *Journal of Magnetic Resonance Imaging* 2011;33(1):2-16.

25. Page, P., Frank, C., & Lardner, R. (2014). *Assessment and treatment of muscle imbalance*. Champaign, IL: Human Kinetics.
26. Papalia, R., Tecame, A., Torre, G., Narbona, P., Maffulli, N., & Denaro, V. (2015). Rugby and shoulder trauma: a systematic review. *Translational medicine@ UniSa*, 12, 5.
27. Provencher MT, Frank RM, LeClere LE, Metzger PD, Ryu JJ, Bernhardson A, Romeo AA. The Hill-Sachs lesion: diagnosis, classification, and management. *Journal of the American Academy of Orthopaedic Surgeons* 2012;20(4):242-52.
28. Schenkman, M., & Rugo de Cartaya, V. (1987). Kinesiology of the shoulder complex. *Journal of Orthopaedic & Sports Physical Therapy*, 8(9), 438-450
29. Sobotta, J., Paulsen, F., & Waschke, J. (2011). *Sobotta Atlas of human anatomy* (15th ed.). München: Elsevier.
30. Struyf F, Nijs, J., Baeyens, J.P., Mottram, S., Meeusen, R. Scapular positioning and movement in unimpaired shoulders, shoulder impingement syndrome, and glenohumeral instability. *Scandinavian Journal of Medicine and Science in Sports*. 2011;20(3):352-358.
31. Thigpen, C. A., Padua, D. A., Michener, L. A., Guskiewicz, K., Giuliani, C., Keener, J. D., & Stergiou, N. (2010). Head and shoulder posture affect scapular mechanics and muscle activity in overhead tasks. *Journal of Electromyography and kinesiology*, 20(4), 701-709.
32. Wang RY, Arciero RA, and Mazzocca AD. The recognition and treatment of first-time shoulder dislocation in active individuals. *JOSPT*. 2009;39(2):118-123
33. Widjaja A, Tran A, Bailey M, Proper S (2006). Correlation between Bankart and Hill-Sachs lesions in anterior shoulder dislocation. *ANZ J Surg* 76 (6): 436–8.
34. Wilk, K. E., Macrina, L. C., & Reinold, M. M. (2006). Non-operative rehabilitation for traumatic and atraumatic glenohumeral instability. *North American journal of sports physical therapy: NAJSPT*, 1(1), 16.
35. Zhao KD, Van Straaten, M.G., Cloud, B.A., Morrow, M.M., An, K-N., & Ludewig, P.M. Scapulothoracic and glenohumeral kinematics during daily tasks in users of manual wheelchairs. *Frontiers in Bioengineering and Biotechnology*. 2015;3:183-193.

6. Supplements

6.1 Abbreviations

ABD	Abduction
ADD	Adduction
ADL	Activity of Daily Living
ARoM	Active Range of Motion
BMI	Body Mass Index
DSS	Deep Stabilization System
EXT	Extension
FLX	Flexion
GH	Glenohumeral
H-S	Hill-Sachs
MRI	Magnetic Resonance Imaging
PIR	Post Isometric Relaxation
PNF	Proprioceptive Neuromuscular Facilitation
PRoM	Passive Range of Motion
PT	Physical Therapy
RoM	Range of Motion
SCM	Sternocleidomastoid
STT	Soft Tissue Technique
TrP	Trigger point
UE	Upper Extremity

6.2 List of figures

Figure 1: Superior and Inferior view of the clavicle (20).....	10
Figure 2: The scapula and anatomical landmarks; post., lat. and ant. view (29).....	12
Figure 3: Ant. view of humeral bone and sup. view of the humeral head (34)	13
Figure 4: The acromioclavicular and coracoclavicular ligaments (29)	14
Figure 5: The shoulder joint according to Sobotta (29).....	15
Figure 6: Rotator cuff muscles insertion according to Sobotta (29).....	17
Figure 7: Brachial Plexus according to Sobotta. (29).....	24
Figure 8: Dermatomes of the upper extremity, anterior and posterior view (29).....	24
Figure 9: Cutaneous nerves of the upper extremity, ventral and dorsal view (29).....	25
Figure 10: Shoulder girdle movement and range of motion according to Kolář (8)	26
Figure 11: Diagram of the rotator muscles of the arm, according to Kapandji (16)	28
Figure 12: Movements of the scapula according to Lippert (20).	29
Figure 13: Scapulohumeral rhythm, according to Kolář (18).....	30
Figure 14: Action of scapular muscles according to Hall (14).....	32
Figure 15: Muscular force couple producing upward rotation of the scapula (20).	34
Figure 16: Typical rugby tackle (personal file)	35
Figure 17: “Arm tackling”, retrieved from article 15	36
Figure 18: Diagram of glenohumeral ligaments in relation to the glenoid labrum and joint capsule (24).....	37
Figure 19: Diagram of Bankart lesion. (24).....	38
Figure 20: MRA of Hill-Sachs lesion (27)	40
Figure 21: Arthroscopic view of a repaired Bankart lesion – 3 suture anchors (7).....	44

6.3 List of tables

Table 1: Scapula’s anatomical landmarks.	11
Table 2: Glenohumeral ligaments and characteristics	16

Table 3: Intrinsic muscle group of the shoulder	18
Table 4: Extrinsic muscle group of the shoulder	19
Table 5:“Secondary movers” group of the shoulder.....	21
Table 6: Phases of flexion and abduction according to Kapandji (16).....	27
Table 7: Relation between the shoulder joint and girdle motion, Lippert (20).....	30
Table 8: Results summary of Widjaja et al. (2006)	41
Table 9: Initial kinesiological examination – ARoM and PRoM.....	51
Table 10: Initial kinesiological examination – Muscle Palpation.....	53
Table 11: Initial kinesiological examination – Muscle Length test (17;25).....	54
Table 12: Initial kinesiological examination – Muscle Strength test (17).....	55
Table 13: Initial kinesiological examination – Anthropometric measurements.....	57
Table 14: Initial kinesiological examination – Deep tendon reflexes	58
Table 15: Initial kinesiological examination – Superficial sensation.....	58
Table 16: Final kinesiological examination – ARoM and PRoM	78
Table 17: Final kinesiological examination – Muscle palpation	80
Table 18: Final kinesiological examination – Muscle Length test (17;25)	81
Table 19: Final kinesiological examination – Muscle strength test (17).....	82
Table 20: Final kinesiological examination – Anthropometric measurements	84
Table 21: Final kinesiological examination – Deep tendon reflexes.....	85
Table 22: Final kinesiological examination – Superficial sensation	85
Table 23: Range of motion gain in the right shoulder	86
Table 24: RoM changes in the right shoulder – Comparative table	87
Table 25: Muscle strength changes on the right side – Comparative table	87
Table 26: Comparative table between initial and final kinesiological examination.....	89

6.4 Ethics Committee Agreement

CHARLES UNIVERSITY
FACULTY OF PHYSICAL EDUCATION AND SPORT
Josef Martího 31, 162 52 Prague 6-Vešelavín

Application for Approval by UK FTVS Ethics Committee

of a research project, thesis, dissertation or seminar work involving human subjects

The title of a project: Case study: Rehabilitation after anterior Bankart surgery.

Project form: Bachelor thesis

Period of realization of the project: January 2020 to February 2020

Applicant: Desiree Ginger Bertron-Simpson, UK FTVS, physiotherapy department

Main researcher: Bertron-Simpson Desiree Ginger, UK FTVS, physiotherapy department

Workplace: C.L.P.A., Prague, Czech Republic.

Supervisor: Mgr. Michaela Stupkova

Project description: The project is to conduct the rehabilitation process after Bankart surgery, due to shoulder instability. It is a case study involving one patient of 16 years old, female. The project is to implement the physiotherapy rehabilitation of the patient aiming to functionally regain full range of motion and strength of shoulder. Parents will be informed about the procedure and must sign a consensus form. The therapy will be led under the doctor's indications.

Characteristics of participants in the research: The participants of this project are mainly the patient who is a female, 16 years old, and me. She already underwent physiotherapy treatment and is a high-level athlete, competing internationally. The subject is registered in the hospital with a valid health-check. It is not her first-time attending therapies in the clinic.

Ensuring safety within the research: The research will not put anyone at risk. Any kind of hazardous episode will always be avoided. Participant will be constantly supervised, and the therapies will strictly follow the doctor's contraindications. All the therapies will be conducted under the supervision of Mgr. Martina Damborova. I declare that there will be no use of invasive methods. Risks of therapy and methods will not be higher than the commonly anticipated risks for this type of therapy.

Ethical aspects of the research: The participant is 16 years old, therefore the consensus of the parents and the person itself is of crucial importance.

The collected data will be anonymized within one week after the end of working with the patient. I understand that anonymization means that the text does not use any item of information or combination of items that could lead to the identification of a person. I will be careful not to enable recognition of a person in the text of the thesis, especially within the anamnesis. After the text has been anonymized, any personal data still kept elsewhere will be deleted.

Photographs of the participant will be anonymized within one week after being taken by blurring the face, parts of the body or any characteristics that could lead to identification of the person. After anonymization any non-anonymized photographs will be deleted.

All collected data will be safely stored on a PC safeguarded by a keyword in a locked room, any data in paper form will be kept safely under lock and key in a locked room. The data will be processed, safely retained and published in an anonymous way in the bachelor thesis.

I shall ensure to the maximum extent possible that the research data will not be misused.

Informed Consent: Will be attached, used and explained to the subject and her parents.

It is the duty of all participants of the research team to protect life, health, dignity, integrity, the right to self-determination, privacy and protection of the personal data of all research subjects, and to undertake all possible precautions. Responsibility for the protection of all research subjects lies on the researcher(s) and not on the research subjects themselves, even if they gave their consent to participation in the research. All participants of the research team must take into consideration ethical, legal and regulative norms and standards of research involving human subjects applicable not only in the Czech Republic but also internationally.

I confirm that this project description corresponds to the plan of the project and, in case of any change, especially of the methods used in the project, I will inform the UK FTVS Ethics Committee, which may require a re-submission of the application form.

In Prague, 28.01.20

Applicant's signature

Approval of UK FTVS Ethics Committee

The Committee: Chair:

doc. PhDr. Irena Parry Martinková, Ph.D.

Members:

prof. PhDr. Pavel Slepíčka, DrSc.

prof. MUDr. Jan Heller, CSc.

PhDr. Pavel Hráský, Ph.D.

Mgr. Eva Prokešová, Ph.D.

MUDr. Simona Majorová

The research project was approved by UK FTVS Ethics Committee under the registration number: 057/2020

Date of approval: 4.2.2020

UK FTVS Ethics Committee (UK FTVS) submitted research project and found no contradictions with valid principles, regulations and international guidelines for carrying out research involving human subjects.

The applicant has met the necessary requirements for receiving approval of UK FTVS Ethics Committee.

Josef Martího 31, 162 52, Prague

- 20 -
Stamp of UK FTVS

Signature of the Chair of
UK FTVS Ethics Committee

6.5 Informed consent

INFORMOVANÝ SOUHLAS

Vážená paní, vážený pane,

v souladu se Všeobecnou deklarací lidských práv, zákonem č. 101/2000 Sb., o ochraně osobních údajů a o změně některých zákonů, ve znění pozdějších předpisů, Helsinskou deklarací, přijatou 18. Světovým zdravotnickým shromážděním v roce 1964 ve znění pozdějších změn (Fortaleza, Brazílie, 2013) a dalšími obecně závaznými právními předpisy Vás žádám o souhlas s prezentováním a uveřejněním výsledků vyšetření a průběhu terapie prováděné v rámci praxe na, kde Vás příslušně kvalifikovaná osoba seznámila s Vaším vyšetřením a následnou terapií. Výsledky Vašeho vyšetření a průběh Vaší terapie bude publikován v rámci bakalářské práce na UK FTVS, s názvem

Získané údaje, fotodokumentace, průběh a výsledky terapie budou uveřejněny v bakalářské práci v anonymizované podobě. Osobní data nebudou uvedena a budou uchována v anonymní podobě. V maximální možné míře zabezpečím, aby získaná data nebyla zneužita.

Jméno a příjmení řešitele
Podpis:.....

Jméno a příjmení osoby, která provedla poučení.....
Podpis:.....

Prohlašuji a svým níže uvedeným vlastnoručním podpisem potvrzuji, že dobrovolně souhlasím s prezentováním a uveřejněním výsledků vyšetření a průběhu terapie ve výše uvedené bakalářské práci, a že mi osoba, která provedla poučení, osobně vše podrobně vysvětlila, a že jsem měl(a) možnost si řádně a v dostatečném čase zvážit všechny relevantní informace, zeptat se na vše podstatné a že jsem dostal(a) jasné a srozumitelné odpovědi na své dotazy. Byl(a) jsem poučen(a) o právu odmítnout prezentování a uveřejnění výsledků vyšetření a průběhu terapie v bakalářské práci nebo svůj souhlas kdykoli odvolat bez represí, a to písemně zasláním Etické komisi UK FTVS, která bude následně informovat řešitele.

Místo, datum

Jméno a příjmení pacienta..... Podpis pacienta:.....

Jméno a příjmení zákonného zástupce

Vztah zákonného zástupce k pacientoviPodpis: