CHARLES UNIVERSITY

Faculty of Physical Education and Sports

Department of Physiotherapy

Rehabilitation of infraclavicular brachial plexus injury and proximal humeral fracture after surgical repair

Bachelor Thesis

Supervisor:
PhDr. Tereza Nováková

Author:
Øyvind Humlen

Prague, 2018

Abstract

"Rehabilitation of infraclavicular brachial plexus injury and proximal humeral fracture after surgical repair"

Careful preoperative evaluation, surgical timing, selected strategies of nerve reconstruction and early and prolonged rehabilitation are of great importance in the influence of producing the most positive outcome for this type of traumatic injury. Encompassed in the thesis are the theoretical and practical aspects of a case study about a patient receiving rehabilitation treatment after surgical repair of multiple structures of the right upper limb. The injuries comprise open fracture of the proximal humerus, lesion to the terminal branches of the brachial plexus and a post-surgical complication with infection of collision wounds of the forearm. In the theoretical part I will attempt to describe the value of different surgical techniques, considerations of nerve reconstruction strategies and rehabilitation program, which all affect treatment outcomes. The case study is based on clinical work performed at Oblastní Nemocnice Kladno during the time period of 15.01.18 – 26.01.18. The subject of study is an 18-year-old man who is hospitalized for the second time with indications of continuous rehabilitation after surgical repair of the brachial plexus dated 11.01.2017.

This thesis is divided into two separate sections. The initial section describes general upper limb anatomy and biomechanics, peripheral nervous system anatomy, pathophysiology of traumatic injury to peripheral nerves, surgical procedures and intention of the postoperative rehabilitation program. The general section is preceded by a case study in which consists of anamnesis, initial kinesiological examination, therapy, and final examination/evaluation.

The main goal of the therapy approach for this patient was to preserve range of motion and trophicity in the plegic forearm, impose physiological stressors securing normal healing of the humeral fracture and improve function of the innervated sensory and motor tissue of the brachial plexus affected by trauma and surgical repair. The methods used in the therapy for this case study was mainly manual techniques, active exercising and electro stimulation. No invasive methods were used.

There was a positive outcome of the applied therapy program. Both active and passive joint range of motion as well as strength grades significantly increased at the affected shoulder. However, no more than minimal improvement could be seen in elbow flexion,

clearly indicating that full function of the right hand had yet to be restored by the end of the last therapy session. Palsy of the distal affected extremity was still present by the end of the treatment period.

Key words: High-energy trauma, infraclavicular brachial plexus injury, proximal humeral fracture, neurorehabilitation.

Dates of the practice: 15.01.18-26.01.18

Location of Case Study: Oblastní Nemocnice Kladno, Vančurova 1548, Kladno - 272 59, Czech Republic.

Abstrakt

"Rehabilitace infraklavikulárního poranění brachiálního plexu a zlomeniny proximálního humeru po chirurgickém řešení"

Předoperační vyšetření, vybrané chirurgické strategie rekonstrukce nervu a časná a následná rehabilitace mají velký vliv na výsledek tohoto typu traumatického poškození. Součástí práce jsou teoretické a praktické aspekty případové studie pacienta, který byl v rehabilitační léčbě po chirurgickém řešení porušených struktur pravé horní končetiny. Zranění zahrnují otevřenou zlomeninu proximálního humeru, lézi koncové větve brachiálního plexu a post-chirurgickou komplikaci s infekcí ran z předloktí. V teoretické části jsou popsány různé chirurgické techniky, úvahy o strategiích rekonstrukce nervů a rehabilitačním programu, které všechny ovlivňují výsledky léčby. Případová studie vychází z klinické práce prováděné v Oblastní Nemocnici Kladno v období od 15.01.18 do 26.01.18. Předmětem kazuistiky je 18letý muž, který je podruhé hospitalizován s indikací intenzivní rehabilitace po chirurgické sutuře brachiálního plexu ze dne 11.01.2017.

Tato práce je rozdělena do dvou samostatných částí. Úvodní část popisuje obecnou anatomii a biomechaniku horních končetin, anatomii periferního nervového systému, patofyziologii traumatického poškození periferních nervů, chirurgické postupy a záměr pooperačního rehabilitačního programu. Speciální část popisuje případovou studii, která se skládá z anamnézy, počátečního kineziologického vyšetření, průběhu terapie a závěrečného vyšetření / hodnocení.

Hlavním cílem terapie tohoto pacienta bylo zachování rozsahu pohybu a troficity a zlepšení funkce inervované senzorické a motorické tkáně brachiálního plexu postiženého traumatem. Metody použité v terapii pro tuto případovou studii byly především manuální techniky, aktivní cvičení a elektrostimulace. Nebyly použity žádné invazivní metody.

Výsledek aplikovaného terapeutického programu byl pozitivní. Jak rozsah aktivního, tak i pasivního kloubního pohybu, stejně jako svalová síla v obalsti postiženého ramene. Nicméně v pohybu do flexe v loketním kloubu nebylo došlo jen minimální zlepšení.

Klíčová slova: traumata s vysokou energií, poranění infiklavikulárního brachiálního plexu, zlomenina proximálního humeru, neurorehabilitace.

Termíny praxe: 15.01.18-26.01.18

Umístění případové studie: Oblastní Nemocnice Kladno, Vančurova 1548, Kladno - 272 59, Česká republika.

Declaration

In this thesis I present a body of research assembled from books, journals and articles, knowledge obtained during lectures at FTVS and learning during clinical practice. Whenever contributions are involved, attention is made in order to illustrate this clearly, with due reference to the literature and acknowledgement of collaborative research and discussions.

I also declare that no invasive methods were used during the treatment sessions and that the patient was fully aware of the procedures at any given time.

The work was performed and completed under the guidance of PhDr. Tereza Nováková, and under the supervision of Mgr. Ilona Kučerová and Bc. Tomás Modlinger, physiotherapists at Oblastní Nemocnice Kladno.

Øyvind Humlen

Prague, Mars 2018

Acknowledgments

I would like to thank Mgr. Ilona Kučerová and Bc. Tomás Modlinger at Oblastní Nemocnice Kladno for their time and eagerness to share valuable knowledge and experience in the field of rehabilitative therapy. Their comprehensive understanding and attention to detail greatly influenced my personal level of competence.

I would also like to thank my supervisor, PhDr. Tereza Nováková, for her insights and thoroughness in the process of writing and content organization, positively enhancing my potential and efforts during this extensive process.

I am grateful to my family, my girlfriend and my colleagues that have stood behind me. Their encouragement has been instrumental to me in order to finish my Bachelor's here at UKFTVS.

Table of contents

1 Introduction

Injury to peripheral nerves due to high-energy trauma is one of the more severe causes of disability today, and represents an important number of work-years lost for society (Taylor, Braza, Rize, & Dillingham, 2008; Wang, Inaba, Byerly, Escamilla, Cho, Carey, Stevanovic, Ghiassi, & Demetriades, 2016). It's estimated that the average cost of a single median nerve injury, including hospital costs and loss of production to be approximately US $61,500. Origins of the trauma may determine which nerves are affected, the kind of nerve damage and the prognosis for outcome (Taylor et al., 2008). But even when the different types of extremity trauma result in very specific damage to particular nerves associated with that location, the depth, severity and underlying structures involved are not always clear. Research has show that up to 5% of all patients admitted to a Level 1 trauma center have peripheral nerve injuries. A previous report showed that the most common nerve involvement in upper-limb trauma was the radial nerve, but this report did not include patients with nerve root, plexus, digital or any other minor nerve injury (Noble, Munro, Prasad & Midha, 1998).

The incident of a particular nerve injury commonly caused by traffic accidents, brachial plexus injuries, has steadily increased since the 1980s (Park, Lee, Kim & Chang, 2017). The brachial plexus is the intricate network of nerves originating in the cervical spine responsible for sensory innervation and movement control of the upper extremity (Hems, 2015). Damage to the brachial plexus can result from multiple reasons, including compression, stretch, or laceration. Compression damage may occur as a result of direct pressure from fractures of the proximal humerus, or more rarely, from the clavicle. Management of injuries to the brachial plexus depends largely upon classification either by anatomical location, etiology, or clinical presentation (Songcharoen, 2008). High-energy traumas may have catastrophic impact on function of the entire upper extremity (Saliba, Saliba, Pugh, Chhabra & Diduch, 2009). Appropriate diagnosis, surgical management, rehabilitation and counseling are therefore crucial to the overall outcome.

2 General part

2.1 Brief anatomy of the pectoral girdle and upper arm

2.1.1 Introduction

The upper limb acts as a powered, mobile, sensory organ exhibiting an exceptional range of movement, permitting wide positioning of the hand (Birch & Tunstall, 2016). Several factors enable this range. Powerful muscles both stabilize and move the thoracoscapular and glenohumeral joint, which both possess remarkably little constraints. The skin around the neck, axilla and across the joints is mobile, and the deep fascial planes and the synovial tubes permit excursion of tendons and muscles against one another. Condensation of fascia around the neurovascular bundles segregates them and enhances gliding against adjacent structures. The upper limb has rich and complex innervation, including concentrations of specialized sensory organelles in the wrist and hand. These are present not only in the skin, but lie also deep in the afferent system from muscles, tendons and joints.

Hand function is mainly enabled by differentiation of the upper limb in order to achieve complex stereotactic, non-stereotactic and gestural movements (Lambert, 2016). Transferring objects in the hand into the visual field is brought about by combined motions of the shoulder and elbow, while the great excursion of the pectoral girdle enable reaching into a broad external environment. According to Lambert (2016), the articulations of the upper extremity become increasingly complex proximodistally, with more potential for stability and subsequently less mobility.

2.1.2 Anatomical relationships

2.1.2.1 The pectoral girdle

An optimal and integrated motion of several joints is required for the function of the pectoral girdle (Ombregt, Bisschop & ter Veer, 2013). The term pectoral girdle is often used to discuss activities of the scapula and clavicle, and to a lesser degree, the sternum (Lynn, 2011). It forms the connection between the spine, the thorax and the upper limb, containing three primary articulations: the acromioclavicular joint, sternoclavicular joint and thoracoscapular-gliding surface. The lower cervical spine, the cervicothoracic junction and the upper thoracic spine act as secondary articulations tying the region together. According to Terry and Chopp (2000) it is important to remember that when discussing the pectoral girdle from the standpoint of its individual component structures, they function to produce shoulder movement together as a dynamic, interrelated unit.

2.1.2.2 The glenohumeral joint

The glenohumeral joint is a synovial ball-and-socket joint and constitutes the articulation between the relatively large head of the humerus and the much smaller glenoid fossa of the scapula (Carmichael & Hart, 1985). The articulation is in many ways a compromise between the need for motion and stability: both depend on the surrounding muscular and soft tissue envelope in a larger degree than its articulating surface area (Lambert, 2016). Despite the fact that only 25-30% of the humeral head is indeed in contact with the glenoid articulating surface, the normal shoulder constrains the humeral head within 1-2 mm of the center of the glenoid cavity throughout most of the arc of motion (Terry & Chopp, 2000). Both static (i.e. capsule, labrum, ligaments) and dynamic (muscles) stabilizers realize this precise constraint, producing a concavity compression effect directed towards the glenoid center. The subacromial, subcoracoid, and subdeltoid bursae are facilitating gliding in conjunction with the synovial lined cavities (Lambert, 2016).

The proximal humerus

The proximal humerus consist of a well-defined relationship between four parts, including the humeral head, the lesser and greater tuberosities and the proximal humeral shaft, and the neck-shaft inclination angle, measuring averagely 145 degrees in relation to the shaft (Schlegel & Hawkins, 1994). The proximal humerus arises from three ossification centers, creating a weakened area susceptible for fractures.

Passive mechanisms

In spite of the slightly flattened shape of the glenoid articular surface, the extension of the labrum creates a significant articular conformity with increased stability (Terry & Chopp, 2000). In addition to deepen the contact area, the labrum also provides anchor points for capsuloligamentous structures. The capsule normally fully seals the joint with approximately 1 mL of joint fluid and a slight negative intra-articular pressure. Further increase in stability is therefore enhanced by the suction effect created. Three glenohumeral ligaments act to limit and stabilize against translation in various directions.

Muscles

Movement occurring at the glenohumeral joint is mainly produced by scapulohumeral and thoracobrachial muscles, including the m. deltoid, m. pectoralis major, m. latissimus dorsi and m. coracobrachialis (Lambert, 2016). The rotor cuff group, consisting of the m. subscapularis, m. supraspinatus, m. infraspinatus and m. teres minor, counteracts and stabilizes the translating effect of the above-mentioned muscles. Generally, the distance between the origin of the muscle and the center of motion of the joint on which it acts, dictates whether its effect of stability or translation of joint surfaces are the greatest. The farther away it acts from, the greater is the effect of the resultant muscular vector on translation of the joint surfaces. On the other hand, the closer it lies, the greater is the effects of stability. The m. pectoralis major and m. deltoid create the largest forces on the distal shaft segment, while the rotator cuff group creates exert the highest deforming forces on the proximal segments, including the articular head and the lesser and greater tuberosities (Schlegel & Hawkins, 1994).

Fascia

The glenohumeral muscles are both attached and enveloped by fascia as this arrangement increases both effectiveness and efficiency (Lambert, 2016). The deep fascia varies greatly in thickness depending upon location and function. The deep fascia over the deltoid for example, is thick anteriorly and posteriorly, blending with the pectoral fascia in front and with the fascia overlying the supraspinatus behind. The pectoral fascia, in contrast, is thin over pectoralis major but thickens inferolaterally between the pectoralis minor and latissimus dorsi to form the axillary fascia. The deep fascia of the upper arm, the brachial fascia, forms a thin and loose covering for the anterior compartment of the arm, while the posterior compartment possess a more robust covering.

Skin

The great range of motion of the shoulder is also reflected in its skin mobility (Lambert, 2016). The skin over the anterior shoulder region is mobile, possessing large stretch potential. The skin over the posterior aspect however, is thicker and less mobile as its being held by coarse connective tissue fibres to the underlying scapula.

Dermatomes

The skin is divided into several areas named dermatomes, with each dermatomes being a skin area with nerve fibers carrying sensory information to its designated spinal root (Patel, 2015). Dermatome maps are generally inconsistent and present leads to areas of overlap between consecutive spinal nerves. Distribution to the skin in the upper extremity is mainly covered by C5 to T2; however, C3 and C4 dermatomes do cover a small area of the skin in the pectoral area. C5 generally innervates and covers the outer aspect of the arm from the shoulder to elbow, with C6 covering the outer part of the forearm. The inner and ulnar aspect of the arm is meanwhile covered by C7 and C8. T1 innervates the skin of the medial forearm and T2 covers the medial distance from the elbow to the upper arm.

Fig. 1. Dermatomes of the upper extremity, from Nerves and Nerve Injuries 2 by Tubbs et al., 2015

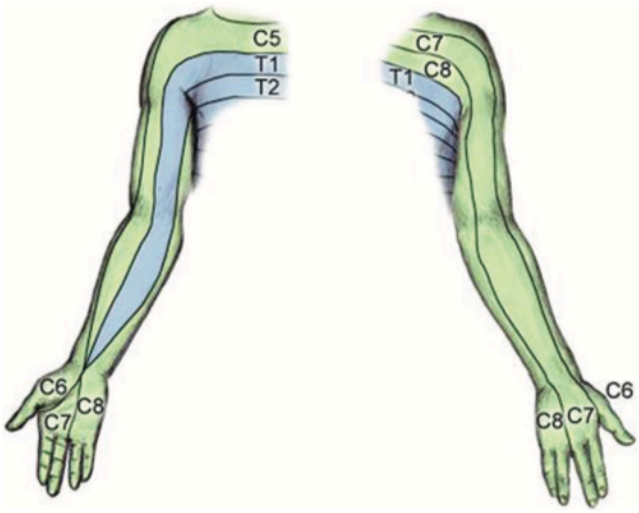

2.2 Kinesiology of the pectoral girdle and upper limb

2.2.1 Movement of the glenohumeral joint

The shoulder joint has three degrees of freedom, which permit movement of the upper limb with respect to three planes in space and the three major axes (Kapandji, 1982). The shoulder may therefore move about the transverse axis, the antero-posterior axis and the vertical axis. Movements of flexion and extension are performed in a sagittal plane; movements of abduction and adduction are performed in a frontal plane; and, movements of flexion and extension with the arm abducted to 90 degrees are performed in a horizontal plane.

Two distinct types of lateral and medial rotation can occur about the long axis; voluntary rotation, occurring only in ball-and-socket joints an depends on the third degree of freedom or; automatic rotation, occurring without voluntary movement in biaxial or triaxial joints when only two of the axes are in use. The movement of circumduction goes about all the three axes, and demarcates a spherical sector of accessibility, wherein the hand are free to move an grasp objects without displacement of the trunk. Due to the great size difference between the humeral head and the glenoid, simple rotation in the glenoid fossa would not be sufficient in terms of articular surface in order to produce extremity movement (Lynn, 2011). A motion combination consisting of glide, spin and roll keeps the humeral head centrated as the upper

extremity abducts. Lateral rotation during abduction is also required in order to produce full range of motion, as the greater tubercle is being rotated from under the acromion process.

2.2.2 Movement of the pectoral girdle

Normal movement of the scapula comprises three components of movement: upward/downward rotation around a horizontal axis perpendicular to the plane of the scapula; internal/external rotation around a vertical axis through the plane of the scapula, and; anterior/posterior tilt around a horizontal axis in the plane of the scapula (Roche, Funk, Sciascia & Kibler, 2015). These translatory motions can be expressed as protraction/retraction, elevation/depression or upward rotation/downward rotation with the clavicle acting as a strut connecting the scapula to the axial skeleton (Lynn, 2015; Kibler & Sciascia, 2009). Primary scapular stabilization and motion on the thorax involves force coupling of both the upper and lower part of the m. trapezius with the m. serratus anterior and the mm. rhomboids (Kibler & Sciascia, 2009). Secondary stabilization occurs through minor fixators like the m. pectoralis minor.

2.2.2.1 Coupled motions of the pectoral girdle and glenohumeral joint

Important functions in both dynamic and static settings are fulfilled by the scapula (Roche et al., 2015). In order to maintain the humerus centrated during motions of the arm, the scapula must be able to rotate in a synchronous manner and thereby maximizing concavity compression and ball-and-socket kinematics. This motion coupling is named scapulohumeral rhythm and requires dynamic stabilization by the scapular fixators and allows for maximal activation of the muscles originating on the scapula.

2.2.3 Scapular dyskinesis: an example of pathokinesiology

Scapular dyskinesis is a common clinical finding and denotes the loss of normal scapular motion control (Roche et al., 2015). It may or may not be related to previous injury or trauma,

and usually includes a clinical presentation consisting of a prominent inferomedial scapular border and early scapular motion during shoulder abduction. Scapular retraction is according to Kibler and Sciascia (2009) the one position that allows for optimal muscle activation of the shoulder joint muscles and constitutes an obligatory part of scapulohumeral rhythm in coupled shoulder motions. Intrinsic muscle pathology, lack of flexibility or inhibition of normal muscle activation account for some of the most common causative mechanisms of dyskinesis (Roche et al., 2015). A pull on the coracoid process is often created by shortness in either the short head of the m. biceps brachii or the m. pectoralis minor, resulting in an unfavorable protracted scapular position. Alterations in periarticular muscle activation may also cause dyskinesis, but regardless of causality, the final result in most cases denotes a loss of scapular retraction both in rest and motion.

2.3 Anatomy of the peripheral nervous system and brachial plexus

2.3.1 Peripheral nerve anatomy

The peripheral nerve is most generally made up from neural, vascular and connective tissue (Lee & Guyuron, 2015). The axon is the basic nerve unit and, depending on the type of peripheral nerve, it may be unmyelinated or myelinated, with a connective tissue sheet named endoneurium surrounding it. Axons with the same anatomical destination are then group into fascicles, having another connective tissue sheet called perineurium layering it. The fascicles get organized into bundles of monofascicular, oligofascicular and polyfascicular patterns, forming peripheral nerves. Each peripheral nerve is coated with a two-layered epineurium, the external and the internal. While the external layer provides an external connective tissue covering, the internal epineurium fills the space between individual fascicles within the nerve. In that way it cushions the bundles from outer compression. Vascular supply runs longitudinally in the epineurium, and sends transverse branches through the perineurium forming vascular networks consisting mainly of capillaries in the endoneurium (Campbell, 2008). Individual nerves vary greatly along the length of the nerve, and may contain different sizes of axons, and different numbers of motor, sensory and sympathetic fibers (Lee & Guyuron, 2015).

2.3.2 The peripheral nervous system

Communication between the central nervous system and peripheral receptors (sensory organs) or effectors (glands or muscles) is established by the peripheral nerves, made up by the cranial and spinal nerves (Varga & Mravec, 2015). One of the classifications of nerve fibers is their functional relation with the central nervous system. The direction of transmission of signals in relation to the central nervous system separates them into afferent and efferent divisions. The afferent fibers project information to the central nervous system, while the efferent ones send information to the periphery. Most nerves are mixed nerves and contain both sensory and motor fibers. As the nerve fibers course throughout the peripheral nerves, each individual nerve fiber axon displays different arrangements (Martinez-Pereira & Zancan, 2015).

The segmentation of the spinal cord is revealed by the origin of the spinal nerves (Martinez-Pereira & Zancan, 2015). They're equal in number, and the first pair of spinal nerves emerges from the spinal cord between the base of the skull and C1. There are eight pairs of cervical nerves, all situated cranially to their corresponding vertebrae, with the exception of the last, which emerge cranially at Th1. From Th1, all remaining spinal nerves are situated below their corresponding vertebrae. Nerves at the cervical and lumbar level are then organized in networks of enlargements and anastomosis of various nerve branches, forming neural plexuses. These neural plexuses are arranged into one large group of nerves and serve the same region of the body. Enlargements in the spinal cord called intumescences can also be found at the level of the plexuses. They´re characterized by an increased number of cells and nerve fibers due to the comprehensive innervation of the limbs.

2.3.3 The brachial plexus

From the base of the cranium and the inferior border of the mandible, the neck extends down to the superior thoracic outlet, which is the space bounded by the sternum, clavicle, first rib and the first thoracic vertebrae (Watkinson & Gleeson, 2016; Ombregt, Bisschop & ter Veer, 2013). It typically measures 10cm transversely and 5 cm anteroposteriorly, and forms the communicating area at the base of the neck for the passage of blood vessels and nerves from the mediastinum and neck to the axilla (Birch & Tunstall, 2016; Ombregt, Bisschop & ter Veer, 2013). According to Sanders (2013), there are three main anatomical spaces in the

thoracic outlet area: the scalene triangle lying above the clavicle; the pectoralis minor space below the clavicle and, the costoclavicular space between the clavicle and the first rib. The neurovascular bundle containing the brachial plexus travels from the scalene triangle into the costoclavicular space and then finally through the pectoralis minor space.

The brachial plexus is formed by the intercommunications among the ventral rami of the inferior cervical nerves and the first thoracic nerves, responsible for both sensory and motor innervations (Martinez-Pereira & Zancan, 2015). Along with the upper limb nerve supply, it also innervates the scapular, pectoral and the thoracodorsal regions. An intricate system of innervation is required to coordinate and execute the myriad of complex movements of the pectoral girdle region (Nathan & McGillicuddy, 2015). Standard schemas of the brachial plexus are often incorporated to better understand the pattern of innervation and how it elaborates its necessary functions. According to Nathan & McGillicuddy (2015), five key components exist in this scheme: five spinal nerve roots, three trunks, six divisions, three cords, and five terminal nerves.

Fig. 2. Schematic view of the brachial plexus, from Nerves and Nerve Injuries 1 by Tubbs et al., 2015

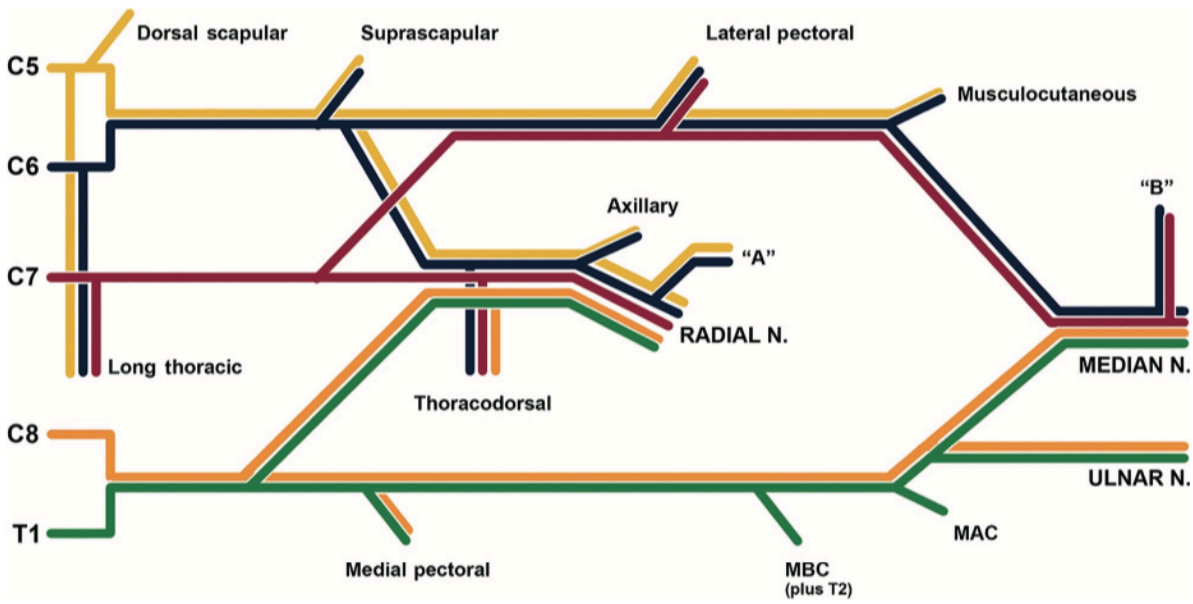

Each spinal nerve of the brachial plexus exits through a neural foramen between two adjacent vertebrae, and then quickly divides into a dorsal and ventral ramus (Nathan & McGillicuddy, 2015). While the dorsal ramus turns to supply the paravertebral muscles, the vertebral joints

and skin of the back, the ventral rami gather anteriorly to form the brachial plexus. The brachial plexus consists of ventral rami from C5 to T1. The combining, separating and mixing of axons from all five spinal nerves forms the brachial plexus into a highly complex structure. As a result of this sorting out of axons along the plexus, every spinal nerve contributes axons to more than one peripheral nerve, and every peripheral nerve has axons from more than one spinal nerve.

The five roots form three trunks: superior (C5-6), medium (C7), and inferior (C8-Th1) (Martinez-Pereira & Zancan, 2015). In essence, movements of the shoulder and elbow flexion are made responsible by the roots of C5-6, while C6-8 innervates and controls the elbow extensor group, wrist and extrinsic thumb and fingers. Important stabilizing functions of the shoulder are mainly made responsibly by the long thoracic (C5-7), the suprascapular (C5-6), and the subclavian (C5-6) nerves. The motor innervation of the flexor muscles and intrinsic muscles of the wrist are made by the roots of C6-8 and Th1. This makes the grasping ability of the hand. The brachial plexus does also give rise to the thoracodorsal (C7), the superior and inferior subscapular (C7), and the lateral (C5-6) and medial (C8-Th1) pectoral nerves.

2.3.3.1 Variations

Studies of human cadavers have shown almost 40 variations of the brachial plexus, making it one of the most important challenges of neural system anatomy (Emamhadi, Chabok, Samini, Alijani, Behzadnia, Firozabadi & Reihanian, 2016). These observations were observed at several levels of the network, with different routing mechanisms and branching patterns being seen. Projections of contributing branches from the C4 and Th2 spinal root to the plexus are other regular findings. These are termed either “prefixed” or “postfixed” respectively (Shin, Spinner, Steinmann & Bishop, 2005). Communicating branches of the terminal nerves are also found to be common, which can be of importance when evaluating unexplained sensory losses after trauma or surgical interventions (Emamhadi et al., 2016).

2.4 General pathophysiology of peripheral nerves

2.4.1 Traumatic injury to peripheral nerves

According to Robinson (2008), peripheral nerve injuries are of great significance as they impede restoration of function and return to work. They also carry the risk of secondary disabilities from fracture or falls among others. Appropriate diagnosis, localization and management depend upon understanding of pathophysiology, classification and mechanisms of recovery. Trauma can be defined as a tissue insult resulting from kinetic energy applied to the nerve or limb (Robinson, 2008). As kinetic energy is proportional to the mass of the object and the square of the velocity, a doubling of velocity results in four times increase of energy applied to the tissue.

2.4.2 Classification of peripheral nerve injuries

Thorough understanding of the classification of nerve injuries is critical in the management of traumatic peripheral nerve injuries (Boyd, Nimigan & Mackinnon, 2011). According to Campbell (2008), there are two commonly used classification schemes for peripheral nerve injuries. These are the Seddon and the Sunderland classifications. Seddon (1943) classified nerve lesions as neurapraxia, axonotmesis and neurotmesis, while Sunderland (1978) has five degrees, where his first, second and fifth degree injury corresponds to Seddon's. With neurapraxia, there is just a conduction block without any damage to the connective tissue. It is the mildest form of nerve injury and is due to local demyelination, while no Wallerian degeneration occurs because there is no disruption to the nerve fibers (Lee & Guyuron, 2015). In axonotmesis, most of the connective tissue framework is maintained while the axon is either damaged or destroyed. Wallerian degeneration occurs at the distal end. In neurotmesis, there is no longer anatomical continuity and most of the connective tissue framework is lost or severely distorted. This includes the axons, the endoneurium, the perineurium and the epineurium. Mackinnon further expanded Sunderland's classification by adding a sixth group, describing a mixture of all or some of the previous degrees of injury (Boyd et al., 2011).

Nerve regeneration

With nerve injuries, regeneration and repair processes initiates at multiple levels, including the nerve cell body, the proximal stump, the injury site itself, the segment between the injury site and the end organ, and at the end organ (Campbell, 2008). Following mild neurapractic injury, regeneration starts almost instantly, with remyelination occurring fairly rapidly. In more severe cases, an initial shock phases is preceded by repair and regeneration continuing for many months. According to Campbell (2008), repair occurs through three mechanisms: remyelination, development of sprouts with growth cones distally from preserved axons, and regeneration from the site of injury. In partial nerve injuries, collateral sprouts may be very effective in providing reinnervation when there are many surviving axons, with recovery occurring within 2-6 months. Regeneration from the injury site is the primary repair mechanism when more than 90% of axons are injured. Successful repair of regeneration from the proximal stump pivots on the distance from the injury site. If the axons cannot reach the distal stump, they're wasted, and become encased in scar tissue forming within that gap. An even with the recovery of good motor function, sensory deficits (proprioception especially) may impair functional outcome.

There are also numerous factors why motor function might not recover after moderate to severe injuries. Post-injury, fibrotic changes in the muscles occur as early as within three weeks; atrophy of muscle fibers also initiate quite rapidly. Without reinnervation fibrosis continue to progress and replaces the muscle completely within about two years. It is therefore essential to have reinnervation within 12-18 months in order to provide a functional outcome. Even with full reinnervation, previously occurring intramuscular fibrotic changes may limit contractile efficiency and reduce muscle strength. Path finding errors – axonal misdirection – are especially problematic with proximal injuries to large mixed nerves.

Surgical considerations and methods

Numerous considerations have to be made in advance of a surgical exploration (Campbell, 2008). Some of these considerations include temporal factors that are critically important to a good outcome: 1) Nerve deficits persisting beyond approximately 12 weeks indicate axonal damage, as this is the time required for resolution of segmental demyelination. Regrowth of the proximal axonal stump is under ideal circumstances occurring at 1mm/day.

2) Muscle atrophy with irreversible changes takes place within 12-18 months. Any surgery after this will not provide any benefit. 3) Viability of the Schwann cells and endoneurial tubes are believed to remain for 18-24 months. Reinnervation must therefore occur before irreversible changes of muscle atrophy happen and the endoneurial tubes cease to support regrowth.

Primary methods of surgical exploration include end-to-end repair, external neurolysis, nerve grafting and nerve transfer, and depend on circumstances and temporal factors (Campbell, 2008). With sharp transections or lacerations, immediate reconstruction is often done. The nerve ends are usually not contused and the local tissue trauma is minimal. The surgical method of choice is in these cases primary end-to-end neurorrhaphy, with the intention of joining the healthy nerves providing alignment of the fascicles. If the nerve is not reconstructed immediately, the proximal and distal stumps retract and the gap increases. A nerve graft will then be needed to bridge the gap, decreasing the chances of a good outcome. This is also necessary when the nerve ends cannot be connected without creating tension. Whether to graft, end-to-end neurorrhaphy or transfer also depends on the status of the nerve stumps. With nerve transfers, intact motor fibers with minor functions are used to innervate the more critical muscles of function. With blunt transections, usually occurring from high-energy forces applied by semi-sharp objects, delayed surgeries are generally preferred. If nerve continuity is uncertain, i.e. following massive trauma, surgery is often postponed in order to see if evidence of reinnervation can be seen. Intervention is then usually done within 3-6 months.

2.5 Traumatic injuries to the brachial plexus

2.5.1 General

The brachial plexus makes a particularly critical portion of the peripheral nervous system due to its anatomical relationships with mobile structures of the upper arm, pectoral girdle and neck (Martinez-Pereira & Zancan, 2015). These structures may be involved when force vectors causing traction or compression that results in trauma.

Traumatic injury to the brachial plexus or its terminal branches is often devastating and causes loss of sensation and motor function (Hems, 2015; Abu-Sittah, Bakhack & El Khatib, 2017). The extent of impairment depends upon the number of damaged nerves, and in severe cases there can be complete paralysis and loss of sensation in the upper extremity (Rankine, 2004). Large improvements in health care management have had great significance for patients who previously would have died as the result of multiple traumas, which are now surviving with injuries to the brachial plexus (Terzis & Papakonstantinou, 2000). Advances in microsurgical techniques and a great variety of philosophies have also greatly improved the clinical presentation and outlook for patients suffering trauma to the plexus.

2.5.2 Epidemiology

Several different authors have studied the demography of brachial plexus palsies, with high velocity/high energy trauma accounting for the majority of them (Terzis & Papakonstantinou, 2000). Automobile and motorcycle accidents are responsible for the most within this category, with motorcycle accidents occurring twice as often owing to the increased external forces applied to the unprotected body. The most commonly found injury type is due to traction and generally results in a larger rate of avulsions in comparison to crush injuries taking place in most automobile accidents. Young men are predominantly affected with an approximate rate of 90%. Additional severe bodily injuries occur according to Azar, Beaty and Canale (2017) in 80% of the patients, with 20% being rupture of the axillary or subclavian nerve, as well as associated injuries like fractures of the proximal humerus, the scapula, the ribs, dislocations of the shoulder, the acromioclavicular joint and contaminant spinal cord injuries.

2.5.3 Classifications of injury

Several classifications of brachial plexus injury exist according to Azar et al. (2017). The most familiar ones classify either according to the mechanism of injury, closed/open injuries, injury grading, injury pattern or according to its level.

Mechanism of injury

Based on the above-mentioned epidemiology, Terzis and Papakonstantinou (2000) propose three major mechanisms of injury:

1) Crush type of injury, with the plexus being crushed between the clavicle and the first rib as a result of direct blunt trauma to the upper extremity or neck.
2) Traction of the plexus, with caudal traction of the arm usually lesions the upper roots, while cranial traction usually affects the lower ones.
3) Compression of the plexus, with lesions taking place due to hematomas or injuries of adjacent soft tissues.

Additionally, Hems (2015) proposes a fourth mechanism:

4) Laceration type of injury, caused by penetrating injuries inflicted by bullets, knife wounds, blast fragments and other penetrating objects.

These injury mechanisms generally present as either an open or a closed type of injury, with closed injuries resulting from automobile accidents clinically being more common today (Shin et al., 2005).

Open injuries

These most commonly result from Hems' (2015) proposed mechanisms of laceration. The upper roots of the supraclavicular plexus are usually affected, even though involvement of any part of the plexus is possible. The clavicle acts as protection for the lower roots of the supraclavicular part, but below it the lateral and posterior cords are vulnerable. As a result of the close proximity of the nerves of the infraclavicular plexus to the axillary vessels, injuries to adjacent vessels are of usual finding and must be treated fist (Azar et al., 2017)

Closed Injuries

Closed injuries caused by traction most commonly happen by two mechanisms (Azar et al., 2017). Number one occurs when widening of the angle between the neck and the axilla increases tension on the plexus, resulting in traction injury if physiological limits are exceeded. The other one occurs when the arm is forcefully abducted. Both mechanisms usually take place while the motorcyclist gets thrown off and strikes his or her head and shoulder on the ground (Hems, 2015). The level of shoulder adduction or abduction usually determines which roots are damaged. Upper roots are most vulnerable to injury in shoulder adduction, while the lower roots are endangered in shoulder abduction exceeding 90 degrees.

Compression injuries on the other hand, may result as a consequence of direct pressure from fractures of the proximal humerus. The same force that damages the brachial plexus may conversely cause skeletal injuries. Such scenarios are most common with infraclavicular lesions. According to Hems (2015) it is rather unusual for the plexus to be damaged by a fracture of the clavicle or first rib despite their close relationship. Subjects suffering multiple simultaneous limb or visceral injuries generally have a much more complicated clinical presentation and outcome.

Grades of injury to the brachial plexus

Damage to the different elements of the plexus often varies in severity (Hems, 2015). After blunt injuries, the nerve trunks may remain in continuity. Spontaneous recovery is then feasible, and may occur within weeks or months depending on if it's graded as either neurapraxia or axonotmesis. Variable potential for spontaneous recovery can be seen in more severe lesions in spite of loss of continuity. Injuries distal to the dorsal root ganglion are called postganglionic (Shins et al., 2005). Neurotmesis occurs in these cases, and surgical exploration is needed for recovery. If the nerve roots are avulsed from spinal cord proximally to the root ganglion, termed postganglionic injuries, only limited options exist for surgical repair. As the C5-C6 roots have strong attachments to the transverse processes, upper roots are less often avulsed than the lower roots. According to Shin et al. (2005), it was reported in a study of traumatic brachial plexus traumas, that 70% of those with root avulsion had avulsion of C7, C8 or T1.

Patterns of injury

Depending on whether the trauma occurs to the nerves above the clavicle, or the nerves beneath it, Hems and Mahmood (2012) distinguish the injury as either supraclavicular or infraclavicular:

Supraclavicular injuries

Supraclavicular lesions assemble a pattern of neurological loss in consistency with damage to a number of the nerve roots that supply the brachial plexus (Hems & Mahmood, 2012). The proximal branches are therefore generally affected. Most injuries to the supraclavicular brachial plexus fall into the following groups (Azar et al., 2017; Hems, 2015):

1) Upper plexus injury (Erb). The C5 and C6 roots are affected with more extensive damage, including C7 and even C8 in more severe cases. The C7 and C8 injuries are more likely to be preganglionic.
2) Total plexus injury: There is usually preganglionic avulsion of the lower roots. Although of all five roots is possible, postganglionic rupture of at least C5 is common.
3) Lower plexus injury (Klumpke): These are usually isolated avulsion injuries of C8 and T1 with involvement of C7 in some cases.

Infraclavicular injuries

Infraclavicular injuries vary considerably in their severity, but generally present with loss of sensation and motor function in a variable number of terminal branches, constituting the major nerves of the upper extremity (Hems & Mahmood, 2012).
When taking into account the skeletal injury, most closed injuries fall into four scenarios:

1. Nerve injuries associated with dislocation of the shoulder joint.
2. Axillary nerve palsy in isolation or in combination with injury to other nerves in the absence of shoulder dislocation.
3. Rupture of the musculocutaneus nerve with or without injury to other nerves
4. Nerve injuries associated with displaced fractures of the proximal humerus

2.6 The example of an infraclavicular injury with displaced proximal humeral fracture

2.6.1 Presentation and diagnosis

Patients with posttraumatic brachial plexus palsy usually appear in the emergency room with multiple injuries (Terzis & Papakonstantinou, 2000). Assessment of plexus function may be difficult in the acute situation if there is skeletal injury affecting the shoulder (Hems, 2015). Associated injuries with life-threatening potential are therefore of chief importance and treated first. With a proximal fracture of the humerus, the brachial plexus injury is likely to be the result of medially directed pressure from the end of the humeral shaft on the neurovascular bundle in the axilla (Hems & Mahmood, 2012). Fractures that go unreduced may worsen the damage of nerves and arteries if ongoing pressure compromising function is present. Clinical features involving progressive neurological loss and severe pain normally exist. According to Hems & Mahmood (2012), immediate surgery to reduce and stabilize the fracture is almost always obligatory in injuries associated with nerve damage. It should be entailed as an emergency with the intention of minimizing risks of ongoing attrition and further damage to the nerves, and thereby maximizing the changes of good recovery. According to Hems (2015), a number of authors indeed as well recommend early surgical exploration for high-energy traumas to the infraclavicular plexus. But if the grade and degree of damage is not clear, the patient is not fit for surgery, or the provisional plan for reconstruction is not viable, the author suggests await up to 2-3 months in order to carry out more investigations and continue clinical observation.

In a study of 15 persons with associated displaced fracture of the proximal humerus, grades of injury were reported in the following manner described in the table (Hems & Mahmood, 2012):

Fig. 3. Details of nerve injuries in association with humeral fracture, borrowed from Hems & Mahmood, 2012.

T. E. J. HEMS, F. MAHMOOD

Table III. Proximal humeral fractures. Details of the nerve injuries in 15 patients (EMG, electromyography)

Nerve	Number injured	Neurapraxia	Axonotmesis (full recovery)	Neurotmesis (repaired)	EMG only
Suprascapular	3	2	-	1 (1)	-
Axillary	10	4	4 (4)	2 (1)	-
Musculocutaneous	6	3	1 (1)	2 (1)	-
Radial	9	1	7 (7)	1 (1)	1
Median	6	2	3 (0)	1 (1)	2
Ulnar	7	1	5 (1)	1 (0)	2

Out of the 15 patients, ten of them had injury to the axillary nerve, with two of them requiring surgical repair. 35-70% had injuries to both the musculoskeletal, radial, median and ulnar nerve, with the majority of them graded as axonotmesis. The least common injury occurred to the supraclavicular nerve, with only three out of 15 being affected.

2.6.2 Preoperative evaluation

Preoperative evaluation includes a detailed history taking, radiographic and electrophysiologic studies and a thoroughly performed clinical examination (Terzis & Kostopoulos, 2007). The clinical examination should include examination of passive and active range of motion of all joints, as well as manual muscle testing. The results should be compared with the contralateral side, and the manual muscle tests should be performed in an anti-gravity position to detect grade 2 strength, while grade 1 strength needs to be palpated (Kendall, McCreary, Provance, Rodgers & Romani, 2005). Sensory evaluation is also of primary importance, including the changes in trophicity, color, static and dynamic two-point discrimination, pressure testing and proprioceptive testing. After nerve injury, all sensory modalities are affected. With regenerating nerves, nonmyelinated fibers are the first to recover and become functional to bring perception of pain, heat and cold.

Due to the fact that most experience the maximum loss of function at the immediate time of injury, questions regarding functional recovery during the time between injury and evaluation should be asked (Terzis & Papakonstantinou, 2000). Questions in concern of how

the person function independently and how he or she has made strategies to compensate for the loss of function should also be carried out.

2.6.3 Surgical approach

The infraclavicular plexus is best explored through a deltopectoral approach (Hems, 2015). Incisions through the tendon of the pectoralis minor, into the fat surrounding the neurovascular bundle and dissections proximally deep to the axilla reveals a step-wise access to the lateral, posterior and medial cord. Exposure of the terminal branches of the brachial plexus are done in the upper arm by making an incision stretching from the m. pectoralis major down to the medial side of the m. biceps brachii. With delayed surgeries, defining the injured nerves often proves to be problematic as scar tissue may surround them. Depending on the grade of injury, appropriate steps are done in order to achieve the most optimal function outcome. In an example of a blunt trauma with the need for grafting, the most commonly used donor nerves for grafting are the sural nerves (Hems, 2015). Each sural nerve can provide about 45 cm of length. According to Terzis & Kostopoulos (2007), the bilateral saphenous nerves and vascularized ulnar nerve grafts are also being used. With motor donors, the use of intraplexus donors is preferred over donors of extraplexus character. Intraplexus motor donors have greater numbers of axons, and there is usually less need for postoperative reeducation as a result of the brain recognizing the various reconnections more easily.

2.6.4 Strategies for reconstruction

In order to obtain the most functional outcome possible, priorities need to be made when deciding which target muscles are to be reinnervated (Terzis & Kostopoulos, 2007).

Shoulder stability

In order for more distal targets to follow, restoration of abduction and external rotation are of high priority in rehabilitation of the upper limb (Terzis & Kostopoulos, 2007). A good opportunity is made for satisfying shoulder stability by ensuring neurotization of both the suprascapular nerve and the axillary nerve.

Elbow flexion

Due to obvious nurturing functions, restoring elbow flexion should be of primary importance when dealing with brachial plexus injuries (Terzis & Kostopoulos, 2007).
The grafts used for reinnervation of the musculocutaneus nerve should therefore be the most optimal ones in order to provide the best donors. Intraplexus donors normally yield better results than extraplexus donors in restoration of the m. biceps brachii. If the lower plexus has escaped any damage, distal nerve-to-nerve transfers can provide a viable source close to the target muscles. These include ulnar nerve fascicles to the biceps branch of the musculocutaneus nerve, or to biceps and brachialis, medial pectoral nerve, and thoracodorsal nerve transfers.

2.6.5 Surgical outcomes

Even though results of repair of infraclavicular injuries are likely to give good muscle strength grading, the outcome usually worsens with either arterial or bony injuries (Hems, 2015). With nerve graft repair of the musculocutaneus nerve, outcomes tend to give grade 3 or 4 recovery of elbow flexion, while the outcome of repair of the axillary nerve is harder to assess in isolation because shoulder abduction also relies on the function of the suprascapular nerve and rotator cuff tendons. The outcome of the median, radial and ulnar nerve is anyhow less encouraging, as repairs tend to be successful with less then 10-20% achieving good results.

2.6.6 Postoperative care

A custom-made brace keeps the upper arm in 45 degrees of abduction instantly after surgery (Terzis & Kostopoulos, 2007). To exclude any neck movement away from the reconstructions, a neckpiece is also applied. This brace is utilized for approximately six to eight weeks, before a sling replaces it. Movements of the shoulder joint are restricted during these weeks, but movement of all other joints is generally accepted to diminish stiffness

(Jaggi, Birch, Dean, Johson & Tripp, 2004). Immediately after the brace is discharged, physical therapy initiates.

2.6.7 Postoperative physical therapy approach

A multidisciplinary team is usually involved in the rehabilitation process after brachial plexus repair, often with close cooperation and integration between the physiotherapist and the occupational therapist in the physical management (Jaggi et al., 2004). A clinical psychologist might assist with any emotional difficulties, and social workers may provide important advising about family and community issues.

The physical rehabilitation of brachial plexus injuries are often of challenging character as multiple critical aspects has to be acknowledged and considered (Smania, Berto, La Marchina, Melotti, Midiri, Roncari, Zenorini, Ianes, Picelli, Waldner, Faccioloi & Gandolfi, 2012). In cases of traumatic high-energy traumas, injuries to the brachial plexus may result in severe and chronic impairments, making necessary early and prolonged therapy. The clinical presentation often includes multiple aspects of sensorimotor disturbances; encompassing pain, sensory deficits, muscle atrophy, muscle weakness, secondary deformities and so forth. Coexisting repaired fractures, with its own clinical presentation, may add additional aspects and parameters to contemplate, depending on its state of healing progression, and has to be respected in terms of anticipated remaining healing time, loading capacity and risks of complications (Schlegel & Hawkins, 1994). Significant functional limitations may be caused by long-term postoperative complications including malunion or nonunion of the regenerating humerus. Malunion potentially distort anatomy as healing occurs either superiorly or medially, reducing the space beneath the acromial arch. With non-union, which not uncommonly occurs as a result of overaggressive physical therapy, inadequate immobilization or poor patient complication, a surgical correction if often needed.

Aims of rehabilitation

According to Jaggi et al. (2004) the aims of rehabilitation include:

- Objective measurement of disability and the accurate measurement of treatment outcome
- Reduction of disability by physical therapy
- Return to original work, the original work modified, or to suitable other work.
- Restoration of abilities to live his or her life independently at home, to enjoy recreation and social life, and to be independently mobile.

Kinesiological assessment

Initial physiotherapeutic assessment is ideally brought about together with the occupational therapist. Areas of particular attention are: pain, sensation, oedema, active and passive range of motion, muscle strength and activities of daily living (Jaggi et al., 2004).

Assessment of possible sensory impairments includes several standardized tests evaluating sensory function and threshold (Smania et al., 2012):

- Evaluation of pain and touch sensation following the specific dermatomes
- Joint position sense, evaluating proprioception at various levels of the upper limb
- Two point discrimination tests
- Vibration perception threshold, measured with a tuning fork
- Thermal threshold, evaluating cold and warm sensations from a set baseline temperature
- Pain threshold (i.e. using a numerical scale of 0-10)

Possible areas of hypersensitivity are recorded, with cutaneous sensitivity without pain likely being a sign of reinnervation.

Tests assessing muscle strength is also a crucial component, as improvements after surgery generally are slow and depends upon many variables, including reinnervation time and healing potential (Smania et al., 2012). Mapping the affected muscles and their strength grade

may give the therapist a general overview of treatment necessity and potential functional challenges of daily living. Development of muscle atrophy may result as a temporal progression of structural and neurophysiological alterations while nervous regeneration is occurring, possibly leading to muscle imbalance and secondary deformities. A detailed strength assessment may also reveal weakness not due to neurological origin, but rather as a sequel to inactivity or faulty posture (Kendall et al., 2005).

A comprehensive assessment of posture and appearance of the limb should also be incorporated (Jaggi et al., 2004). Many of the brachial plexus palsy patients adopts a typically flexed posture, and thoroughly assessment from all views are important to recognize any alterations in joint position and muscle tension.

Early treatment aims

A fundamental goal in rehabilitation of brachial plexus palsy is to maintain adequate muscle trophy until the nerves are reinnervated (Smania et al., 2012). Physical therapy also aims at improving strength of affected and paretic muscles (Kolár, 2013). Management of neuropathic pain is a substantial concern in adult patients, as it often compromises quality of life and increases resistance to therapy (Jaggi et al., 2004). Other goals of importance include improving sensory functions to regain tactile gnosis, oedema control, teaching of management of the affected limb, teaching postural awareness, preventing deformities, addressing muscular imbalances as recovery occurs and encouraging functional independence.

Later treatment aims

If limitations of joint range of motion still are present, stretches or relaxation techniques should be performed as soon as possible (Jaggi et al., 2004). Even with no recovery of hand function, preserving joint motion is important for both cosmetic and hygienic reasons. Ensuring balance and symmetry of joint motion in all planes is therefore of high priority.

Facilitation techniques improving muscle strength and their implementation into physiological movement patterns should also be incorporated (Kolár, 2013, Jaggi et al., 2004). An example of choice includes proprioceptive neuromuscular facilitation (PNF) according to Kabat (1950), which help facilitate strength components of all the affected

muscles of the plexus injury. Encouraging shoulder and scapular stabilization by sensorimotor stimulation techniques may also improve both motor coordination and joint stability.

Surgical scars may become adhered and tethered to soft tissue layers below and in close proximity, and might contribute to loss of movement. These are also important to consider and treat.

Postural awareness can be practiced through balance and proprioceptive work, encouraging deep stabilization function (Jaggi et al., 2004). Endorsing the use of any available function in their affected upper limb is also advisable. This help promote independence, provides exercise to weak muscles and stimulation to sensory-impaired areas of concern.

3 Special part

3.1 Methodology

The clinical work for this bachelor thesis took place at Oblastní Nemocnice Kladno in Prague, Czech Republic, from 15.01.18 to 26.01.18. All clinical work during this time was performed under the supervision of Mgr. Ilona Kučerová and Bc. Tomás Modlinger.

This is a case study of an 18-year-old male that underwent surgical repair of the terminal branches of the brachial plexus and of a proximal humeral displacement fracture of the right upper extremity. Infected collision wounds of the right forearm also underwent surgical treatment. The subject of study underwent two surgeries, with the first one carried out as an emergency after the accident, stabilizing the humeral fracture. He was at the initial examination two and a half months post surgery of the brachial plexus repair. Therapy was applied in a larger therapy room well equipped with devices of electro therapy, several hydraulic therapy tables, a larger cage for sling therapy, bosu-balls, soft foam balls, and other available equipment. A goniometer, a measure band and a neurological hammer were also utilized. Therapy was generally performed two times per day, for approximately one hour each session. The first therapy session was made on Day 2, and the last on Day 8, making it a total of 13 sessions. A numerical pain scale ranging from 0-10 was utilized to control pain levels.

The rehabilitation mobilized previously instructed therapies at the Charles University including the soft tissue techniques by Lewit, post isometric relaxation by Lewit, manual methods by Lewit, proprioceptive neuromuscular facilitation by Kabat, developmental positions by Kolár, as well as ones taught at clinical work placements (ischemic pressure trigger point treatment among others).

The patient was informed of my position as a student and his participation in therapy for my resolution of the bachelor's thesis. The patient was requested to give his informed consent in written form (see attachment), and the Committee of the Faculty of Physical Education and Sport of the Charles University approved the project on the 30th of January 2018.

3.2 Anamnesis

3.2.1 General demographics

Patient's name: J. V. **Today's date:** 15.01.18 **Date of surgery:** 01.11.17

Diagnosis: Brachial plexus palsy with infraclavicular lesion, open displacement fracture of the proximal humerus and infection of collision wounds of the right upper extremity.

Codes: Z509, G832, T928, Z924, Z967.

Age: 18 years of age. **DOB:** 07.04.1999 **Gender:** male.

Occupation: He currently goes to high school.

Height: 180 cm. **Weight:** 119 kg. **BMI:** 36,7

Alcohol use: No. **Tobacco use:** 10 cigarettes/day **Allergies:** None.

Handedness: Left-handed.

3.2.2 Current symptoms/chief complaint

The patient is currently in rehabilitation after surgical repair and nerve reconstruction of the brachial plexus on the right side, with an earlier reduction surgery of the fractured proximal humerus. His current symptoms include functional limitations of activities of daily living, mainly due to forearm peripheral palsy and reduced motor and sensory function of the elbow and shoulder.

3.2.3 Mechanism of present injury

The subject suffered a traffic accident situated in the front passenger seat of a motor vehicle dated to the 16th of April 2017. High-energy trauma to the right upper extremity resulted in an open displacement fracture of the proximal humerus and lesion of several terminal branches of the infraclavicular brachial plexus. The collision trauma also inflicted larger soft tissue damage to the right forearm.

3.2.4 Excerpt from Patient's Health Care File

The first surgical repair took place at Motol Hospital the 16th of April 2017, carried out as an emergency routine with intramedullary stabilization of the fractured right humerus. He was then operated on the 11th of November 2017, reinnervating selected lesioned terminal branches of the right brachial plexus. Reinnervation of the axillary nerve and musculocutaneus nerve were performed using grafts from the sural and thoracodorsal nerve. Surgical exploration of the suprascapular, median, ulnar and radial nerve, as well as necretomy of post-surgically infected wounds of the forearm was also carried out.

He was then instructed to wear a sling, preventing contraindicated movement and supporting indicated positioning of the shoulder. The patient was originally hospitalized at Oblastní Nemocnice Kladno the 28th of November 2017 in order to initiate physical therapy, and was then discharged during the Christmas Holidays. He then reinitiated rehabilitation the 15th of January 2017.

3.2.5 Past injuries/Hospitalization/Surgeries

Previous to this injury, the patient has to this date not experienced any injuries, nor has he been hospitalized.

3.2.6 Medications

The patient is currently taking anopyrin and milgamma.

3.2.7 Family history

His mother suffers from Diabetes Mellitus type 2. His father and two sisters are healthy.

3.2.8 Living Environment

The patient is currently living in a house with his family. He has a normal social life. Since the patient is not right handed, many activities are simplified due to habitual reasons. Movements requiring bilateral movements of the hands are anyhow currently not possible, making several activities tiresome and largely complicated.

3.2.9 Personal Care

Despite his functional limitations, the patient is fully able to carry out management of all personal hygiene activities and dressing; primarily because of he is left-handed.

3.2.10 Indications for rehabilitation

The prescription of physiotherapy recommends therapy of the upper extremity along with electrotherapy. The therapy plan should include mobilization, scar care, the Kenny method, analytical exercises, improving joint range of motion and improving strength of affected muscles. Functional improvements facilitating abilities of daily living are of large importance.

3.2.11 X-ray picture and visual impression of the right upper extremity

Pic. 1. X-ray picture of the right shoulder (date: 29th of November 2017).

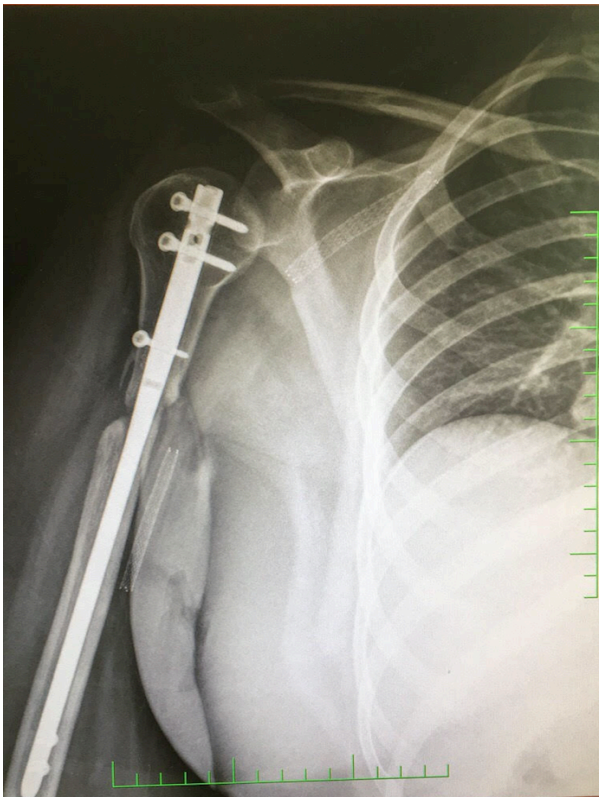

Pic. 2. Right upper extremity

3.3 Initial Kinesiological Examination (Date: 15.01.18-16.01.18)

3.3.1 Postural examination

Pic. 3. Initial postural front view

Pic. 4. Initial postural back view

Pic. 5. Initial postural left view

Pic. 6. Initial postural right view

Initial front view (see pic. 3) - base of support slightly tilted to the right, excessive lateral rotation of the right femur, medially rotated humeri (the right more than the left), right shoulder positioned slightly higher with atrophy of the m. deltoid, tissue folding on the left side above the epigastric region.

Initial back view (see pic. 4) – left lower extremity slightly shifted forward, slight knock-knees, higher muscular tonicity of the paravertebral muscles on the left side at thoracolumbar region.

Initial left side view (see pic. 5) – protraction of the left shoulder, slight flexion of the left elbow with closed fingers.

Initial right side view (see pic. 6) – forward shifted center of gravity, pelvic anteflexion, protruding abdominal wall, ribcage tilted downwards, protraction of the right shoulder, increased thoracic kyphosis, hyperlordosis in the upper cervical region, forward head position.

Notes: characteristic signs of what Janda (1983) defines as an upper crossed syndrome is present.

3.3.2 Anthropometrical data

Tab. 1. Initial anthropometric measurements

LENGTH OF THE UPPER EXTREMITIES	**RIGHT**	**LEFT**
Total length	73,5 cm	73 cm
The length of the humerus	29 cm	28,5 cm
The length of the forearm	25 cm	25 cm
The length of the hand	19,5 cm	19,5 cm
CIRCUMFERENCES		
The circumference of the upper arm	36 cm	38 cm
The circumference of the forearm	21 cm	22 cm

3.3.3 Breathing pattern investigation

Breathing occurs without participation of the accessory breathing muscles. However, the lower chest does not expand fully ventrally, and the abdominal wall does not expand fully laterally and posteriorly.

3.3.4 Dynamic spine investigation

Tab. 2. Initial test of basic movements of the spine and pelvis

Type of movement	**General mobility**		**Segmental mobility**	
Retroflexion	The sum of all joints display normal range of motion. No (0/10) is felt during the movement.		Restricted mobility of the lower lumbar spine, with hypermobility visual in the thoracolumbar junction.	
Anteflexion	The sum of all joints display restricted range of motion. He is not able to curl his spine segmentally. No pain (0/10) is felt during the movement.		Restricted motion can be seen in the lumbar spine and the upper thoracic segments.	
	RIGHT	**LEFT**	**RIGHT**	**LEFT**

Lateroflexion	The sum of all joints shows slight restricted range of motion. Rotational synkineses of the pelvis to the contralateral side is present.	The sum of all joints shows slight restricted range of motion. Rotational synkineses of the pelvis to the contralateral side is present.	Slight restricted movement in the cervicothoracic area.	The cervicothoracic junction does not move during side bending.

3.3.5 Joint of range of motion tests according to Kendall (2005)

The results are given in degrees and according to the SFTR-method (except for cervical spine).

Tab. 3. Initial tests of joint range of motion according to Kendall

CERVICAL SPINE				
MOVEMENT AND NORMS	**RIGHT**		**LEFT**	
	ACTIVE	PASSIVE	ACTIVE	PASSIVE
Rotation (75)	65	75	60	65
Lat. Flex (45-60)	40	45	30	35
	ACTIVE		PASSIVE	
Flexion (45)	40		45	
Extension (45)	35		45	
SHOULDER JOINT				
NORMS	**RIGHT**		**LEFT**	
	ACTIVE	PASSIVE	ACTIVE	PASSIVE
S: 45-0-180	S: 0-0-150	S: 35-0-155	S: 35-0-170	S: 40-0-180
F: 150-0-0	F: 130-0-0	F: 135-0-0	F: 140-0-0	F: 145-0-0

T: 30-0-120	T: 10-0-100	T: 15-0-110	T: 20-0-115	T: 25-0-120
R: 90-0-70	R: 60-0-60	R: 70-0-70	R: 80-0-60	R: 90-0-70
ELBOW JOINT				
NORMS	**RIGHT**		**LEFT**	
	ACTIVE	PASSIVE	ACTIVE	PASSIVE
S: 0-0-145	0-0-0	0-0-120	0-0-120	0-0-135
RADIOULNAR JOINT				
NORMS	**RIGHT**		**LEFT**	
	ACTIVE	PASSIVE	ACTIVE	PASSIVE
R: 90-0-90	0-0-0	65-0-70	75-0-75	90-0-90
WRIST JOINT				
NORMS	**RIGHT**		**LEFT**	
	ACTIVE	PASSIVE	ACTIVE	PASSIVE
S: 70-0-80	0-0-0	30-0-40	60-0-60	70-0-70
F: 20-0-30	0-0-0	10-0-15	15-0-25	20-0-30

Notes: In the cervical spine, there is about a 10-degree negative difference in rotation and side bending to the left. There is a marked decrease in passive shoulder abduction and external rotation on the right side. Horizontal adduction is also restricted. Active shoulder extension of the right extremity is not possible due to weakness. Active flexion of the right elbow is also not possible due to weakness. The radioulnar and wrist joints possess no active motion.

3.3.6 Length of selected muscles according to Kendall (2005)

Tab. 4. Initial tests of muscle length according to Kendall

MUSCLES	RIGHT	LEFT
m. Pectoralis minor, m. biceps brachii and m. coracobrachialis	Shortness for m. pectoralis minor.	Shortness for m. pectoralis minor
m. Pectoralis major; clavicular and sternocostal parts	Shortness both in clavicular and sternocostal dir.	Shortness only in a clavicular dir.
m. Teres major, latissimus dorsii and m. rhomboid major and minor.	Shortness.	Normal.
Medial rotators of the glenohumeral joint	Shortness.	Normal.
Lateral rotators of the glenohumeral joint	Normal.	Normal.

Notes: A bilateral shortness of the m. pectoralis minor and the clavicular part of the m. pectoralis major was observed. The sternocostal part of the m. pectoralis major, m. teres major, m. latissimus dorsii, the rhomboids muscles and the medial rotators of the glenohumeral joint of the right upper extremity were also observed shortened.

3.3.7 Active movement against resistance of the cervical spine

Tab. 5. Initial tests of active movement against resistance

DIRECTION OF ISOMETRIC RESISTANCE		
Anteflexion	Answers with moderately strong pressure. No pain felt (0/10).	
Retroflexion	Answers with strong pressure. No pain felt.	
	RIGHT	**LEFT**

Side-bending	Slightly painful (2/10) upon contraction.	No pain felt (0/10).

3.3.8 Palpation

Chest examination:

- Restricted fascia in a caudo-cranial direction below the clavicle on both sides.
- Palpable trigger points of m. pectoralis minor on both sides.
- Palpable trigger points of clavicular part of m. pectoralis major on both sides.
- Clavicle tender upon palpation near the acromioclavicular joint on the right side.
- Coracoid process tender on palpation on the right side.

Scapula examination:

- Palpable trigger point of m. subscapularis on right side.

Neck examination:

- Palpable trigger point of the upper fibers of m. trapezius and m. levator scapulae on both sides.
- Palpable trigger point of m. sternocleidomastoid and m. scaleni on right side.
- First ribs on both sides tender upon palpation.
- Fascia in the cervicothoracic region slightly restricted.

Upper extremities (right):

- Atrophy of the deltoid muscle.
- Active scars penetrate all soft tissue layers along the arm.
- Large scar formation lying horizontally above the articulations of the elbow.
- Restrictions of all soft tissues of the forearm due to muscle removals.

Others:

- Increased resistance in the diaphragm upon palpation beneath the costal arches going laterolaterally.

3.3.9 Manual strength tests comparing sides according to Kendall (2005)

Tab. 6. Initial tests of manual muscle strength according to Kendall

MANUAL STRENGTH TESTS		
RIGHT	**MUSCLE/MUSCLE GROUP**	**LEFT**
2	Coracobrachialis	**5**
4	Supraspinatus	**5**
3	Middle deltoid	**4+**
3	Anterior deltoid	**5**
3	Posterior deltoid	**4+**
4	Pectoralis major (p. clav.)	**5**
4+	Pectoralis major (p. stern.)	**5**
4+	Pectoralis minor	**5**
2+	Lateral rotators	**4+**
3-	Medial rotators	**5**
2+	Teres maj. & Subscapularis	**4+**
2+	Latissimus dorsii	**4+**
1+	Biceps brachii	**5**
3+	Triceps brachii	**5**
2+	Rhomboids, Levator scapulae, Trapezius	**4**
4+	Upper Trapezius	**5**
2+	Middle Trapezius	**4-**
2+	Lower Trapezius	**4-**
4-	Serratus anterior	**5**

Notes: A lot of different tests and test positions (in order to grade correctly) were quite tiring for the patient. The left side possesses normal strength grading. The right side shows signs of impaired or reduced strength in the majority of tests.

3.3.10 Muscle strength and nerve supply chart according to Kendall (2005)

Tab. 7. Initial chart of muscle strength and nerve supply according to Kendall

	MUSCLE STRENGTH GRADING	RIGHT ARM	PERIPHERAL NERVES																			KEY D = dorsal prim. Ramus V = ventral prim. Ramus PR = plexus root ST = superior trunk P = posterior cord L = lateral cord M = medial cord								
				D	V	V	V	PR	PR	ST	ST	P	P	P	L	M	P	L	P	LM	M										
			T	1												1			1	1	1										
			CERVICAL	1-8	1-8	1-4	3,4,5	5,6,7,8	4,5	5,6	4,5,6,	4,5,6,7	5,6,7,8	5,6,7	5,6,7	6,7,8	5,6	4,5,6,7	5,6,7,8	5,6,7,8	7,8										
		MUSCLE	CERVICAL	CERVICAL	CERVICAL	PHRENIC	LONG THORACIC	DORS. SCAPULAR	N. TO SUBCLAV.	SUPRASCAPULAR	U. SUBSCAPULAR	THOR.DORASAL	L. SUBSCAPULAR	LAT. PECTORAL	MED.PECTORAL	AXILLARY	MUSCULOCUTAN.	RADIAL	MEDIAL	ULNAR		SPINAL SEGMENT									
																						C1	C2	C3	C4	C5	C6	C7	C8	T1
	-	Head and neck ext.	☐																			1	2	3	4	5	6	7	8	1
CERVICAL PLEXUS	-	Infrahyoid muscles			☐	☐																1	2	3						
	-	Rectus capitis ant. and lat.			☐																	1	2							
	-	Longus capitis			☐																	1	2	3	4					
	-	Longus colli		☐																			2	3	4	5	6	7		
	2+	Levator scapulae			☐			☐																3	4	5				
	-	Scalene ant., med. and lat.		☐																				3	4	5	6	7	8	
	-	Sternocleidomastoid			☐																	1	2	3						
	2+	Trapezius, lower, middle			☐																		2	3	4					

	-	Diaphragm																				3	4	5				
BRACHIAL PLEXUS	4 -	Serratus anterior																						5	6	7	8	
	2 +	Rhomboid maj. and min.																					4	5				
	-	Subclavius																						5	6			
	4	Supraspinatus																					4	5	6			
	2 +	Infraspinatus																					4	5	6			
	3	Subscapularis																						5	6	7		
	2 +	Latissimus dorsi																							6	7	8	
	2 +	Teres major																						5	6	7		
	4	Pectoralis major upper																						5	6	7		
	4 +	Pectoralis major lower																							6	7	8	1
	4 +	Pectoralis minor																							6	7	8	1
Axil.	2 +	Teres minor																						5	6			
	3	Deltoid																						5	6			
Musc.	2 -	Coracobrachialis																							6	7		
	1	Biceps																						5	6			
	1	Brachialis																						5	6			
RADIAL	3 +	Triceps																							6	7	8	1
	-	Anconeus																								7	8	
	-	Brachialis (small part)																						5	6			
	-	Brachioradialis																						5	6			
	0	Extensor carpi rad. long.																						5	6	7	8	
	0	Extensor carpi rad. brev.																						5	6	7	8	
	0	Supinator																						5	6			
	0	Extensor digitorum																							6	7	8	
	0	Extensor digit minimi																							6	7	8	
	0	Extensor carpi ulnaris																							6	7	8	

	0	Abductor pollicis longus																							**6**	**7**	**8**	
	0	Extensor pollicis brevis																							**6**	**7**	**8**	
	0	Extensor pollicis longus																							**6**	**7**	**8**	
	0	Extensor indicis																							**6**	**7**	**8**	
MEDIAN	**0**	Pronator teres																							**6**	**7**		
	0	Flexor carpi radialis																							**6**	**7**	**8**	
	0	Palmaris longus																							**6**	**7**	**8**	**1**
	0	Flexor digitorum sup.																								**7**	**8**	**1**
	0	Flexor digi. prof. 1,2																								**7**	**8**	**1**
	0	Flexor pollicis longus																							**6**	**7**	**8**	**1**
	0	Pronator quadrutus																								**7**	**8**	**1**
	0	Abductor pollicis brevis																							**6**	**7**	**8**	**1**
	0	Opponens pollicis																							**6**	**7**	**8**	**1**
	0	Flexor pollicis brevis																							**6**	**7**	**8**	**1**
	0	Lumbricales 1,2																							**6**	**7**	**8**	**1**
ULNAR	**0**	Flexor carpi ulnaris																								**7**	**8**	**1**
	0	Flexor digi. prof. 3,4																								**7**	**8**	**1**
	0	Palmaris brevis																								**7**	**8**	**1**
	0	Abductor digiti minimi																								**7**	**8**	**1**
	0	Opponens digiti minimi																								**7**	**8**	**1**
	0	Flexor digiti minimi																								**7**	**8**	**1**
	0	Palmar interossei																									**8**	**1**
	0	Dorsal interossei																									**8**	**1**
	0	Lumbricales 3,4																								**7**	**8**	**1**
	0	Adductor pollicis																									**8**	**1**
	0	Flexor pollicis brevis																									**8**	**1**

Notes: The chart indicates, at a glance, that the muscles supplied by the ulnar, median and radial nerve are graded as zero, with the exception of the m. triceps brachii, which also has innervation from the T1 segment. Those by the musculocutaneus nerve are trace, and those by the ventral ramus of cervical nerves 1-4, dorsal scapular and thoracodorsal nerve show poor grades. That of the suprascapular nerve shows good grade, but fair involvement of the m. subscapularis and m. teres minor might have interfered with the tests. That of the long thoracic nerve shows good grade, and those of the pectoral nerves show good to normal grades.

3.3.11 Basic movement pattern examination of selected movements

Tab. 8. Initial examination of basic movement patterns

	RIGHT	**LEFT**
SHOULDER ABDUCTION	- Scapulohumeral rhythm: approx. ratio 1:1. Substitution by increased activation of upper scapular fixators. Slight lateral head flexion occurs and the elbow starts to bend at approx. 150 degrees.	- Slight increase in scapulohumeral rhythm (2:1.5) and increased activation of the upper scapular fixators. Scapula slightly winging.
NECK FLEXION	- Slight neck protraction and visual contraction of sternocleidomastoid with initiation of movement.	
TRUNK FLEXION	- Rib flaring, neck protraction and partial range of motion achieved. Substitutional muscle contractions visual along the entire anterior kinetic chain.	

3.3.12 Joint play/screening examination according to Lewit (2010)

Tab. 9. Initial examination of joint play/joint screening

	JOINT		JOINT PLAY/SCREENING	RESULT
AO, CERVICAL, AND C/T-JUNCTION	**C0/C1**		Anteflexion Retroflexion Lateroflexion Rotation Shifting	No restrictions in either direction.
	C1/C2		Rotation Side bending	No restrictions
	C2-C6		Rotation Side bending Shifting	Restrictions of C3/C4 into side bending and rotation to the left.
	C6-T3		Rotation Side bending Shifting	Restrictions of C7/T1 and T1/T2 into side bending and rotation to the left.
1st RIB	Left		Springing pressure from above	Restricted
			Neck flexion in lateral rotation	Restricted
	Right		Springing pressure from above	Restricted
			Neck flexion in lateral rotation	Restricted
UPPER EXTREMITY	RIGHT	Scapula	(In side-lying position)	Restricted in caudal and medial direction with crepitation.
		AC-joint	Ventrodorsal direction Caudocranial direction	Restricted Restricted
		SC- joint	Pressure in cranial direction	Not restricted

		Shoulder	Caudal direction	Restricted
			Cranial direction	Not restricted
			Ventral direction	Restricted
			Dorsal direction	Not restricted
		Elbow	Radial direction	Not restricted
			Ulnar direction	Not restricted
		Wrist	Dorsal direction	Not restricted
			Palmar direction	Not restricted
	LEFT	Scapula	(In side-lying position)	Restricted in caudal and medial direction without crepitation.
		AC-joint	Ventrodorsal direction Caudocranial direction	Not restricted Not restricted
		SC-joint	Pressure in cranial direction	Not restricted
		Shoulder	Caudal direction	Not restricted
			Cranial direction	Not restricted
			Ventral direction	Not restricted
			Dorsal direction	Not restricted
		Elbow	Radial direction	Not restricted
			Ulnar direction	Not restricted
		Wrist	Dorsal direction	Not restricted
			Palmar direction	Not restricted

Notes: In the cervical spine, restrictions into side bending and rotation of the C3/C4 segment could be seen. In the cervicothoracic junction, similar movement restrictions could be seen in the C7/T1 and T1/T2 segment. The first rib was restricted on both sides, and the scapula has restricted motion on both sides in a caudal and medial direction. Crepitation under the scapula could also be felt on the right side. Slight restrictions in joint play could also be found in the glenohumeral joint into a ventral and caudal direction.

3.3.13 Basic neurological examination according to Kolár (2013)

- Subjective light touch of upper extremities: The corresponding dermatomes of segment C5, C6, C7 and C8 are all feeling normally when simultaneously touched down to the elbow on both sides. Dermatomes C4 and T1 have slightly reduced sensation in the region of the m. biceps brachii of the right UE. In the region of the elbow and all the way to his fingertips there is a complete loss of skin sensation of the right upper extremity.
- Pain sensibility test: the region around the right elbow and below does not respond to any pain provocations of the right upper extremity. Left side is normal.
- Position sense test: the subject does not recognize any positional change on the right upper extremity of the finger, but can slightly feel changes of the wrist. Left upper extremity is normal.
- Two-point discrimination: all the way up to the upper part of his right arm he is not able to detect any difference in a one or a two-point contact (ranging from 3-5 cm). The left arm is normal.
- Deep tendon reflex examination:

Tab. 10. Initial examination of deep tendon reflexes

	Right upper extremity	**Left upper extremity**
Bicipital reflex (C5)	Hyporeflexic	Normoreflexic
Tricipital reflex (C7)	Normoreflexic	Normoreflexic
Finger flexor reflex (C8)	Hyporeflexic	Normoreflexic

3.3.14 Conclusion of initial kinesiological examination

The initial kinesiological examination was performed on Monday the 15th of January 2018 and fully completed on the Tuesday the 16th. The subject of examination is an 18-year old man whom suffered from a car accident back in April 2017. Large trauma to his arm and shoulder region caused both an open humeral fracture and lesion of the terminal branches of the brachial plexus. The forearm is currently plegic with complete loss of sensation and motor

function. A post-surgical infection of the collision wounds of the affected forearm led also to a need for necrotomy to prevent further complications.

The subject's static posture shows characteristics of an upper crossed syndrome as defined by Janda (1983), with the similar muscular imbalances characterizing this habitual holding and alignment. The findings of the joint and muscle length tests also confirm this suggestion. The characteristic capsular pattern of the glenohumeral joint as defined by Cyriax (1993) is present.

The shoulder abduction test reveals altered scapulohumeral rhythm on both sides, with the right side being the most affected. This suggests an altered order of activation and movement stereotype with overcompensation by the upper scapular stabilizers.

Increased tension (Trp's) of the scalenes, sternocleidomastoid, pectoralis minor, subscapularis and upper fixators of the scapula could be palpated on the right side, along with atrophy of the m. deltoid. There was also a trigger point located in the diaphragm. Breathing pattern was however without the use of accessory muscles, with only slight restrictions in lower chest expansion and posterior and lateral diaphragm expansion. Movement restrictions were found at the segment level of C3/C4, C7/T1, and T1/T2. The first ribs were blocked on both sides, and the acromioclavicular joint was restricted in a ventrodorsal and caudocranial direction on the right side.

Based on the muscle strength and nerve supply chart of the right upper extremity, the most severe involvement is that of the terminal branches of the axillary, musculocutaneus, suprascapular, radial, median and ulnar nerves, confirming his medical diagnosis. The medial and lateral cord giving rise to the pectoral nerves seem least affected. Low grading of the muscles innervated by the thoracoscapular nerve might also be due to the nerve graft that was collected. As the muscle testing reveals a bilateral weakness of the lower scapular fixators, this particular weakness might be a result not of the trauma, but rather as a consequence of chronic movement dysfunction. Also, the anthropometric findings show a slight smaller circumference of the total right upper extremity, and visible atrophy of the m. deltoid.

The basic neurological tests show complete loss (anesthesia) of light touch sensation along all dermatomes below the elbow of the right upper extremity. Dermatomes C4 and T1

have slightly reduced sensation (hypesthesia) in the region of the anterior upper arm. Pain sensation is also reduced in this region, and absent below the elbow. The left upper extremity is normal for comparison.

3.3.15 Short-term physiotherapy plan

Short-term plan

A short-term rehabilitation plan will mainly focus on securing complete healing of the humeral fracture and reinnervation of the lesioned nerves. Emphasis should therefore be put on normalizing mobility and tonus to functionally and anatomically linked structures of the superior thoracic outlet and the pectoral girdle. Improving joint range of motion and muscle strength is necessary in order to immediate support his activities of daily living. Any further degradation of motor and sensory function in the fingers, wrist, forearm and elbow should be prevented and ideally also improved. Accepted loading parameters and subjective pain tolerance must be respected when imposing stressors necessary for physiological bone healing (Porter, 2003).

Goal setting

Improve motor and sensory function sufficiently to achieve self-sufficiency and independency at home.

Plan-specific details

- As a preventive measure (mainly preventing atrophy and fibrotisation), electrical stimulation needs to be applied to finger flexors and extensors. This will aid in blood circulation and improve the conditions for nerve growth.
- The joints of the fingers, hand, wrist and elbow will undergo passive range of motion to prevent contractures.
- Improve/maintain skin sensation and proprioception of the arm.
- Soft tissue treatment of active scars.
- Soft tissue manipulation of restricted skin and fascia.

- Aim to restore segmental mobility of restricted spinal segments.
- Aim to restore springing to the first rib and acromioclavicular joints.
- Aim to restore normal joint play of the glenohumeral joint.
- Aim to restore mobility to the restricted scapula.
- Passive exercising of the pectoral girdle musculature.
- Facilitation of weak extremity muscles.
- Relaxation of hypertoned anterior and superior pectoral girdle muscles.
- Aim to strengthen the hypotoned lower scapular fixators.
- Aim to facilitate global physiological postural stabilization.

3.3.16 Long-term physiotherapy plan

The long-term plan will continue the work prescribed in short term, and therefore maintain attention to improving motor and sensory function in the upper extremity and its functional and structural connections. The lesion however, needs in the long term to be viewed not only as a regional dysfunction, but also as a global movement dysfunction (Kolár, 2013). It therefore becomes important to address movement restriction and dysfunction in all key regions of the body (Lewit, 2010). The long-term plan supports a change towards more physiological postural stabilization and joint loading of the global system, minimizing stressors that may disturb newly gained function:

- Prevention of degradation (mainly atrophy and fibrotisation) in the fingers, wrist and forearm by means of electrotherapy, skin stimulation and passive range of movement.
- Progressively increase loading parameters of the humerus.
- Continue the facilitation of weak and paretic muscles.
- Correct any remaining postural muscle imbalances to facilitate optimal joint loading and function.
- Strengthen the postural function of the deep stabilizing system.

3.4 Therapy progresses

3.4.1 Monday 15th of January: initial kinesiological examination

3.4.2 Tuesday 16th of January

10AM Session

Goals of therapy:

- End of initial kinesiological examination.
- Prevent loss of range of motion in the wrist on the affected side.
- Prevent changes in forearm muscle trophicity on the affected side.
- Improve scar tissue quality and fascial mobility of the affected upper extremity.
- Improve mobility of cervicothoracic fascia.
- Relaxation of hypertoned muscles in the region of the superior thoracic outlet on the right side.
- Improve scapular motion in a caudal and medial direction on both sides.
- Release tension of the m. diaphragm.

Therapy session:

- Electro stimulation applied to the wrist extensors and flexors for approx. 10 minutes, using a monopolar technique, with a single pulse stimulation of 30-40 mA. Approx. 10-20 contractions per muscle.
- Passive range of motion exercising of fingers, wrist and elbow into possible directions on the affected arm.
- Soft tissue techniques according to Lewit applied to active scars, skin and fascia on the affected upper arm.
- Relaxation of muscle hypertone utilizing post-isometric relaxation according to Lewit of upper part of m. trapezius on both sides, then relaxation of m. sternocleidomastoid and mm. scaleni on the right side.

- Relaxation of the m. diaphragm in sitting according to Lewit.
- Scapular mobilization according to Lewit in side lying on both sides.

Results:

- Objective: reduced tension in the treated muscles, with a noticeably more caudal joint position of the right humerus. The fascia of the neck and C/T-junction shows more mobility.
- Subjective: the patient can no longer feel any pain upon palpation of the m. sternocleidomastoid and mm. scaleni on the right side.

1PM Session:

Trigger points on the right side in the m. sternocleidomastoid and mm. scaleni are reduced and do no longer produce any local or referred pain upon palpation. The upper part of the m. trapezius on the right side still harbors tension and needs further relaxation.

Goals of therapy:

- Prevent loss of range of motion in the affected wrist.
- Prevent changes in forearm muscle trophicity on the affected arm.
- Specific improvement of contraction of m. biceps brachii on the affected arm.
- Relaxation of hypertoned anterior scapular fixators on both sides.
- Relaxation of the upper part of the m. trapezius on the right side.
- Facilitate weakened extremity musculature of the affected extremity.
- Encourage scapular stabilization and glenohumeral joint centration on both sides.

Therapy session:

- Electro stimulation applied to the right wrist extensors and flexors for approx. 10 minutes, using a monopolar technique, with a single pulse stimulation of 30-40 mA. Approx. 10-20 contractions per muscle.
- Passive range of motion exercising of fingers, wrist and elbow into possible directions of the affected arm.

- Applying the Kenny Method on m. biceps brachii on the affected arm. Repeating the procedure three times.
- Relaxation of muscle hypertone utilizing post-isometric relaxation according to Lewit of m. pectoralis major (clavicular part) and m. pectoralis minor on both sides, and the upper part of the m. trapezius on the right side.
- Proprioceptive neuromuscular facilitation according to Kabat of the right scapula in all four directions utilizing "reversal of antagonists", in side lying.
- Joint centration technique of the glenohumeral joint in side lying, using an extended elbow to prolong the lever. Encouraging isometric contractions to withstand a small external force directed in different directions. Spending more time on the right side then left.

Results:

- Objective: tension in the pectoralis group is reduced on both sides.
- Subjective: the subject reports pain (2/10) in region of the humeral fracture.

3.4.3 Wednesday the 17th of January

The subject feels well rested today and motivated to improve. The clavicular part of the m. pectoralis major and the m. pectoralis minor still harbor tension and are tender upon palpation on the right side only. The session will also aim to restore normal joint play to the glenohumeral and acromioclavicular joints of the right side.

10AM Session

Goals of therapy:

- Prevent loss of range of motion in the wrist on the affected arm.
- Prevent changes in forearm muscle trophicity on the affected arm.
- Improve scar tissue quality and skin sensation on the affected arm.
- Specific improvement of contraction of m. biceps brachii on the affected arm.
- Relaxation of hypertoned anterior scapular fixators on the right side.

- Restore joint play to the glenohumeral and AC-joints on the right side.
- Strengthen active shoulder flexion and extension within the available ROM on the right side.

Therapy session:

- Electro stimulation applied to the right wrist extensors and flexors for approx. 10 minutes, using a monopolar technique, with a single pulse stimulation of 30-40 mA. Approx. 10-20 contractions per muscle.
- Passive range of motion exercising of fingers, wrist and elbow into possible directions of the affected arm.
- Scar tissue and skin sensation treatment according to Lewit on the affected upper extremity.
- Applying the Kenny Method on m. biceps brachii of the affected arm. Repeating the procedure two times.
- PIR principles according to Lewit of the clavicular part of m. pectoralis major and m. pectoralis minor on the right side, in supine lying.
- Mobilization of the glenohumeral joint into caudal and ventral direction according to Lewit on the right side.
- Mobilization of the acromioclavicular joint into dorsoventral and caudocranial direction on the right side, according to Lewit.
- Anti-gravity active glenohumeral flexion and extension of the affected arm with a sling-supported elbow and forearm, in side lying. Fixating the scapula to encourage joint centration. Applying 0.5 kg weighted resistance. 3x10 repetitions.

Results

- Objective: palpable increased tonus of the m. Biceps brachii. Re-testing shows normalization of the joint play at the GH-joint and AC-joint of the right side.
- Subjective: he feels a little bit tired, but no pain felt during the course of the session.

1PM Session

Because the anti-gravity strengthening went well, we will try to apply a slightly more demanding exercise in regards to scapular stabilization. We'll apply this while simultaneously keeping the loading parameter of the humerus in an allowable range. He also responded well to the PNF techniques, and we will therefore continue the proprioceptive facilitation of the affected extremity.

Goals of therapy

- Prevent loss of range of motion in the wrist of the affected arm.
- Prevent changes in forearm muscle trophicity of the affected arm.
- Improve scar tissue quality and skin sensation of the affected arm.
- Specific improvement of contraction of m. biceps brachii of the affected arm.
- Improve proprioception of the upper extremity of the affected arm.
- Encourage physiological scapular stabilization of both sides and facilitating the global stability system.

Therapy session

- Electro stimulation applied to the right wrist extensors and flexors for approx. 10 minutes, using a monopolar technique, with a single pulse stimulation of 30-40 mA. Approx. 10-20 contractions per muscle.
- Passive range of motion exercising of fingers, wrist and elbow into possible directions of the affected arm.
- Scar tissue and skin sensation treatment according to Lewit on the affected upper arm.
- Applying the Kenny Method on m. biceps brachii on the affected side. Repeating the procedure three times.
- PNF on the affected arm according to Kabat utilizing 'reversal of antagonists' and 'hold-relax' techniques into the UE 1.D and 2.D. Particularly focus on 1.D.F and 2.D.F.
- Utilizing a modified developmental position in kneeling according to Kolár, encouraging lower scapular fixator activation (lower part of m. trapezius, m. rhomboids). Moving back and forth, changing the direction of force through the joint.

Results

- Objective: the subject is able to actively stabilize the scapula physiologically during the easier developmental position (with least forces acting against the lower fixators). Respect was carefully paid to accepted loading of the humerus, with minimal weight placed on the right upper extremity.

- Subjective: he feels no pain during the course of the session.

3.4.4 Thursday the 18th of January

Trigger points in the sternocleidomastoid have reappeared on the right side, but tension in the m. pectoralis major and minor is nearly normalized upon palpation. Range of motion in the glenohumeral joint is significantly improving. Focus will be put on the cervicothoracic region in order to reduce tension in the soft tissues surrounding the superior thoracic outlet. We will also continue with the modified developmental positions in kneeling.

10AM Session

Goals of therapy:

- Prevent loss of range of motion in the wrist and elbow of the affected arm.
- Prevent changes in forearm muscle trophicity of the affected arm.
- Improve scar tissue quality on the upper part of the affected arm.
- Specific improvement of contraction of m. biceps brachii of the affected arm.
- Restore segmental mobility to the cervicothoracic junction.
- Reduce tension in the m. sternocleidomastoid on the right side.
- Encourage physiological scapular stabilization on both sides and facilitating the global stability system.

Therapy session

- Electro stimulation applied to the wrist extensors and flexors for approx. 10 minutes, using a monopolar technique, with a single pulse stimulation of 30-40 mA. Approx. 10-20 contractions per muscle.
- Passive range of motion exercising of fingers, wrist and elbow into possible directions, right arm.
- Scar tissue treatment according to Lewit on the affected upper extremity.
- Applying the Kenny Method on m. biceps brachii on the affected arm. Repeating the procedure three times.
- Mobilization of the T1/T2 and T7/T1 segment according to Lewit.
- Post-isometric relaxation of the m. sternocleidomastoid on the right side according to Lewit.
- Utilizing a modified developmental position in kneeling according to Kolár, encouraging lower scapular fixator activation on both sides (lower part of m. trapezius, m. rhomboids).

Results

- Objective: mobilization of the C7/T1 segment was not necessary as the mobilization of the T1/T2 reflexively normalized it. Pain could no longer be felt in the m. sternocleidomastoid after the segment mobilization and PIR.

- Subjective: he feels slightly tired after the session. He reports pain (2/10) in the shoulder region, possible due to his prolonged efforts during the therapy.

1PM Session

This session will be shorter due to the patient's feeling of tiredness.

Goals:

- Prevent loss of range of motion in the wrist of the affected arm.
- Prevent changes in forearm muscle trophicity of the affected arm.

- Improve scar tissue quality on the upper part of the affected arm.
- Specific improvement of contraction of m. biceps brachii of the affected arm.
- Improve scapular motion in medial and caudal directions on both sides.
- Passive movement exercising of the glenohumeral joint of the affected extremity.

Therapy session:

- Electro stimulation applied to the wrist extensors and flexors for approx. 10 minutes, using a monopolar technique, with a single pulse stimulation of 30-40 mA. Approx. 10-20 contractions per muscle.
- Passive range of motion exercising of fingers, wrist and elbow into possible directions of the affected arm.
- Scar tissue treatment according to Lewit on the affected upper extremity.
- Applying the Kenny Method on m. Biceps brachii on the affected arm. Repeating the procedure two times.
- Scapular mobilization according to Lewit in side lying on both sides.
- Passive range of motion exercising of the glenohumeral joint on the right side.

Results

- Objective: the elbow flexion capacity is still very limited. Scar tissues are more pliable.
- Subjective: no pain felt during the session. The patient reports a more “free” feeling of the shoulder.

3.4.5 Friday the 19th of January

Due to bad sleep and a cold developed overnight this session will be short in duration and not demanding for the patient. The scar tissue has improved significantly, and will not be treated in this session. The mobility of the cervicothoracic junction is normal upon testing, but the first ribs and the C3/C4 segment are restricted. We will also work on glenohumeral range of motion restriction into external rotation of the right side by Trp ischemic pressure release according to Travell and Simons (1999).

10AM Session

Goals of therapy

- Prevent loss of range of motion in the wrist
- Prevent changes in forearm muscle trophicity
- Specific improvement of contraction of m. biceps brachii.
- Improve mobility of the first rib on both sides.
- Improve mobility into side bending and rotation of the C3/C4 segment.
- Release tension in the m. subscapularis on the right side.

Therapy session

- Electro stimulation applied to the right wrist extensors and flexors for approx. 10 minutes, using a monopolar technique, with a single pulse stimulation of 30-40 mA. Approx. 10-20 contractions per muscle.
- Passive range of motion exercising of fingers, wrist and elbow into possible directions.
- Applying the Kenny Method on m. Biceps brachii. Repeating the procedure two times.
- Mobilization of the first ribs according to Lewit.
- Mobilization of the C3/C4 into rotation according to Lewit.
- Ischemic pressure treatment of Trp in m. subscapularis according to Travell and Simons.

Results

Objective: rotation and side bending of the cervical spine to the left is restored upon re-testing. The first rib on both sides spring normally, but there is slight pain felt on the right side. Reduced tension in the m. subscapularis of the right side, with the glenohumeral external rotation range of motion consequently improved.

Subjective: the subject complained of radiating pain upon palpation of the m. subscapularis before the treatment. Less pain (2/10) is now felt.

1PM Session

There is still hypertension in the m. subscapularis. We will continue the facilitation of lower scapular stabilization in the modified developmental position, and use PNF according to Kabat to facilitate all strength components in the shoulder on the affected side.

Goals of therapy

- Prevent loss of range of motion in the wrist on the affected side.
- Prevent changes in forearm muscle trophicity on the affected side.
- Specific improvement of contraction of m. biceps brachii on the affected side.
- Release tension in the m. subscapularis of the right side.
- Facilitate all strength components of the shoulder in the affected side.
- Encourage physiological scapular stabilization on both sides and facilitate the global stability system according to Kolár.

Therapy session

- Electro stimulation applied to the right wrist extensors and flexors for approx. 10 minutes, using a monopolar technique, with a single pulse stimulation of 30-40 mA. Approx. 10-20 contractions per muscle.
- Passive range of motion exercising of fingers, wrist and elbow into possible directions of the affected arm.
- Applying the Kenny Method on m. biceps brachii of the affected arm. Repeating the procedure two times.
- Ischemic pressure treatment of Trp in m. subscapularis of the right side according to Travell and Simons.
- PNF according to Kabat utilizing 'reversal of antagonists' techniques into the UE 1.D and 2.D of the affected side.
- Utilizing a modified developmental position in kneeling according to Kolár, encouraging lower scapular fixator activation (lower part of m. trapezius, m. rhomboids).

Results

Objective: Normalization of tonus of the m. subscapularis of the right side without any further improvement of glenohumeral range of motion into external rotation. Improvement can be seen in the developmental positions, but both his scapula starts winging when the angle of the lever arm changes.

The firing of the m. biceps brachii of the affected side is still minimal upon contraction.

Subjective: No pain upon palpation of the m. subscapularis on the right side.

3.4.6 Monday the 22th of January

Today the patient feels more energetic. He slept well during the weekend and the cold has disappeared. A more neutral position of the glenohumeral joint of both sides can be observed from the side view.

The tension of the muscles and soft tissue in superior thoracic outlet on the right side has improved significantly. The remaining focus will therefore be to further improve glenohumeral joint centration and strength, putting most attention to the right affected side. Shortness in the m. teres major, m. latissimus dorsi, and m. rhomboid major and minor on the right side will also be treated.

10AM Session

Goals of therapy

- Prevent loss of range of motion in the wrist on the affected side.
- Prevent changes in forearm muscle trophicity on the affected side.
- Specific improvement of contraction of m. biceps brachii of the affected side.
- Reduce hypertension in the teres major, m. latissimus dorsi, and m. rhomboid major and minor on the right side.

- Continue the progressions made with PNF patterns, improving all strength components of the right upper extremity.

Therapy session

- Electro stimulation applied to right the wrist extensors and flexors for approx. 10 minutes, using a monopolar technique, with a single pulse stimulation of 30-40 mA. Approx. 10-20 contractions per muscle.
- Passive range of motion exercising of fingers, wrist and elbow into possible directions of the affected side.
- Applying the Kenny Method on m. biceps brachii of the affected side. Repeating the procedure three times.
- Utilizing PIR principles according to Lewit to reduce tension in the teres major, m. latissimus dorsi, and m. rhomboid major and minor on the right side.
- PNF of the right scapula according to Kabat in side lying, emphasizing hold-relax into in posteromedial direction.
- PNF 2.D.F of right upper extremity according to Kabat, with reversal of antagonists and hold-relax.

Results

- Objective: the patient shows stronger rotational strength in the PNF patterns of the right side.

- Subjective: the subject reports a small sensation of pain (2/10) in the end range of shoulder flexion of the right side during the PNF 2.D pattern.

1PM Session

We will continue the therapy from the 10pm session.

Goals of therapy

- Prevent changes in forearm muscle trophicity of the affected side.
- Prevent loss of range of motion in the wrist of the affected side.
- Specific improvement of contraction of m. biceps brachii of the affected side.
- Continue with PNF patterns, improving proprioception and strength of the affected side.
- Encourage physiological scapular stabilization of both side and facilitating the global stability system.

Therapy session

- Electro stimulation applied to the right wrist extensors and flexors for approx. 10 minutes, using a monopolar technique, with a single pulse stimulation of 30-40 mA. Approx. 10-20 contractions per muscle.
- Passive range of motion exercising of fingers, wrist and elbow into possible directions of the affected side.
- Applying the Kenny Method on m. biceps brachii of the affected side. Repeating the procedure three times.
- PNF 2.D.F of right upper extremity according to Kabat, with reversal of antagonists and hold-relax.
- Utilizing a modified developmental position in kneeling according to Kolár, encouraging lower scapular fixator activation (lower part of m. trapezius, m. rhomboids). He is asked to resist being pushed out of position, by isometrically stabilizing both the pelvis and the scapula. He is also asked to move slightly forward and backwards in order to change the angle of force acting through the shoulder, while isometrically holding the intended position. Minimal loading placed on the humerus.

Results:

- Objective: the patient responded well to the developmental position, but finds it very difficult to maintain scapular fixation when the shoulder angle changes. No progressions to more demanding positions can be made yet.
- Subjective: The patient is very satisfied with the strength progressions being made with the PNF patterns of the affected upper extremity.

3.4.7 Tuesday the 23th of January

We will continue the work from yesterday, but also prepare him for regular self-treatment, as this is the last day of receiving therapy as being an inpatient.

10AM Session

Goals of therapy

- Prevent changes in forearm muscle trophicity of the affected side.
- Specific improvement of contraction of m. biceps brachii of the affected side.
- Continue with PNF patterns, improving proprioception and strength of the affected side.
- Encourage physiological scapular stabilization on both sides and facilitating the global stability system.

Therapy session

- Electro stimulation applied to the right wrist extensors and flexors for approx. 10 minutes, using a monopolar technique, with a single pulse stimulation of 30-40 mA. Approx. 10-20 contractions per muscle.
- Passive range of motion exercising of fingers, wrist and elbow into possible directions of the affected side.

- Applying the Kenny Method on m. biceps brachii on the affected side. Repeating the procedure three times.
- PNF 2.D.F of right upper extremity according to Kabat, with reversal of antagonists and hold-relax.
- PNF of the right scapula according to Kabat in side lying, emphasizing hold-relax into in posteromedial direction.
- Utilizing a modified developmental position in kneeling according to Kolár, encouraging lower scapular fixator activation (lower part of m. trapezius, m. rhomboids).

Results

- Objective: the patient responds well to the PNF of the right scapula, with an increased ability to move the scapula against resistance in a posteromedial direction (strengthening the medial and lower fixators).
- Subjective: no pain is felt during the session, but gets easily exhausted during the developmental positioning.

1PM Session

This session we will mainly dedicate to self-treatment along with the regular electrotherapy and passive exercising of the fingers, wrist and elbow.

Goals:

- Prevent changes in forearm muscle trophicity of the affected side.
- Prevent loss of range of motion in the wrist of the affected side.
- Prepare some basic exercises that he can practice at home.

Therapy:

- Electro stimulation applied to the right wrist extensors and flexors for approx. 10 minutes, using a monopolar technique, with a single pulse stimulation of 30-40 mA. Approx. 10-20 contractions per muscle.

- Passive range of motion exercising of fingers, wrist and elbow into possible directions of the affected side.
- Self-treatment instructions.

Self-treatment

- Developmental kneeling position. The patient is instructed to move back and forth, changing the angle of force going through the shoulder joints. He is recommended to at least 3 sets per day, with 5-10 repetitions going back and forth. When he feels like he's loosing the fixating position of the scapula, he is instructed to take a break.
- Nodding of the head. The patient is instructed to perform slow nodding of the head, pushing the chin towards the back of the spine, with the intention to strengthen the deep neck flexors and reciprocally inhibit compensational recruitment of the m. sternocleidomastoid. As he progress, he can shift from sitting to supine lying. The patient is recommended to perform 2-3 sets of 5 slow repetitions, repeating this procedure 2-3 times per day if possible.
- Other self-treatment exercises were also prescribed by the doctors, encouraging strength increase of shoulder movements useful in activities of daily living.

3.4.8 Wednesday the 24th of January: final kinesiological examination

Wednesday the 24th of January marks the end of the patient's hospitalization period in Oblastní Nemocnice Kladno. He will from now on continue as an outpatient with weekly visits at the outpatient department for continual rehabilitation.

3.5 Final kinesiological examination (Date: 24.01.18)

3.5.1 Postural observations

Pic. 7. Final postural front view

Pic. 8. Final postural back view

Pic. 9. Final postural left view

Pic. 10. Final postural right view

Final front view (see pic. 7) - base of support slightly tilted to the right, excessive lateral rotation of the right femur, medially rotated humeri (left more than right), atrophy of the m. deltoid of the right shoulder, tissue folding on the left side above the epigastric region.

Final back view (see pic. 8) – slight knock-knees, normalization of tonus in the thoracolumbar region on the left side.

Final left side view (see pic. 9) – protraction of the left shoulder, slight flexion of the left elbow with less closed fingers.

Final right side view (see pic. 10) – forward shifted center of gravity, pelvic anteflexion, protruding abdominal wall, ribcage tilted downwards, marked decreased protraction of the right shoulder, hyperlordosis in the upper cervical region, forward head position.

Notes: characteristic signs of what Janda (1983) defines as an upper crossed syndrome are still present, but the right shoulder is more neutrally positioned with less protraction and less medial rotation. The left elbow is less flexed and the fingers more open. The paravertebral hypertone on the left side of the thoracolumbar region is reduced.

3.5.2 Anthropometric data

Tab. 11. Final anthropometric measurements

LENGTH OF THE UPPER EXTREMITIES	**RIGHT**	**LEFT**
Total length	73,5 cm	73 cm
The length of the humerus	29 cm	28,5 cm
The length of the forearm	25 cm	25 cm
The length of the hand	19,5 cm	19,5 cm
CIRCUMFERENCES		
The circumference of the upper arm	36 cm	38 cm
The circumference of the forearm	21 cm	22 cm

3.5.3 Breathing pattern investigation

Breathing occurs now also with ventral expansion of the lower chest. Lateral and posterior expansion of the diaphragm is still not present.

3.5.4 Dynamic spine test investigation

Tab. 12. Final test of basic movements of the spine and pelvis

Type of movement	**General mobility**		**Segmental mobility**	
Retroflexion	The sum of all joints display normal range of motion. No (0/10) is felt during the movement.		Restricted mobility of the lower lumbar spine, with hypermobility visual in the thoracolumbar junction.	
Anteflexion	The sum of all joints display restricted range of motion. Curling of individual segments occurs more fluidly in the cervicothoracic region. No pain (0/10) is felt during the movement.		Restricted motion can be seen in mainly in the lumbar spine.	
	RIGHT	**LEFT**	**RIGHT**	**LEFT**
Lateroflexion	The sum of all joints shows slight restricted range of motion. Rotational	The sum of all joints shows slight restricted range of motion. Rotational	Mainly restrictions in the thoracic region.	Mainly restrictions in the thoracic region.

	synkineses of the pelvis to the contralateral side is present.	synkineses of the pelvis to the contralateral side is present.		

3.5.5 Joint range of motion tests according to Kendall (2005)

The results are given in degrees and according to the SFTR-method (except for neck).

Tab. 13. Final test of joint range of motion according to Kendall

CERVICAL SPINE				
MOVEMENT AND NORMS	**RIGHT**		**LEFT**	
	ACTIVE	PASSIVE	ACTIVE	PASSIVE
Rotation (75)	65	75	70	75
Lat. Flex (45-60)	40	45	30	35
	ACTIVE		PASSIVE	
Flexion (45)	40		45	
Extension (45)	40		45	
SHOULDER JOINT				
NORMS	**RIGHT**		**LEFT**	
	ACTIVE	PASSIVE	ACTIVE	PASSIVE
S: 45-0-180	S: 5-0-170	S: 35-0-175	S: 35-0-170	S: 40-0-180
F: 150-0-0	F: 145-0-0	F: 150-0-0	F: 140-0-0	F: 150-0-0
T: 30-0-120	T: 10-0-100	T: 15-0-110	T: 20-0-115	T: 25-0-120
R: 90-0-70	R: 65-0-60	R: 75-0-70	R: 80-0-60	R: 90-0-70
ELBOW JOINT				
NORMS	**RIGHT**		**LEFT**	
	ACTIVE	PASSIVE	ACTIVE	PASSIVE

S: 0-0-145	0-0-0	0-0-125	0-0-120	0-0-135
RADIOULNAR JOINT				
NORMS	**RIGHT**		**LEFT**	
	ACTIVE	PASSIVE	ACTIVE	PASSIVE
	0-0-0	70-0-70	75-0-75	90-0-90
WRIST JOINT				
NORMS	**RIGHT**		**LEFT**	
	ACTIVE	PASSIVE	ACTIVE	PASSIVE
S: 70-0-80	0-0-0	35-0-50	60-0-60	70-0-70
F: 20-0-30	0-0-0	10-0-20	15-0-25	20-0-30

3.5.6 Length of selected muscles according to Kendall (2005)

Tab. 14. Final tests of muscle length according to Kendall

MUSCLES	**RIGHT**	**LEFT**
m. Pectoralis minor, m. biceps brachii and m. coracobrachialis	Shortness only for m. pectoralis minor.	Shortness only for m. pectoralis minor.
m. Pectoralis major; clavicular and sternocostal parts	Normal.	Normal.
m. Teres major, latissimus dorsii and m. rhomboid major and minor.	Shortness	Normal.
Medial rotators of the glenohumeral joint	Shortness.	Normal.
Lateral rotators of the glenohumeral joint	Normal.	Normal.

3.5.7 Active movement against resistance of the cervical spine

Tab. 15. Final tests of active movement against resistance

DIRECTION OF ISOMETRIC RESISTANCE		
Anteflexion	Answers with moderately strong pressure. No (0/10) felt.	
Retroflexion	Answers with strong pressure. No (0/10) pain felt.	
	RIGHT	**LEFT**
Side-bending	No pain (0/10) felt.	No pain (0/10) felt.

3.5.8 Palpation

Chest examination:

- No restrictions of fascial mobility on both sides.
- Normotonic m. pectoralis minor on both sides (with slight higher tension in the right).
- Slightly higher tonus of the m. pectoralis major on the left side.
- Palpation of the acromioclavicular joint on both sides does not provoke any pain.

Scapula examination:

- Slight hypertone of the m. subscapularis of right side.

Neck examination:

- Normotonic upper fibers of m. trapezius on right side, slightly hypertone on the left side.
- Normotonic m. sternocleidomastoid and m. scaleni on both sides.
- First ribs slightly tender upon palpation on right side.

- Normal mobility of the cervicothoracic fascia.

Upper extremities (right):

- Atrophy of the deltoid muscle.
- Improvement of scar tissue quality of the affected arm.
- Large scar formation lying horizontally above the articulations of the elbow.
- Restrictions of all soft tissues of the forearm due to muscle removals.

3.5.9 Manual muscle strength tests comparing sides according to Kendall (2005)

Tab. 16. Final tests of muscle strength according to Kendall

RIGHT	**MUSCLE/MUSCLE GROUP**	**LEFT**
2	Coracobrachialis	**5**
4+	Supraspinatus	**5**
4	Middle deltoid	**4+**
4+	Anterior deltoid	**5**
4-	Posterior deltoid	**4+**
4+	Pectoralis major (p. clav.)	**5**
5-	Pectoralis major (p. stern.)	**5**
4+	Pectoralis minor	**5**
3+	Lateral rotators	**4+**
3	Medial rotators	**5**
3	Teres maj. & Subscapularis	**4+**
3	Latissimus dorsii	**4+**
1+	Biceps brachii	**5**
4	Triceps brachii	**5**
3	Rhomboids, Levator scapulae, Trapezius	**4**
4+	Upper Trapezius	**5**

3-	Middle Trapezius	**4-**
3-	Lower Trapezius	**4-**
4+	Serratus anterior	**5**

NOTES: No change in the strength of m. coracobrachialis and m. biceps brachii. Only a slight increase in strength could be observed of the middle and lower parts of m. trapezius.

3.5.10 Muscle strength and nerve supply chart according to Kendall (2005)

Tab. 17. Final chart of muscle strength and nerve supply according to Kendall

	MUSCLE STRENGTH GRADING	RIGHT ARM	PERIPHERAL NERVES																			KEY D = dorsal prim. Ramus V = ventral prim. Ramus PR = plexus root ST = superior trunk P = posterior cord L = lateral cord M = medial cord								
			CERVICA	T	D	V	V	V	PR	PR	ST	ST	P	P	P	L	M	P	L	P	LM	M									
			1-8	1													1			1	1	1									
			1-8		1-8	1-4	3,4,5	5,6,7,8	4,5	5,6	4,5,6,	4,5,6,7	5,6,7,8	5,6,7	5,6,7	6,7,8	5,6	4,5,6,7	5,6,7,8	5,6,7,8	7,8									
		MUSCLE	CERVICAL	CERVICAL	CERVICAL	PHRENIC	LONG THORACIC	DORS. SCAPULAR	N. TO SUBCLAV.	SUPRASCAPULAR	U. SUBSCAPULAR	THOR.DORASAL	L. SUBSCAPULAR	LAT. PECTORAL	MED.PECTORAL	AXILLARY	MUSCULOCUTAN.	RADIAL	MEDIAL	ULNAR		SPINAL SEGMENT									
																						C1	C2	C3	C4	C5	C6	C7	C8	T1
	-	Head and neck ext.																				1	2	3	4	5	6	7	8	1
CERVICAL PLEXUS	-	Infrahyoid muscles																				1	2	3						
	-	Rectus capitis ant. and lat.																				1	2							
	-	Longus capitis																				1	2	3	4					
	-	Longus colli																					2	3	4	5	6	7		
	3	Levator scapulae																						3	4	5				

	-	Scalene ant., med. and lat.		□																			3	4	5	6	7	8	
	-	Sternocleidomastoid			□																1	2	3						
	3 -	Trapezius, lower, middle			□																	2	3	4					
		Diaphragm				□																	3	4	5				
BRACHIAL PLEXUS	4 +	Serratus anterior					□																		5	6	7	8	
	3	Rhomboid maj. and min.						□																4	5				
	-	Subclavius							□																5	6			
	4 +	Supraspinatus								□														4	5	6			
	3	Infraspinatus								□														4	5	6			
	3	Subscapularis									□		□												5	6	7		
	3	Latissimus dorsi										□														6	7	8	
	3	Teres major											□												5	6	7		
	4 +	Pectoralis major upper												□											5	6	7		
	5 -	Pectoralis major lower												□	□											6	7	8	1
	4 +	Pectoralis minor													□											6	7	8	1
Axil.	3	Teres minor														□									5	6			
	4	Deltoid														□									5	6			
Musc.	2	Coracobrachialis															□									6	7		
	1 +	Biceps															□								5	6			
	1	Brachialis															□								5	6			
RADIAL	4	Triceps																□								6	7	8	1
	-	Anconeus																□									7	8	
	-	Brachialis (small part)																□							5	6			
	-	Brachioradialis																□							5	6			
	0	Extensor carpi rad. long.																□							5	6	7	8	
	0	Extensor carpi rad. brev.																□							5	6	7	8	
	0	Supinator																□							5	6			
	0	Extensor digitorum																□								6	7	8	

	0	Extensor digit minimi																							**6**	**7**	**8**	
	0	Extensor carpi ulnaris																							**6**	**7**	**8**	
	0	Abductor pollicis longus																							**6**	**7**	**8**	
	0	Extensor pollicis brevis																							**6**	**7**	**8**	
	0	Extensor pollicis longus																							**6**	**7**	**8**	
	0	Extensor indicis																							**6**	**7**	**8**	
MEDIAN	**0**	Pronator teres																							**6**	**7**		
	0	Flexor carpi radialis																							**6**	**7**	**8**	
	0	Palmaris longus																							**6**	**7**	**8**	**1**
	0	Flexor digitorum sup.																								**7**	**8**	**1**
	0	Flexor digi. prof. 1,2																								**7**	**8**	**1**
	0	Flexor pollicis longus																							**6**	**7**	**8**	**1**
	0	Pronator quadrutus																								**7**	**8**	**1**
	0	Abductor pollicis brevis																							**6**	**7**	**8**	**1**
	0	Opponens pollicis																							**6**	**7**	**8**	**1**
	0	Flexor pollicis brevis																							**6**	**7**	**8**	**1**
	0	Lumbricales 1,2																							**6**	**7**	**8**	**1**
ULNAR	**0**	Flexor carpi ulnaris																								**7**	**8**	**1**
	0	Flexor digi. prof. 3,4																								**7**	**8**	**1**
	0	Palmaris brevis																								**7**	**8**	**1**
	0	Abductor digiti minimi																								**7**	**8**	**1**
	0	Opponens digiti minimi																								**7**	**8**	**1**
	0	Flexor digiti minimi																								**7**	**8**	**1**
	0	Palmar interossei																									**8**	**1**
	0	Dorsal interossei																									**8**	**1**
	0	Lumbricales 3,4																								**7**	**8**	**1**
	0	Adductor pollicis																									**8**	**1**
	0	Flexor pollicis brevis																									**8**	**1**

3.5.11 Basic movement pattern examination

Tab. 18. Final examination of basic movement patterns

	RIGHT	LEFT
SHOULDER ABDUCTION	- Scapulohumeral rhythm: less substitution by the upper scapular fixators, but the rhythm is still slightly altered.	- Slight increased scapulohumeral rhythm ratio.
NECK FLEXION	- Normal neck flexion with normal involvement of deeper neck flexors.	
TRUNK FLEXION	- Ribs are still flaring, and substitutions along the anterior muscle chain are observed. Increased involvement of the m. sternocleidomastoid.	

3.5.12 Joint play/screening examination according to Lewit (2010)

Tab. 19. Final examination of joint play/joint screening

	JOINT		JOINT PLAY/SCREENING	RESULT
AO, CERVICAL, AND C/T-JUNCTION	**C0/C1**		Anteflexion Retroflexion Lateroflexion Rotation Shifting	No restrictions in either direction.
	C1/C2		Rotation Side bending	No restrictions
	C2-C6		Rotation Side bending Shifting	No restrictions
	C6-T3		Rotation Side bending Shifting	No restrictions
1st RIB	Left		Springing pressure from above	No restrictions
			Neck flexion in lateral rotation	No restrictions
	Right		Springing pressure from above	No restrictions
			Neck flexion in lateral rotation	No restrictions
UPPER EXTREMITY	RIGHT	Scapula	(In side-lying position)	Restricted in caudal direction without crepitation.
		AC-joint	Ventrodorsal direction Caudocranial direction	Not restricted
		SC- joint	Pressure in cranial direction	Not restricted

		Shoulder	Caudal direction	Not restricted
			Cranial direction	Not restricted
			Ventral direction	Not restricted
			Dorsal direction	Not restricted
		Elbow	Radial direction	Not restricted
			Ulnar direction	Not restricted
		Wrist	Dorsal direction	Not restricted
			Palmar direction	Not restricted
	LEFT	Scapula	(In side-lying position)	Not restricted
		AC-joint	Ventrodorsal direction Caudocranial direction	Not restricted Not restricted
		SC-joint	Pressure in cranial direction	Not restricted
		Shoulder	Caudal direction	Not restricted
			Cranial direction	Not restricted
			Ventral direction	Not restricted
			Dorsal direction	Not restricted
		Elbow	Radial direction	Not restricted
			Ulnar direction	Not restricted
		Wrist	Dorsal direction	Not restricted
			Palmar direction	Not restricted

NOTES: Restrictions of scapular mobility in a caudal direction without crepitation in the right shoulder.

3.5.13 Basic neurological examination according to Kolár (2013)

- Subjective light touch of upper extremities: The corresponding dermatomes of segment C5, C6, C7, C8, and T1 are all feeling normally when simultaneously touched down to the elbow. Skin sensation in the elbow and below is slightly changed, with improved sensation approx. 5-7 cm distally to the elbow.
- Pain sensibility test: the elbow region registers pain normally, but looses its sensibility when tested in the forearm region and more distally.

- Position sense test: does not recognize any positional change of the finger, but can slightly feel changes of the wrist.
- Two-point discrimination: he is able to discriminate normally in the upper part of the right arm normally, with exceptions of the C5 dermatome in the m. biceps brachii area.
- Deep tendon reflex examination

Tab. 20. Final examination of deep tendon reflexes

	Right upper extremity	**Left upper extremity**
Bicipital reflex (C5)	Hyporeflexic	Normoreflexic
Tricipital reflex (C7)	Normoreflexic	Normoreflexic
Finger flexor reflex (C8)	Hyporeflexic	Normoreflexic

3.5.14 Conclusion of final kinesiological examination

The final kinesiological examination was performed on Wednesday the 24th of January 2018 after 12 therapy sessions on Mr. J. V. The subject was hospitalized with indications of rehabilitation after surgery of open proximal humeral fracture dated back to 16.04.17 and surgery of the brachial plexus injury dated 11.01.17.

In the final kinesiological examination it was found that the patient has improved in several ways, which were in accordance with the goals of therapy. This includes improvement in muscle strength, glenohumeral and cervical joint range of motion, reduced hypertonicity in functionally chained muscles, fascial mobility and improved joint positioning of the affected shoulder. Joint restrictions are normalized upon testing with the exception of caudal scapular motion. Global changes in posture cannot be seen yet, as the final postural examination still shows important characteristics of what Janda (1983) defines as an “upper crossed syndrome”. The muscle tests show weak, but improved grades of strength in the region of the shoulder. Sensory functions in the distal part of the affected arm are slightly improved, but palsy is still fully present of motor and sensory function of the fingers, wrist and radioulnar joint. Finally, occasional minor symptoms of pain (2/10) during weight bearing or movement might suggest that the fracture is yet to heal completely (Porter, 2003).

3.6 The effect of therapy

3.6.1 Statistical data comparing initial and final examination

3.6.1.1 Muscle strength comparison

Tab. 21. Comparison between initial and final muscle strength examination according to Kendall of the right upper extremity

INITIAL EXAMINATION	MUSCLE/MUSCLE GROUP	FINAL EXAMINATION
2	Coracobrachialis	**2**
4	Supraspinatus	**4+**
3	Middle deltoid	**4**
3	Anterior deltoid	**4+**
3	Posterior deltoid	**4-**
4	Pectoralis major (p. clav.)	**4+**
4+	Pectoralis major (p. stern.)	**5-**
4+	Pectoralis minor	**4+**
2+	Lateral rotators	**3+**
3-	Medial rotators	**3**
2+	Teres maj. & Subscapularis	**3**
2+	Latissimus dorsii	**3**
1+	Biceps brachii	**1+**
3+	Triceps brachii	**4**
2+	Rhomboids, Levator scapulae, Trapezius	**3**
4+	Upper Trapezius	**4+**
2+	Middle Trapezius	**3-**
2+	Lower Trapezius	**3-**
4-	Serratus anterior	**4+**

3.6.1.2 Joint range of motion comparison

Tab. 22. Comparison between initial and final joint range of motion according to Kendall of the right shoulder joint complex

SHOULDER JOINT				
NORMS	**INITIAL EXAMINATION**		**FINAL EXAMINATION**	
	ACTIVE	PASSIVE	ACTIVE	PASSIVE
S: 45-0-180	S: 0-0-150	S: 35-0-155	S: 5-0-170	S: 35-0-175
F: 150-0-0	F: 130-0-0	F: 135-0-0	F: 145-0-0	F: 150-0-0
T: 30-0-120	T: 10-0-100	T: 15-0-110	T: 10-0-100	T: 15-0-110
R: 90-0-70	R: 60-0-60	R: 70-0-70	R: 65-0-60	R: 75-0-70

3.6.1.3 Results

Specific selected statistical changes from initial to final kinesiological exam reveal a global increase in muscular strength, with particular change in grade of the middle and anterior part of the m. deltoid and the lateral rotator group, mainly encompassing the m. suprascapularis, m. infrascapularis and m. teres minor, highlighted in light yellow color (see tab. 21). No changes in strength could be seen upon the final testing of the m. biceps brachii, m. coracobrachialis, m. pectoralis minor or the upper part of the m. trapezius, highlighted in light orange color.

From the joint range of motion testing (see. tab. 22), the most significant changes could be seen in the shoulder joint, resulting in significant increase in both active and passive range of motion in the sagittal, frontal and rotational plane. No change could be seen in the transverse plan of motion. Positive changes are highlighted in light yellow color, and light orange color indicating no change.

3.6.2 Evaluation

The patient entered Oblastní Nemocnice Kladno after surgeries including humeral bone reduction, repair of terminal branches of the brachial plexus and necrotomy of post-surgical infection of collision wounds in the forearm. Priorities of rehabilitation emphasized the importance of securing complete physiological healing of the fractured humerus and reinnervation of the lesioned terminal nerves. Improving decreased muscle strength and restricted joint range of motion was central in order to immediately support his activities of daily living. This implied as well a treatment strategy aimed to normalize altered muscle tonicity and tissue mobility to functionally and anatomically linked structures in the region of the pectoral girdle.

The patient was challenged in a variety of different ways in order to be fully perceptive and sensible in dealing with certain areas of attention, either during postural stabilization work to encourage lower scapular stabilization or visualization during the application of Kenny method to the m. biceps brachii in order to facilitate contraction. Through such careful attention to details and awareness of joint position he was able during the two weeks of therapy to make considerable improvements in joint function.

Even though sensory or motor recovery might not be obtainable for distal extremity function, he should be able to continue to improve significantly in shoulder and elbow function. The 26th of January marked the end of his hospitalization period at the hospital, and will from now on continue with weekly treatment at the outpatient department. He will also need to apply daily self-therapy and exercising in order to reach his highest level of potential improvement.

Therapeutic methods that could prove to continue to be applied later in his rehabilitation plan are principals from the Kenny Method, Proprioceptive Neuromuscular Facilitation (PNF) and developmental positioning within the system of Dynamic Neuromuscular Stabilization (DNS).

4 Conclusion of the study

The utmost goal of rehabilitation after brachial plexus injuries is to restore normal pectoral girdle and upper extremity function. Advances in microsurgery as well as neurorehabilitation have led to large improvements in functional outcomes. Despite this fact, many patients are still suffering severe impairments, with only moderate potential in terms of regeneration of function. Nevertheless, scientific and clinical research demonstrates the general beneficial effects of both early and prolonged rehabilitation after surgical repair (Jaggi et al., 2004).

During the two weeks of clinical practice at Oblastní Nemocnice Kladno, I was offered the opportunity to work with my patient as well as multiple others in the department of rehabilitation. My supervisors did a superb job of enriching my educational experience and holistic understanding by sharing their expert knowledge and skill in the field of rehabilitative therapy.

The patient in this case study was a privilege to work with, as he was greatly motivated and eager to improve his state of condition, participating actively during the sessions and continually sustained a positive outlook. I believe this was a detrimental factor for his improvements of function. I also believe that with more personal clinical experience, the effects of therapy might have been further accelerated, but physical therapy must be recognized as a vastly comprehensive field of study, requiring many years of practice and reflection in order to obtain a fine-tuned clinical reasoning skill and understanding of the wide range of interconnected factors influencing treatment outcomes.

The two weeks spent at Oblastní Nemocnice Kladno was a great experience and I am very satisfied with my supervisors and location of choice, as well as the treatment outcome of this case study. Neurological injuries have truly been an important field of interest for me since I started the Bachelor program in Physiotherapy, and for that I am grateful to be given this valuable opportunity of further insights and exploration.

5 Bibliography

1. Abu-Sittah, G. S., Bakhack, J., & El Khatib, A. (2017). Management of Brachial Plexus Injuries. In: G. S. Abu-Sittah, J. J. Hoballah, & J. Bakhack (Eds.), *Reconstructing the War Injured Patient.* Switzerland: Springer.

2. Azar, F. M., Beaty, J. H., & Canale, S. T. (2017). *Campbell's Operative Orthopaedics* (13th ed.). United States: Elsevier Ltd.

3. Birch, R., & Tunstall, R. (2016). Pectoral girdle and upper limb: overview and surface anatomy. In: S. Standring (Ed.), *Gray's Anatomy: The Anatomical Basis of Clinical Practice* (pp. 776-793). United States: Elsevier Ltd.

4. Boyd, K. U., Nimigan, A. S., & Mackinnon, S. E. (2011). Nerve reconstruction in the hand and upper extremity. *Clinical Plastic Surgery, 38*(4), 643-660.

5. Campbell, W. W. (2008). Evaluation and management of peripheral nerve injury. *Clinical Neurophysiology, 119*(9), 1951-1965.

6. Carmichael, S. W., & Hart, D. L. (1985). Anatomy of the Shoulder Joint. *Journal of Orthopaedic and Sports Physical Therapy, 6*(4), 225-228.

7. Cyriax, J. H. (1993). *Cyriax's Illustrated Manual of Orthopaedic Medicine (2. Ed.).* London: Butterworth-Heinemann Ltd.

8. Emamhadi, M., Chabok, S. Y., Samini, F., Alijani, B., Behzadnia, H., Firozabadi, F. A., & Reihanian, Z. (2016). Anatomical Variations of Brachial Plexus in Adult Cadavers; A Descriptive Study. *The Archives of Bone and Joint Surgery, 4*(3), 253-258.

9. Hems, T. (2015). Brachial Plexus Injuries. In: R. S. Tubbs, E. Rizk, M. M. Shoja, M. Loukas, N. Barbaro, & R. Spinner (Eds.), *Nerves and Nerve Injuries, Volume 2: Pain, Treatment, Injury, Disease, and Future Directions.* United States: Elsevier Ltd.

10. Hems, T. E. J., & Mahmood, F. (2012). Injuries to the terminal branches of the infraclavicular brachial plexus. *Journal of Joint and Bone Surgery Britain, 94*(6), 799-804.

11. Jaggi, A., Birch, R., Dean, L., Johnson, K., & Tripp, S. (2004). Peripheral nerve injuries. In: M. Law & H. Allen (Eds.), *Physical Management in Neurological Rehabilitation* (pp. 153-175). London: Elsevier Ltd.

12. Janda, V. (1983). *Muscle Function Testing.* London: Butterworths.

13. Kabat, H. (1950). Studies on Neuromuscular Dysfunction, XIII: new concepts and techniques of neuromuscular reeducation for paralysis. *Permanente Foundation medical bulletin*, *8*(3), 121-143.

14. Kapandji, I. A. (1982). *The Physiology of the Joints: Annotated diagrams of the mechanics of the human joints, Volume One, Upper Limb* (5th ed.). United States: Churchill Livingstone.

15. Kendall, F. P., McCreary, E. K., Provance, P. G., Rodgers, M. M., & Romani, W. A. (2005). *Muscles, Testing and Function with Posture and Pain (5. Ed.).* United States: Lippincott Williams & Wilkins.

16. Kibler, B. W., & Sciascia, A. (2009). Current concepts: scapular dyskinesis. *British Journal of Sports Medicine, 44*(5), 300-305.

17. Kolár, P. (2013). *Clinical Rehabilitation.* Prague: Alena Kobesová

18. Lambert, S. M. (2016). Shoulder girdle and arm. In: S. Standring (Ed.), *Gray's Anatomy: The Anatomical Basis of Clinical Practice* (pp. 797-836). United States: Elsevier Ltd.

19. Lee, M., & Guyuron, B. (2015) Postoperative Neuromas. In: R. S. Tubbs, E. Rizk, M. M. Shoja, M. Loukas, N. Barbaro & R. J. Spinner (Eds.), *Nerves and Nerve Injuries, Volume 2: Pain, Treatment, Injury, Disease, and Future Directions* (pp. 99-111). United States: Elsevier Ltd.

20. Lewit, K. (2010). *Manipulative Therapy: Musculoskeletal Medicine.* Amsterdam: Elsevier.

21. Lynn, L. (2011). *Clinical Kinesiology and Anatomy* (5th ed.). United States: F. A. Davis Company.

22. Martinez-Pereira, M. A., & Zancan, D. M. (2015). Comparative Anatomy of the Peripheral Nerves. In: R. S. Tubbs, E. Rizk, M. M. Shoja, M. Loukas, N. Barbaro & R. J. Spinner (Eds.), *Nerves and Nerve Injuries, Volume 1: History, Embryology, Anatomy, Imaging, and Diagnosis* (pp. 55-77). United States: Elsevier Ltd.

23. Nathan, J. K., & McGillicuddy, J. E. (2015). Anatomy of the Ventral Rami, Upper Trunk, and Its Divisions and Branches. In: R. S. Tubbs, E. Rizk, M. M. Shoja, M. Loukas, N. Barbaro & R. J. Spinner (Eds.), *Nerves and Nerve Injuries, Volume 1: History, Embryology, Anatomy, Imaging, and Diagnosis* (pp. 527-535). United States: Elsevier Ltd.

24. Noble, J., Munro, C. A., Prasad, V. S. S. V., & Midha, R. (1998). Analysis of Upper and Lower Extremity Peripheral Nerve Injuries in a Population of Patients with Multiple Injuries. *Journal of Trauma, 45*(1), 116-122.

25. Ombregt, L., Bisschop, P., & ter Veer, H. J. (2013). *A System of Orthopaedic Medicine* (3rd ed.). United States: Elsevier Ltd.

26. Park, H. R., Lee, G. S., Kim, S., & Chang, J. –C. (2017). Brachial Plexus Injury in Adults. *Journal of the Korean Society of Peripheral Nervous System, 3*(1), 01-11.

27. Patel, S. (2015). Human Dermatomes. In: R. S. Tubbs, E. Rizk, M. M. Shoja, M. Loukas, N. Barbaro & R. J. Spinner (Eds.), *Nerves and Nerve Injuries, Volume 1: History, Embryology, Anatomy, Imaging, and Diagnosis* (pp. 527-535). United States: Elsevier Ltd.

28. Porter, S. B. (2003). Tidy's Physiotherapy (13th ed.). United Kingdom: Elsevier Ltd.

29. Rankine, J. J. (2004). Adult traumatic brachial plexus injury. *Clinical Radiology, 59*(9), 767-774.

30. Robinson, L. R. (2008). Traumatic Injury to Peripheral Nerves. *Muscle & Nerve, 23*(6), 863-873.

31. Roche, S. J., Funk, L., Sciascia, A., & Kibler, B. W. (2015) Scapular dyskinesis: the surgeon's perspective. *Journal of Shoulder and Elbow, 7*(4), 289-297.

32. Saliba, S., Saliba, E. N., Pugh, K. F., Chhabra, A., & Diduch, D. (2009). Rehabilitation Considerations of a Brachial Plexus Injury With Complete Avulsion of C5 and C6 Nerve Roots in a College Football Player: A Case study. *Sports Health, 1*(5), 370-375.

33. Sanders, R. J. (2013). Anatomy of the Thoracic Outlet and Related Structures. In: K. A. Illig, R. W. Thompson, J. A. Freischlag, D. M. Donahue, S. E. Jordan, & P. I. Edgelow (Eds.), *Thoracic Outlet Syndrome* (pp. 17-28). United States: Springer-Verlag.

34. Schlegel, T. F., & Hawkins, R. J. (1994). Displaced Proximal Humeral Fractures: Evaluation and Treatment. *Journal of the American Academy of Orthopaedic Surgery, 2*(1), 54-66.

35. Seddon, H. J. (1943). Three Types of Nerve Injury. *Brain, 66*(4), 237-288.

36. Songcharoen, P. (2008). Management of Brachial Plexus Injury in Adults. *Scandinavian Journal of Surgery, 97*(4), 317-323.

37. Smania, N., Berto, G., La Marchina, E., Melotti, C., Midiri, A., Roncari, L., Zenorini, A., Ianes, P., Picelli, A., Waldner, A., Faccioli, S., & Gandolfi, M. (2012). Rehabilitation of Brachial Plexus Injuries in Adults and Children. *European Journal of Physical and Rehabilitation Medicine, 48*(3), 483-506.

38. Sunderland, S. (1978). *Nerves and nerve injuries* (2nd ed.). Baltimore: Williams and Wilkins.

39. Taylor, C. A., Braza, D., Rice, J. B., & Dillingham, T. (2008). The Incidence of Peripheral Nerve Injury in Extremity Trauma. *American Journal of Physical Medicine & Rehabilitation, 87*(5), 381-385.

40. Terry, G. C., & Chopp, T. M. (2000). Functional Anatomy of the Shoulder. *Journal of Athletic Training, 35*(3), 248-255.

41. Terzis, J. K., & Kostopoulos, V. K. (2007) The Surgical Treatment of Brachial Plexus Injuries in Adults. *American Society of Plastic Surgeons, 119*(4), 73-92.

42. Terzis, J. K., & Papakonstantinou, K. C. (2000). The Surgical Treatment of Brachial Plexus Injuries in Adults. *Plastic Reconstruction Surgery, 106*(5), 1097-1122.

43. Tubbs, R. S., Rizk, E., Shoja, M. M., Loukas, M., Barbaro, N., & Spinner, R. J. (2015). *Nerves and Nerve Injuries, Volume 1: History, Embryology, Anatomy, Imaging, and Diagnosis.* United States: Elsevier Ltd.

44. Tubbs, R. S., Rizk, E., Shoja, M. M., Loukas, M., Barbaro, N., & Spinner, R. J. (2015). *Nerves and Nerve Injuries, Volume 2: Pain, Treatment, Injury, Disease, and Future Directions.* United States: Elsevier Ltd.

45. Travell, J. G., & Simons, D. G. (1999). *Myofascial Pain and Dysfunction: The Trigger Point Manual. Volume 1. Upper Half of Body* (2. Ed.). United States: Williams & Wilkins.

46. Wang, E., Inaba, K., Byerly, S., Escamilla, D., Cho, J., Carey, J., Stevanovic, M., Ghiassi, A., & Demetriades, D. (2016). Optimal timing for repair of peripheral nerve injuries. *Journal of Trauma and Acute Care Surgery, 83*(5), 875-881.

47. Watkinson, J. C., & Gleeson, M. (2016). Neck. In: S. Standring (Ed.), *Gray's Anatomy: The Anatomical Basis of Clinical Practice* (pp.442-474). United States: Elsevier Ltd.

6 Supplements

6.1 Application for approval by UK FTVS Ethics Committee

CHARLES UNIVERSITY
FACULTY OF PHYSICAL EDUCATION AND SPORT
José Martího 31, 162 52 Prague 6-Veleslavín

Application for Approval by UK FTVS Ethics Committee

of a research project, thesis, dissertation or seminar work involving human subjects

The title of a project: Case study of physiotherapeutic treatment of a patient in rehabilitation after surgeries of open humeral fracture, denervation of the brachial plexus and infection.

Period of realization of the project: January 2018 - May 2018

Applicant: Øyvind Humlen, student, UK FTVS, Department of Physiotherapy

Main researcher: Øyvind Humlen, student, UK FTVS, Department of Physiotherapy

Workplace: Oblastní Nemocnice Kladno

Supervisor: PhDr. Tereza Nováková, Ph.D.

Project description: The project takes place in a rehabilitation setting at Oblastní Nemocnice Kladno. The aim of the project is to ensure optimal rehabilitation and healing process for a single subject after surgery. The project utilizes the experimental method with data collections including mainly non-invasive assessment, clinical examination, observation, manual and electrical therapy and final assessment.

Characteristics of participants in the research: The number of participants in the research is one (1). The subject is 18 years of age, male, and currently inpatient at the hospital due to indications of rehabilitation.

Ensuring safety within the research: Minimal risk will be involved during the course of the research. Risks of therapy and methods will not be higher than the commonly anticipated risks for this type of therapy. The treatment will take place in an open and safe environment with the presence of supervision PhDr. Tereza Nováková, Ph.D. Other personnel will additionally also be in immediate proximity in case of necessity. The therapeutic methods of choice will be strictly according to the teachings of the Faculty, which impose as minimal risk to the patient as possible. Pain levels of the subject and recommended loading parameters must also be respected.

Ethical aspects of the research: Processing and retaining the data in an anonymised form will ensure personal data protection. The data will be used only in the bachelor thesis, and will not be published anywhere else After the anonymization the personal data will be deleted. Photographs of the participant will be anonymised by blurring the face, parts of the body, or characteristics that could lead to identification of the person. Any non-anonymised photographs will be deleted after the end of the research.

I shall ensure to the maximum extent possible that the research data will not be misused.

Informed Consent: attached

It is the duty of **all participants of the research team** to protect life, health, dignity, integrity, the right to self-determination, privacy and protection of the personal data of all research subjects, and to undertake all possible precautions. Responsibility for the protection of all research subjects lies on the researcher(s) and not on the research subjects themselves, even if they gave their consent to participation in the research. All participants of the research team must take into consideration ethical, legal and regulative norms and standards of research involving human subjects applicable not only in the Czech Republic but also internationally.
I confirm that this project description corresponds to the plan of the project and, in case of any change, especially of the methods used in the project, I will inform the UK FTVS Ethics Committee, which may require a re-submission of the application form.

In Prague, 25/01/2018 Applicant's signature: Øyvind Humlen

Approval of UK FTVS Ethics Committee

The Committee: Chair: doc. PhDr. Irena Parry Martínková, Ph.D.
Members: prof. PhDr. Pavel Slepička, DrSc.
doc. MUDr. Jan Heller, CSc.
PhDr. Pavel Hráský, Ph.D.
Mgr. Eva Prokešová, Ph.D.
MUDr. Simona Majorová

The research project was approved by UK FTVS Ethics Committee under the registration number: 045/2018
Date of approval: 30.1.2018

UK FTVS Ethics Committee reviewed the submitted research project and **found no contradictions** with valid principles, regulations and international guidelines for carrying out research involving human subjects.

The applicant has met the necessary requirements for receiving approval of UK FTVS Ethics Committee.

UNIVERZITA KARLOVA
Fakulta tělesné výchovy a sportu
José Martího 31, 162 52 Praha 6
Stamp of UK FTVS
– 20 –

Signature of the Chair of
UK FTVS Ethics Committee

6.2 Informed consent

UNIVERZITA KARLOVA
FAKULTA TĚLESNÉ VÝCHOVY A SPORTU
José Martího 31, 162 52 Praha 6-Veleslavín

INFORMOVANÝ SOUHLAS

Vážená paní, vážený pane,

v souladu se Všeobecnou deklarací lidských práv, zákonem č. 101/2000 Sb., o ochraně osobních údajů a o změně některých zákonů, ve znění pozdějších předpisů, Helsinskou deklarací, přijatou 18. Světovým zdravotnickým shromážděním v roce 1964 ve znění pozdějších změn (Fortaleza, Brazílie, 2013) a dalšími obecně závaznými právními předpisy Vás žádám o souhlas s prezentováním a uveřejněním výsledků vyšetření a průběhu terapie prováděné v rámci praxe na …….……., kde Vás příslušně kvalifikovaná osoba seznámila s Vaším vyšetřením a následnou terapií. Výsledky Vašeho vyšetření a průběh Vaší terapie bude publikován v rámci bakalářské práce na UK FTVS, s názvem ……

Získané údaje, fotodokumentace, průběh a výsledky terapie budou uveřejněny v bakalářské práci v anonymizované podobě. Osobní data nebudou uvedena a budou uchována v anonymní podobě. V maximální možné míře zabezpečím, aby získaná data nebyla zneužita.

Jméno a příjmení řešitele ..... Podpis:.....

Jméno a příjmení osoby, která provedla poučení..... Podpis:.....

Prohlašuji a svým níže uvedeným vlastnoručním podpisem potvrzuji, že dobrovolně souhlasím s prezentováním a uveřejněním výsledků vyšetření a průběhu terapie ve výše uvedené bakalářské práci, a že mi osoba, která provedla poučení, osobně vše podrobně vysvětlila, a že jsem měl(a) možnost si řádně a v dostatečném čase zvážit všechny relevantní informace, zeptat se na vše podstatné a že jsem dostal(a) jasné a srozumitelné odpovědi na své dotazy. Byl(a) jsem poučen(a) o právu odmítnout prezentování a uveřejnění výsledků vyšetření a průběhu terapie v bakalářské práci nebo svůj souhlas kdykoli odvolat bez represí, a to písemně zasláním Etické komisi UK FTVS, která bude následně informovat řešitele.

Místo, datum .....

Jméno a příjmení pacienta ..... Podpis pacienta: .....

Jméno a příjmení zákonného zástupce .....….

Vztah zákonného zástupce k pacientovi ..... Podpis: .....

6.3 Abbreviations

C

C1 – Cervical 1

C2 – Cervical 2

C3 – Cervical 3

C4 – Cervical 4

C5 – Cervical 5

C6 – Cervical 6

C7 – Cervical 7

C8 – Cervical 8

D

DNS – Dynamic Neuromuscular Stabilization

F

Fig. – Figure

P

Pic. – Picture

PNF – Proprioceptive Neuromuscular Facilitation

S

SFTR – Sagittal frontal transverse rotational

T

Tab. – Table

Th1 – Thoracic 1

Th1 – Thoracic 2

U

UK FTVS – Fakulta telesne vychovy a sportu Univerzity Karlovy

6.4 List of tables

6.5 List of figures

6.6 List of pictures

Picture 9 – final postural left view

Picture 10 – final postural right view