CHARLES UNIVERSITY IN PRAGUE

FACULTY OF PHYSICAL EDUCATION AND SPORTS

Department of physiotherapy

A Case study of physiotherapy treatment of a patient with low back pain

Bachelor's thesis

Supervisor: PhDr. Lenka Satrapová, Ph.D.

Author: Alsheikh mosab saleh

Prague, 2016

ABSTRACT

Title: A Case Study of Physiotherapy Treatment of Patient with Lower Back Pain

Aims: This thesis presents a case study of a physiotherapy approach to the treatment of lower back pain localised in the area of the lumbosacral junction, with pain sometimes radiating to the left hip. The theoretical section of this thesis explains the anatomy, kinesiology and biomechanical pathologies of the lumbar spine, while the practical section presents the case study, and discusses the examinations and treatment approaches used and the effectiveness of the therapy.

Methods: The practical section is based on the case of a 70-year old male, who complained of back pain. The study consisted of physiotherapeutic approaches for an initial kinesiological examination, followed by four therapy sessions lasting an hour each, and a final kinesiological examination. All methods used were non-invasive.

Results: Progress was remarkable during the four session of therapy. The patient's pain level in the lumbosacral junction and the left hip decreased to approximately 0/10 on a visual analogue scale.The therapies employed were very successful.

Conclusions: The patient felt an improvement after four sessions, and that his goals, which were to the pain he felt at rest and during sleep, had been achieved. The patient was very motivated, and therefore has a good prognosis.

Keywords: lumbosacral pain, hip joint pain, muscular imbalance, case study, physiotherapy.

DECLARATION

I hereby declare that this work is entirely my own individual work based on knowledge gained from books, journals, reports and by attending lectures and seminars at FTVS.

I also declare that no invasive methods were used during the practical approach and that the patient was fully aware of the procedures at any given time.

Prague, April 2016

ACKNOWLEDGEMENTS

First and foremost, I would like to thank my Dad, Alsheikh Saleh, and my family for their confidence, ongoing motivation and support in the course of my studies and general living. I could not have done this without you. I would also like to express my gratitude to my friends Monyr Abo Eldahab, Fadi Hobou and Hikmat Salarzy, for their support and belief in me.

Special thanks to the professors that I have encountered at FTVS over the past three years for sharing their knowledge and practice.

I would like to thank PhDr. Lenka Satrapová, PhD, who has guided me through every step of the entire process of this thesis, I appreciate everything you have taught me.

I would like to thank my supervisor during my thesis practice, Bc. Peter Horvath, for sharing his knowledge and allowing me to realise my full potential during my Bachelor's practice.

To conclude, thank you again to all, listed or not listed here, for the help and support, which has allowed me to finish my Bc. work.

Thank you all.

Alsheikh Mosab Saleh

Prague, April 201

TABLE OF CONTENTS

1 Introduction to the lumbar spine and pelvic girdle

The lumbar spine arranges the fibro-osseous pathway for the inferior portion of the spinal cord, the cauda equina, and the lumbosacral spinal nerves proceeding to and from the trunk and lower extremities. As a result of the magnitude and complexity of these functional demands, the lower back is a common site of dysfunction. The high rate of lower back dysfunction and the uncertainty of its clinical manifestations create a challenge for diagnosing the cause of lower back pain (LBP). The function of the lumbar spine is the result of a complicated interplay between the musculoskeletal and neurovascular structures that create a mobile, yet stable, transition between the thorax and pelvis. The lumbar region repetitively encounters enormous loads throughout the lifetime, while still providing the mobility necessary to allow the individual to perform the myriad tasks of their activities of daily life (ADL) (Oatis, 2003).

The pelvic girdle is formed by a single bone, the hip, or coxal bone, which serves as the attachment point for each lower limb. Each hip bone, in turn, is firmly joined to the axial skeleton via its attachment to the sacrum of the vertebral column. The right and left hip bones also converge anteriorly to attach to each other. The bony pelvis is the entire structure formed by the two hip bones and the sacrum, and is attached inferiorly to the sacrum.

Unlike the bones of the pectoral girdle, which are highly mobile to enhance the range of upper limb movements, the bones of the pelvis are strongly united to each other to form a largely immobile weight-bearing structure. This is important for stability because it enables the weight of the body to be easily transferred laterally from the vertebral column, through the pelvic girdle and hip joints, and into either lower limb whenever the other limb is not bearing weight. Thus, the immobility of the pelvis provides a strong foundation for the upper body as it rests on top of the mobile lower limbs (openstax, n.d.).

2 Theoretical part

2.1 The anatomy of the lumbar spine and pelvic girdle

The lumbar vertebral column consists of five separate vertebrae, which are named according to their location in the intact column. From above downwards they are named as the first, second, third, fourth and fifth lumbar vertebrae (L1–L5). The vertebral bodies become progressively larger from L1 to L5 (Bogduk, 2005).

2.1.1 The lumbosacral vertebrae

The lumbar vertebrae are irregular bones consisting of various named parts (Figure 1). The anterior part of each vertebra is a large block of bone called the vertebral body. The vertebral body is more or less box-shaped, with essentially flat top and bottom surfaces, and slightly concave anterior and lateral surfaces. Viewed from above or below the vertebral body has a curved perimeter that is more or less kidney-shaped. The posterior surface of the body is essentially flat, but is obscured from thorough inspection by the posterior elements of the vertebra. The greater part of the top and bottom surfaces of each vertebral body is smooth and perforated by tiny holes. However, the perimeter of each surface is marked by a narrow rim of smoother, less perforated bone, which is slightly raised from the surface. This rim represents the fused ring apophysis, which is a secondary ossification centre of the vertebral body. The posterior surface of the vertebral body is marked by one or more large holes known as the nutrient foramina. These foramina transmit the nutrient arteries of the vertebral body and the basivertebral veins. The anterolateral surfaces of the vertebral bodies are marked by similar, but smaller, foramina which transmit additional intraosseous arteries.

Projecting from the back of the vertebral body are two stout pillars of bone. Each of these is called a pedicle. The pedicles attach to the upper part of the back of the vertebral body; this is one feature that allows the superior and inferior aspects of the vertebral body to be identified. To orientate a vertebra correctly from each pedicle towards the midline is a sheet of bone called the lamina. The two laminae meet and fuse with one another in the midline.

Each lamina has slightly irregular and perhaps sharp superior edges, but its lateral edge is rounded and smooth. There is no superior lateral comer of the lamina because in this direction the lamina blends with the pedicle on that side. The inferolateral corner and inferior border of each lamina are extended and enlarged into a specialised mass of bone

called the inferior articular process. A similar mass of bone extends upwards from the junction of the lamina with the pedicle, to form the superior articular process (Bogduk, 2005).

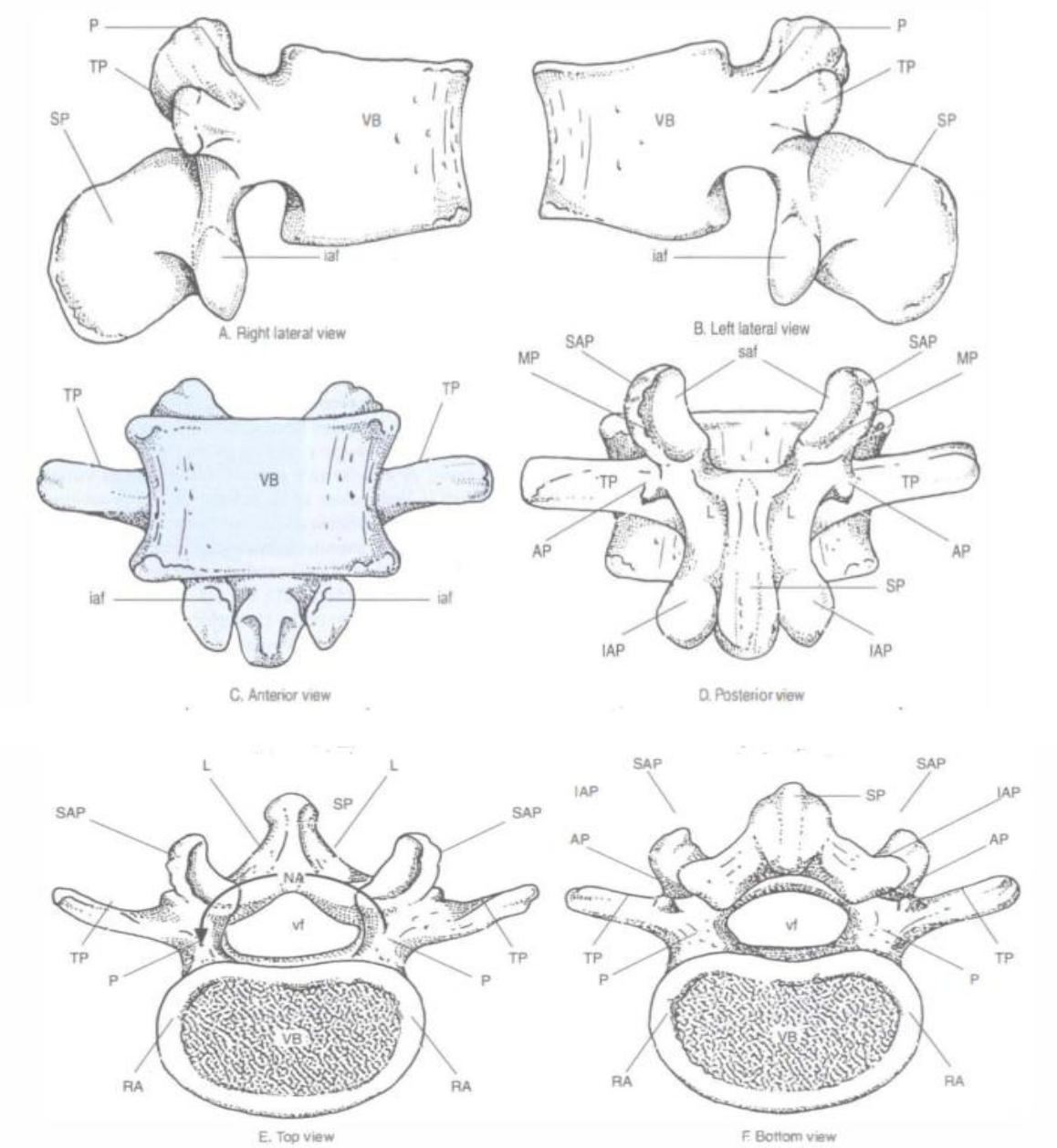

Figure 1: The parts of a typical lumbar vertebra (Bogduk,2005)

AP, accessory process; IAF, inferior articular facet; IAP, inferior articular process; L, lamina; MP, mamillary process; NA, neural arch; P, pedicle; RA, ring apophysis; SAF, superior articular facet; SAP, superior articular process; SP, spinous process; TP, transverse process; VB, vertebral body; VF, vertebral foramen.

2.1.2 The sacrum

The sacrum consists of the five fused sacral vertebrae and the intervertebral discs (IVD) that lie between them. It is wedge-shaped and presents markedly concave anterior and convex posterior surfaces. The base of the sacrum has a surface which faces the last lumbar vertebra, L5 (Figure 2).

The anterior surface bears four transverse lines (demarcating the boundaries between the fused bodies), which terminate on each side in the four anterior sacral foramina, lateral to which is the fused lateral mass. The foramina lie in an almost parallel vertical row so that the wedge shape of the sacrum is due to the rapidly diminishing size of the lateral mass from above down. The anterior primary rami of the upper four sacral spinal nerves, as they emerge from the anterior foramina, produce distinct neural grooves on the lateral mass.

The posterior surface of the sacrum is made up of the fused vertebral arches that form the roof of the sacral canal. It presents a median crest of fused spines, each represented by a small spinous tubercle. On either side of this crest are the fused laminae, which bear laterally an articular crest of fused articular processes, again each represented by a small tubercle; the articular crests terminate below in the sacral cornua. The last laminar arch (or more) is missing, leaving the sacral hiatus. Lateral to the articular tubercles are the four posterior sacral foramina, which lie directly opposite their corresponding anterior foramina, and which are closed laterally by the posterior aspect of the lateral mass, bearing a line of transverse tubercles. The lateral mass bears on its upper outer aspect a large auricular surface, which articulates with the corresponding articular surface of the ilium, behind which is large roughened area for attachment of the strong sacroiliac (SI) ligament.

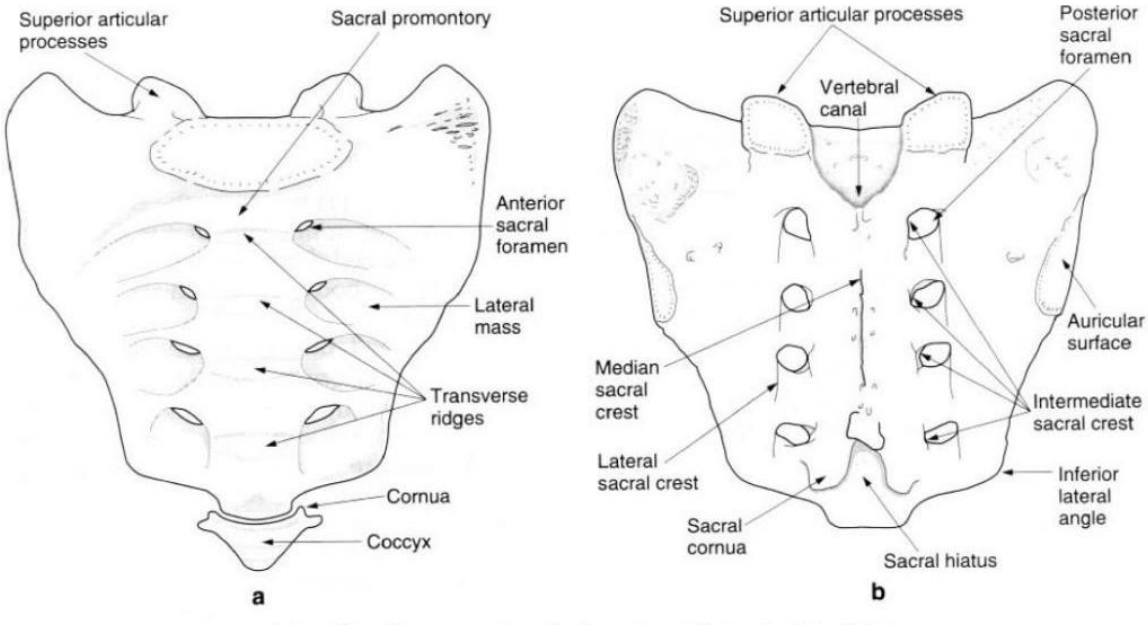

Figure 2: The sacrum (Објавио Vladimir Complete Conditioning, 2013)

A, anterior view; B, posterior view

The upper surface (or base) of the sacrum shows the features of a rather modified vertebra: the body is oval in section, its anterior edge forming the sacral promontory. The sacral canal is triangular in section, produced by very short pedicles and long lamina. The superior articular facet faces backward and inwards to receive the inferior facet of L5. The upper surface of the lateral mass is termed the ala and is grooved by the lumbosacral cord of the sciatic plexus.

The sacral hiatus, the triangle-shaped oblique hiatus on the posterior aspect of the apex of the sacrum, is of considerable practical importance; it is here that the extradural space terminates and the hiatus forms a convenient portal of entry into this compartment. The sacral hiatus results from failure of fusion of the lamina of the fifth sacral segment; or it may be more extensive than this, as will be described later under vertebral anomalies. It is bound above by the fused lamina of the fourth sacral segment (or of a still higher segment if the hiatus is more extensive), on which is situated the corresponding spinous tubercle. Laterally are the margins of the deficient lamina of L5, which below bear the sacral cornua; anteriorly lies the posterior surface of the body of the fifth sacral segment. The sacral hiatus usually lies two inches above the tip of the coccyx and directly beneath the uppermost limit of the natal cleft. It is better to locate it by direct palpation

of the depression that it forms between the sacral cornua. The hiatus is roofed over by the sacrococcygeal ligament (about 1–3mm thick), subcutaneous fat and skin; its ease of location varies inversely with the depth of the fat (Ellis & McLarty, 1962).

2.1.3 The coccyx

The coccyx consists of four fused rudimentary vertebrae. The surface that faces the sacrum has cornua, or horns (Figure 3), formed from the completely fused articular processes of the first coccygeal vertebra.

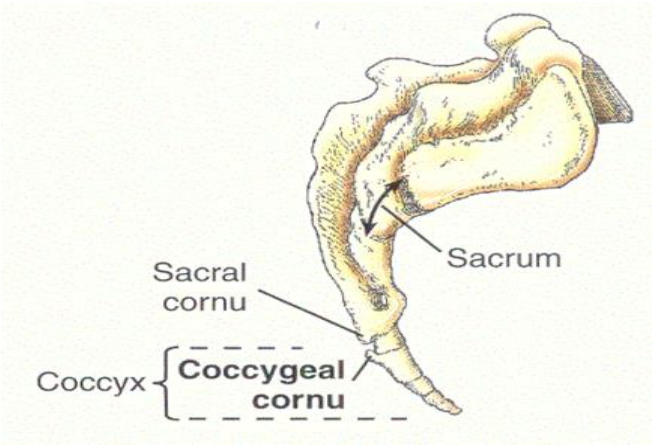

Figure 3: Lateral view of the coccyx and sacrum (Radiology Key, 2016)

2.1.4 The innominate bone

The bones of the pelvic girdle consist of two innominate bones, also known as the hip bones. Each bone is formed from the union of three different bones: the ilium, ischium and pubic bones. The three parts unite at the central point, the acetabulum, from which each of the three expand: the ilium superiorly, the ischium posteroinferiorly, and the pubic anteroinferiorly. They are connected by hyaline cartilage until 20–25 years of age, then they became one bone. The largest bone is the ilium and the smallest is the pubic bone. The muscles that originate from the ilium, ischium and pubis are described below. Table 1 shows all the muscles originating from the innominate bones with their functions (Oatis, 2003).

Table 1: Summary of the muscles that originate from the innominate bone along with their function

Muscles	Function of the hip
Gluteus maximus	E and lateral rotation
Gluteus medius	ABD and medial rotation
Gluteus minimus	ABD and medial rotation
Iliposas	Flexion
Rectus femoris	Flexion
Sartorius	F, ABD and lateral rotation
Tensor fascia latae	F, ABD and medial rotation
Pectinus	F, ADD and lateral rotation
Gracilis	ADD
Adductor magnus	ADD and lateral rotation
Adductor longus	ADD, lateral rotation and assists with F
Adductor brevis	ADD and lateral rotation
Biceps femoris (long head)	E of thigh
Semitendinosus	E
Semimembranosus	E
Gamellus inferior	External rotation of the thigh
Gamellus superior	
Piriformis	
Obtrautor externus	
Obtruator internus	
Quadratus femoris	

Sourced from Platzer (1984).

2.1.5 The lumbar plexus

The lumbar plexus is a network of nerve fibres that supplies the skin and musculature of the lower limb (Figure 4). It is located in the lumbar region, within the substance of the psoas major muscle, and anterior to the transverse processes of the lumbar vertebrae. The plexus is formed by the anterior rami (divisions) of the lumbar spinal nerves L1, L2, L3 and L4. It also receives contributions from the 12th thoracic spinal nerve (Gray, 1918)

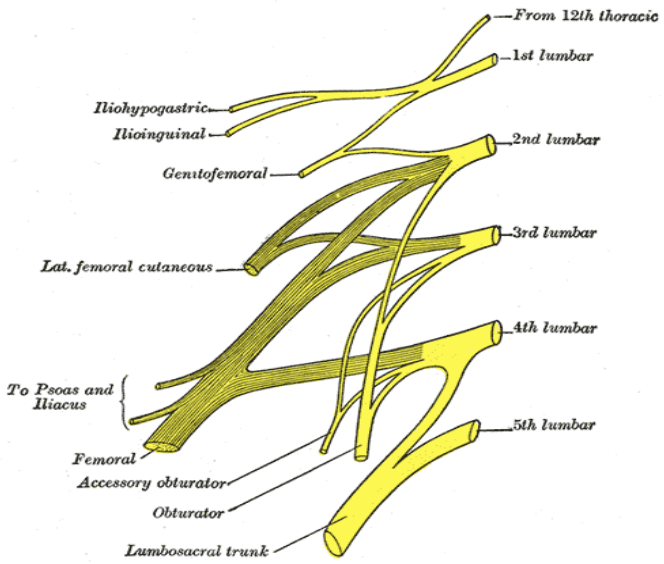

Figure 4: The lumbar plexus (Gray, 1918)

Table 2: Summary of the lumbar plexus nerves and roots

Nerve	Root
Iliohypogastric	L1 (with contributions from T12)
Ilioinguinal	L1
Genitofemoral	L1, L2
Lateral femoral cutaneous of the thigh	L2, L3
Femoral	L2, L3, L4
Obturator	L2, L3, L4
Accessory obturator	L3, L4

Sourced from Gray (1918).

2.1.6 The sacral plexus

The sacral plexus (Figure 5) is a network of nerve fibres that supplies the skin and muscles of the pelvis and lower limb. It is located on the surface of the posterior pelvic wall, anterior to the piriformis muscle.

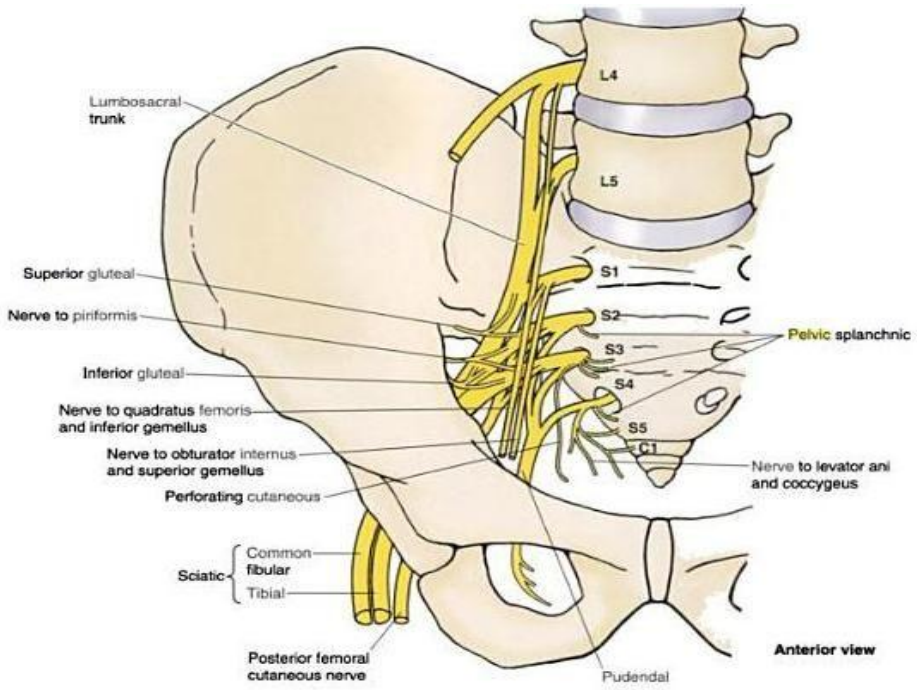

Figure 5: The sacral plexus (Park, n.d.)

The sacral plexus is formed by lumbosacral trunk and anterior rami (divisions) of the sacral spinal nerves S1, S2, S3 and S4 (Figure 5). It also receives contributions from the lumbar spinal nerves L4 and L5. The lumbosacral trunk comprises the whole of the anterior division of the fifth, and a part of that of the fourth, lumbar nerves, it appears at the medial margin of the psoas major and runs downward over the pelvic brim to join the first sacral nerve.

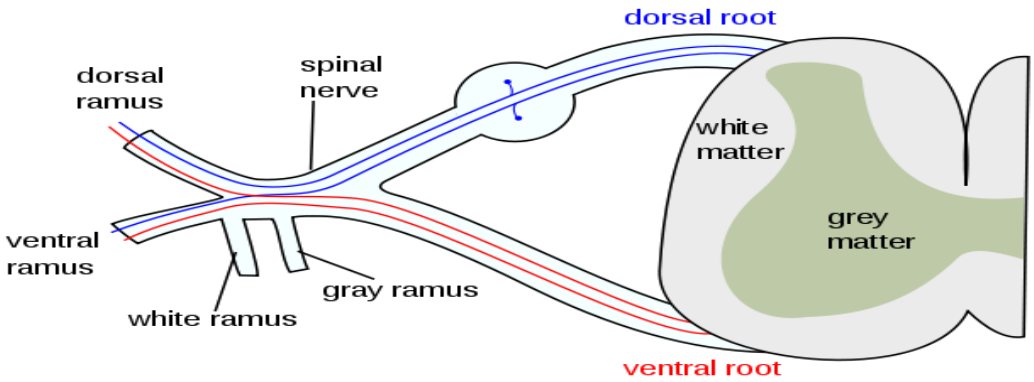

Figure 6: The anterior rami of vertebral levels S1–S4 make up the roots of sacral plexus (sourced from Boundless, n.d.)

The anterior division of the third sacral nerve divides into an upper and a lower branch, the former entering the sacral and the latter the pudendal plexus. The nerves forming the sacral plexus converge towards the lower part of the greater sciatic foramen, and unite to form a flattened band, from the anterior and posterior surfaces of which several branches arise. The band itself is continued as the sciatic nerve. This splits on the back of the thigh into the tibial and common peroneal nerves. These two nerves sometimes arise separately from the plexus (Gray, 1918).

2.2 Kinesiology of the lumbar spine

The lumbar vertebrae increase in size from cranial to caudal, reflecting their role in transmitting the superincumbent body weight to the pelvis for transmission to the lower limbs. Typically, they are wider from side to side than from front to back, are taller anteriorly than posteriorly, and have long, thin transverse processes and short, almost horizontal spinous processes. With the exception of L5, the facets (zygapophyses) of the superior articular processes of the lumbar vertebrae are vertical and directed medially and slightly posteriorly, while those of their inferior articular processes are vertical and directed laterally and slightly anteriorly; the facet (zygapophyseal) joint cavities are oriented predominately in the sagittal plane and facilitate flexion and extension. The wedge-shaped (taller anteriorly) vertebral bodies are responsible for the lordosis (dorsal concavity) formed by the upper lumbar spine, but the lordotic curvature in the lower part is attributed to both the vertebrae and IVDs, both of which are taller anteriorly (Oatis, 2003).

2.2.1 Motion of the lumbar spine

We consider the lumbar spine as a whole unit based on cardinal planes. The physiological motions the lumbar spine is able to undertake in certain planes are flexion and extension in the sagittal plane, lateral flexion in the frontal plane and rotation in the transverse plane. The lumbar spine is attached to structures that allow these motion: the muscles and ligaments. The function of the muscles from the anterior, posterior and lateral aspect will be described below, followed by the ligaments and the motion that they restrict.

Muscles of the anterior aspect

The anterior aspect muscles are the flexors of the trunk. Many classic anatomy texts consider the whole abdominal wall to be an important flexor of the trunk, but the rectus femoris is the major flexor of the trunk and the most active muscle during sit-ups and curl-ups. The function of the rectus femoris is to flex the trunk and depress the ribs. The external oblique functions to flex the trunk, support contralateral trunk rotation, increase the intrabdominal pressure, depress the ribs and support the spinal stabilisation. The internal oblique functions to flex the trunk, to depress the ribs, increase the intra-abdominal pressure, ipsilateral trunk rotation and stabilise the spine. The transversus abdominis functions to increase the intra-abdominal pressure (IAP) and stabilise the spine (Oatis, 2003).

Muscles of the posterior aspect

The erector spinae are powerful extensors of the vertebral column, and consist of the sacrospinalis, semispinalis, multifidus, rotators, interspinalis, intertransversarii, levator costarum, longissimus and iliocostalis. Acting concentrically and bilaterally they can extend the thoracic and lumbar spines, whereas acting unilaterally they can laterally flex the trunk.

Muscles of the lateral aspect

Pure flexion is not described as motion. It can be defined as a composition of side bending and rotational movement, and the muscles are involved in this movement are the quadratus lumborum, which bilaterally extends the trunk, the psoas major, which flexes the trunk and laterally flexes the lumbar spine (Oatis, 2003).

Ligaments of the lumbar spine

The ligaments of the lumbar spine confer mobility and stability on this spine. They are interlocked with the fascia, tendinous attachments of muscles and outer portion of the IVD and function to curb motion (Figure 7).

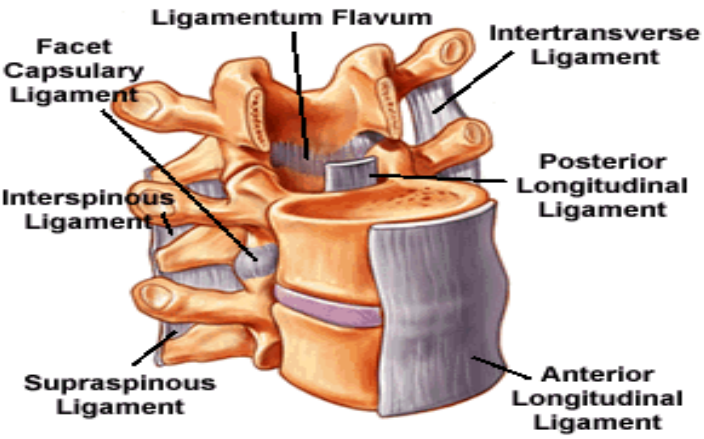

Figure 7: Ligaments found in the lumbar spine (Spine Institute, n.d.)

They are classified as extrasegmental [anterior longitudinal (ALL), posterior longitudinal (PLL) and supraspinous], segmental (ligamentum flavum, interspinous and intertransverse) or regional (iliolumbar). By recognising the location of the ligament and the direction of the fibres, we are able to hypothesise the motions that a given ligament resists. For example, ligaments posterior to the axis of rotation of a motion segment (the PLL, interspinous, ligamentum flavum and supraspinous ligament) restrain against flexion, while the anterior longitudinal ligament restrains extension.

Table 3: The description, function and the displacement resisted by the lumbar ligaments

Ligament	Description	Function	Displacement resisted
ALL	About one inch wide, the ALL runs the entire length of the spine from the base of the skull to the sacrum. It connects the front of the vertebral body to the front of the annulus fibrosis.	A primary spine stabiliser, provides intervertebral joint stability and prevents hyperextension	Vertical separation of anterior vertebral bodies.
PLL	About one inch wide, the PLL runs the entire length of the spine from the base of the skull to sacrum. It connects the back of the vertebral body to the back of the annulus fibrosis.	A primary spine stabiliser, the PLL helps with the prevention of posterior disc protrusion, as well as hyperflexion of the vertebral column.	Separation of posterior vertebral bodies.

Supraspinous	This ligament attaches the tip of each spinous process to the other.	Limits flexion of the vertebral column.	Separation of the spinous processes.
Interspinous	This thin ligament attaches to the ligamentum flavum, which runs deep into the spinal column.	Limits flexion.	Separation of posterior vertebral bodies; i.e., lumbar flexion, posterior translation of superior vertebral bodies.
Ligamentum flavum	Unique among the lumbar ligaments and characterised by its yellow colour, this ligament contains large amounts (~80%) of the elastin protein. It elongates passively by about 40% of its resting length without tissue failure. It runs from the base of the skull to the pelvis, in front of and between the lamina, and protects the spinal cord. The ligamentum flavum also runs in front of the facet joint capsules.	The strongest ligament, it acts to maintain the upright posture and to assist the vertebral column in resuming its place after flexion. The high content of elastin prevents buckling of the ligament into the spinal canal due to extension, which would cause canal compression.	Separation of the laminae.
Intertransverse	This thin ligament runs between the transverse processes of the vertebral column one segment at a time. It often blends with the intertransversarii muscles.	Limits lateral flexion.	Separation of transverse processes.
Iliolumbar	A series of bands that run from the transverse processes of L5 to the ilium, the anterior band travelling from the anterior-inferior–lateral part of the transverse process and widening to attach on the anterior part of the iliac tuberosity. Additionally, a posterior band arises from the apex of the transverse process and attaches the superior to the anterior processes.	Resists flexion, extension, rotation, and lateral bending.	Flexion, extension, rotation, and lateral bending.

Sourced from Bogduk (2005) and Oatis (2003).

The thoracolumbar fascia

The role of the thoracolumbar fascia (TLF) is to support the structure in the region that runs from the sacrum and iliac crest up to the thoracic cage. It is a dense band of connective tissue with a developed lattice of collagen fibres. The fascia imparts resistance and support during full flexion of the trunk. The elastic tension of the fascia assists the initiating motion of the trunk into the extension. The anatomy, function and clinical considerations of the TLF are described below.

The TLF consists of three layers attaching to many other core stabilising structures of the central zone (Nickelston, 2013):

- Anterior layer: Attaches to the anterior aspect of the lumbar transverse processes and the anterior surface of the quadratus lumborum.
- Middle layer: Attaches to the medial tip of the transverse processes, allowing the transverse abdominis to rise.
- Posterior layer: Covers all the muscles from the lumbosacral region through the thoracic region, towards the cervical splenii attachments. This posterior layer attaches to both the erector spinae and gluteus maximus aponeurosis (Vleeming, 1995).

The gluteus maximus and contralateral latissimus dorsi contribute to coordinating the contralateral pendulum-like motions of the upper and lower limbs that characterise running or swimming because of a shared attachment to the posterior layer of the TLF (Nickelston, 2013). Another important role of the internal fibres of the TLF that attach to the posterior fibres of the internal obliques and diaphragm is establishing core stabilisation via their contribution to IAP (Kolar, 2013).

2.2.2 Curvature of the spine

The spine is curved in the sagittal and frontal planes. In the sagittal plane, it is curved twice in an S-shape, convexity forward (cervical lordosis with an apex between C3–C4 and lumbar lordosis with an apex at L5), and convexity backward (thoracic kyphosis with the apex between T5 and T6). The degree of the lordosis is influenced by many factors, such as heredity, pathological conditions, the individual's mental state and forces applied to the spine during the ADL. The spinal curvature plays a significant role in postural function. From a functional perspective, symmetry is the most important

aspect, meaning that the maintenance of an erect posture demands minimal muscles activity (Oatis, 2003).

2.2.3 Spinal stability

There is a critical link between muscle activation and stiffness. Activating a muscle increases the stiffness of the muscle and the joint. Activating a group of muscle synergists and antagonists in the optimal way becomes critical issue. From a motor control point of view, the full complement of the stabilising musculature has to work together to obtain stability. If one muscle has inappropriate activation or force, stiffness will result in instability or unstable behaviour. Stiffness is defined as the ratio between the forces applied to an object and the object's resulting change in shape.

Many years ago it was claimed that the IAP plays a significant role in supporting the lumbar spine, especially during heavy lifting. It was though that the IAP reduces compressive loads in the spine, but it was found that abdominal muscle activity creates high IAP, increasing spine compression, and some suggest that spinal stability is the result of the IAP producing an external moment that assists the erector spinae to support the spine. Others suggest that the abdominal muscles, with other trunk muscles, distribute stiffness, causing an air splint to develop around the spine (Bogduk, 2012; Hirsch, 1955; McKenzie & May, 1981).

2.2.4 Load bearing

The motion of the lumbar spine occurs in three planes: sagittal, coronal and horizontal, and is the result of various forces acting on the lumbar spine and sacrum: compressive force, tensile force, shear force, bending moment and torsional moment. When load is applied externally to the vertebral column, it produce a stress on the stiff vertebral bodies and the relatively elastic discs, causing strains to be produced more easily in the discs. The pressure in the nucleus pulposus is greater than zero even at rest, producing a preload mechanism allowing for a greater resistance to the applied force.

Hydrostatic pressure increases within the IVDs, creating an outward pressure towards the vertebral endplates which results in bulging of the annulus fibrosis and tensile force within the concentric annular fibres. This force transmission has a slow effect on the pressure on the adjacent vertebral disc, as shock absorber. The IVDs acts as a fibrocartilage transmitting force between adjacent vertebrae during spinal movement (Smith, Russell & Hodges, 2006).

2.2.5 The diaphragm

The diaphragm is a dome-shaped muscle separating the thoracic and abdominal cavities. It has a convex upper surface that faces the thorax, and a concave inferior surface that is directed towards the abdomen. During inspiration the diaphragm contracts and moves down caudally like a piston into the abdominal cavity, which creates a negative pressure in the thoracic cavity that forces air into the lungs and simultaneously increases the IAP. The diaphragm is the primary breathing muscle, and yet many individuals have difficulty with activating it correctly. Dysfunctional breathing patterns are a common contributing factor for LBP conditions, and are actually often a stronger predictor for LBP than other established risk factors (Page, Frank & Lardner, 2010).

2.2.6 Lower crossed syndrome

Janda describes the lower crossed syndrome as tightness of the thoracolumbar extensors on the dorsal side crosses with tightness of the iliopsoas and rectus femoris. Weakness of the deep abdominal muscles ventrally crosses with weakness of the gluteus maximus and medius. This pattern of imbalance creates a joint dysfunction, especially at the L4–L5 and L5–S1 segments, the SI joint, and the hip joint. Specific postural changes seen in the lower crossed syndrome include anterior pelvic tilt, increased lumbar lordosis at the lumbar sacral junction; as a consequence, insufficient hip extension is

observed during gait, which leads to an even greater pelvic anteversion. This result in significant overexertion of the lumbosacral junction, and loading of the hip joint leads to subsequent adaptive changes. At the same time, the posterior edge of the IVDs is overloaded. With the lower crossed syndrome, the thoracolumbar junction becomes the stabilisation region during gait. This imbalance pattern is one of the main causes of LBP (Bogduk, 2005).

2.3 Biomechanics of the lumbar spine and structure of the intervertebral discs

The IVDs consist of three distinct components (Figure 8): the central nucleus pulposus, the peripheral annulus fibrosus and two vertebral endplates.

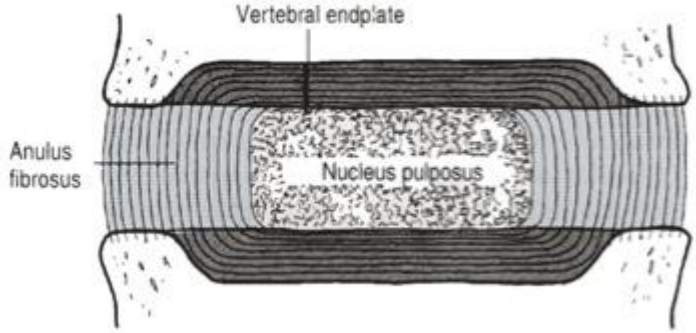

Figure 8: Structure of the IVD (Bogduk, 2005)

2.3.1 Nucleus pulposus

The nucleus pulposus is a gel-like mass composed of water and proteoglycans held together by randomly arranged fibres of collagen. With its water-attracting properties, any attempt to deform the nucleus causes the applied pressure to be dispersed in various directions, similar to a person on a waterbed (Jensen, 1980).

2.3.2 Annulus fibrosus

The annulus fibrosus consists of concentric layers of collagen fibres (lamellae). The fibre orientation of each layer of lamellae alternate so it allows effective resistance to multidirectional movements (Jensen, 1980).

2.3.3 Vertebral endplate

The vertebral endplate is a plate of cartilage that acts as a barrier between the disc and the vertebral body. The vertebral endplates cover the superior and inferior aspects of the annulus fibrosus and the nucleus pulposus (Jensen, 1980).

2.3.4 Innervation

The disc is innervated in the outer few millimetres of the annulus fibrosus (Jensen, 1980).

2.3.5 Biomechanics of the lumbar intervertebral discs

In the normal disc (Figure 9), a compressive load increases the internal pressure of the disc and stretches the annulus fibres. The resultant stresses are directed radially to the endplates and the annulus. The inner layers of the annulus are subjected to a small compressive stress, which is transferred to other vertebrae by the fluid pressures of the nucleus. The outer annulus layers are subjected to tensile stress without transference. Because of their alignment the outer layers of annulus fibres are capable of absorbing the tensile stress. The magnitude of tensile stresses depends on the thickness of the annulus fibres. Bending involves tension, compression, and some shear stresses at different locations in the disc. Bending in forward flexion, lateral flexion, or extension of the spine produces tensile stress on the convex side of the annulus and a compressive stress, caused by the body weight, on the concave side. The side of the annulus under tension stretches, while the side under compression bulges. Torsion stress in the spine comes from twisting on the long axis. The motion of one vertebra on another produces both tensile and shear stresses in the annulus. These shear stresses take place in the horizontal plane about the rotational axis. Because the annulus fibres cross at oblique angles to the horizontal plane, torsion produces tensile stresses in the fibres resisting rotation. Shear stresses exist perpendicular to the annulus fibre direction. Because the bond between parallel fibres is comparatively weak, these shear stresses may be the reason for failure in the annulus. Combinations of movements such as twisting, bending, and bending with rotation will result in increased stresses and strains on the disc,

particularly with a superimposed load. These stresses can lead to disc injury (Balabgue, Mannion, Pellisé & Cedraschi, 2012).

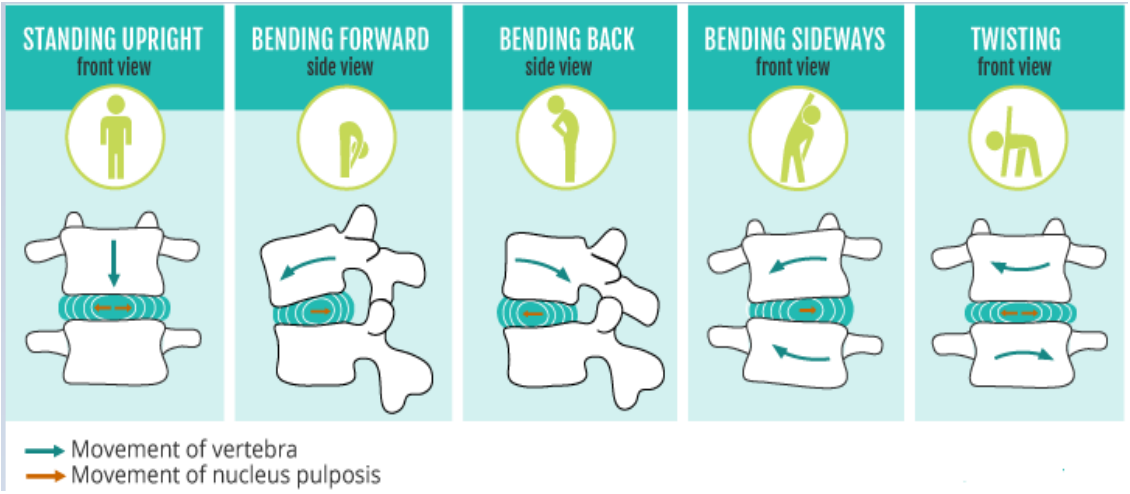

Figure 9: Movement of vertebrae and the nucleus pulposus in different planes (Olgakabel, 2015)

2.4 Disease

LBP is the fifth most common reason for people to visit a doctor, and affects approximately 60–80 per cent of people during their lifetime. The lifetime prevalence of LBP is reported to be as high as 84 per cent, and the prevalence of chronic LBP is about 23 per cent, with 11–12 per cent of the population being disabled by LBP (Burton et al., 2004).

2.4.1 Characterisation

The definition of LBP depends in the source. According to the European Guidelines for the Prevention of LBP, LBP is defined as pain and discomfort, localised under the costal margin and above the inferior gluteal folds, with or without pain in the leg (Burton et al., 2004). Another definition, that of Kinkade (2007), which resembles the European guidelines, is that LBP is pain that occurs posteriorly in the region between the lower rib margin and the proximal thighs. The most common form of LBP is ‘non-specific LBP’ and is defined as LBP not attributed to a recognisable, known specific pathology (Burton et al., 2004).

Causes

Different factors can lead to pain. Movements that involve lifting, twisting or bending forward can be the cause. More frequently, pain is the result of poor posture and excessive static strain. It can be caused by remaining in a static position for long periods of time or by faulty movement patterns. The pain can also develop gradually as a result of factors that apply excessive stress and strain to the locomotor system structures.

LBP is usually categorised into three sub-types: acute, sub-acute and chronic. This subdivision is based on the duration of the pain. Acute LBP is an episode of LBP for less than six weeks, sub-acute LBP occurs between six and 12 weeks and chronic LBP occurs for 12 weeks or more (Koes, Van Tulder & Thomas, 2006).

2.4.2 Clinical picture

LBP can be found various clinical states or mixture of states according to the severity of the cause. Patients with back pain can be classified according to the diagnosis (such as fractures, cancer, infection and ankylosing spondylitis) and the specific causes of back pain with neurological deficits (such as radiculopathy, caudal equina syndrome), but if the LBP is caused by biological factors (e.g., weakness, stiffness), psychological factors (e.g., depression, fear of movement and catastrophisation) or social factors (e.g., work environment) it is classified as non-specific LBP (Lewit, 2009).

2.4.3 Clinical signs

Non-specific LBP has a specific clinical presentation, but no precipitating event or factor can be found (Anderson, 2007). The common findings are:

- Postural asymmetry
- Weakness of the abdominal and gluteal musculature
- Overactivity of the hip flexors and erector spinae
- The patient is often hypermobile
- Insufficiency of the deep stabiliser system, which leads to compensatory development of large numbers of trigger points
- Radiation of pain, either to the buttocks or the leg, without signs of the nerve roots being affected

2.5 Common structural pathologies of the lumbar spine

LBP is the most common symptom when it comes to the structural pathologies of the lumbar spine. In this section, four common structural pathologies that can lead to symptoms of LBP will be described. There are many structural conditions related to LBP, but the four selected diagnoses are the most common seen in the healthcare community, especially by physiotherapists.

2.5.1 Scoliosis

Scoliosis is a sideward curving or lateral bending of the spine, resulting in one or two curves, making the spine take an S-shape (Figure 10). This can sometimes be found in three segments of the spine, and is known as a triple scoliosis.

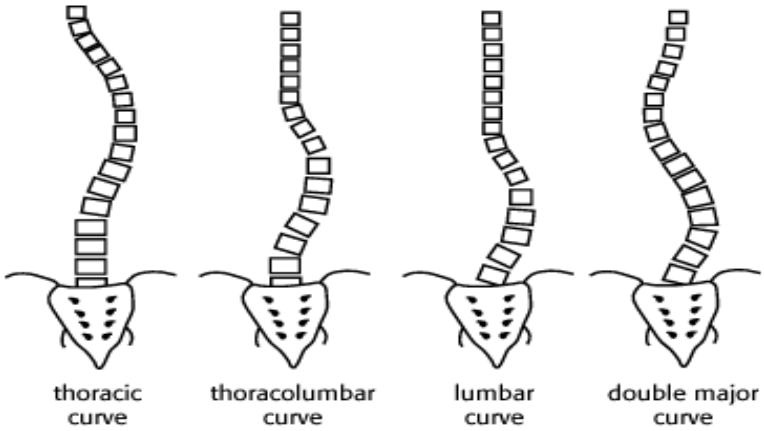

Figure 10: Patterns of scoliosis (sourced from University of Washington, 2016)

There are two types of scoliosis, according to their aetiology. Non-structural scoliosis means that the spine is structurally normal, but a lateral curve has developed as a secondary response to a problem occurring elsewhere in the body. Non-structural scoliosis also is known as compensatory or postural scoliosis and can occur due to differing leg lengths or a tilt to the pelvis, as well as flexion deformities at the hip or knee.

Structural scoliosis is the type of scoliosis where the spine not only has a lateral curve, but also has a rotational element to the vertebrae. Structural scoliosis directly involves the structural aspects of the spine and does not go away when the patient lies down or sits upright. The most common scoliosis, known as idiopathic scoliosis, is divided into

three classifications according to the child's age at the time of diagnosis. The classifications of idiopathic scoliosis are infantile (aged three years and younger), juvenile (discovered between ages three and ten), and adolescent idiopathic scoliosis (discovered between age ten and skeletal maturity). Idiopathic scoliosis affects 2 to 4 per cent of all adolescents. Adolescent idiopathic scoliosis is estimated to comprise 80 per cent of idiopathic scoliosis cases, and is detected most commonly in children between the ages of ten and 16 years, and most commonly affects girls (Gunzberg & Szpalski, 2006).

2.5.2 Spondylolysis and spondylolisthesis

These conditions are one of the common causes of structural LBP. Spondylolysis is a breakdown or fracture of the narrow bridge between the upper and lower facets, called the pars interarticularis. It can occur on one side (unilateral) or both sides (bilateral) and at any level of the spine, but most often at the fourth or fifth lumbar vertebra (Figure 11).

If spondylolysis is present, there is a potential to develop spondylolisthesis. Spondylolisthesis is the actual slipping forward of the vertebral body (Figure 10). It occurs when the pars interarticularis separates and allows the vertebral body to move forward out of position, causing pinched nerves and pain. Spondylolisthesis usually occurs between the fourth and fifth lumber vertebra or at the last lumbar vertebra and the sacrum. This is where the spine curves into its most pronounced S-shape and where the stress is heaviest (McGill, 2007).

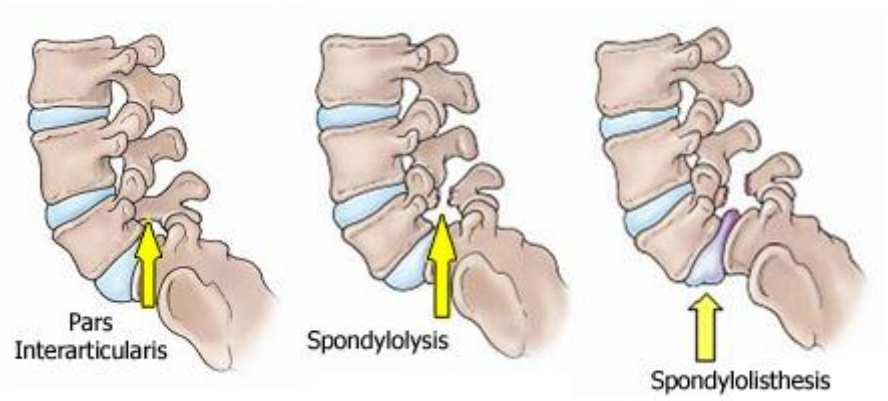

Figure 11: Fractures of the pars interticularis can lead to spondylolysis and spondylolisthesis (American Academy of Orthopaedic Surgeons, 2007)

2.5.3 Disc herniation

The herniation process begins from failure in the innermost annulus rings and progresses radially outward. Damage to the annulus of the disc appears to be associated with fully flexing the spine for a repeated or prolonged period of time. The nucleus loses its hydrostatic pressure and the annulus bulges outward during disc compression (Figure 12) (Shahbandar & Press, 2005).

The most common direction for a disc herniation to occur is in the posterolateral direction, where the annulus fibrosis is thin and not supported by the ALL or PLL. Approximately 95 per cent of lumbar disc herniations occur at L4–L5 and L5–S1, causing pain in the L5 or S1 nerve that radiates down the sciatic nerve, while L4–L5 usually causes L5 impingement in addition to sciatica pain. This type of herniated disc can lead to weakness when raising the toe and possibly in the ankle, also known as foot drop, and numbness and pain can be present on the top of the foot (Schroth & Borysov, 2006).

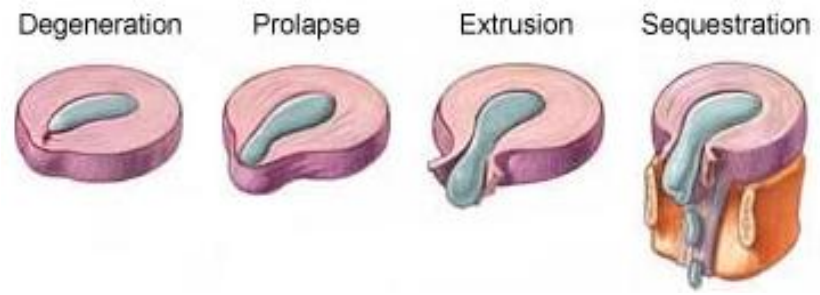

Figure 12: Lesions of the disc (Umaña, n.d.)

2.5.4 Intervertebral disc injuries

Injuries to the IVDs of the lumbosacral spine are invoked as a causative factor of LBP. Among the possible aetiologies of LBP, the IVD has been implicated as a more frequent source than muscular strain or ligamentous sprain. However, no single injury to the IVD has been unequivocally identified as a pain generator in the lower back (Manek & McGregor, 2005).

2.6 Rehabilitation of the structural pathologies of the lumbar spine

2.6.1 Scoliosis

Conservative treatment

The primary aim of scoliosis management is to stop curvature progression. Pulmonary function (vital capacity) and the treatment of pain are also of major importance. The first of three modes of conservative scoliosis management is based on physical therapy, including the Lyonaise, Schroth, Klapps crawling, vojta and other methods.

The second mode of conservative management method is scoliosis intensive rehabilitation, which appears to be effective with respect to many signs and symptoms of scoliosis and for impeding curvature progression. The third mode of conservative management is brace treatment, which has been found to be effective in preventing curvature progression. It appears that brace treatment may reduce the prevalence of surgery (Kolar, 2013).

Surgical treatment

Surgery may be used to treat severe scoliosis. The result will not be a perfectly straight spine, but the aim of the surgery is to decrease rib hump and pelvic rotation, ensure the stability of the spine and to make sure the curvature does not increase. Surgical intervention is not considered if the curvature progression is not greater than 40–50º (Steiner & Michelli, 1985; Turner & Bianco, 1971).

2.6.2 Spondylolysis and spondylolisthesis

Conservative treatment

Treatment of spondylolysis or spondylolisthesis begins with a trial of conservative care. In children and adolescents this includes rest from sporting activities that provoke back pain, non-steroidal anti-inflammatory agents (NSAIDs), and physical therapy. Therapeutic exercises are aimed at strengthening the abdominal and back muscles and increasing flexibility in the hamstrings and hip flexors. Acute lesions have a greater healing potential are treated with restriction from sporting activities and thoracolumbar orthosis. The use of orthotics helps to decrease lumbar lordosis, thereby reducing extensor stress on the acute pars lesion to allow for osseous healing. Bracing, such as the modified Boston brace, with 30° of abdominal concavity and 15° of lumbar flexion, is recommended for 23 h/day for six months, followed by gradual discontinuation with resumption of sporting activity so long as the patient is asymptomatic. In adults conservative treatment includes NSAIDs, physical therapies, such as heat or ice, chiropractic manipulation, and lifestyle modifications. Physical therapy is the most commonly prescribed initial treatment with an emphasis on flexion and extension, deep abdominal and back muscles, and core strengthening. Strengthening of the abdominal muscles helps to produce the IAP that maintains normal postural alignment, while exercises that focus on flexion and extension target deep back muscles, such as the multifidus, to improve dynamic spinal stability and mobility (Standaert & Herring, 2000).

2.6.3 Disc herniation

1.6.3.1 Conservative treatment

There are several conservative treatment option that relieve the symptoms of disc herniation. These include NSAIDs to decrease inflammation and pain, narcotics and cortisone injections. Physical therapy plays a major role in herniated disc recovery. Its

methods not only offer immediate pain relief, but they also teach the patient about their body condition to prevent further injury. The main goal of treatment is to improve trunk stability, lengthen shortened muscles (mainly the iliopsoas and hamstrings), strengthen weakened muscles (mainly the abdominals and gluteals) and improve any neurological deficits (Dawson, 2016).

Surgical treatment

Surgical management is typically reserved for those who have failed conservative measures, have progression of slippage or symptomatic segmental instability, or present with a neurologic deficit or deformity. A spinal fusion is performed between the lumbar vertebra and the sacrum. Sometimes an internal brace of screws and rods is used to hold together the vertebrae as the fusion heals (Dawson, 2016).

3 CASE study

3.1 Methodology

My Bachelor's practice took place at the Malvazinky Rehabilitation Clinic in Prague from 18–29 January 2016, guided and supervised by Bc. Peter Horvath. My thesis patient is a man who suffers from LBP. The patient was informed of my thesis practice so that we could cooperate, and so that he could consent to his personal information, anamnesis and present situation being used (see Informed Consent, Annex No. 2, which was approved by the Ethics Committee of the Charles University, shown in Supplement No. 1).

My case study was undertaken at the outpatient physiotherapy department. My supervisor specialises in diagnoses such as acute and chronic back pain, spinal disc herniation, conditions following spinal or orthopaedic surgery, functional disorders and muscular imbalances, and especially pelvic diaphragm problems. Each physiotherapist has their own office with a bench and equipment for exercise, such as fitness balls, balance wobbleboards etc. The department also offers various physical therapies, including ultrasound, magnetotherapy and shockwave therapy, among others.

My patient underwent a total of four therapy sessions between 18 and 29 January 2016. Initial and final examinations were included at the beginning of the first session and at the beginning of the last session, respectively. The instruments used were a measuring tape, plastic goniometer and a neurological hammer during both the initial and final examinations. Bc. Peter Horvath supervised my study, and all examinations and therapeutic approaches were done in cooperation with him. We performed the initial examination together and discussed and set plans for the rehabilitation sessions. Each session was noted and the final examination was compared with the initial examination to determine the results of the therapy.

3.1.1 Anamnesis

Name: ZB

Date of birth: 1947

Diagnosis: LBP

Present state:

- Height: 1.86 m
- Weight: 101 kg
- Body mass index: 29.2

The patient, a 70-year-old man, complained of sharp LBP localised in the region of the lumbosacral junction, with the pain sometimes radiating to the left hip. He began to experience LBP six years ago. In order to reduce the pain, he used to go for a classic massage once a week. This relaxed him for a short period, and he then consulted a neurologist who recommended exercises to strengthen his abdominal muscles.

3.1.2 History of the current problem

The patient reported experiencing LBP for a long time about ten years ago, but that it was not sharp. In 2010 he began to have sharp LBP, at about 6/10 on a visual analogue scale (VAS). The patient feels pain when walking, standing for long period of time and sometimes when sitting. Aggravating positions are extending the trunk backward from a flexed position, and infrequently when he coughs or sneezes. Relieving positions are lying supine with flexed knees and walking for a duration of 20 minutes.

The left hip pain began when he walked for a long distance, especially when he performs abduction (ABD); on a VAS it scored 4/10. Avoiding hip ABD relieves the pain. The patient's sleeping position is supine with pillows between his thighs.

Medical history: In 2013 he had a pulmonary embolism. He began to have pain in both legs and the back pain worsened.

Social history: He does not play any sport, but likes to walk for long distances. He also takes care of his garden, but complains of LBP while working in the garden and sometimes during his ADL.

Work history: The patient is a retired engineer, but worked in an office.

Pharmacological history: Warfarin 5 mg since 2013, Letrox 50 ug.

Abuses: The patient is a non-smoker and a social drinker.

Allergies: None.

3.1.3 Previous rehabilitation

In 2012 and 2014 at the U Malavzinky Clinic for his LBP.

3.1.4 Statement from the patient's medical documentation

MRI of the lumbosacral spine on 14/03/2014. Results: The skeleton in the investigation showed adequate structures and density with no lesions. Degenerative changes are found in the IVD of L4–L5 and L5–S1, along with dorsal osteophytes in the IVD L5–S1.

3.1.5 Rehabilitation

Eight sessions of physiotherapy, prescribed by the patient's neurologist to decrease pain and provided postural re-education.

3.1.6 Differential considerations

- Blockage of joints in any part of the spine
- Change of posture
- Mechanical problems (compression)
- Piriformis syndrome
- Cervical dysfunction causing the pain to radiate to the lumbar spine
- Changes in muscle tone
- Instability of the spine

3.2 Initial kinesiological examination

Performed on 18 January 2016.

Initial Scale test: 49 kg on the left side, 52 kg on the right side.

3.2.1 Postural examination, Kendall's method

Results of the postural examination according to Kendall (2005) the posterior, side and anterior views during the initial examination are presented in Table 4.

Table 4: Postural examination results

Posterior view	Side view (left and right)	Anterior view
Both scapula abducted Left shoulder higher than right shoulder Short base of foot Hyperextension of the left knee Slight valgosity of the left ankle	Flat lumbar Thoracic kyphosis Cervical kyphosis Shoulder protruded Head forward	Left shoulder higher than right Position of head in the midline with slight rotation in the right Hyperactivity of SCM visible Eversion in both feet Short base of foot Abdominal slackening

3.2.2 Gait examination, Kendall's method

- Short base, equal length of strides
- Takeoff at metatarsal ends of the foot
- No extension of the hip, compensated by excessive flexion of the knees
- Head protrusion
- Very slight arm movements
- No trunk or pelvic movements (stiff posture)

Modifications

Table 5: Initial examination and results of gait modification

Tiptoes (S1)	Able to execute normally
On heel (L5)	Able to execute with poor instability
Squat (L3/4)	Able to execute with pain in lumbosacral area
Backward (gluteals)	Able to execute with a small range of motion into extension
Sideways (adductors /abductors)	Able to execute normally

3.2.3 Pelvic examination

- Crest: Same level
- Posterior superior iliac spines (PSIS): Same level
- Anterior superior iliac spines (ASIS): Same level
- ASIS and PSIS (right side): PSIS slightly higher
- ASIS and PSIS (left side) PSIS slightly higher

Result: Patient has physiological anterior pelvic tilt

3.2.4 Dynamic spine test

Flexion

- Small range of motion (ROM)
- Slow when performing the movement
- Thoracic kyphosis and overload (more on the left paravertebral)
- Flat lumbar
- Anterior pelvic tilt during the movement

Extension

- Small ROM
- Thoracic overloading (entire movement)
- Flat lumbar
- Mild pain present in the lumbar part during the movement

Lateral flexion to the right

- Normal ROM
- Arms are in contact with the body
- Thoracic overloading—all the movement is carried out by the lower thoracic segments
- Rotational synkinesis of the pelvis is present

Lateral flexion to the left

- Decreased ROM by 10 cm compared to the left
- Arms are in contact with the body
- Thoracic overloading—all the movement is carried out by the lower thoracic segments

Rotation to the left and the right

- Movement substitution by trunk moving along the sagittal plane
- During assisted rotation, the rotation was 10° more to both sides and the patient reported pain of around 3/10 on the VAS in the lumbosacral area

3.2.5 Altered movement patterns, by Janda's method (Liebenson, 2007)

Extension

Right lower extremity extension: Anterior tilt of the pelvis followed by activation of the gluteals, hamstrings and contralateral paravertebrals simultaneously, along with movement of the trunk anticlockwise. The ROM was 5°. The patient was barely able to correct the movement synkinesis of the trunk by keeping it still on the bed, after being given appropriate instructions.

Left lower extremity extension: The same movement synkinesis, although not exaggerated. The ROM in extension was a few degrees more than the right. The patient was not able to correct the movement synkinesis after being given instructions.

Abduction

Right lower extremity: The pelvis moves forward, and the leg is externally rotated.

Left lower extremity: The pelvis moves forward, and the leg is flexed and externally rotated. The patient was incapable of correcting the movement synkinesis of both legs after being given instructions.

Result: Fixed overplay of the tensor fascia latae (TFL) on the right side, and the TFL and iliopsoas on the left side, with no proper spinal stability.

Curl-up

Anterior tilt of the pelvis, flexion of the knees and hip, very weak abdominals. The patient was incapable of correcting the movement synkinesis after being given instructions.

3.2.6 Anthropometry

Table 6: Anthropometry results of the lower extremity during the initial examination

Lower extremity	Left (cm)	Right (cm)
Anatomical length	107	107
Functional length	104	103

3.2.7 Soft tissue examination, Lewit's method

Kibler's fold: Not possible to perform on the lumbar and lower thoracic area.

Skin mobility and elasticity: Slight restriction in the lumbar area in all directions.

Fascia: Restriction of the TLF in the caudal direction.

3.2.8 Range of motion examination, Kendall's method

Table 7: Active and passive ROM of the left and right hips and knees during initial examination

		Left (degrees)		Right (degrees)	
		Active	Passive	Active	Passive
Hip	S	5-0-100	10-0-110	5-0-110	10-0-120
	F With knee extended	30-0-20 (Painful)	35-0-25 Soft restriction in ABD	35-0-35	40-0-40
	F With knee flexed	30-0-25	40-0-30	40-0-40	40-0-40
	R90	40-0-10	45-0-10	35-0-10	35-0-10
Knee	S	0-0-135	0-0-140	0-0-140	0-0-140

3.2.9 Neurological examination

Superficial reflex examination of the lower extremity: Light touch.

Results:

- Decreased sensitivity of the lateral aspect of the thigh, leg and foot of the right leg

Deep sensation examination: Movement sense and position sense examination of the big toe.

Results:

- Decreased proprioception of the left lower extremity
- Intact proprioception of the right lower extremity

Reflexes: Mono-reflexes of the patella (L2–L4), hamstring (L5–S1) and Achilles (S1):

Results:

- Normal

Provocative tests: Laseque's sign, reverse Laseque's sign and Bragard's sign.

Results:

- Signs were negative on both extremities

3.2.10 Muscle palpation, muscle shortness and muscle strength testing according to Kendall's method

Table 8: Muscle tone, muscle length and muscle strength of the left and right lower extremities during initial examination

Muscles tested	Left lower extremity			Right lower extremity		
	Muscle tone	Muscle shortness	Muscle strength	Muscle tone	Muscle shortness	Muscle strength
Quadrates lumborum	♦	√	4-			4-
Gluteus maximus	♦		3+	♦		3+
Gluteus medius and minimus	♦		3+	♦		3+
Coccygeus						

Adductor longus	♦	√	4-		√	4+
Adductor brevis			4-			4+
Adductor magnus			4-			4+
Gracilis			4			4+
Hip lateral rotators (gamellues superior and inferior obturator externus and internus piriformis and quadratus femoris)		√	3		√	3+
Piriformis	♦	√	4	♦	√	4+
Ilipsoas	♦	√	3+	♦	√	4-
Tensor facia latae		√	4		√	4+
Sartorius			4			4
Biceps femoris	♦		4	♦		4+
Semimembranosus	♦		4-			4
Semitendinosus	♦		4-			4
Rectus femoris	♦		4+			4+
Vastus medialis	♦		4	♦		4+
Vastus lateralis and intermedius			4			4
Gastrocnemius and plantaris	♦	√	4+		√	4+
Soleus		√	4+		√	4+
Peroneus longus and brevis			4			4
Tibialis posterior			4			4+
Tibialis anterior			4			4
Rectus abdominals			3+			3+
Transverse abdominals	♦		2-			2-
External and internal obliques			2-			2-

Key: Hypertonic muscles, ♦; Eutonic and normal length muscles, ; Hypotonic muscles, ■; Shortened muscles, √.

3.2.11 Joint play, Lewit's method

Table 9: Initial examination of joint play of selected joints of the left and right lower extremities

		Left lower extremity	Right lower extremity
Head of fibula	Dorsal direction	No blockages	Restricted but not painful
	Ventral direction	No blockages	No blockages
Talocrural joint in dorsal direction		No blockages	No blockages
Cuboid	Plantar direction	No blockages	Restricted and painful
	Ventral direction	No blockages	Restricted and painful
Navicular	Plantar direction	Restricted and painful	No blockages
	Ventral direction	Restricted and painful	No blockages
Lisfranc joint	Plantar direction	Restricted and painful	No blockages
	Ventral direction	No blockages	No blockages
Metatarsophalangeal joint of the 1st to 5th toes shearing movement		No blockages	No blockages
Metatarsophalangeal joint of the 1st toe rotation		No blockages	No blockages
Proximal and distal phalanges (1st to 5th)	Plantar direction	No blockages	No blockages
	Ventral direction	No blockages	No blockages
	Lateral direction	No blockages	No blockages

Table 10: Initial examination of joint play of the SI joint and the lumbar and thoracic spine according to Lewit's method

SI joint	Left side: Restricted and stiff	Right side: Restricted and stiff
Lumbar spine	Flexion: No blockages	Extension movement decreased slightly in individual lumbar segments
Thoracic spine	Flexion: restricted in lower thoracic segments	Extension: Restricted in lower thoracic segments
	Lateral flexion to the left: No blockages	Lateral flexion to the right: Restricted in lower thoracic segments
	Rotation to the left: No blockages	Rotation to the right: Restricted in lower thoracic segments

3.2.12 Specialised tests

Trendelenburg's test

- Left side: Positive, dropping of the pelvis and visible gluteal weakness
- Right side: More controlled for short time

During the test the patient compensated by shifting the trunk backward and in slight rotation anticlockwise (on both sides, but more on the left side).

Patrick's sign

- Positive on both extremities.

Breathing examination

The patient has a paradoxal breathing pattern, but he can change it after instructions to perform a correct breathing pattern. The ribs do not expand in the lateral directions on both sides, but move in the cranial and caudal directions.

3.2.13 Conclusions of the examination

The patient is a 70-year-old male who complains of sharp LBP, which radiates to the left hip. He is currently complaining of pain at 6/10 on a VAS in the lumbosacral area at rest and during movement and pain in the left hip of about 4/10 on a VAS during ABD and external rotation of the hip.

The patient presents a positive Trendelenburg's test on the left side, with visible weakness of the gluteals, and a positive Patrick's sign bilaterally.

Flexion and extension of lumbar and lower thoracic spine are restricted, with good lateral flexion and rotation components. Pain was present on both sides. Both SI joints are restricted. Thoracic overloading (movements carried on by lower thoracic segments) is very visible in all movements of the trunk.

The patient has a shorter functional length of the right lower extremity by 1 cm, with the following muscles being hypertonic: iliopsoas (both side), gluteals and piriformis (very hypertonic) on both sides, quadratus lumborum (left side), biceps femoris and vastus medialis (both sides), and reports severe pain upon palpation of the pes inserinus bilaterally.

Shortened muscles are the TFL, adductor longus and lateral rotators of the hip, which limits the ROM on both sides, especially in the left hip during adduction (ADD), ABD and internal rotation to painful restrictions.

Neurological deficits include a decreased sensitivity of the lateral aspect of the left lower extremity and decreased proprioception on the left leg.

3.2.14 Main goal of therapy

The main goal of therapy was to reduce the pain that the patient feels at rest and during movement in the region of the lumbosacrum, and the pain in his left hip during movement so that he is able to perform his normal ADL and work in his garden. A second goal is to decrease the neurological symptoms that the patient displays on his left lower extremity.

3.2.15 Rehabilitation plan

Short-term plan:

- Decrease the hypertonicty of hypertonic muscles
- Increase the strength of the abdominals, gluteals and trunk muscles to gain spinal stability
- Correct the patient's posture
- Stretch the shortened muscles
- Decrease the neurological symptoms of the lower extremity
- Remove blockages found in the lower extremity joints, spinal segments and ribs
- Re-education of the patient's breathing, upper and lower breathing stereotypes, and the conventional lateral expansion of the diaphragm
- Postural re-education when sitting, standing, performing his ADL and working
- Educate the patient regarding the self-therapy exercises, and demonstrate how to perform them
- Help the patient to change the musculoskeletal structure of his body and therefore to decrease his pain

Long-term rehabilitation plan:

- Improve and maintain the short-term rehabilitation plan
- Increase his proprioception by sensorimotor training
- After performing detailed further examinations of the upper trunk and upper extremities, resolve the problems of the blockages found in the upper extremity joints, sternoclavicular joint and cervical spine
- Correct muscle imbalances caused by a combination of muscle hypertonicity, muscle shortness or/and weakness
- Attend to neurological symptoms that may arise in the examinations
- Education regarding the correct posture when sitting, standing, performing the ADL, driving and working

3.2.16 Therapy progress

Day to day therapy

Date: 18/01/2016

- Objective information: Patient was positive about starting the therapy.
- Subjective information: Before we began the therapy he complained about his back pain, especially when walking.
- Goal of today's therapy: A complete examination, and therapy to stretch the shortened muscles found during the examination and strengthen them, as well as mobilise any blocked segments.

Therapy proposal:

- Soft tissue techniques
- Post-isometric relaxation (PIR)
- Mobilisation
- Traction

Therapy:

- Soft tissue techniques of the sacral fascia in the caudal direction, as proposed by Lewit (2009).
- PIR relaxation as proposed by Lewit (2009) on the left piriformis, gluteus maximus, biceps femoris, adductor longus and gracilis, along with the ilipsoas.
- Mobilisation of the left head of the fibula in the dorsal direction, the navicular and cuboid in both dorsal and ventral directions and the Lisfranc joint in the plantar direction.
- Mobilisation of the spine according to Lewit (2009): the lumbar spine in lateral flexion and flexion, the thoracic spine both anticlockwise and clockwise, and mobilisation of individual segments in the prone position and while sitting.
- Mobilisation of the SI joint as proposed by Lewit (2009) on the left side.
- Traction by PIR of the left hip (Lewit, 2009).

- Traction mobilisation of the lumbar spine with the patient supine, knees in maximum flexion and hips at about 100° flexion, and movement by the lower extremity to the left and right in semi-circular motions (Lewit, 2009).

Results:

- Mobilisation relieved the pain in the left cuboid and navicular bones.
- The patient felt relief after the spinal mobilisation.
- The position for the iliopsoas PIR was unpleasant for the patient to maintain, therefore, a change of position is necessary for next session.
- The TFL, piriformis and gluteals were very hypertonic, and PIR will take time to work, therefore a change of therapy to proprioceptive neuromuscular facilitation (PNF) using relaxation techniques is needed.

Self-therapy:

Exercises:

- Control of pelvic movements: The patient should be in the supine position, and slowly perform anteversion and retroversion of the pelvis; one set of ten repeats, twice daily.
- Stretching of the hamstrings against a ball, and a piriformis stretch sitting on a chair, placing one leg over the other and pushing the knee of the top leg towards himself in a diagonal direction; twice daily, three times each stretch, holding the stretch for about 15 seconds.
- Gluteals: The patient should be in the prone position, and simply contract the gluteals without anterior tilt of the pelvis; two sets of ten repetitions, twice daily.
- Abdominals: The patient should be in a supine position, controlling the pelvis in retroversion, with the knees and hips flexed to 90° and the feet flat on a physioball. The patient contracts the abdominals to extend the hip and knee and push the ball forward with the feet; one set, ten repetitions, twice daily.
- Thoracic breathing: The patient should be on all fours, with a straight spine, and abducts one arm at a time with the head rotating to the direction of the arm being abducted. The patient breathes in during the arm ABD and breathes out when the

arm is brought back to the starting position. One set with ten repetitions on each side, twice daily.

- Breathing exercises: the patient should be supine, with the knees flexed so that the feet are flat on the ground. The arms are behind the head. The patient should breathe deeply, while trying to bring out the abdominal wall during breathing in, and the abdominal wall back down during breathing out; one set of ten repetitions, twice daily.

Day to day therapy

Date: 22/01/2016

- Objective information: The patient was looking forward to beginning his therapy, and he felt more confident about the session.
- Subjective information: No change in the patient's pain levels. However, he feels the breathing exercises helped to relieve his back pain slightly.
- Goal of today's therapy: Relaxation of the piriformis and gluteals. Regaining ROM in ABD and ADD of the hip.

Therapy proposal:

- Soft tissue techniques
- Mobilisation
- PNF
- Joint centration
- Traction

Therapy:

- Soft tissue techniques on the sacral fascia in the caudal direction by Lewit's method.
- Mobilisation by Lewit's method of the left head of fibula in dorsal direction, navicular and cuboid in both dorsal and ventral directions, and the Lisfranc joint in the plantar direction.

- Mobilisation of the spine by Lewit's method: the lumbar spine in lateral flexion and flexion; for the thoracic spine both anticlockwise and clockwise mobilisation of individual segments in both the prone and sitting positions.
- Mobilisation of the SI joint by Lewit's method on the left side.
- PNF by Kabat's technique.
- Hold-relax: on the left lower extremity, first diagonal flexion and extension, and the second diagonal extension pattern.
- Centration of the left hip by Kolar's method.
- Traction mobilisation of the lumbar spine by Lewit's method.

Results:

During PNF the patient struggled due to the stretching pain, especially on the second diagonal extension pattern at the end of the diagonal, although after the therapy, the pain in the left hip was reduced and the sharp pain in the lumbosacral area was slightly reduced as well.

Self-therapy:

Same as the previous programme.

2.2.16.3 Day to day therapy

Date: 25/01/2016

- Objective information: the patient asked for more exercises to do at home, and was very positive about today's therapy. He reported that the therapy so far had significantly reduced his pain.
- Subjective information: The pain had decreased in the left hip joint to about 1/10 on a VAS, and the lumbosacral pain had decreased in intensity to about 3/10 on a VAS.
- Goal of today's therapy: Continue relaxing the piriformis, gluteals, TFL and adductors; regain full ROM of the left hip in ABD and ADD; correct the muscular imbalance of the lower trunk. Strengthen the gluteals and abdominals to gain spinal stability. Educate the patient regarding sensori-motoric exercises for home therapy.

Therapy proposal:

- Soft tissue techniques
- PNF
- Mobilisation
- Joint centration

Therapy:

- Soft tissue techniques by the sacral fascia in the caudal direction by Lewit's method.
- PNF by Kabat's hold-relax technique on both the left and right lower extremity first diagonal flexion and extensions, and second diagonal extension pattern.
- Mobilisation of the spine by Lewit's technique: Lumbar spine in lateral flexion and flexion; for the thoracic spine, both anticlockwise and clockwise mobilisation of individual segments in the prone and sitting positions.
- Mobilisation of the SI joint by Lewit's method on the left side.

Results:

The patient was very positive. The adductors were more relaxed, the ROM of the left hip joint was 45°, and there is no longer a hard barrier.

Self-therapy:

As for the previous session, but now for the gluteal contraction exercises, he should contract the gluteals and slowly raise his leg (one at a time) for about a centimetre, trying to keep the pelvic from anteriorly tilting, for one set of ten repetitions, twice daily. The patient has more control over this movement now.

- Breathing exercises, as the patient feels these help a great deal with his pain: The patient should be in a sitting position, with the arms on the lateral aspect of the lower ribs. While breathing out, he should push his ribcage inwards, and when breathing in, he should relieve the resistance. On the third inspiration, he should quickly release his hands, allowing for an expansion of the ribcage in the lateral direction.

- Exercises for the external oblique abdominals: In the supine position, with the arms along the body, he should pull the rib cage down towards the symphysis and try to hold this position while breathing in normally. Next, one leg at a time, flex the knees and put the feet flat on the ground while keeping the ribcage down. Repeat one set of ten repetitions, twice daily.
- Piriformis stretch: In the supine position, the patient should bend both knees, hold one knee and bring it close to the chest, try to put the foot of the other leg onto the knee held close to the chest.

Sensori-motorics and advice:

- Use a spiky ball to facilitate the lower extremity. Use hot and cold towels, for one minute each on the left side of the lower extremity, 15 minutes a day.
- In a seated position, place the short foot on the floor, then try to push the knee down and hold the position of the short foot for ten minutes per day.
- Trying to abduct and adduct the toes while watching TV or doing paperwork at home.
- Correct gait re-education.

Day to day therapy

Date: 29/01/2016

- Objective information: The patient was very happy with the results of the therapy.
- Subjective information: The patient had not experienced any pain since his last session, and reported being able to carry out his ADL without pain.
- Goal of today's therapy: As for the last therapy session, correct the muscular imbalance with the exercises listed above.

Therapy proposal:

- Soft tissue techniques
- PNF
- Mobilisation and Joint centration

Therapy:

- Soft tissue techniques of the sacral fascia in the caudal direction by Lewit's method.
- PNF by Kabat's hold-relax technique on both the left and right lower extremity first diagonal flexion and extension, and the second diagonal extension pattern.
- Mobilisation of the spine by Lewit's method: the lumbar spine in lateral flexion and flexion; for the thoracic spine both anticlockwise and clockwise mobilisation of individual segments in the prone and sitting positions.
- Mobilisation of the SI joint by Lewit's method on the left side.
- Mobilisation of the left head of fibula in the dorsal direction, navicular and cuboid in both dorsal and ventral directions, and the Lisfranc joint in the plantar direction using Lewit's techniques.
- Manipulation of the ribs on the left side by Lewit's method.

Results:

Very satisfactory results were obtained. The pain in the left hip was 0/10 on a VAS, and the pain in the lumbosacral area was occasional and 1/10 on a VAS. The patient's left hip ABD and ADD is within the normal ROM, with no painful restrictions. Mobilisation has helped to release the painful blockages found in the joints, especially the spine.

The patient is able to control his pelvic movements now, and does all exercise precisely and carefully. He can also control his breathing pattern, and realises when he is using paradoxal breathing and changes it when concentrating. The patient can also take the position for iliopsoas PIR by Lewit's technique easily now, and without pain. Most importantly, the patient is able to perform his ADL without experiencing pain.

Self-therapy:

- All the exercises the patient has learned during the therapy sessions
- Head and neck exercises that the patient has learned, and is able to perform without difficulty
- Self-PIR for the sternocleidomastoid, levator scapulae, trapezius upper fibres and scalene anterior

- Pushing the chin back, then holding and releasing it while maintaining the correct posture of the head and neck to try to increase the activity of the deep neck flexors.

3.3 Final kinesiological examination

Final scale test: 50 kg on the left side, 51 kg on the right side

3.3.1 Postural examination, Kendall's method

Results of the postural examination using the Kendall (2005) method with the posterior, side and anterior views during the final examination are presented in Table 11.

Table 11: Results of the final postural examination

Posterior view	Side view (left and right)	Anterior view
Both scapulae abducted Left shoulder higher than right Short base of foot Normal extension of the left knee Slight valgosity of the left ankle	Slight lordosis of the lumbar spine Thoracic spine, less kyphosis Cervical spine, less kyphosis Shoulders protruded Head forward	Left shoulder higher than right Position of head in the midline with slight rotation to the right Hyperactivity of SCM visible Eversion in both feet Short base of foot Abdominal slackening

3.3.2 Gait examination by Kendall's method

- Short base, equal length of strides
- Takeoff at metatarsal ends of feet
- Starting to use extension of the hip, and less flexion of the knees
- Head protrusion
- More arm movements
- Improvement of pelvic movement synkinesis

Modifications

Table 12: Final examination and results of gait modification

Tiptoes (s1)	Able to execute normally
On heel (L5)	Able to execute with more stability
Squat (L3/4)	Able to execute without pain
Backward (gluteals)	Able to execute normally
Sideways (adductors and abductors)	Able to execute normally

3.3.3 Pelvic examination

- Crest: Same level
- PSIS: Same level
- ASIS: Same level
- ASIS and PSIS (right side): PSIS slightly higher
- ASIS and PSIS (left side): PSIS slightly higher

Result: Patient has a physiological anterior pelvic tilt

3.3.4 Dynamic spine test

Flexion

- Lumbar spine less flat, the loading is spread through the upper and lower thoracic spine
- Normal ROM
- Slow performing the movement
- Patient controls the anteversion to about 40° of trunk flexion

Extension

- Normal ROM
- Loading is spread across the upper and lower parts of the thoracic spine
- No pain during movement

Lateral flexion to the right

- Normal ROM
- Arms are in contact with the body
- Loading is spread across the upper and lower parts of the thoracic spine

Lateral flexion to the left

- Decreased ROM by 5 cm compared to the right side
- Arms are in contact with the body
- Loading is spread across the upper and lower parts of the thoracic spine

Rotation to the left and right

- Movement substitution by trunk is more controlled and less in the sagittal plane compared to the initial kinesiological examination
- During assisted rotation, the rotation is 30° to both sides and the patient does not feel any pain

3.3.5 Altered movement patterns, by Janda's method

Extension

Right lower extremity extension: Anterior tilt of the pelvis was controlled, followed by activation of the gluteals, hamstrings and co-activation of the paravertebrals. The ROM was 10°.

Left lower extremity extension: The same movement synkinesis as observed in the initial examination, but less exaggerated. The ROM in extension was a few degrees more than the right.

Abduction

Right lower extremity: The pelvis movement was more controlled and the leg moved in the coronal plane.

Left lower extremity: The pelvis movement was more controlled and the leg moved in the coronal plane.

Result: When the patient was concentrating on the movement, he was able to fix his movement pattern.

Curl-up

Anterior tilt of the pelvis was controlled, flexion of the knees and hip was still present but is not excessive, abdominal strength is starting to be observed.

3.3.6 Anthropometry

Table 13: Final anthropometry results for the lower extremities during the final examination

Lower extremity	Left (cm)	Right (cm)
Anatomical length	107	107
Functional length	104	103

3.3.7 Soft tissue examination, Lewit's method

Kibler's fold: It was easier to gain a skin fold.

Skin mobility and elasticity: There was no restriction in the lumbar area in any direction.

Fascia: There was an increase in movement of the TLF in the caudal direction.

3.3.8 Range of motion examination, Kendall's method

Table 14: Final examination of the active and passive ROM of the hips and knees

		Left (degrees)		Right (degrees)	
		Active	Passive	Active	Passive
Hip	S	10-0-110	15-0-120	10-0-110	15-0-120
	F With knee extended	45-0-30	45-0-30	45-0-40	45-0-40
	F With knee flexed	45-0-30	45-0-35	45-0-40	45-0-40
	R90	45-0-25	45-0-30	35-0-25	45-0-35
Knee	S	0-0-140	0-0-140	0-0-140	0-0-140

The most improved ROM parameters are ABD at the hip by 15° on the left and 10° on the right, along with ADD of the hip by 10° on the left and 5° on the right.

Results: The most improved parameters are bilateral hip flexion, ABD and ADD, which are within the normal ROM.

3.3.9 Neurological examination

Superficial sensation examination of the lower extremity: Light touch.

Results:

- Decreased sensitivity of the lateral aspect of the thigh and shaft and foot of the left leg; however, the patient feels that the difference when comparing the two legs is better than it was in the first session

Deep sensation examination: Movement sense and position sense examination of the big toe.

Results:

- Decreased proprioception of the left lower extremity
- Intact proprioception of the right lower extremity

Reflexes: Mono-reflexes of the patella (L2–L4), hamstring (L5–S1) and Achilles (S1).

Results:

- Normal reflexes

Provocative tests: Laseque's sign, reverse Laseque's sign and Bragard's sign.

Results:

- All signs were negative on both extremities

3.3.10 Muscle palpation, muscle length and muscle strength tests, Kendall's method

Table 15: Final examination of muscle tone, muscle length and muscle strength of the left and right lower extremities

Muscles tested	Left lower extremity			Right lower extremity		
	Muscle tone	Muscle shortness	Muscle strength	Muscle tone	Muscle shortness	Muscle strength
Quadrates lumborum			4			4-
Gluteus maximus	Decreased		4-	Decreased		4-
Gluteus medius and minimus			4-			4-
Coccygeus						
Adductor longus			4+			4+
Adductor brevis			4			4+

Adductor magnus			4			4+
Gracilis			4			4+
Hip lateral rotators (gamellues superior and inferior, obturator externus and internus, piriformis and quadratus femoris)		√	3+		√	3+
Piriformis	Decreased		4+	Decreased	√	4+
Ilipsoas	Decreased	√ Decreased	3+	Decreased	√ Decreased	4-
Tensor facia latae	Decreased		4+			4+
Sartorius			4+			4+
Biceps femoris			4+			4+
Semimembranosus			4			4+
Semitendinosus			4			4
Rectus femoris			4+			4+
Vastus medialis			4+			4+
Vastus lateralis and intermedius			4+			4+
Gastrocnemius and plantaris			4+			4+
Soleus			4+			4+
Peroneus longus and brevis			4			4+
Tibialis posterior			4			4+
Tibialis anterior			4			4
Rectus abdominals			3+			3+
Transverse abdominal	Decreased		3			3
External and internal obliques			3+			3+

Results:

Generally, the hypertonicity has decreased in all of the muscles listed above, especially the left quadratus lumborum, gluteus maximus, adductors, piriformis, iliopsoas and TFL. Muscle shortness has also been resolved, except for the left and right lateral rotators of the hip joint, which corresponds to the decrease in internal rotation of the hip.

3.3.11 Joint play by Lewit's method

Table 16: Final examination of joint play of selected joints of the left and right lower extremities

		Left lower extremity	Right lower extremity
Head of fibula	Dorsal direction	No blockages	No blockage
	Ventral direction	No blockages	No blockages
Talocrural joint in dorsal direction		No blockages	No blockages
cuboid	Planter direction	No blockages	No blockage
	Ventral direction	No blockages	No blockage
Navicular	Planter direction	No blockage	No blockages
	Ventral direction	No blockage	No blockages
Lisfrank joint	Planter direction	No blockage	No blockages
	Ventral direction	No blockages	No blockages
Metatarsophalangeal joint of the (1st to 5th toes) shearing movement		No blockages	No blockages
Metatarsophalangeal joint of the 1st toe rotation		No blockages	No blockages

Table17: Final examination of joint play of the SI joint and lumbar and thoracic spine according to Lewit's method

SI joint	Left side: No blockage	Right side: No blockage
Lumbar spine	Flexion: No blockages	Extension: No blockage in lower thoracic segments
Thoracic spine	Flexion: No blockage in lower thoracic segments	Extension: No blockage in lower thoracic segments
	Lateral flexion to the left: No blockages	Lateral flexion to the right: No longer blocked in the lower thoracic segments
	Rotation to the left: No blockages	Rotation to the right: No longer blocked in the lower thoracic segments

Ribs

The ribs nicely expand during inspiration and approximate during expiration (bilaterally, although the left side is expands and approximates more).

3.3.12 Specialised tests

Trendelenburg's test

- Left side: Better control; however, compensation of the trunk by moving backward
- Right side: Pelvis slightly rotated anticlockwise; however, better gluteal control is observed, and well balanced

Overall result: Better stabilisation of the pelvis and proper gluteal activation is observed.

Patrick's sign

- Positive on both lower extremities, but the distance of the knees to the bed is closer than it was in the initial kinesiological examination.

Breathing examination

The patient is able to control his paradoxal breathing pattern when he is concentrating by using his hands. The ribs have begun to expand in lateral direction as well.

3.3.13 Conclusion of the final examination

Overall, the patient's posture has improved, and the flat lumbar curvature is now slightly lordotic. The TLF has been stretched and is no longer restricted.

The most improved ROM parameters are ABD at the hip by 15° on the left and 10° on the right, along with ADD of the hip by 10° on the left and 5° on the right.

With respect to the muscles, a decrease of hypertonicty is observed in both lower extremities; however, a greater decrease in tone was noted on the left side in the following muscles: quadratus lumborum, gluteus maximus, adductors, piriformis, iliopsoas and TFL. A visible increase in muscle strength is seen in bilateral abdominals and gluteus maximus; and the Trendelenburg's test shows an improvement in gluteal activation and proper pelvic stabilisation of both left and right sides, yet more on the left side.

The restrictions located in the SI joint, lumbar and thoracic spines, ribs, head of fibula, navicular and cuboid bones have been resolved. The patient's sensation in the left lower extremity is increased when compared to the other extremity. Finally, the breathing stereotype has improved, and the ribs are undergoing normal physiological lateral expansion. The patient's pain has decreased about 0/10 in VAS in the lumbosacral junction and the left hip as well.

3.3.14 Therapy effects

Table 18: Main findings of initial and final examinations

Initial examination	Final examination
Posture Posterior Hyperextension of the left knee Side view (left and right) Thoracic kyphosis Cervical kyphosis	**Posture** Posterior Normal extension of the left knee Side view (left and right) Thoracic spine, less kyphosis Cervical spine, less kyphosis
Gait examination No extension of hip, compensated by excessive flexion of the knees Very slight arm movements No trunk or pelvic movements (stiff posture)	**Gait examination** Starting to use extension of the hips, less flexion of the knees More arm movements Improvement of pelvic movement synkinesis
Gait modification examination On heel (L5): Able to execute, with poor instability Squat (L3/4): Able to execute, with pain in the lumbosacral area Backward (gluteals): Able to execute, with small ROM into extension	**Gait modification examination** On heel (L5): Able to execute, with more stability Squat (L3/4): Able to execute, without pain Backward (gluteals): Able to execute normally
Dynamic spine test Flexion Small ROM Thoracic kyphosis and overload (more on the left paravertebral) Anterior pelvic tilt during the movement Extension Small ROM Thoracic overloading (entire movement) Mild pain present in the lumbar region during the	**Dynamic spine test** Flexion Normal ROM Lumbar spine less flat, the loading spread through the upper and lower thoracic spine Able to control anteversion about 40° of trunk flexion Extension Normal ROM Loading is spread across the upper and lower

movement Lateral flexion to the right Thoracic overloading: The entire movement is carried out by the lower thoracic segments. Lateral flexion to the left Decreased ROM by 10 cm compared to the right Thoracic overloading: The entire movement is carried out by the lower thoracic segments Rotation to left and right Movement substitution by the trunk moving along the sagittal plane During assisted rotation, the rotation was 10° more to both sides and the patient felt pain about 3/10 on a VAS in the lumbosacral area	parts of the thoracic spine, no pain during the movement Lateral flexion to the right Loading is spread across the upper and lower parts of the thoracic spine Lateral flexion to the left Decreased ROM by 5 cm compared to the right Loading is spread across the upper and lower parts of the thoracic spine Rotation to left and right Movement substitution by the trunk is more controlled and less in the sagittal plane During assisted rotation, the rotation is 30° to both sides and the patient feels pain of 0/10 on VAS in the craniomedial sacral area
Altered movement patterns Extension Physiological, the ROM was 5° **ABD** Right lower extremity: the pelvis moves forward, and the leg is externally rotated Left lower extremity: the pelvis moves forward, and the leg is flexed and external rotation. **Curl-up** Anterior tilt of the pelvis, flexion of the knees and hips, very weak abdominals. The patient incapable of correcting the movement synkinesis after being given instructions **Soft tissue examination** Kibler's fold: Not possible to perform on the lumbar and lower thoracic areas Skin mobility and elasticity: Slight restriction in the lumbar area in all directions Fascia: Restriction of the TLF in the caudal direction	**Altered movement patterns** Extension Physiological, the ROM was 10° **ABD** Right lower extremity: the pelvis movement was more controlled and the leg moved in the coronal plane Left lower extremity: the pelvis movement was more controlled and the leg moved in the coronal plane **Curl-up** Anterior tilt of the pelvis is controlled, flexion of the knees and hip still present but not excessive, abdominal strength observed **Soft tissue examination** Kibler's fold: It is easier to gain a skin fold Skin mobility and elasticity: No restriction in the lumbar area in any direction Fascia: An increase in movement of the TLF in the caudal direction

Range of motion examination

The most improved ROM parameters are ABD at the hip by 15° on the left and 10° on the right, along with ADD of the hip by 10° on the left and 5° on the right.

Neurological examination

Superficial sensation examination of the lower extremity by light touch revealed decreased sensitivity of the lateral aspect of the thigh and the shaft and foot of the left leg. However, during the final examination the patient stated that he felt that the difference between the two legs is less than it was on the initial examination.

Manual muscle testing

In general, the hypertonicity has decreased in all muscles, especially in the left quadratus lumborum, gluteus maximus, adductors, piriformis, iliopsoas and TFL. Muscle shortness has also been resolved, except for the left and right lateral rotators of the hip joint, which corresponds to the decrease in internal rotation of the hip.

Joint play examination

Table 19: Comparison of the results of the initial and final joint play examinations

Initial examination	Final examination
Head of fibula: Dorsal direction, right side, restricted but not painful	Head of fibula: Dorsal direction, right side, no blockage
Cuboid: Plantar and ventral directions, right side restricted and painful	Cuboid: Plantar and ventral directions, right side, no blockage
Navicular: Plantar and ventral directions, left side, restricted and painful	Navicular: Planter and ventral directions, left side, no blockage
Lisfranc joint: Plantar direction, left side, restricted and painful	Lisfranc joint: Plantar direction, left side, no blockage
SI joint on both sides: Flexion restricted and stiff, extension restricted and stiff	SI joint on both sides: Flexion, no blockage; Extension, no blockage
Lumbar spine extension: Movement decreased slightly in individual lumbar segments	Lumbar spine extension: Regained movement in individual lumbar segments
Thoracic spine: Flexion, extension; Lateral flexion and rotation to the right side restricted in the lower thoracic segment	Thoracic spine: Flexion, extension; Lateral flexion and rotation to the right side, no blockage

Breathing examination

Table 20: Comparison of the results of the initial and final breathing examinations

Initial examination	Final examination
During breathing the ribs do not expand in lateral directions on both side, but move in cranial and caudal directions	The ribs expand during inspiration and approximate during expiration bilaterally, although the left side expands and approximates more

Special tests

Table 21: Comparison of the results of the initial and final special tests

Initial examination	Final examination
Trendelenburg' test Left side: Positive, dropping of the pelvis and visible gluteal weakness Right side: More controlled for short times	**Trendelenburg's test** Left side: Better control, but compensation of the trunk by moving backward Right side: Pelvis slightly rotated anticlockwise; however, better gluteal control is observed, and well balanced
Patrick's sign Positive on both extremities	**Patrick's sign** Positive on both lower extremities, but the distance of the knees to the bed is less than on initial kinesiological examination

3.3.15 Prognosis

The patient will continue to come to the Malvazinky Clinic for further rehabilitation once a week for at least another three weeks. It is important to continue to promote self-management because the therapy has been effective for his LBP. If the patient continues his active rehabilitation programme and considers taking more physical exercise he will continue to improve his spinal stability and quality of life. In addition to conditioning his back, he needs to condition his whole body. Physical activities such as walking or swimming can help to strengthen his back. It will be necessary to plan and start a more rigorous exercise programme after his pain is completely resolved and he has a good understanding of basic simple exercises. It is important that he begins this programme slowly. His future exercise programme could include walking, bicycling or swimming, along with strength training.

4 Conclusion

The results above show that the applied therapy has been successful and beneficial for the patient. The therapy has been focused a lot on approaches for improving his posture. I think that the reason for his problems has been contributed due to this posture fault in both sitting and standing. There has also been a large focus on the patient´s breathing pattern, which I think also has a lot to do with her musculoskeletal dysbalance. during the practice, I have learned the importance of rehabilitating breathing pattern dysfunction to aid in the rehabilitation and restoration of spine stability. I have learned that knowledge and skills are the components of successful therapy, however, communication and cooperation with your colleagues are needed as well. I think that all the experiences, which I had during my work, will improve the quality of my career as well as my personal life.

5 Reference list

Anderson, S. M. (2007). Spinal curves and scoliosis. *Radiologic Technology, 79*(1), 44–65.

Balagué, F., Mannion, A. F., Pellisé, F., & Cedraschi, C. (2012). Non-specific LBP. *Lancet, 379*(9814), 482–491.

Bogduk, N. (2005). *Clinical anatomy of the lumbar spine and sacrum*. Oxford: Elsevier Health Sciences.

Bogduk, N. (2012). *Clinical and radiological anatomy of the lumbar spine*. Oxford: Elsevier Health Sciences.

Burton, A. K., Balagué, F., Cardon, G., Eriksen, H. R., Henrotin, Y., & Lahad, A. (2004). *European guidelines for prevention in LBP.* Brussels: European Commission Research Directorate General.

Dawson, M. D. (2016). *Herniated disc: Treatment and recovery*. Retrieved from: http://www.spineuniverse.com/conditions/herniated-disc/herniated-disc-treatmentrecovery.

Ellis, H., & McLarty, M. (1962). Anatomy for anaesthetists: The lumbar spine and sacrum. *Anaesthesia, 17*(2), 238–246.

Gray, H. (1918). Anatomy of the human body, by Henry Gray. Thoroughly reviewed and re-edited by W. H. Lewis.

Gunzburg, R., & Szpalski, M. (Eds.). (2006). *Spondylolysis, spondylolisthesis, and degenerative spondylolisthesis*. Philadelphia: Lippincott Williams & Wilkins.

Hirsch, C. (1955). The reaction of intervertebral discs to compression forces. *Journal of Bone and Joint Surgery of America, 37*(6), 1188–1196.

Jensen, G. M. (1980). Biomechanics of the lumbar intervertebral disc: A review. *Physical Therapy, 60*(6), 765–773.

Kendall, F. P., McCreary, E. K., Provance, P. G., Rodgers, M. M., & Romani, W. A. (2005). Muscles: testing and function with posture and pain.

Kinkade, S. (2007). Evaluation and treatment of acute lower back pain. *American Family Physician, 75*(8), 1181–1188.

Koes, B. W., Van Tulder, M. W., & Thomas, S. (2006). Diagnosis and treatment of lower back pain. *British Medical Journal, 7555,* 1430.

Kolár, P., & Andelova, V. (2013). *Clinical rehabilitation*. Prague: Rehabilitation Prague School.

Lewit, K. (2009). *Manipulative therapy: Musculoskeletal medicine*. Edinburgh: Elsevier/Churchill Livingstone.

Liebenson, C. (Ed.). (2007). *Rehabilitation of the spine: A practitioner's manual*. Philadelphia: Lippincott Williams & Wilkins.

Manek, N. J., & MacGregor, A. J. (2005). Epidemiology of back disorders: Prevalence, risk factors, and prognosis. *Current Opinion in Rheumatology, 17*(2), 134-140.

McGill, S. (2007). Low back disorders: Evidence-based prevention and rehabilitation. *Human Kinetics,*

McKenzie, R. A., & May, S. (1981). The lumbar spine. *Mechanical Diagnosis & Therapy, 1,* 374.

Nickelston, P. (2013). Thoracolumbar fascia: The chronic pain linchpin. *Dynamic Chiropractic, 31,*

Oatis, C. A. (2003). The mechanics and pathomechanics of human movement.

Openstax. (2016). *The pelvic girdle and pelvis*. Retrieved from http://philschatz.com/anatomy-book/contents/m46375.html

Page, P., Frank, C., & Lardner, R. (2010). Assessment and treatment of muscle imbalance: the Janda approach.

Platzer, W. (1984). *Color atlas and textbook of human anatomy: Locomotor System*. vol. 1.

Shahbandar, L., & Press, J. (2005). Diagnosis and non-operative management of lumbar disc herniation. *Operative Techniques in Sports Medicine, 13*(2), 114–121.

Schroth, T. D. S., & Borysov, B. (2006). Indications for conservative management of scoliosis (guidelines). *Scoliosis, 1,*

Smith, M. D., Russell, A., & Hodges, P. W. (2006). Disorders of breathing and continence have a stronger association with back pain than obesity and physical activity. *Australian Journal of Physiotherapy, 52*(1), 11–16.

Standaert, C. J., & Herring, S. A. (2000). Spondylolysis: A critical review. *British Journal of Sports Medicine, 34*(6), 415–422.

Steiner, M. E., & Micheli, L. J. (1985). Treatment of symptomatic spondylolysis and spondylolisthesis with the modified Boston brace. *Spine, 10*(10), 937–943.

Turner, R. H., & Bianco, A. J. (1971). Spondylolysis and spondylolisthesis in children and teenagers. *Journal of Bone and Joint Surgery of America, 53*(7), 1298–1306.

Vleeming, A., Pool-Goudzwaard, A. L., Stoeckart, R., van Wingerden, J. P., & Snijders, C. J. (1995). The posterior layer of the thoracolumbar fascia: Its function in load transfer from spine to legs. *Spine, 20*(7), 753–758.

6 Supplementary material

Ethics committee approval form

UNIVERZITA KARLOVA V PRAZE
FAKULTA TĚLESNÉ VÝCHOVY A SPORTU
José Martího 31, 162 52 Praha 6-Veleslavín

Application for Approval by UK FTVS Ethics Committee

of a research project, thesis, dissertation or seminar work involving human subjects

The title of a project: Physiotherapeutic case study of chronic low back pain
Project form: bachelor
Period of realization of the project: January 2016
Applicant: Msab Al-Sheik
Main researcher: Msab Al-Sheik
Co-researcher(s):
Supervisor (in case of student's work): Peter Horvath
Financial support:

Project description: My project is about a patient suffering from chronic low back pain. He is out patient in Rehabilitační klinika Malvazinky, Praha 5. First session: initial kinesiological examination for 15 minutes and therapy, with supervisor, according to his instruction and the hospital protocol. The method used: (PIR) and joint mobilization according to Lewit Soft tissue technique, gait training, passive - active movement and passive active stretching. Final session: the final kinesiological examination - in the 4th session.

Ensuring safety within the research: Non- invasive methods were used. The work with patient is done according to hospital protocol.

Ethical aspects of the research: The participant is an adult and he is non-vulnerable, all personal data remain anonymised.

Informed Consent: attached

It is a duty of **all participants of the research team** to protect life, health, dignity, integrity, the right to self-determination, privacy and protection of the personal data of all research subjects, and to undertake all possible precautions. Responsibility for the protection of all research subjects lies on the researcher(s) and not on the research subjects themselves, even if they gave their consent to participation in the research. All participants of the research team must take into consideration ethical, legal and regulative norms and standards of research involving human subjects applicable not only in the Czech Republic but also internationally.

I confirm that this project description corresponds to the plan of the project and in case of any change, especially of the methods used in the project, I will inform the UK FTVS Ethics Committee, which may require a re-submission of the application form.

In Prague, 01. 02. 2016 Applicant's signature:

Approval of UK FTVS Ethics Committee

The Committee: Chair: doc. PhDr. Irena Parry Martínková, Ph.D.
Members: prof. PhDr. Pavel Slepička, DrSc.
doc. MUDr. Jan Heller, CSc.
doc. Ing. Monika Šorfová, Ph.D.
Mgr. Pavel Hráský, Ph.D.
MUDr. Simona Majorová

The research project was approved by UK FTVS Ethics Committee under the registration number: 057/2016
Date of approval: 4.2.2016

UK FTVS Ethics Committee reviewed the submitted research project and **found no contradictions** with valid principles, regulations and international guidelines for carrying out research involving human subjects.

The applicant has met the necessary requirements for receiving approval of UK FTVS Ethics Committee.

Stamp of UK FTVS

UNIVERZITA KARLOVA v Praze
Fakulta tělesné výchovy a sportu
José Martího 31, 162 52, Praha 6
1

Signature of the Chair of UK FTVS Ethics Committee

INFORMOVANÝ SOUHLAS

Vážená paní, vážený pane,
v souladu se Všeobecnou deklarací lidských práv, zákonem č. 101/2000 Sb., o ochraně osobních údajů a o změně některých zákonů, ve znění pozdějších předpisů, Helsinskou deklarací, přijatou 18. Světovým zdravotnickým shromážděním v roce 1964 ve znění pozdějších změn (Fortaleza, Brazílie, 2013) a dalšími obecně závaznými právními předpisy Vás žádám o souhlas s prezentováním a uveřejněním výsledků vyšetření a průběhu terapie prováděné v rámci praxe na1 …….……., kde Vás příslušně kvalifikovaná osoba seznámila s Vaším vyšetřením a následnou terapií. Výsledky Vašeho vyšetření a průběh Vaší terapie bude publikován v rámci bakalářské práce na UK FTVS, s názvem2 ……

Získané údaje, fotodokumentace, průběh a výsledky terapie budou uveřejněny v bakalářské práci v anonymizované podobě. Osobní data nebudou uvedena a budou uchována v anonymní podobě. V maximální možné míře zabezpečím, aby získaná data nebyla zneužita.

Jméno a příjmení řešitele ..... Podpis:.....

Jméno a příjmení osoby, která provedla poučení3.....Podpis:.....
Prohlašuji a svým níže uvedeným vlastnoručním podpisem potvrzuji, že dobrovolně souhlasím s prezentováním a uveřejněním výsledků vyšetření a průběhu terapie ve výše uvedené bakalářské práci, a že mi osoba, která provedla poučení, osobně vše podrobně vysvětlila, a že jsem měl(a) možnost si řádně a v dostatečném čase zvážit všechny relevantní informace, zeptat se na vše podstatné a že jsem dostal(a) jasné a srozumitelné odpovědi na své dotazy. Byl(a) jsem poučen(a) o právu odmítnout prezentování a uveřejnění výsledků vyšetření a průběhu terapie v bakalářské práci nebo svůj souhlas kdykoli odvolat bez represí, a to písemně zasláním Etické komisi UK FTVS, která bude následně informovat řešitele.

Místo, datum .....
Jméno a příjmení pacienta ..... Podpis pacienta:.....
Jméno a příjmení zákonného zástupce4 .....…..
Vztah zákonného zástupce k pacientovi ..... Podpis: .....

List of tables

List of figures

List of abbreviations

ABD: Abduction

ADD: Adduction

ADL: Activities of Daily Living

ALL: Anterior Longitudinal Ligament

ASIS: Anterior Superior Iliac Spine

Cm: Centimetres

FTVS: Fakulta Telesne Vychovy a Sportu

IAP: Intra-abdominal Pressure

IVD: Intervertebral Disc

Kg: Kilograms

LBP: Low back pain

LS: Lumbosacral

NSAID: Non-steroidal Anti-inflammatory Drug

PIR: Post-isometric Relaxation

PLL: Posterior Longitudinal Ligament

PNF: Proprioceptive Neuromuscular Facilitation

PIIS: Posterior Inferior Iliac Spine

PSIS: Posterior Superior Iliac Spine

ROM: Range of Motion

SC: Sacrococcygeal

SI: Sacroiliac

TFL: Tensor fascia latae

VAS: Visual Analogue Scale

SCM: Sternocleidomastoid