Charles University
Faculty of Physical Education and Sport
Department of Physiotherapy
Bachelor's Program in Physiotherapy Specialization in Health Care

Bachelor's Thesis

Physiotherapeutic Treatment of a Patient with Diagnosis of Ankle Distortion

Submitted by

Panayiotis Vryonides

On May 30, 2014

Supervisor
PhDr. Tereza Novakova, Ph.D.

Instructor
Mgr. Zaher El Ali

Abstract

Title: Physiotherapeutic treatment of a patient with ankle distortion

Nazev: Fyzioterapeutická léčba pacienta s zkreslení kotníku

Author: Vryonides Panayiotis

Location of clinical practice: C.L.P.A **(Centrum léčby pohybového aparátu)**

Aim

The purpose of my bachelor thesis is to understand the structure and function of the ankle joint as well to discuss the most common injuries concerning the ankle. Moreover a day-to-day rehabilitation program will be presented concerning ankle distortion.

Summary

The bachelor thesis consists of two major parts, the general part where an extensive analysis concerning the diagnosis (ankle distortion), the anatomy, biomechanics and common injuries takes place. Moreover it follows the practical part, which also is the main part of the thesis. It consist the anamnesis, all the initial and final examinations and the day after day rehabilitation procedures and progress. Regarding the therapeutic session, they were composed with stability exercises, sensomotoric stimulation, strengthening and also from physical therapy laser.

Results

Subsequently of the eight rehabilitation sessions that I had with my patient, he fully recovers. The pain and the limitation on the ankle joint that he had wasn't enormous as a result to succeed great results in that limited time that we had. A full range of motion, elimination of the pain and a significant improvement in terms of stability and balance was achieved.

Key words: ankle, ankle distortion, physiotherapy, and stability

Declaration

I declare that this bachelor thesis has been entirely based on my own individual work and on my own practice that took place at C.L.P.A (Centrum léčby pohybového aparátu) clinic in Prague from 3/2/14 until 14/2/14.

The entire information gather in this bachelor thesis has been listed in the references, which exist at the end of the thesis. I also want to mention that my patient was aware for all the examination procedures and therapies. Finally the patient and I signed a proposed informed approval.

Prague,
May, 2014 Panayiotis Vryonides

Acknowledgment

I would like to express my gratitude towards my family for the endless and unconditional support that they offer me during this stressful process. It has been difficult and without their support it would be even worse.

In addition I would like to thank all of my professors for the knowledge and the help for all the three years of my studies. Special thanks, to my supervisor PhDr. Tereza Novakova, Ph.D, for her valuable help through the demanding process of writing my bachelor thesis. Moreover, I would like to thank my supervisor at C.L.P.A (Centrum léčby pohybového aparátu), Mgr. Zaher EL Ali for his valuable guidance and for the creative cooperation we had.

Table of Contents

1. Preface (Introduction)

My physical therapy practice took place at C.L.P.A (Centrum léčby pohybového aparátu). My practical experience was scheduled for two weeks starting from 3rd of February until the 14th of February 2014.

The diagnosis that I choose to have for my thesis was an Ankle Distortion. My patient is a young hockey athlete, eighteen years old male. He obtained the injury on his ankle after a crush with an opponent during a match on 31st of January.

Concerning the goals of the therapeutic plan was to decrease pain, increase range of motion and regain stability of the ankle.

Regarding the theoretical part of the thesis, it is focused on the anatomy of the ankle, the kinesiology and biomechanical point of view. Moreover there are included information about the examination procedures and the therapeutic sessions throughout my practice.

In favor of practical part I evaluate all the information that were possible to be obtained. Furthermore in that part of the thesis which also to mention that is the biggest from the two, consists of the patients anamnesis, initial and final examination, short and long rehabilitation plans, conclusion of examination and evaluation of the effect of therapy.

2. General Part

2.1. Anatomy of the ankle joint

The ankle joint considers being synovial in its type and involves the talus of the foot and the tibia and fibula of the leg. The main movements permitted in the ankle joint are hinge-like dorsiflexion and plantar flexion of the foot. (Drake, 2009)

Additionally the foot ordinarily rests on the sole (plantar) surface and exposes the upper (dorsal) surface. The outstanding deviation of a foot is the enlargement and backward projection of one of its bones to form the heel. (Peck, 1951)

The ankle joint acts as a shock absorber and propulsion engine for the body. The foot and ankle consists of twenty-six bones, thirty-three joints, more than one hundred muscles, tendons and ligaments and a network of nerves, skin, soft tissues and blood vessels. The coo function of these structures provides the body with balance, stability and support. (Paulsen et al, 2011)

2.1.1. Bones of the ankle joint

The bones consists the ankle joint are the two bones of the lower leg (fibula and tibia) and the talus of the foot.

The tibia also recognized, as the shinbone is the stronger of the two bones of the lower leg and also connects the knee with the ankle. Moreover at the distal end it forms the medial malleolus. The fibula also called calf bone is located laterally to tibia and its distal end shapes the lateral malleolus. (Feneis et al, 2000)

The talus is a bone from the group of bones in the foot. Together with the two bones of the lower leg they form the ankle joint.

Figure 1: The bones of the foot and lower leg (Clemente, 2006)

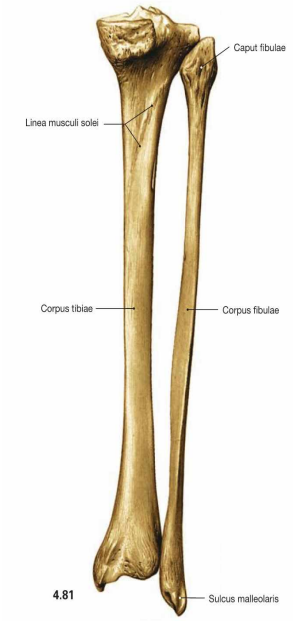

Figure 2: The bones of the lower leg (Paulsen et al, 2011)

2.1.2. Arches of the foot

The structure of the foot bones does not lie in a horizontal plane but they are forming longitudinal and transverse arches. Those arches are very important for the whole body posture as they absorb and distribute the downward forces from the body during standing and moving.

The longitudinal arch of the foot is organized between the posterior end of the calcaneus and the heads of the metatarsals. It can be observed more on the medial aspect of the foot as there it forms the highest point.

The transverse arch of the foot reaches its highest point in a coronal plane, from the head of talus to the metatarsal heads.

Furthermore for maintaining these arches there exist specific structures as ligaments and muscles that provide support. These ligaments are plantar calcaneonavicular, plantar calcaneocuboid, long plantar ligaments and plantar aponeurosis. Additionally muscles that supply dynamic support during walking are tibialis anterior-posterior and fibularis longus. (Drake, 2009)

2.1.3. Ligaments of ankle joint

The ligaments around the ankle can be divided, depending on their anatomic position, into three groups: the lateral ligaments, the deltoid ligament on the medial side, and the ligaments of the tibiofibular syndesmosis that join the distal epiphyses of the bones of the lower leg (tibia and fibula). (Golano et al, 2010)

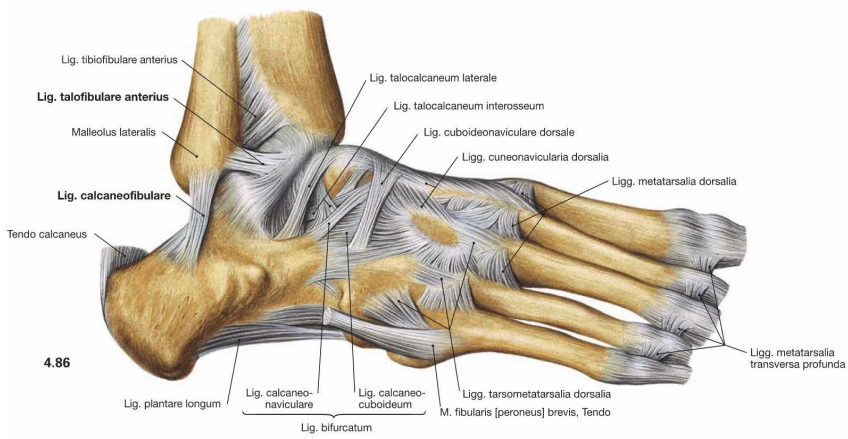

Figure 3: The ligaments of the ankle joint (Paulsen et al, 2011)

2.1.4. Muscles of the ankle joint

The muscles of the lower leg are divided in three groups, the posterior, the lateral and the anterior compartments. Furthermore there exist two more categories of muscles on the foot, on the dorsal and sole aspect. The muscles located in the sole aspect have a further subdivision of four layers.

The posterior compartment consists of the muscles mainly responsible for plantarflex, invert the foot and flex the toes. It is also divided in two subgroups the superficial and the deep. The superficial group is composed of large and powerful muscles as it is necessary to propel the body forward off the planted foot during walking and can elevate the body upwards onto the toes during standing. (Drake, 2009)

Muscle	Origin	Insertion	Innervation	Action
Gastrognemius	Medial head- medial femur condyle Lateral head- lateral femur condyle	Posterior surface of calcaneus	Tibial nerve	Plantar flexion of foot
Plantaris	Inferior part of lateral supracondylar line of femur and oblique popliteal ligament of knee	Posterior surface of calcaneus	Tibial nerve	Plantar flexion of foot
Soleus	Medial border of tibia, posterior aspect of fibula	Posterior surface of calcaneus	Tibial nerve	Plantar flexion of foot

Table 1: Superficial group of muscles in the posterior compartment of leg (Drake, 2009)

Muscle	Origin	Insertion	Innervation	Action
Popliteus	Posterior surface of proximal tibia	Lateral femoral condyle	Tibial nerve	Unlocks knee joint (lateral rotation of femur
Flexor hallucis Longus	Posterior surface of fibula	Plantar surface of distal phalanx of great toe	Tibial nerve	Flexes great toe
Flexor digitorum longus	Posterior surface of tibia	Plantar surfaces of the distal surfaces of the lateral four toes	Tibial nerve	Flexes lateral four toes
Tibialis posterior	Posterior surfaces of interosseous membrane	Tuberosity of navicular	Tibial nerve	Inversion and plantarflexion of foot
Popliteus	Posterior surface of proximal tibia	Lateral femoral condyle	Tibial nerve	Unlocks knee joint (lateral

				rotation of femur

Table 2: Deep group of muscles in the posterior compartment of leg (Drake, 2009)

The function of both muscles located in the lateral compartment is the eversion of the foot (turn the sole outwards).

Muscle	**Origin**	**Insertion**	**Innervation**	**Action**
Fibularis longus	Upper lateral surface of fibula and lateral tibial condyle	Distal end of medial cuneiform and base of metatarsal I	Sperficial fibular	Eversion and plantarflexion of the foot
Fibularis brevis	Lower two-thirds of lateral surface of shaft of fibula	Lateral tubercle at base of metatarsal V	Superficial fibular	Eversion of foot

Table 3: Muscles of the lateral compartment of leg (Drake, 2009)

The muscles located on the anterior compartment of leg consist of four muscles and their responsible function is to dorsiflex the foot, extend the toes and invert the foot.

Muscle	**Origin**	**Insertion**	**Innervation**	**Action**
Tibialis anterior	Lateral surface of tibia	Medial and inferior surfaces of medial	Deep fibular	Dorsiflaxion and inversion of foot

		cuneiform		
Extensor hallucis longus	Middle-one half of medial surface of fibula	Dorsal surface of distal phalanx of great toe	Deep fibular	Extension of great toe, dorsal flexion of foot
Extensor digitorum longus	Proximal-one half of medial surface of fibula	Bases of distal and middle phalanges of lateral four toes	Deep fibular	Extension of lateral four toes, dorsal flexion of foot
Fibularis Tertius	Distal part of medial surface of fibula	Dorsomedial surface of base of metatarsal V	Deep fibular	Dorsiflexion and eversion of foot

Table 4: Muscles of the anterior compartment of leg (Drake, 2009)

The extensor digitorum brevis is the only muscle located in the dorsal aspect of the foot.

Muscle	**Origin**	**Insertion**	**Innervation**	**Action**
Extensor digitorum brevis	Superolateral surface of the calcaneus	Base of proximal phalanx of great toe	Deep fibular	Extension of metatarsophalangeal joint of great toe and flexion of toes II to IV

Table 5: Muscle of the dorsal aspect of the foot (Drake, 2009)

In the sole aspect of the foot the muscles are organized into four layers with the first layer situated superficially and the fourth most deep.

The first layer is immediately under the plantar aponeurosis and is composed of three components.

Muscle	Origin	Insertion	Innervation	Action
Abductor hallucis	Medial process of calcaneal tuberosity	Medial side of base of proximal phalanx of great toe	Medial plantar nerve from the tibial nerve	Abducts and flexes great toe at metatarsophalangeal joint
Flexor digitorum brevis	Medial process of calcaneal tuberosity and plantar aponeurosis	Middle phalanges of lateral four toes	Medial plantar nerve from the tibial nerve	Flexes lateral four toes at proximal interphalangeal joint
Abductor digiti minimi	Lateral and medial processes of calcaneal tuberosity	Lateral side of base of proximal phalanx of little toe	Lateral plantar nerve from tibial nerve	Abducts little toe at the metatarsophalangeal joint

Table 6: First muscle layer in the sole of the foot (Drake, 2009)

The second layer of muscles positioned in the sole aspect of the foot is related with the tendon of flexor digitorum longus muscle, which pass through this layer.

Muscle	Origin	Insertion	Innervation	Action
Quadratus plantae	Medial surface of calcaneus	Lateral side of tendon of flexor	Lateral plantar nerve from tibial nerve	Assist flexor digitorum longus tendon

	and lateral process of calcaneal tuberosity	digitorum longus		
Lumbricals	First lumbrical- medial side of tendon of flexor digitorum longus II,III,IV- adjacent surfaces of flexor digitorum longus	Medial free margins of extensor hoods of toes II to V	First lumbrical- plantar nerve from the tibial nerve II,III,IV- lateral plantar nerve from the tibial nerve	Flexion of metatarsophalangeal joint and extension of interphalangeal joints

Table 7: Second layer of muscles in the sole of the foot (Drake, 2009)

Concerning the third layer of muscles there are three muscles organized in that. The two of those are associated with the big toe and the other one with the fifth toe.

Muscle	**Origin**	**Insertion**	**Innervation**	**Action**
Flexor hallucis brevis	Plantar surface of cuboid and lateral cuneiform	Lateral and medial sides of proximal phalanx of the great toe	Medial plantar nerve from tibial nerve	Flexes metatarsophalangeal joint of great toe
Adductor	Transverse head-	Lateral	Lateral	Adducts great toe

hallucis	ligaments associated with metatarsophalangeal joints of lateral three toes, Oblique head-bases of metatarsals II to IV	side of base of proximal phalanx of great toe	plantar nerve from tibial nerve	
Flexor digiti minimi brevis	Base of metatarsal V	Lateral side of base of proximal phalanx of great toe	Lateral plantar nerve from tibial nerve	Flexes little toe at metatarsophalangeal joint

Table 8: Third layer of muscles in the sole of the foot (Drake, 2009)

The fourth layer, which is the last one and the deepest as well it, consist of two muscle groups.

Muscle	**Origin**	**Insertion**	**Innervation**	**Action**
Dorsal interossei	Sides of adjacent metatarsals	Dorsal expansions and bases of proximal phalanges of toes II to IV	Lateral plantar nerve from tibial nerve	Abduction of toes II to IV at metatarsophalangeal joints
Plantar interossei	Medial sides of metatarsals of toes	Dorsal expansions and bases of proximal phalanges of toes III to V	Lateral plantar nerve from tibial nerve	Adduction of toes III to V at metatarsophalangeal joints

Table 9: Fourth layer of muscles in the sole of the foot (Drake, 2009)

2.1.5. Innervation concerning the ankle joint

The nerves innervating the lower leg are divided into three groups. Furthermore the foot is supplied by the tibial, deep fibular, superficial fibular, sural and saphenous nerves.

Concerning the posterior compartment the associated nerve is the tibial nerve. Tibial nerve is a major branch of sciatic nerve that descends into the posterior compartment from the popliteal fossa. In the leg the tibial nerve gives rise to two cutaneous branches the sural nerve and medial calcaneal nerve.

The nerve associated with the lateral compartment of the lower leg is the superficial fibular nerve. This nerve originates as one of the major branches of the common fibular nerve, which enters the lateral compartment of the lower leg from the popliteal fossa. The common fibular nerve originates from the sciatic nerve.

Regarding the innervation of the anterior compartment of the lower leg associated nerve is the deep fibular nerve, the other major branch of the common fibular nerve, which passes anteromedially through the intermuscular septum into the anterior compartment of the lower leg, which it supplies. (Drake, 2009)

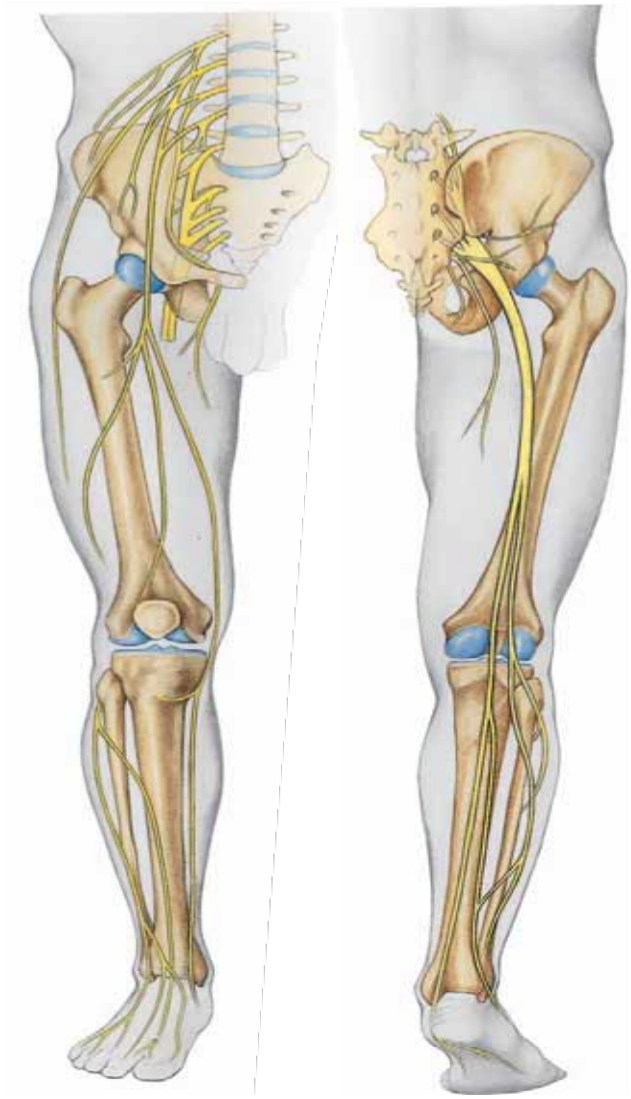

Figure 4: The nerves on the anterior and posterior aspect of the lower extremities (Clemente, 2006)

2.1.6. Blood supply related to ankle

The popliteal artery is the major blood supply to the leg and foot and enters the posterior compartment of the leg from the popliteal fossa behind the knee. As it continues inferiorly and enters the deep region of the posterior compartment of the leg, it immediately divides into an anterior tibial artery and posterior tibial artery.

The anterior tibial artery supplies the anterior compartment of the lower leg. The posterior tibial artery supplies the posterior and lateral compartments of the leg.

Additionally the anterior tibial artery gives rise to an anterior medial malleolar artery and an anterior lateral malleolar artery, which pass posteriorly around the distal ends of tibia and fibula. More over the posterior tibial artery has two major branches the circumflex fibular artery, which passes laterally through the soleus muscle, and the fibular artery, which passes, along the lateral side of the posterior compartment.

Concerning the veins generally they follow the arteries.

Blood supply to the foot is by branches of the posterior tibial artery and dorsalis pedis artery. The lateral plantar artery joins with the terminal end of the dorsalis pedis artery to form the deep plantar arch which branches of this supply the toes. The medial plantar artery supplies a deep branch to adjacent muscles. It ends by joining the digital branch of the deep plantar arch, which supplies the medial side of the great toe.

There are interconnected networks of deep and superficial veins in the foot. The deep veins follow the arteries whereas the superficial veins drain into a dorsal venous arch on the dorsal surface of the foot over the metatarsals. The great saphenous vein originates from the medial side of the arch and the small saphenous vein originates from the lateral side of the arch. (Drake, 2009)

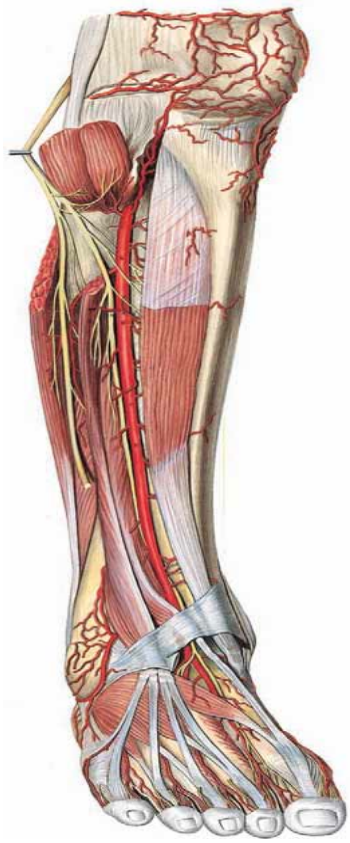

Figure 5: Deep Dissection of the Anterior and Lateral Compartments: Nerves and Arteries (Clemente, 2006)

2.2. Kinesiology of ankle joint

The ankle joint is a ginglymus or hinge joint uniting the tibia and fibula with the talus. The axis about which motion takes place extends obliquely from the postero-lateral aspect of the fibular malleolus to the anteromedial aspect of the tibial malleolus.

Flexion and extension are the two movements that occur about the oblique axis. Flexion is movement of the foot in which the plantar surface moves in a caudal and posterior direction. Extension is movement of the foot in which the dorsal surface moves in an anterior and cranial direction.

Confusion has arisen regarding the terminology of these two ankle joint movements. An apparent discrepancy occurs because decreasing an angle frequently is associated with flexion whereas increasing it is associated with extension.

Bringing the foot upward to "bend the ankle" seems to connote flexion; pointing the foot downward to "straighten the ankle" connotes extension. (In a review of 48 authors, 12 of them had the wrong definitions for ankle flexion and extension.) To avoid confusion, use of the terms dorsiflexion for extension and plantar flexion for flexion has been widely accepted. (Kendall et al, 20013)

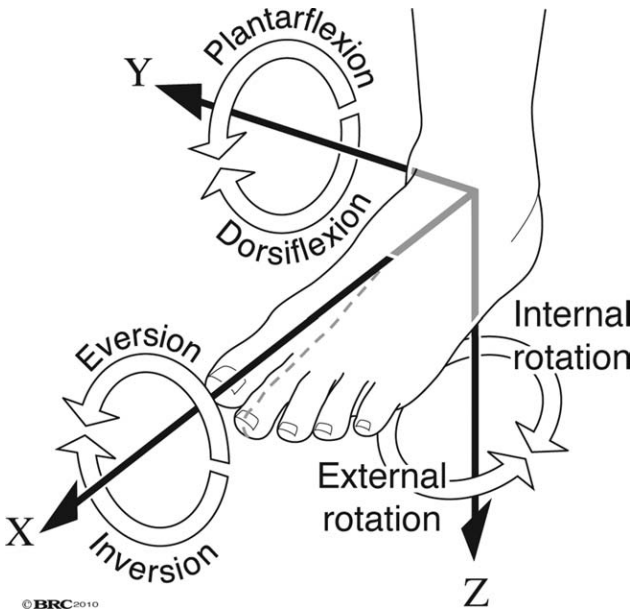

Figure 6: Terminology used to describe the motion of the foot with respect to the leg. (Funk, 2011)

2.3. Biomechanics of ankle joint

What is commonly referred to as the ankle actually consists of two joints: the tibiotalar joint, often called the ankle joint, and the talocalcaneal joint, often called the subtalar joint.

Ankle joint motion is primarily responsible for dorsiflexion and plantar flexion, whereas subtalar joint motion is primarily responsible for inversion and eversion. Internal and external rotation involves roughly equal contributions from the ankle and subtalar joints. Inversion and internal rotation are strongly coupled to each other and weakly coupled to plantar flexion.

Likewise, eversion and external rotation are strongly coupled to each other and weakly coupled to dorsiflexion. Forced rotation about any one of these axes induces rotation about the other two-coupled axes during normal, unconstrained motion of the foot/ankle complex.

Injury, however, typically occurs because the motion of the foot relative to the leg is constrained and abnormal. (Funk, 2011)

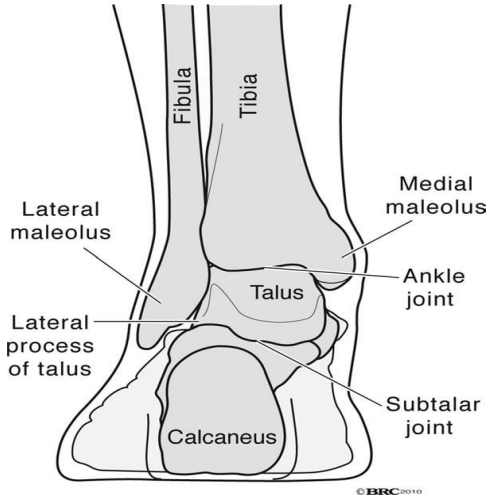

Figure 7: Bony anatomy of the hind foot and ankle (Funk, 2011)

During activities of daily living, the ankle functions under load. In response, ligaments stretch or slacken and articular surfaces in contact indent.

The movements of the calcaneus, talus and fibula relative to the stationary tibia in lower-leg preparations were tracked with a stereo photogrammetric system. It was shown that for each individual specimen, the calcaneus follows a unique path of non-resisted coupled motion relative to the tibia and that most of this motion occurred at the ankle, with little motion at the subtalar level. The CaFi and the TiCa ligaments showed near-isometric pattern of rotations about their origins and insertions, whereas posterior ligaments slackened during plantar flexion and anterior ligaments slackened during dorsiflexion. In other words, during virtually unloaded joint movement, there are ligament fibres that maintain constant length throughout movement, and this must guide joint mobility, and others that tighten to define only the extremes of this movement.

More recent studies have reported that the instantaneous axis of rotation translates and rotates during passive dorsal plantar flexion, suggesting that the hinge joint concept is an oversimplification. A few recent works have also demonstrated an associated shift of the contact area during flexion not only at the trochlea tali but also at the tibial mortise. (Leardini et al, 2014)

Among the lateral ligaments, the ATFL is the weakest as it has the lowest ultimate load, approximately 138.9N, which is about half of that of PTFL, that is, 261.2N, and one-third of that of CaFi, that is, 345.7N. Due to its low ultimate load and the anatomical positions of origins and insertions, the ATFL is most commonly injured in a lateral ankle sprain. (Fong et al, 2009)

2.3.1. Biomechanical malposition of athlete's foot

According to studies that were conducted regarding the positioning of athletes feet concluded that two types of malposition exist, the forefoot varus and the forefoot valgus. Both situations are consider abnormal as they eliminate the shock absorb function of the foot.

The term 'forefoot varus' means the non-weight bearing varus position of the forefoot (the great toe and first metatarsal have risen up) while the talus and calcaneus have been placed in neutral position (that is, perpendicular to the tibia). In a normal foot, all the toes and metatarsals remain in contact with the floor. When the body weight is borne so that all toes have contact with the floor, the forefoot varus leg shows excessive (compensatory) calcaneal valgus (eversion) and the tibia rotates internally. In other words, the system shows ankle hyper pronation, which can be corrected by orthotics with a medial wedge.

In the 'forefoot valgus' malposition, the little toe and fifth metatarsal bone rise up when (under non-weight bearing) the talus and calcaneus are placed in neutral position. Under weight bearing there occurs an excessive (compensatory) calcaneal varus (inversion) and the tibia rotates externally. In other words, the system shows ankle hyper supination. (Kannus, 1992)

2.3.2. Common foot disorders

Pronation and supination are important in determining whether the foot will behave as a flexible or rigid structure during the gait cycle. When the foot meets the ground, pronation is produced by simultaneously everts the calcaneus then adducting and plantar flexing the talus while supination occurs through the opposite movement of calcaneal inversion.

The common foot abnormalities consider being flat feet, neuromuscular disorders, metatarsalgia, tendonitis and plantar fasciitis. (Nicolopoulos et al, 2000)

2.4. Ankle distortions and ankle sprains

Ankle sprain also known as ankle distortion, twist ankle, rolled ankle and floppy ankle referred to a common medical condition where one or more ligaments of the ankle is partially or completely torn.

Among recurrent injuries, the ankle is also the most common site and many individuals will go on to develop residual problems, such as pain and recurrent bouts of instability. The recurrent nature of these injuries increases the likelihood of decrease physical activity. It has been estimated that one out of three individuals who suffer an ankle sprain will go on to have recurrent issues. (McKeon et al, 2014)

2.4.1. Grades of ankle sprains

An ankle distortion or ankle sprain with damage to the lateral ankle ligaments represents the most common musculoskeletal injury and represents the most frequently observed injury in the emergency room. (Audenaert, 2010)

There exists three grades of ankle sprains, a grade I ankle sprain involves a mild sprain of the anterior talofibular ligament with a negative ankle drawer and talar tilt test. A grade II sprain involves disruption of the anterior talofibular with sprain of the calcaneofibular, with positive ankle drawer and negative talar tilt test, whereas a grade III ankle sprain involves disruption of the lateral ligament complex with both positive ankle drawer and talar tilt tests.

The clinician must take a careful evaluation of an individuals ankle sprain to determine if there present any fracture. For that the Ottawa ankle rules have been used to determine when radiologic assessment is necessary in the face of inversion ankle injuries. Some positive indicators for testing include difficulty bearing weight and tenderness about the medial or lateral malleolus or fifth metatarsal. (DeLisa et al, 2005)

2.4.2. Epidemiology

Ankle sprain is one of the most common musculoskeletal injuries, representing 10-15 % of all sports injuries. It is consider a minor trauma but, according to many authors, 6-18 months after the injury, 72% of examined patients still show recurring symptoms and repeated lateral ankle sprains. (Stecco et al, 2011)

Ankle injuries are common. In athletes, the lateral ligament complex of the ankle is the single most injured structure in the body. This dramatic statistic is due to the fact that the vast majority (85%) of ankle injuries are sprains, and the vast majority (85%) of ankle sprains involve the lateral ligament complex. Many of these lateral ligament sprains involve additional injuries to other soft tissue structures. In severe sprains, avulsion fractures of the lateral malleolus are common in children and in adults over 40 years old. (Funk, 2011)

2.4.3. Clinical image

Soft tissue injuries commonly elicit the physiological inflammatory responses of redness, swelling, heat and pain, ankle sprain injuries are no exception. Edema formation is a significant hindrance to the healing process and can cause pain and reduce mobility. (Man et al, 2007)

2.4.4. Posttraumatic treatment

Treatment of the ankle sprains is usually accomplished in phases. Phase I consists of a common acronym PRICE (Protection, Rest, Ice Compression, Elevation) or PRINCE (Protection, Rest, Ice, Non-steroidal anti-inflammatory drugs, Compression, Elevation) used in treatment of ankle sprains which are very important. The ankle should be protected from further injury and rested for the first 2-3 days. Icing should be instituted during the first days following the injury. Application of ice for 15-20 min every 1-2 hours helps with pain relief and swelling. NSAIDS are helpful in pain control. Ibuprofen 600mg every 6 hours for a week is commonly used as long as the patient has no history of gastric ulcers. Compression wraps can be used initially to control swelling and pain. Elevation of the ankle above the level of the heart helps with swelling.

The phase II of ankle injury treatment usually occurs 2-3 days after the injury. Ankle ligaments heal stronger when healing in the presence of a gentle load, thus early weight bearing is encouraged early. Physical therapy is essential in recovery with ROM, resistance exercises and proprioceptive ankle training. Proprioceptive, agility and endurance training are included one the patient reaches about 80% of his baseline ankle strength. In severe ankle sprains the recovery program may take up to 8 weeks. In minor sprains it may take 1 or 2 weeks. (Small, 2009)

2.4.5. Indication of ankle sprain surgery

Ankle sprains mostly require auto therapy (P.R.I.C.E) and physical therapy (a combination of exercises and electrotherapy) for its complete recovery. In contrast to these conditions, a complete rupture of ligament structures around the ankle require an operative repair or joint arthroscopy.

2.4.6. Examination procedures

2.4.6.1. Physician's diagnostics examination

The physician evaluation is essential to be performed prior to any kind of treatment, differentiating an ankle sprain from a fracture. Identifying any hematoma, joint deformity and swelling is critical. Additionally a palpation examination follows to determine which structures are injured. Range of motion in all directions follows to find out in which level the restrictions are. This examination is performed actively and passively in the order I mentioned them. Finally the physician will provide a series of tests before instruct the patient to undertake further imaging method examinations as Talar tilt, Anterior Drawer, External rotation (Kleiger's test), Thompson's test and Compression test.

2.4.6.2. Imaging methods

X-rays is a suitable and effective technique in order to obtain pictures that can be evaluated for functional limitations. After the tests that the physician will apply then x-rays should performed in order to find out whether there is a fracture of a bony structure. The negative of this technique is that only bones are presented on the picture. (Lewit, 2009)

Magnetic resonance imaging (MRI) has been shown to be highly sensitive and specific to injuries of the distal tibiofibular ligaments, and it has demonstrated excellent agreement among raters. Moreover, MRI provides insight into the extent of ankle injury and helps to identify concomitant injuries to other structures in the region. (Glenn et al, 2010)

2.5. Physiotherapists examinations

The physiotherapists are essential that adheres to the protocol examinations, and obtain important information, which will allow to the further appropriate progress of the therapy.

2.5.1. Anamnesis

The medical history of the patient is extremely important as it will guide the therapy in the correct track and moreover prevent any inappropriate application of modalities that will lead to undesirable effects. The physical therapist must work on a professional level but on the other hand should be friendly as it will make the procedure of the anamnesis more pleasant for the patient and more important the patient while feeling good he/she will be more open to discussion, eliminating the chances of missing any important information.

Moreover the physiotherapist should observe during the history examination the patient's body language, attitude and social awareness. (Cemusova, 2011)

2.5.2. Posture examination

The posture examination is executed to examine the patient's overall structure of his/her body. This examination is performed in three views, the anterior (front), posterior (behind) and lateral (side). During the anterior view the therapist observe the position of the toes, appearance of the longitudinal arch, alignment in regard to pronation or supination of the foot, the position of patella, knocked knees or bowlegs and any rotation of the head or abnormal appearance of the ribs. During the lateral view the therapist should observe from both sides left and right for detecting any rotation faults. During the posterior view the physiotherapist should note the alignment of the tendo-calcaneus, postural adduction or abduction of the hips, the posterior iliac spines height, lateral pelvic tilt, lateral deviations of the spine and the position of shoulders and both scapula. (Kendal et al, 2013)

2.5.3. Anthropometric measurements

In this examination procedure the physiotherapist measure the length, the height and the circumference of the whole upper and lower extremity. Additionally all these measurements should be taken in a relaxed position (lying or sitting for the upper extremity).

The measuring tape is placed on the skin where particular points of the skeleton are projected. Moreover circumference measurements of the head, thorax waist and hips are performed.

2.5.4. Mobility of Segment (Dynamic test)

In case of an altered position of the pelvis, the spinal curves have to be observed as well as the function of the whole spine. The patient by doing the test, Flexes of the whole trunk, expresses the flexibility of the whole spine and shows if scoliosis is present. (Jalovcova, 2011)

2.5.5. Two scales test

This test is performed in conditions where patients cannot completely load their lower extremities and the therapist by that examination can determine the percentage of loading. An optimal deference of weight bearing between both lower extremities for the total body weight considers being a percentage of 10-15 %. The test is performed with the patient standing on two different scales with one leg on each scale.

2.5.6. Special test

In the case of the ankle sprain it is important determining the stability of the ankle joint, as it is typical patients after that kind of injuries suffering from instability.

The Vele foot test is a special test that describes the stability condition of the ankle joint. It is divided in four grades with grade I being the normal (physiological) and grade IV consider serious stability disorder.

A - norm

Digits slightly touch the pad it is possible to insert a sheet of paper between the fingers and foot with ease.

B - slight deviation

Slight posture deficiency, digits are pressed against the pad and paper is difficult to insert/retrieve.

C - bad alignment

Claw-like positioning, fingers are heavily pressed against the pad, paper is impossible to insert/retrieve.

D - serious stability disorder

Foot posture change, deformity, pathology, claw-like stance.

2.5.7. Gait examination

Significant is the examination of walking (gait). Throughout the particular examination the patient must be without clothes and shoes allowing the physiotherapist to distinguish any structural abnormalities as well as the walking rhythm (periodic, non-periodic), walking speed and distance, length of steps, axial position of the lower limb, ground motion of the feet, movement of center of gravity and movements of the hands. The gait examination is performed in nine ways, forward, backward, with hands overhead, on heels, on toes, ascending, descending, with crutches and with eyes closed. (Jelinkova, 2012)

2.5.8. Basic movement patterns

The concept of basic movement pattern examination is to evaluate the quality of movements and the sequence of muscle activation. The principles to demonstrate this examination are, slow movement as a high level of coordination is needed, the therapist shouldn't guide or correct any movement during the active phase and no contact should be performed, as it will result to facilitate the muscles. Reasons that may cause a pathological movement are a defensive mechanism to an irritation or bad lifestyle habits. (Janda, 1983)

2.5.9. Soft tissue examination

This examination is performed with waving techniques and hold to relaxation techniques toward the restricted directions. The aim of soft tissue examination for the physiotherapist is to determine whether there exist any restriction on the skin, sub-skin and fascia. (Lewit, 2009)

2.5.10. Range of motion examination

The range of motion is crucial for distinguish the severity of ones limitation but on the other hand is important for practically demonstrate the improvement throughout a rehabilitation plan. The measures are done with an instrument called goniometer. The physiotherapist should always use the same goniometer eliminating the chances of mistake measurements. Moreover the measurements should be performed on both active and passive movements. (Jelinkova, 2012)

2.5.11. Muscle strength test

In muscle testing, weakness must be distinguished from restriction of range of motion. Frequently a muscle cannot complete the normal range of motion. It may be that the muscle is too weak to complete the movement or it may be that the range of motion is restricted because of shortness of the muscle, capsule or ligament. The examiner should passively carry the part through the range of motion to determine whether any restriction exists. If no restriction is present then failure by the subject to hold the test position may be interpreted as weakness unless joint or tendon laxity is present.

The basic rules of procedure that apply to muscle strength testing are. Place the subject in a position that offers the best fixation of the body as a whole. Stabilize the part proximal to the tested part or as in the case of the hand, adjacent to the tested part. Stabilization is necessary for specificity in testing. Place the part to be tested in precise antigravity test position whenever appropriate to help elicit the desired muscle action and aid in grading. Use test movements in the horizontal plane when testing muscles that are too weak to function against gravity. Apply pressure directly opposite the line of pull of the muscle or the muscle segment being tested.

Apply pressure gradually but not too slowly, allowing the subject to get set and hold. Use a long lever whenever possible, unless contraindicated.

The grading system as it was described from Robert Lovett includes six grades. Gone- no contraction, Trace- muscle can be felt to tighten but cannot produce movement, Poor- produces movement with gravity eliminated (no function against gravity, Fair- can move against gravity, Good- can raise the part against outside resistance, Normal- can overcome a greater amount of resistance than a Good muscle. (Kendall et al, 2013)

2.5.12. Muscle length test

Muscle length test are performed to determine whether the range of muscle length is normal, limited or excessive. Muscles that are excessive in length are usually weak and allow adaptive shortening of opposing muscles. Muscle length testing consist of movements that increase the distance between origin and insertion, thereby elongating muscles in directions opposite those of the muscle actions. (Kendall et al, 2013)

2.5.13. Muscle tone

The importance of palpation is remarkable in the diagnosis of painful structures of the locomotor system and essential for all manipulative techniques. This examination therefore follows next, immediately after the inspection.

The first step in palpation is to place a hand onto the surface of the patient's body and then to focus one's attention on the aspect to be tested: warmth, moisture, consistency (rough or smooth surface), mechanical properties (resistance, mobility, stretch capacity) and whether the examination causes the patient to feel pain. (Lewit, 2009)

2.5.14. Joint play examination

The objective of manipulation (joint play) is to restore the normal mobility of joints. There exist two types of manipulation: mobilization and thrust techniques. Important in manipulation is the correct positioning of the patient and the practitioner, the appropriate fixation and taking up the slack (engaging the barrier). By examining and comparing the joint play movements between the two sides, the therapist is able to distinguish whether there is a blockage or not in the target joint. (Lewit, 2009)

2.6. Rehabilitation plan for ankle distortion according Lind (non-operative protocol)

This protocol refers to a general therapeutic approach in treating an ankle distortion grade II and I. It is a non-operative course of treatment used at the Rosenberg orthopedic clinic in the U.S regarding the mainstream of favorable results.

2.6.1. Phase I – Maximum Protection (weeks 0-1)

Ice and modalities to reduce pain and inflammation
Compression wrap to reduce swelling
Crutches as instructed
Elevate the ankle above the heart
Begin active range of motion all planes as directed by physician
Stationary bike/non-impact and pool program

2.6.2. Phase II – Progressive Range of Motion and Early Strengthening (weeks 1-2)

Continue with modalities to reduce swelling and control pain
Wean off crutches as instructed
Continue with active range of motion with light terminal stretching
Begin 4 plane ankle TB
Foot intrinsic strengthening
Begin closed chain progression bilateral exercises (squats, calf raises, toe raises)
Proprioception drills

Bike, elliptical, treadmill walking

May begin shallow water pool jogging

2.6.3. Phase III – Progressive Strengthening (weeks 2-3)

Continue with modalities to reduce swelling

Restore full range of motion all planes

Continue with open and closed chain ankle and foot intrinsic strengthening

Progress difficulty of proprioception drills

Begin straight plane dry land running

Begin controlled lateral agility work

2.6.4. Phase IV – Advanced Strengthening – Return to Sports (weeks 3-6)

Continue with modalities as needed

Continue with end range stretching

Progress strengthening and proprioception

Advance to sprinting and agility drills or tape

Simulate return to sport activity with field or court drills

Must demonstrate a negative clinical exam and pass a strength and agility test with greater than 90% efficiency for physician release

(Lind, 2013)

2.6.5. Therapeutic approach concerning ankle distortion

Therapeutic approaches vary depending on the understanding of every individual physiotherapist. In contrast to that the main idea remains the same, which is the elimination of pain, regain the physiological range of motion decrease any swelling and after all the ability of the patient to return to his/ her daily life without any restrictions.

To achieve that, there exist a series of modalities that I will focus on. These therapeutic procedures are the manual therapy which is essential in terms of unblock any restricted joints, sensomotiric training for acquiring new skills as for correct and maintaining faulty posture, P.N.F (Proprioceptive Neuromuscular Facilitation) as a way for strengthening, kinesiotaping for improving the stability and provide a feeling of a stronger joint to the patient. From the physical therapy spectrum we can include H.V.P.C (High Voltage Pulsed Current) for pain relief and facilitation of edema resolution, TENS for relief from pain, Acupuncture for reducing swelling and pain, S.W.D (Short Wave Diathermy) and P.S.W.D (Pulsed Short Wave Diathermy).

Cryotherapy is a therapeutic resource that temporarily reduces spasticity symptoms. it lowers the stretch sensitivity of neuromuscular spindles, by reducing intrafusial fiber activity in the gamma system, which leads to decrease of nerve conduction velocity.

It can either by local or global application, and it is subzero temperatures. In general, cryotherapy is good to use for inflammations, decreasing of pain and spasms. The TENS mechanisms of action are based on the hypothesis that it provokes an additional sensory input in the central nervous system, causing presynaptic inhibition of the suprasegmental pathways. The frequency can be of 100 Hz.

Thermotherapy optimizes sensory and motor function recovery in hemiplegic stroke patients. It results in an increase in molecular vibration and cellular metabolic rate. This form of treatment is divided into two categories, namely superficial and deep heating modalities. These are further divided into chemical, electric, or magnetic. Temperatures range from 41°C to 77°C. from thermotherapy, hot packs are most suitable for patients with stroke. These packs can be placed on the muscles affected by spasticity, which is flexors of upper extremity, and extensors of lower extremity.

3. Special Part (Case Study)

3.1. Methodology

The clinical practice took place at C.L.P.A (Centrum léčby pohybového aparátu) clinic. The practice was for two weeks from 3rd of February 2014 until 14th of February 2014. It was an eight hours timetable daily with a total of eighty hours for the whole two weeks practice.

During my clinical practice I was under the supervision of Mgr. Zaher el Ali. The diagnosis of my patient was an ankle distortion. I had eight sessions with my patient scheduled on the same time, starting from 3rd of February where I also performed the initial kinesiology examinations. The final kinesiology examinations were performed during our last physiotherapeutic session on 14th of February.

The physiotherapeutic sessions took place in the individual therapy rooms as well at the gym room. Mainly I used my hands for the examinations and therapy. In addition, the instruments that I used for the examinations were scale, goniometer tape and neurologic hammer. Moreover during the therapeutic procedures that took place mostly at the gym room I used the following instruments, overball, posturomed device, bosu ball, wobble board, swiss ball, thera-band and laser device with point application.

I would like also to mention that my patient and I signed an acquiescence form. In addition my clinical practice was approved from the Ethics Committee of the Faculty of Physical Education and Sport at Charles University, with the approval number 095/2014. Moreover there is a copy included in my thesis of this form.

3.2. Anamnesis

Patient: A.K, 18 years old, (male)

Diagnosis: Ankle Distortion (Left L.E)

Code: S93.40

3.2.1. Present State

Height: 1.87cm

Weight: 100kg

BMI: 28.6

Pain level: 4/10 (during walking upstairs), 3/10 (when standing for long time) in scale from 1 as minimum to 10 as maximum

The patient feels pain on his ankle during walking especially on stairs mostly on the anterolateral region. As a result of his pain he cannot attaint his hockey training sessions.

The reason that the patient visited the rehabilitation department is because he has irritations on his left ankle. During a hockey competition on 31st of January he powerfully crushed with an opponent resulting to twist his ankle inside the skates. He felt a little pain but he continued until the end of the competition. When he went home he felt a little irritation and he applied ice. The next day he observed little swelling so he visited the doctor for examination. The doctor after assess the patient he concluded that he had an ankle distortion (grade 1). Finally, I would like also to mention that the patient is in good mood and looking forward to be able to play hockey again with his team.

3.2.2. Personal Anamnesis

The patient did not have any similar injury before. Moreover the patient has had all common childhood diseases.

3.2.3. Family Anamnesis

He has one younger sister. All family members are healthy.

3.2.4. Operation Anamnesis

He had no operations.

3.2.5. Medication

He does not take any medications.

3.2.6. Allergy Anamnesis

The patient does not suffer from any allergies

3.2.7. Social Anamnesis

The patient is in a relationship and he lives in a house with his family.

3.2.8. Occupation Anamnesis

He is a student of Lyceum, third grade. He is in sitting position for many hours as a student so this will be positive for the rehabilitation process.

3.2.9. Hobbies

He plays hockey for 12 years. Furthermore he likes watching television and playing videogames. Apart from hockey he likes very much going for skiing.

3.2.10. Abuses

The patient occasionally drinks alcohol, when he is with friends.

3.2.11. Previous Rehabilitation

He had no previous rehabilitation but he did have massage sessions especially after competitions.

3.2.12. Statement from the patient's medical documentation

The patient had X-rays for his left ankle but I did not seem them.

3.2.13. Indication of rehabilitation

Decrease the swelling

Improve P.F, D.F, E and I, of left ankle joint

Laser therapy

Strengthening and sensomotoric stimulation exercises for both L.Es

3.2.14. Differential Diagnosis

The patient feels pain on his left ankle that causes a restriction of movement. It is not a severe pain but it limits his daily activities. The pain probably arises from the overstretched ligaments around the joint but also there could be other factors causing that such as muscle imbalance and trigger points.

3.3. Initial Kinesiology Examination

3.3.1. Posture evaluation in standing

Feet distance	Feet close to each other
Transverse arch	Collapse on both feet
Longitudinal arch	Physiological
Calf	Symmetrical
Knee Patella	Physiological position on both L.E External rotation: negative Internal rotation: negative
Thigh contour	Symmetrical in both sides
Anterior superior iliac spines	On the same level
Umbilicus	No deviations
Sternum	Middle line
Nipples	Symmetrical
Hands	Slight pronation and flexed on both U.E
Clavicles	Symmetrical
Shoulders	Slightly protracted
Head position	Physiological
Weight bearing	He shifts his weight more on right side

Table 10: Initial postural examination- Anterior view

Ankle joint	Slight dorsal flexion on both L.E
Knee joint	Straight line
Pelvis position	Slight anteflexion
Lumbar region of spine	Slight hyperlordosis
Thoracic region of spine	Physiological kyphosis
Shoulder position	Slight protraction of both shoulders
Cervical region of spine	Slight straightening
Head position	Slight protraction

Table 11: Initial postural examination- Lateral View

Heels position	Symmetrical
Achilles tendon	Predominance on both L.E
Calf	Symmetrical
Popliteal lines	Symmetrical
Subgluteal lines	Symmetrical
Iliac crests	On the same level
Posterior superior iliac spines	Symmetrical
Scapulas	On the same level
Upper extremities	Slight pronation
Shoulders	Slight protraction
Head position	Physiological

Table 12: Initial postural examination- Posterior View

Conclusion of posture evaluation

According to the anterior view (Table 1) both transverse arches are collapsed because of the nature of his sport activity that demands to wear the skates for long period of time. Furthermore the patient's Achilles tendons are prominent as a result of the skates. Calf and thigh are symmetrical on both sides. Hands are in slight pronated position and flexed, shoulders are slight protracted which indicates the tension that the flexor muscles of upper body such as pectoralis, biceps brachii, sternocleidomastoid, scalene in contrast to the elongation of extensor muscles such as trapezius, latissimus dorsi, triceps brachi. Moreover there was a general shifting of body weight towards right side because of the pain. According to the lateral view (Table 2) the ankles are in dorsal flexion position which indicates the tightness of dorsal flexor muscles such as tibialis anterior, extensor digitorum longus and peroneus tertius. Moreover there was observed a pelvis anteflexion resulting to lumbar hyperlordosis. Both shoulders were slightly protracted as a result of pectoral muscle tightness and lastly head was in a slight protracted position. According to posterior view (Table 3) heels were in a symmetrical position with predominance of Achilles tendon on both sides. Calf muscles, popliteal and subgluteal lines were symmetrical. Iliac crests were on the same level as well as scapulas. Upper extremities were slight in pronated position. Additionally shoulders

were on a slight protracted position. Finally the patients head was on a physiological position.

Note: The patient is not able to fully load his left L.E.

3.3.2. Dynamic test (Mobility of segments)

Maximal extension: The patient is able to provide the movement in a physiological range of motion without any discomfort or pain.

Lateroflexion: The patient is able to provide the movement with no pain. He has little more range of motion towards the right side and the movement seems fluent. There is no restriction on left side or pain.

Maximal flexion: He is able to provide the movement with no pain. The range of motion of all vertebral segments distributed equally. The patient does not feel any discomfort or dizziness during the movement.

Conclusion of dynamic testing

During the dynamic testing I didn't find anything important concerning the diagnosis and the pain that my patient have. There was physiological mobility of the spine and good balance.

Note: The dynamic test is performed to indicate if there is any restriction between the spine segments or scoliosis as the patient cannot load fully his left L.E.

3.3.3. Special test

3.3.3.1. Vele test

Grade 3: Bad alignment

The patient had a claw-like positioning with toes heavily pressed on the floor, the paper was impossible to placed under the toes.

Conclusion of special test

The patient couldn't provide the grade 3 tests for stability of the ankle. From these findings I could conclude that the patient suffers from instability on his ankles.

3.3.4. Two scales test

Left	Right
45kg	55kg

Table 13: Initial two scales test

Conclusion of two-scale test

The two-scale test showed that the patient has a weight bearing discrepancy as a result of the injury and the inability of the patient to load completely his injured leg (left L.E)

3.3.5. Anthropometric measurement

3.3.5.1. Lower extremities Length – Circumferences

Left		Right
101cm	Anatomical length (ASIS)	101cm
111cm	Functional length (Umbilicus)	111cm
94cm	Length of thigh	94cm
47cm	Length of middle leg	47cm
25cm	Length of foot	25cm
50cm	Circumference of thigh (vastus medialis)	50cm
60cm	Circumference of thigh (quatriceps)	61cm
41cm	Circumference of knee	41cm
43cm	Circumference of calf	44cm
38cm	Circumference of ankle	36cm
27cm	Circumference of foot	27cm

Table 14: Lower extremities initial length and circumferences

Conclusion of anthropometric measurements

The only noticeable difference that my patient has in on the level of his ankle where a minor swelling on his left ankle due to the injury cause the difference of 2cm.

3.3.6. Gait examination

3.3.6.1. Forward walking

Step phase: Left step was smaller and faster than right

Stance phase: Physiological

Rolling of feet: Not fluent

Pelvis rotation: Limited

Trunk movements: Limited

Arm synkinesis: Physiological

3.3.6.2. Backward walking

Step phase: slight smaller step the left one, first contact point was the toes and last the heel

Stance phase: physiological

Rolling of feet: Not fluent

Pelvis rotation: Limited

Trunk movements: Limited

Arm synkinesis: Physiological

3.3.6.3. Walking on toes

The patient wasn't able to provide it as he was feeling pain on his left ankle.

3.3.6.4. Walking on heels

The patient could provide it with slight unbalanced posture. Was also slightly leaning forward. Moreover he felt a minor pain on his left ankle.

<u>Conclusion of gait examination</u>

The patient was performing a smaller and faster left step because of the pain. This pain also was limiting the motion of trunk region. I don't believe the reason of the limited motion of the trunk is caused by a joint blockage but is only an analgesic position.

3.3.7. Examination of basic movement patterns (according to Janda)

Extension of hip joint: Negative (both sides)

Movement: The patient performed the movement with the correct sequence of muscles activation. First gluteus maximus then hamstrings, contralateral spinal extensors muscles lumbar region, ipsilateral spinal extensors muscles lumbar region, contralateral spinal extensors muscles thoracic and lumbar region, ipsilateral spinal extensors muscles thoracic and lumbar region and last shoulder girdle muscles.

Abduction of hip joint: Positive (both sides tensor mechanism)

Movement: The movement that the patient performed wasn't a pure abduction of hip. Instead there was involved a slight flexion motion of hip. There was a primary activation of tensor fascia latae and then gluteus medius and minimus. This compensatory movement was observed in both sides.

Curl up (trunk flexion): Negative (both sides)

Movement: The patient had no problem to provide the sitting up position from supine. Furthermore the motion was smooth and a curling movement of the trunk was observed.

Conclusion of basic movement patterns

During the movement pattern examination there was observed an altered motion while providing the hip abduction movement. This led us to the hypothesis that tensor fascia latate probably is hyper tone and/or short while gluteus medius and minimus are hypo tone and/or elongated. Findings that will be assess on further examinations.

3.3.8. Range of motion examination (according to Kendall)

Hip Joint					
Right	**Active**	**Left**	**Right**	**Passive**	**Left**
-	**Hip joint**	-	-	**Hip joint**	-
20^0	Extension	20^0	25^0	Extension	25^0
95^0	Flexion	95^0	100^0	Flexion	100^0
45^0	Abduction	45^0	50^0	Abduction	50^0
16^0	Adduction	18^0	20^0	Adduction	22^0
30^0	Internal rotation	35^0	35^0	Internal rotation	39^0
45^0	External rotation	45^0	50^0	External rotation	50^0

Table 15: Initial examination of the ROM of Hip joint

Knee Joint					
Right	**Active**	**Left**	**Right**	**Passive**	**Left**
-	**Knee joint**	-	-	**Knee joint**	-
0^0	Extension	0^0	-5^0	Extension	-5^0
140^0	Flexion	140^0	150^0	Flexion	150^0

Table 16: Initial examination of the ROM of Knee joint

Ankle Joint					
Right	**Active**	**Left**	**Right**	**Passive**	**Left**
45^0	Plantar flexion	45^0	50^0	Plantar flexion	50^0
25^0	Dorsal flexion	20^0	30^0	Dorsal flexion	25^0
40^0	Inversion	40^0	45^0	Inversion	45^0
15^0	Eversion	10^0	20^0	Eversion	15^0

Table 17: Initial examination of ROM of Ankle joint

Conclusion of Goniometry examination

The goniometry examination indicated us with few important findings. Firstly there was a slight limitation of movement on hip flexion, which I strongly believe is based on hypertonic and/or short hamstrings. Probably there is a muscle misbalance between hip flexors and extensors. Furthermore there was a limitation on ankle dorsal flexion and eversion because of pain.

3.3.9. Muscle strength test (according to Kendall)

Lower extremities muscle strength test		
Right	**Muscle**	**Left**
5	Tibialis anterior	4
5	Extensor digitorum longus/brevis	4
5	Peroneus Tertius	3+
5	Tibialis posterior	4
5	Flexor digitorum longus	4
5	Peroneus longus	5
5	Peroneus brevis	5
5	Gastrocnemius	4
4	Soleus	5
5	Hamstrings	5
5	Quadriceps	5
4	Gluteus medius	4
4	Gluteus minimus	4
4	Iliopsoas	4
5	Tensor fasciae latae	5
5	Sartorius	5
5	Piriformis	5
5	Gluteus maximus	5
4	Hip adductors	5
5	Flexor hallucis longus	5
4	Flexor hallucis brevis	4
4+	Extensor hallucis longus	4

Table 18: Initial examination of both lower extremities muscle strength test

Conclusion of muscle strength test

Weakness was present on the muscles that act towards the dorsal flexion and eversion, (tibialis anterior, peroneus tertius, extensor digitorum longus). I believe there isn't a significant weakness but is pain that minimize the performance of the particular movements. The patient has a very good physic and as soon as the pain will be eliminated the movements will be performed without any difficulty.

3.3.10. Muscle length test (according to Janda)

Lower extremities muscle length test		
Right	**Muscle**	**Left**
0	Gastrocnemius/ Plantaris	0
0	Soleus	0
0	Hip adductors	0
0	Piriformis	0
0	Iliopsoas	0
1	Sartorius	1
1	Rectus femoris	1
1	Hamstrings	1
1	Tensor fasciae latae	1
0	Tibialis anterior	0

Table 19: Initial examination for both lower extremities muscles length test

Conclusion of muscle length examination

There was observed shortness on Rectus femoris, Sartorius, Hamstrings and Tensor fascia latae on both sides.

3.3.11. Muscle tone examination (Palpation)

Muscle tone for both lower extremities		
Right	**Muscle**	**Left**
Hypotonus	Piriformis	Hypotonus
Hypotonus	Hamstrings	Eutonus
Hypertonus	Tensor fasciae latae	Hypertonus
Hypertonus, trigger points	Quadriceps	Hypertonus, trigger points
Hypertonus	Iliopsoas	Hypertonus
Hypertonus	Sartorius	Hypertonus
Eutonus	Gluteus maximus	Eutonus
Hypotonus	Gluteus medius	Hypotonus
Hypotonus	Gluteus minimus	Hypotonus
Hypotonus	Tibialis anterior	Hypotonus
Hypertonus	Gastrocnemius	Hypertonus
Eutonus	Erector spinae	Eutonus

Table 20: Initial examination for muscle tone for both lower extremities

Conclusion of palpation examination

Palpation examination indicated a various hypertonic muscles as well as trigger points. Muscles on the anterior and posterior compartment of the thigh were hypertonic. Specifically quatriceps, tensor fascia latae, Sartorius, iliopsoas and gastrognemius muscles were hypertonic on both sides. Furthermore trigger points were found on quadriceps muscle on both sides. Moreover gluteus medius, minimus and piriformis were hypotonic on both sides while hamstrings were hypotonic only on right side.

3.3.12. Joint play examination (according to Lewit)

Sacroiliac examination:

Stoddard's crossed-hands: There was no restriction on both sides

Upper part of sacroiliac joint: There was no restriction on both sides

Lower part of sacroiliac joint: There was no restriction on both sides

Patella examination:

There was no restriction on any direction on both L.E

Head of fibula:

There was no restriction on any direction on both L.E

Lisfranc's joint:

There was restriction on dorsal and plantar direction on left L.E

Chopart's joint:

There was restriction on dorsal direction on left L.E

Subtalar joint:

There was restriction on both L.E during exerting the traction towards the distal and upward direction

Talocrular joint:

There was no restriction on any direction on both L.E

Metatarsophalangeal joints:

There was restriction in all metatarsophalangeal joints on both L.E except the 1st on the right L.E and the 3rd on the left L.E

Conclusion of joint play examination

Restrictions were found on Lisfranc's joint on dorsal and plantar direction on left L.E, on Chopart's joint on dorsal direction on left L.E, on Subtalar joint on both L.E during exerting the traction towards the distal and upward directions and on Metatarsophalangeal joints on both L.E except the 1st on the right L.E and the 3rd on the left L.E.

3.3.13. Neurologic examination

3.3.13.1. Superficial sensation

Touch: physiological on both lower extremities

Tactile: physiological on both lower extremities

3.3.13.2. Deep sensation

Stereognosis: physiological

Positioning- Kinesthesis: physiological

3.3.13.3. Tendon reflexes

Patellar reflex: physiological on both sides

Achilles' tendon reflex: physiological on both sides

Conclusion of neurologic examination

The neurologic examination bilaterally had negative findings. No neurological defects were present. The superficial sensation and tendon reflexes were physiological without any pathological findings bilaterally.

3.3.14. Conclusion of initial kinesiology examination

According to the anterior view (Table 1) both transverse arches are collapsed because of the nature of his sport, activity which demands to wear the skates for long period of time. Furthermore the patient's Achilles tendons on both sides are prominent as a result of the skates. Calf and thigh are symmetrical on both sides. Hands are in slight pronated position and flexed, shoulders are slight protracted which lead us to the hypothesis that tension of the flexor muscles of upper body such as pectoralis, biceps brachii, sternocleidomastoid, scalene maybe present in contrast to the elongation of extensor muscles such as trapezius, latissimus dorsi, triceps brachi. Moreover there was a general shifting of body weight towards right side because of the pain.

According to the lateral view (Table 2) the ankles are in dorsal flexion position from which a further examination should be performed for dorsal flexor muscles such as tibialis anterior, extensor digitorum longus and peroneus tertius as tightness might be presented. Moreover there was observed a pelvis anteflexion resulting to lumbar hyperlordosis. Both shoulders were slightly protracted as a result of pectoral muscle tightness and lastly head was in a slight protracted position. According to posterior view (Table 3) heels were in a symmetrical position with predominance of Achilles tendon on both sides. Calf muscles, popliteal and subgluteal lines were symmetrical. Iliac crests were on the same level as well as scapulas. Upper extremities were slight in pronated position. Additionally shoulders were on a slight protracted position. Finally the patient's head was on a physiological position.

During these measurements I observed a minor swelling on the area of the ankle mostly on lateral side. Furthermore the patient cannot load maximally his left leg because of the pain. This leads to the analgesic position where he shifts more weight on his right leg.

The patient was performing a smaller and faster left step because of the pain. This pain also was limiting the motion of trunk region. I don't believe the reason of the limited motion of the trunk is caused by a joint blockage but is only an analgesic position.

During the movement pattern examination there was observed an altered motion while providing the hip abduction movement on both sides.

The range of motion examination indicated us with a couple of important findings. Firstly there was a slight limitation of movement on hip flexion, which I strongly believe is based on hypertonic and/or short hamstrings. Probably there is a muscle disbalance between hip flexors and extensors. Furthermore there was a limitation on ankle dorsal flexion and eversion because of pain.

Weakness was present on the muscles that act towards the dorsal flexion and eversion, (tibialis anterior, peroneus tertius, extensor digitorum longus).

There was observed shortness on Rectus femoris, Sartorius, Hamstrings and Tensor fascia latae.

Palpation examination indicated a various hypertonic muscles as well as trigger points. Muscles on the anterior and posterior compartment of the thigh were hypertonic.

Specifically quatriceps, tensor fascia latae, Sartorius, iliopsoas and gastrognemius muscles were hypertonic on both sides. Furthermore trigger points were found on quadriceps muscle on both sides. Moreover gluteus medius, minimus and piriformis were hypotonic on both sides while hamstrings were hypotonic only on right side.

Restrictions were found on Lisfranc's joint on dorsal and plantar direction on left L.E, on Chopart's joint on dorsal direction on left L.E, on Subtalar joint on both L.E during exerting the traction towards the distal and upward directions and on Metatarsophalangeal joints on both L.E except the 1st on the right L.E and the 3rd on the left L.E.

The neurologic examination bilaterally had negative findings. No neurological defects were present. The superficial and tendon reflexes were physiological without any pathological findings bilaterally.

After all the examination procedures that I provided to my patient I conclude that the main restrictions are the pain from the overstretched ligaments and the general instability of the ankle caused from the skates. I believe there isn't a significant weakness but is pain that minimize the performance of the particular movements resulting probably by a minor trauma on ligaments of the ankle. The patient has a very good physic because he is engaged in sports and as soon as the pain will be eliminated the movements will be performed without any difficulty.

3.3.15. Therapy proposal

After all the information that I obtained from the various examinations and anamnesis I will focus on improving the general stability of the ankle. He has strong physic and I believe important for him is to strengthen the small muscles responsible for the stability of the ankle as well as relax the tension on the lower extremities muscles. Another important factor that I am considering to work on is to correct the posture of my patient as he has the tendency to lean forward and external rotating his hip joint especially the on skates. The pain doesn't concern me as a limitation of the movement but as an indicator whether my rehabilitation program will be successful. My approach would be soft tissue techniques, various stability exercises for the ankle as well as strengthening exercises for eversion muscle group of ankle.

In addition sensomotoric training would star in correcting the problem afflicting the patient. Furthermore I will use P.I.R technique for relaxation of hypertonic muscles and for trigger points. Additionally in my therapy sessions I will include joint play mobilization for the blocked joints. He could also include swimming and running in the pool in his training sessions as it would enhance the stability and strengthening of the muscles of feet. Moreover I will use laser from physical therapy for enhancing and improving the regeneration process of ligaments. Finally good exercises that will help him overcome his pain would be drawing the alphabet and reaching objects with his feet fingers.

3.4. Short term and long term rehabilitation plan

Short-term

Decrease swelling on left ankle

Decrease the level of pain on left ankle

Strengthen weak muscles (peroneus tertius, tibialis anterior, peroneus tertius and extensor digitorum longus).

Relax hypertonic and shortened muscles (quatriceps, tensor fascia latae, Sartorius, iliopsoas and gastrognemius)

Correct the posture (there was observed a lining forward position while bending the knees)

Regain mobility on restricted joints (Lisfranc's joint on dorsal and plantar direction on left L.E, on Chopart's joint on dorsal direction on left L.E, on Subtalar joint on both L.E during exerting the traction towards the distal and upward directions and on Metatarsophalangeal joints on both L.E except the 1st on the right L.E and the 3rd on the left L.E.)

Improve stability of ankle joint

Long-term

Maintain and improve the results from short rehabilitation plan

Improve coordination of muscles

Prevention tips during competition or demanding training sessions (avoid sudden turns, use an ankle support brace or taping)

Concerning daily activities he should avoid standing over an extended period of time and furthermore to try and concentrate during walking and standing on sole three point contact with the floor

Moreover during playing hockey he should also provide the three-point contact in the hockey shoes

Perform balance exercises while wearing the hockey shoes like skating on one leg.

3.5. Rehabilitation plan progress

3.5.1. Session: (1st) Date/Time: 3/2/14 - 9:30 a.m.

During the first session I started with the initial kinesiology examination and then I continued with the therapy, which was concentrated to reduce the minor edema on the ankle joint as well as strengthening exercises for the weak muscles. Furthermore I provided relaxation techniques for the hypertonic, short muscles. In addition I performed sensomotoric exercises for improving balance as well regains the collapse arches of feet. Finally I included laser therapy (enthesopathia) for reinforce the healing process of the tissues.

Goals of therapy: Decrease edema, strengthening of weak muscles, relax hypertonic-short muscles, and regain mobility on restricted joints.

Level of pain: 4/10 mostly during eversion

The range of motion (active eversion, left) was found to be at 10°

The edema (left ankle) is present

Execution:

1. Soft tissue techniques for increase the circulation and provide relaxation to the patient (massage on both lower extremities) for 15min.
2. Joint play manipulation on the restricted joints according Lewit (joint on dorsal and plantar direction on left L.E, on Chopart's joint on dorsal direction on left L.E, on Subtalar joint on both L.E during exerting the traction towards the distal and upward directions and on Metatarsophalangeal joints on both L.E except the 1st on the right L.E and the 3rd on the left L.E.)

3. P.I.R technique for relaxation of hypertonic muscles (quatriceps, tensor fascia latae, iliopsoas and gastrognemius) (3 times each muscle) [bilaterally]
4. Sensomotoric training on sitting and standing position for improving the function of the foot and also enhancing the collapse arches of the foot.
    - Training of the small foot on sitting position passive and then active. (10 repetitions)
    - Postural correction with forward lean from the ankles. (10 repetitions)
5. Exercises at the gym for strengthening the weak muscles and improve the stability of the ankle joint.
    - Passive and active movements (plantar, dorsal flexion, inversion and eversion) (2sets×10 repetitions) [bilaterally]
    - Heel and toes walking (patient was walking first on heels and then on toes for 30 repeats each)
    - Bosu (the patient was performing steps on and of the bosu) [3sets×10 repetitions]
    - Patient supine and provide stretching with rope for gastrognemius. Foot towards dorsal flexion. (2sets×15sec) [Bilaterally]
6. Laser therapy for enhancing the healing process of the tissues for 10 min
    - Wavelength: 830 nm
    - Power: 1mW
    - Continuous
7. Results of the therapeutic session

After the first session the patient felt a slight improvement in terms of stability and proprioception of his ankle. The pain was still at the same level.

8. Home exercise:
    - Alphabet: Drawing the alphabet by his foot. The patient is sitting on the chair with his foot in the air and using his big toe as a pencil he draw one by one the alphabet letters. (3 repetitions)
    - Towel crunches: Spread the towel on the floor. Pull it toward you with toes until the towel is fully gathered around your foot. Repeat 10 to 15 times.

3.5.2. Session: (2nd) **Date/Time: 4/2/14 - 9:30 a.m.**

During the second rehabilitation session I started with soft tissue techniques then I continued with P.I.R technique and joint play technique. Then it followed strengthening exercises at the gym and lastly laser therapy (enthesopathia).

Goals of therapy: Decrease edema, strengthening of weak muscles, relax hypertonic-short muscles, and regain mobility on restricted joints.

Level of the pain: the level of the pain was the same (4/10 mostly during eversion)

The range of motion (active eversion, left) was at the same degree as during the first session

Edema (left ankle) was mild decreased than previews session

Execution:

1. Soft tissue techniques for increase circulation and provide relaxation to the patient. (For 15min) [Bilaterally]
2. Joint play manipulation on the restricted joints according Lewit (joint on dorsal and plantar direction on left L.E, on Chopart's joint on dorsal direction on left L.E, on Subtalar joint on both L.E during exerting the traction towards the distal and upward directions and on Metatarsophalangeal joints on both L.E except the 1st on the right L.E and the 3rd on the left L.E.)
3. P.I.R technique for relaxation of hypertonic muscles (quatriceps, tensor fascia latae, iliopsoas and gastrognemius) (3 times each muscle) [bilaterally]
4. Sensomotoric training on sitting and standing position for improving the function of the foot and also enhancing the collapse arches of the foot for 15min.
    - Training of the small foot on sitting position passive and then active. (10 repetitions)
    - Postural correction with forward lean from the ankles. (10 repetitions)
5. Exercises at the gym for strengthening the weak muscles and for improving the stability of the ankle.
    - Active movements (plantar, dorsal flexion, inversion and eversion), against Thera-Band (red color) resistance (2 sets×10 repetitions)
    - Patient supine he then elevates his pelvis towards ceiling and provides plantar flexion on the ankles. (2 sets×10 repetitions)

- Bosu exercises: Patient stands on bosu and shifts his weight towards each side. (3 sets×10 repetitions)
- Patient supine and provide stretching with rope for gastrognemius. Foot towards dorsal flexion. (2sets×15sec) [Bilaterally]

6. Laser therapy for enhancing the healing process of the tissues for 10 min
   - Wavelength: 830 nm
   - Power: 1mW
   - Continuous
7. Results

The patient after the therapeutic session felt even better. He felt his ankle more coordinated and had a general positive feeling about the therapy. He furthermore mentioned that he is not afraid to use his ankle.

8. Home exercise

- Alphabet: Drawing the alphabet by his foot. The patient is sitting on the chair with his foot in the air and using his big toe as a pencil he draw one by one the alphabet letters. (3 repetitions)

- Towel crunches: Spread the towel on the floor. Pull it toward you with toes until the towel is fully gathered around your foot. Repeat 10 to 15 times.

3.5.3. Session: (3rd) **Date/Time: 6/2/14 - 10:00 a.m.**

For the third rehabilitation session I started with soft tissue techniques then I continued with P.I.R technique and joint play technique. Then it followed strengthening exercises at the gym and lastly laser therapy (enthesopathia).

Goal of therapy: Decrease edema, strengthening of weak muscles, relax hypertonic-short muscles, and regain mobility on restricted joints, sensory motor stimulation

Level of the pain: the level of the pain was the same (4/10 mostly during eversion)

The range of motion (active eversion, left) was increased to 12°

The edema (on left ankle) was eliminated

Execution:

1. Soft tissue techniques for improving the circulation and provide relaxation to the patient. (Massage on both lower extremities) for 15min
2. Joint play manipulation on the restricted joints according Lewit (joint on dorsal and plantar direction on left L.E, on Chopart's joint on dorsal direction on left L.E, on Subtalar joint on both L.E during exerting the traction towards the distal and upward directions and on Metatarsophalangeal joints on both L.E except the 1st on the right L.E and the 3rd on the left L.E.)
3. P.I.R technique for relaxation of hypertonic muscles (quatriceps, tensor fascia latae, iliopsoas and gastrognemius) (3 times for each muscle) [bilaterally]
4. Sensomotoric training on sitting and standing position for improving the function of the foot and also enhancing the collapse arches of the foot for 15min.
    - Training of the small foot on sitting position passive and then active. (10 repetitions)
    - Postural correction with forward lean from the ankles. (10 repetitions)
    - Postural correction while patient is on one leg. (10 repetitions)
5. Exercises at the gym for strengthening the weak muscles and for improving the stability of the ankle.
    - Active movements (plantar, dorsal flexion, inversion and eversion) against Thera-Band (green color) resistance (2 sets×10 repetitions)
    - Walking on unstable surfaces (10 surfaces in a row). During each step patient was flexing his knee and hip at a 90˚ degree angle. (4 repetitions).
    - On supine position against the wall. The patient was supine with both legs flexed at 90˚ degree angle on knee and hip joints. I placed one gym ball between his feet and the wall and the patient was pushing towards plantar flexion. (2 sets×10 repetitions)
    - Bosu exercises: The patient was standing on the Bosu and elevates alternative each leg towards flexion knee and hip at a 90˚ degree angle. (For 15sec×2sets).
    - Patient supine and provide stretching with rope for gastrognemius. Foot towards dorsal flexion. (2sets×15sec) [Bilaterally]

6. Laser therapy for enhancing the healing process of the tissues for 10 min
    - Wavelength: 830 nm
    - Power: 1mW
    - Continuous
7. Results

The patient felt even better after the therapy. He even noticed the pain to decrease during the exercises. There was not as much restriction as before.

8. Home exercises
    - Stretching on stairs. I asked from the patient to provide stretching while stepping on stairs. (3sets ×10 repetitions).
    - Marble pick up. Grasp the ball between your first and second toes; pick up and transfer to the opposite pile. (15 to 20 times)
    - Towel crunches: Spread the towel on the floor. Pull it toward you with toes until the towel is fully gathered around your foot. Repeat 10 to 15 times.

3.5.4. Session: (4th) **Date/Time: 7/2/14 - 10:00 a.m.**

Today I started with soft tissue techniques then I continued with P.I.R technique. Moreover it followed exercises at the gym and for the last part of the laser therapy (enthesopathia).

Goal of therapy: strengthening of weak muscles, relax hypertonic-short muscles, and regain mobility on restricted joints, sensory motor stimulation

Level of the pain: the level of the pain was the same (3/10 mostly during eversion)

The range of motion (active eversion, left) was classified at the same degree

Execution:

1. Soft tissue techniques for increase circulation and provide relaxation to the patient (massage for both lower extremities) 15min.
2. P.I.R technique for relaxation of hypertonic muscles (quatriceps, tensor fascia latae, iliopsoas and gastrognemius) (3 times for each muscle) [bilaterally]

3. Sensomotoric training on sitting and standing position for improving the function of the foot and also enhancing the collapse arches of the foot for 15min.
    - Training of the small foot on sitting position passive and then active. (10 repetitions)
    - Postural correction with forward lean from the ankles. (10 repetitions)
    - Postural correction while patient is on one leg. (10 repetitions)
4. Exercises at the gym for strengthening the weak muscles
    - Active movements (plantar, dorsal flexion, inversion and eversion), against Thera-Band (green color) resistance (2set×10 repetitions)
    - On supine position against the wall. The patient was supine with both legs flexed at 90˚ degree angle on knee and hip joints. I placed one gym ball between his feet and the wall and the patient was pushing towards plantar flexion but only with one foot each time. (2 sets×10 repetitions)
    - Bosu exercises: The patient was standing on the Bosu and elevates alternative each leg towards flexion knee and hip at a 90˚ degree angle. (For 15sec×2sets). Furthermore the patient was standing with both legs on bosu and I provide pressure in all directions and was trying to maintain his balance. (3sets×15sec)
    - Walking on unstable surfaces (10 surfaces in a row). During each step patient was flexing his knee and hip at a 90˚ degree angle and passing an overball under his flexed leg. (4 repetitions)
    - Patient supine and provide stretching with rope for gastrognemius. Foot towards dorsal flexion. (2sets×15sec) [Bilaterally]
5. Laser therapy for enhancing the healing process of the tissues for 10 min
    - Wavelength: 830 nm
    - Power: 1mW
    - Continuous
6. Results

After this physiotherapeutic session I observed a minor improvement in terms of balance during the training part of the session as well a better coordination. The patient felt much better and also the pain was decreased.

Home exercises

- Stretching on stairs. I asked from the patient to provide stretching while stepping on stairs. (3sets ×10 repetitions).
- Marble pick up. Grasp the ball between your first and second toes; pick up and transfer to the opposite pile. (15 to 20 times)
- Towel crunches: Spread the towel on the floor. Pull it toward you with toes until the towel is fully gathered around your foot. Repeat 10 to 15 times.

3.5.5. Session: (5th) **Date/Time: 10/2/14 - 10:00 a.m.**

For this rehabilitation session I started with soft tissue techniques then I continued with P.I.R technique and joint play technique. Then it followed strengthening exercises at the gym and lastly laser therapy (enthesopathia).

Goal of therapy: strengthening of weak muscles, relax hypertonic-short muscles, and regain mobility on restricted joints, sensory motor stimulation

Level of the pain: the level of the pain was the same (2/10 mostly during eversion)

During that therapeutic session the range of motion (active eversion, left) was increased to 14°

Execution:

1. Soft tissue techniques for increase circulation and provide relaxation to the patient (massage for both lower extremities) 15min.
2. Joint play manipulation on the restricted joints according Lewit (joint on dorsal and plantar direction on left L.E, on Chopart's joint on dorsal direction on left L.E, on Subtalar joint on both L.E during exerting the traction towards the distal and upward directions and on Metatarsophalangeal joints on both L.E except the 1st on the right L.E and the 3rd on the left L.E.)
3. P.I.R technique for relaxation of hypertonic muscles (quatriceps, tensor fascia latae, iliopsoas and gastrognemius) (3 times for each muscle) [bilaterally]
4. Sensomotoric training on sitting and standing position for improving the function of the foot and also enhancing the collapse arches of the foot for 15min.

- Postural correction with forward lean from the ankles. (10 repetitions)
- Postural correction while patient is on one leg. (10 repetitions)
- Postural correction while patient was performing lunges. (10 repetitions)

5. Exercises at the gym for strengthening the weak muscles
    - Active movements (plantar, dorsal flexion, inversion and eversion), against Thera-Band (blue color) resistance (2set×10 repetitions)
    - Bosu exersices: The patient was standing on the Bosu and elevates alternative each leg towards flexion knee and hip at a 90˚ degree angle. (For 15sec×2sets). Furthermore the patient was standing with both legs on bosu and I provide pressure in all directions and was trying to maintain his balance. (3sets×15sec). More over I instruct the patient to stand on the bose bent his knees and close his eyes while trying to maintain his balance. (3sets×15sec)
    - Posturome Squats. The patient stands with both legs on posturomed and squats. (15repetitions×2sets)
    - Walking on a rope and during performing each step the patient should move an overball from one side of the rope to the other without falling from the rope. (4 repetitions)
6. Laser therapy for enhancing the healing process of the tissues for 10 min
    - Wavelength: 830 nm
    - Power: 1mW
    - Continuous
7. Results

After todays rehabilitation session my patient was really happy because he felt a minor pain only. The only movement that causes pain is the eversion but is less day after day.

8. Home exercises
    - Toe Circles

      Move your ankle through its entire range of motion (up and down, in and out, and in circles). Move only the ankle and not the leg. (2set×10 repetitions)

3.5.6. Session: (6th) **Date/Time: 11/2/14 - 10:00 a.m.**

The rehabilitation session today started with soft tissue techniques then I continued with P.I.R technique. Moreover it followed strengthening exercises at the gym and for last laser therapy (enthesopathia).

Goal of therapy: strengthening of weak muscles, relax hypertonic-short muscles, and sensory motor stimulation (proprioception)

Level of the pain: the level of the pain was the same (1/10 mostly during eversion)

Range of motion (active eversion, left) was at the same degree as last therapeutic session

Execution:

1. Soft tissue techniques for increase circulation and provide relaxation to the patient (massage for both lower extremities) 15min.
2. P.I.R technique for relaxation of hypertonic muscles (quatriceps, tensor fascia latae, iliopsoas and gastrognemius) (3 times for each muscle) [bilaterally]
3. Sensomotoric training on sitting and standing position for improving the function of the foot and also enhancing the collapse arches of the foot for 15min.
    - Postural correction while patient was performing lunges. (10 repetitions)
    - Postural correction while patient was performing jumps. (10 repetitions)
4. Exercises at the gym for strengthening the weak muscles
    - Active movements (plantar, dorsal flexion, inversion and eversion), against Thera-Band (blue color) resistance (2sets×10 repetitions)
    - Bosu exercises: The patient was standing with both legs on bosu and I provide pressure in all directions and was trying to maintain his balance. (3sets×15sec). More over I instruct the patient to stand on the bose bent his knees and close his eyes while trying to maintain his balance. (3sets×15sec). Additionally the patient was standing on bosu with bent knees and I was throwing towards him a 2kg ball in all directions.

- Walking on a rope and during performing each step the patient should move an averball from one side of the rope to the other without falling from the rope. (4 repetitions)
- Posturomet Squats. The patient stands with both legs on posturomed and squats. (15 repetitions×2sets). Moreover he closes his eyes and tries to balance while holding an overball above his head. (15sec×2sets)
- Walking on a rope and during performing each step the patient should move an overball around his balancing leg providing a circle. (4 repetitions)

5. Laser therapy for enhancing the healing process of the tissues for 10 min
    - Wavelength: 830 nm
    - Power: 1mW
    - Continuous
6. Results

Today the patient felt little pain only when he provided the eversion with the thera-band. He was very satisfied and happy, as today he will attend his training sessions for first time. Moreover instructed him to provide ice therapy for 10min after his training as prevention of swelling and in case of any pain or discomfort.

7. Home exercises
    - Toe Circles

      Move your ankle through its entire range of motion (up and down, in and out, and in circles). Move only the ankle and not the leg. (2set×10 repetitions)

3.5.7. Session: (7th) **Date/Time: 13/2/14 - 10:00 a.m.**

For this rehabilitation session I started with soft tissue techniques then I continued with P.I.R technique. Then it followed exercises at the gym and for last laser therapy (enthesopathia).

Goal of therapy: strengthening of weak muscles, relax hypertonic-short muscles, and sensory motor stimulation (proprioception)

Level of the pain: the level of the pain was the same (0/10)

On that session the degree of range of motion (active eversion, left) was increased to 16°

Execution:

1. Soft tissue techniques for increase circulation and provide relaxation to the patient (massage for both lower extremities) 15min.
2. P.I.R technique for relaxation of hypertonic muscles (quatriceps, tensor fascia latae, iliopsoas and gastrognemius) (3 times for each muscle) [bilaterally]
3. Exercises at the gym for strengthening the weak muscles
    - Bosu exercises: The patient was standing on the Bosu and elevates alternative each leg towards flexion knee and hip at a 90˚ degree angle. (For 15sec×2sets). In addition he was standing with both legs on bosu and I provide pressure in all directions and was trying to maintain his balance. (3sets×15sec). More over I instruct the patient to stand on the bose bent his knees and close his eyes while trying to maintain his balance. (3sets×15sec). Additionally the patient was standing on bosu with bent knees and I was throwing towards him a 2kg ball in all directions.
    - Jumps. The patient was standing in front of a pillow and he was providing jumps on that pillow but at the landing phase he only step with one leg. (2sets×10 repetitions) [Bilaterally]
    - Posturomet Squats. The patient stands with both legs on posturomed and squats. (15 repetitions×2sets). Moreover he closes his eyes and tries to balance while holding an overball above his head. (15sec×2sets)

4. Laser therapy for enhancing the healing process of the tissues for 10 min
    - Wavelength: 830 nm
    - Power: 1mW
    - Continuous
5. Results

The patient is very happy and satisfied as he felt no pain and he could perform all the exercises with no restrictions or pain. He looks forward to play again hockey and he feels that he would be able soon to help his team.

3.5.8. Session: (8th) **Date/Time: 14/2/14 - 10:00 a.m.**

For the last rehabilitation session I started with soft tissue techniques then I continued with P.I.R technique. Additionally it followed strengthening exercises at the gym and for the last part laser therapy (ethesopathia).

Goal of therapy: strengthening of weak muscles, relax hypertonic-short muscles, sensory motor stimulation (proprioception) and maintain stability of the ankle

Level of the pain: the level of the pain was the same (0/10)

During the last therapeutic session the range of motion (active eversion, left) achieve 17° degrees

Execution:

1. Soft tissue techniques for improving the circulation and provide relaxation to the patient (massage for both lower extremities) 15min.
2. P.I.R technique for relaxation of hypertonic muscles (quatriceps, tensor fascia latae, iliopsoas and gastrognemius) (3 times for each muscle) [bilaterally]
3. Exercises at the gym for strengthening the weak muscles
    - Bosu exercises: The patient was standing on the Bosu and elevates alternative each leg towards flexion knee and hip at a 90˚ degree angle. (For 15sec×2sets).

In addition he was standing with both legs on bosu and I provide pressure in all directions and was trying to maintain his balance. (3sets×15sec). More over I instruct the patient to stand on the bose bent his knees and close his eyes while trying to maintain his balance. (3sets×15sec). Additionally the patient was standing on bosu with bent knees and I was throwing towards him a 2kg ball in all directions.

- Posturomet Squats. The patient stands with both legs on posturomed and squats. (15 repetitions×2sets). Moreover he closes his eyes and tries to balance while holding an overball above his head. (15sec×2sets)
- Jumps. The patient was standing in front of a pillow and he was providing jumps on that pillow but at the landing phase he only step with one leg. (2sets×10 repetitions) [Bilaterally]
- Bosu exercises: The patient was standing in front of the bosu and providing lunges on it. (3sets×15 repetitions)
- Walking on a rope on his toes. (4 repetitions)

6. Laser therapy for enhancing the healing process of the tissues for 10 min
    - Wavelength: 830 nm
    - Power: 1mW
    - Continuous
7. Results

The patient is very happy and satisfied as he felt no pain and he could perform all the exercises with no restrictions or pain. He looks forward to play again hockey and he feels that he would be able soon to help his team. Finally I advised the patient to use a protective bracing only during competitions.

3.6. Final Kinesiology Examination

3.6.1. Posture evaluation in standing

Feet distance	Feet close to each other
Transverse arch	In better condition on both feet
Longitudinal arch	Physiological
Calf	Symmetrical
Knee Patella	Physiological position on both L.E External rotation: physiological Internal rotation: physiological
Thigh contour	Symmetrical in both sides
Anterior superior iliac spines	On the same level
Umbilicus	No deviations
Sternum	Middle line
Nipples	Symmetrical
Hands	Physiological on both U.E
Clavicles	Symmetrical
Shoulders	Physiological
Head position	Physiological
Weight bearing	Symmetrical weight bearing

Table 21: Final postural examination- Anterior view

Ankle joint	Neutral position on both L.E
Knee joint	Straight line
Pelvis position	Slight anteflexion
Lumbar region of spine	Slight hyperlordosis
Thoracic region of spine	Physiological kyphosis
Shoulder position	Physiological position of both shoulders
Cervical region of spine	Slight straightening
Head position	Slight protraction

Table 22: Final postural examination- Lateral View

Heels position	Symmetrical
Achilles tendon	Predominance on both L.E
Calf	Symmetrical
Popliteal lines	Symmetrical
Subgluteal lines	Symmetrical
Iliac crests	On the same level
Posterior superior iliac spines	Symmetrical
Scapulas	On the same level
Upper extremities	Slight pronation
Shoulders	Slight protraction
Head position	Physiological

Table 23: Final postural examination- Posterior View

Conclusion of posture evaluation

The patient seems to be improved in terms of overall posture. He is more stable with his hands and shoulders in physiological position and his ankles again in neutral position. The patient as I mentioned before is a young athlete with a strong physic and does not suffer from any severe deformity or pure posture. The key factors, which are his ankles and feet, look more stable.

3.6.2. Dynamic test (Mobility of segments)

Maximal extension: The patient is able to provide the movement in a physiological range of motion without any discomfort or pain.

Lateroflexion: The patient is able to provide the movement with no pain. He has little more range of motion towards the right side and the movement seems fluent. There is no restriction on left side or pain.

Maximal flexion: He is able to provide the movement with no pain. The range of motion of all vertebral segments distributed equally. The patient does not feel any discomfort or dizziness during the movement.

Conclusion of dynamic testing

During the dynamic testing I didn't find anything important concerning the diagnosis and the pain that my patient have. There was physiological mobility of the spine and good balance.

Note: The dynamic test is performed to indicate if there is any restriction between the spine segments or scoliosis, as the patient cannot load fully his left L.E.

3.6.3. Special test

3.6.3.1. Vele test

Grade 1: Norm

Digits slightly touch the floor. It is possible to insert a sheet of paper between and under the toes with ease.

Conclusion of special test

The patient after the therapeutic sessions he regains his stability. Undoubtedly he has to continue training to maintain those results.

3.6.4. Two scales test

Left	Right
49kg	51kg

Table 24: Final two scales test

Conclusion of two-scale test

After the physiotherapeutic sessions and the elimination of the pain I can observe that the difference on the weight bearing is diminished. Concluding that there is no actual weight bearing discrepancy.

3.6.5. Anthropometric measurement

3.6.5.1. Lower extremities Length - Circumferences

Left		Right
101cm	Anatomical length (ASIS)	101cm
111cm	Functional length (Umbilicus)	111cm
94cm	Length of thigh	94cm
47cm	Length of middle leg	47cm
25cm	Length of foot	25cm
50cm	Circumference of thigh (vastus medialis)	50cm
61cm	Circumference of thigh (quatriceps)	61cm
41cm	Circumference of knee	41cm
44cm	Circumference of calf	44cm
36cm	Circumference of ankle	36cm
27cm	Circumference of foot	27cm

Table 25: Lower extremities final length and circumferences

Conclusion of Anthropometric measurements

The patient now has no difference in terms of the anthropometric measurements as the swelling is eliminated.

3.6.6. Gait examination

3.6.6.1. Forward walking

Step phase: Physiological

Stance phase: Physiological

Rolling of feet: Improved than before

Pelvis rotation: Slightly presented

Trunk movements: Limited

Arm synkinesis: Physiological

3.6.6.2. Backward walking

Step phase: little unstable

Stance phase: physiological

Rolling of feet: Not fluent

Pelvis rotation: Slightly presented

Trunk movements: Limited

Arm synkinesis: Physiological

3.6.6.3. Walking on toes

The patient was able to provide it with no pain

3.6.6.4. Walking on heels

The patient could provide it with good balance. Was also slightly leaning forward.

Conclusion of gait examination

The patient performed great change, as there was no pain to limit his movements. He could perform the modification gait on toes and on heels with no pain and good balance.

3.6.7. Examination of basic movement patterns (according to Janda)

Extension of hip joint: Physiological (both sides)

Movement: The patient performed the movement with the correct sequence of muscles activation. First gluteus maximus then hamstrings, contralateral spinal extensors muscles lumbar region, ipsilateral spinal extensors muscles lumbar region, contralateral spinal extensors muscles thoracic and lumbar region, ipsilateral spinal extensors muscles thoracic and lumbar region and last shoulder girdle muscles.

Abduction of hip joint: Physiological (both sides)

Movement: The movement that the patient performed was a pure abduction of hip with no alternate movements.

Curl up (trunk flexion): Physiological (both sides)

Movement: The patient had no problem to provide the sitting up position from supine. Furthermore the motion was smooth and a curling movement of the trunk was observed.

Conclusion of basic movement patterns

During the movement pattern examination there was observed an improvement concerning the hip abduction where at the initial examination was presented a pathological movement.

3.6.8. Range of motion examination (according to Kendall)

Hip Joint					
Right	**Active**	**Left**	**Right**	**Passive**	**Left**
-	**Hip joint**	-	-	**Hip joint**	-
20^0	Extension	20^0	25^0	Extension	25^0
95^0	Flexion	95^0	100^0	Flexion	100^0
45^0	Abduction	45^0	50^0	Abduction	50^0
19^0	Adduction	19^0	22^0	Adduction	22^0
35^0	Internal rotation	35^0	38^0	Internal rotation	39^0
48^0	External rotation	48^0	50^0	External rotation	50^0

Table 26: Final examination of the ROM of Hip joint

Knee Joint					
Right	**Active**	**Left**	**Right**	**Passive**	**Left**
-	**Knee joint**	-	-	**Knee joint**	-
0^0	Extension	0^0	-5^0	Extension	-5^0
145^0	Flexion	145^0	150^0	Flexion	150^0

Table 27: Final examination of the ROM of Knee joint

Ankle Joint					
Right	**Active**	**Left**	**Right**	**Passive**	**Left**
45^0	Plantar flexion	45^0	50^0	Plantar flexion	50^0
25^0	Dorsal flexion	25^0	30^0	Dorsal flexion	30^0
40^0	Inversion	40^0	45^0	Inversion	45^0
17^0	Eversion	17^0	20^0	Eversion	20^0

Table 28: Final examination of ROM of Ankle joint

Conclusion of Range of motion examination

The range of motion examination indicated a significant change as the pain was not present and the patient could perform the movements with no limitations.

3.6.9. Muscle strength test (according to Kendall)

Lower extremities muscle strength test		
Right	**Muscle**	**Left**
5	Tibialis anterior	5
5	Extensor digitorum longus/brevis	5
5	Peroneus Tertius	5
5	Tibialis posterior	5
5	Flexor digitorum longus	5
5	Peroneus longus	5
5	Peroneus brevis	5
5	Gastrocnemius	5
5	Soleus	5
5	Hamstrings	5
5	Quadriceps	5
5	Gluteus medius	5
5	Gluteus minimus	5
5	Iliopsoas	5

5	Tensor fasciae latae	5
5	Sartorius	5
5	Piriformis	5
5	Gluteus maximus	5
5	Hip adductors	5
5	Flexor hallucis longus	5
5	Flexor hallucis brevis	5
5	Extensor hallucis longus	5

Table 29: Final examination of both lower extremities muscle strength test

Conclusion of muscle strength test

There was no indication of weakness. The patient was able to perform everything with no restrictions.

3.6.10. Muscle length test (according to Janda)

Lower extremities muscle length test		
Right	**Muscle**	**Left**
0	Gastrocnemius/ Plantaris	0
0	Soleus	0
0	Hip adductors	0
0	Piriformis	0
0	Iliopsoas	0
0	Sartorius	0
0	Rectus femoris	0
1	Hamstrings	1
1	Tensor fasciae latae	1
0	Tibialis anterior	0

Table 30: Final examination for both lower extremities muscles length test

Conclusion of shortening examination

There was still observed a minor shortness on hamstrings and tensor fascia latae. There was an improvement but still shortness was presented.

3.6.11. Muscle tone examination (Palpation)

Muscle tone for both lower extremities		
Right	**Muscle**	**Left**
Eutonus	Piriformis	Eutonus
Eutonus	Hamstrings	Eutonus
Eutonus	Tensor fasciae latae	Eutonus
Eutonus	Quadriceps	Eutonus
Eutonus	Iliopsoas	Eutonus
Eutonus	Sartorius	Eutonus
Eutonus	Gluteus maximus	Eutonus
Eutonus	Gluteus medius	Eutonus
Eutonus	Gluteus minimus	Eutonus
Eutonus	Tibialis anterior	Eutonus
Eutonus	Gastrocnemius	Eutonus
Eutonus	Erector spinae	Eutonus

Table 31: Final examination for muscle tone for both lower extremities

Conclusion of palpation examination

There was improvement of all muscles as they return to their physiological state.

3.6.12. Joint play examination (according to Lewit)

Sacroiliac examination:

Stoddard's crossed-hands: There was no restriction on both sides

Upper part of sacroiliac joint: There was no restriction on both sides

Lower part of sacroiliac joint: There was no restriction on both sides

Patella examination:

There was no restriction on any direction on both L.E

Head of fibula:

There was no restriction on any direction on both L.E

Lisfranc's joint:

There was no restriction on any direction on both L.E

Chopart's joint:

There was no restriction on any direction on both L.E

Subtalar joint:

There was no restriction on any direction on both L.E

Talocrular joint:

There was no restriction on any direction on both L.E

Metatarsophalangeal joints:

There was restriction in all metatarsophalangeal joints on both L.E except the 1st on the right L.E and the 3rd on the left L.E

Conclusion of joint play examination

Restrictions were found only in all metatarsophalangeal joints on both L.E except the 1st on the right L.E and the 3rd on the left L.E.

3.6.13. Neurologic examination

3.6.13.1.Superficial sensation

Touch: physiological on both lower extremities

Tactile: physiological on both lower extremities

3.6.13.2.Deep sensation

Stereognosis: physiological

Positioning- Kinesthesis: physiological

3.6.13.3.Tendon reflexes

Patellar reflex: physiological on both sides

Achilles' tendon reflex: physiological on both sides

Conclusion of neurologic examination

The neurologic examination bilaterally had negative findings. No neurological defects were present. The superficial sensation and tendon reflexes were physiological without any pathological findings bilaterally.

3.6.14. Conclusion of final kinesiology examination

After all the examination procedures that I provided to my patient I conclude that the main restrictions are the pain from the overstretched ligaments and the general instability of the ankle caused from the skates. I believe there isn't a significant weakness but is pain that minimize the performance of the particular movements resulting probably by a minor trauma on ligaments of the ankle. The patient has a very good physic because he is engaged in sports and as soon as the pain will be eliminated the movements will be performed without any difficulty.

3.7. Evaluation of the effect of the therapy

A male patient had a distortion of his left ankle during a hockey competition on 31st of January. After he visited the doctor to be diagnosed for the distortion he visited the rehabilitation department on 3rd of February.

From the examinations that I provided to the patient I found that he is didn't suffer from any severe limitation concerning movement. The presence of pain was what limited any movement. Furthermore my patient did have restricted joints and also a lot of tension on his leg muscles on both sides. Additionally and most important in my opinion was the imbalanced posture caused by the weak muscles of his feet.

The effects of the therapy were positive as the pain was eliminated and a significant improvement of all the above-mentioned limitation. The swelling on the ankle is eliminated, the hypertonic muscles were assessed and regain their normal tone, the restricted joints were movable and the balance was remarkably improved.

Furthermore therapies that would be beneficial for the patient are kinesiotaping for stabilizing the joint and provide a better support and P.N.F (proprioceptive neuromuscular facilitation) for enhance the strengthening process. Concerning physical therapy apart from laser therapy that was applied I could include ultrasound and TENS current for enhancing the healing process.

Before			**After**		
Strength test	Peronieus Tertius (left)	3+	Strength test	Peronieus Tertius (left)	5
Palpation	Tibialis Anterior (left)	Hypotonus	Palpation	Tibialis Anterior (left)	Eutonus
Palpation	Gastrognemius (left)	Hyertonus	Palpation	Gastrognemius (left)	Eutonus
R.O.M	Active Eversion (left)	10^0	R.O.M	Active Eversion (left)	17^0
Gait	Walking on Heels	Unable	Gait	Walking on Heels	Able
Gait	Walking on Toes	Unable	Gait	Walking on Toes	Able
Vele test	Grade 3	Unstable on ankle joints	Vele test	Grade 1	Stable on ankle joints

Table 32: Results before and after the therapy

3.8. Prognosis

The patient had eight rehabilitation sessions for his left ankle distortion. All the goals set for the rehabilitation program were successfully achieved. According to the outstanding will of my patient and the incredible cooperation that it was developed during the physiotherapeutic sessions between the patient and me, the prognosis is surely positive.

Nevertheless the patient needs to continue with the strengthening of the small muscle groups of his feet and also to work on balance exercises in order to eliminate any chance of reoccur of twisting his ankles.

4. Conclusion

During my practice I faced the fascinating challenge of treating a patient that is an active sports man. I was always involved in sports and I knew from the beginning how important was for him to get as soon as possible back to his sport activity. In addition a very encourage factor that kept me focus was that day after day the patient and I were observing improvement.

We had a great cooperation with a general positive thinking of achieving our one and only goal, to get him back to the hockey field the soonest. This positive thinking from both sides I believe enhanced the rehabilitation process. I tried to perform all the techniques and the knowledge that I acquired from my studies. I am satisfied with the results as my patient was pain free back to his sports activity and also instructed for few prevention tips.

Finishing, I would like to refer to the friendly and professional guidance of my supervisor, Mgr. Zaher EL Ali at C.L.P.A (Centrum léčby pohybového aparátu) clinic. It was determinant for achieving success and fulfilled of the goals during rehabilitation process.

5. BIBLIOGRAPHY

5.1. Article references

1. Golano, P., & Vega, J., & DeLeeuw, P. A., & Malagelada, F., & Manzanares, M. C. (2010). Anatomy of the ankle ligaments: a pictorial essay. Knee surgery, Sports Traumatology, Arthroscopy, 18(5), 557-69. Retrieved April 17, 2014 from ProQuest Central Journal database

2. Hertel, J. (2002). Functional anatomy, pathomechanics, and pathophysiology of lateral ankle instability. *Journal of Athletic Training*, 37(4), 364-375. Retrieved April 17, 2014 from ProQuest Central Journal database

3. Small, K. (2009). Ankle sprains and fractures in adults. Orthopaedic Nursing, 28(6), 314-20. Retrieved April 17, 2014 from ProQuest Central Journal database

4. Chorley, J., & Hergenroeder, A. (1997). Management of ankle sprains. *Pediatric Annals*, 26(1), 56-64. Retrieved April 17, 2014 from ProQuest Central Journal database

5. Richard, S., & Brone, S., & Roberts, O. W. (2002). Rehabilitating ankle sprains. *The physician and Sportsmedicine*, 30(8), 48-50. Retrieved April 17, 2014 from ProQuest Central Journal database

6. Leardini, A., & O'Connor, J., & Giannini, S. (2014). Biomechanics of the natural, arthritic, and replaced human ankle joint. *Journal of Foot and Ankle Research*, 7-8. Retrieved May 2, 2014 from http://www.jfootankleres.com

7. Kannus, V. (1992). Evaluation of abnormal biomechanics of the foot and ankle in athletes. Br J Sports Med, 26, 83-89. Retrieved May 2, 2014 from http://bjsportmed.com

8. Nicolopoulos, S., & Scott, W., & Giannoudis, V. (2000). Biomechanical basis of foot orthotic prescription. Current Orthopaedics, 14, 464-469. Retrieved May 3, 2014 from http://www.idealibrary.com

9. Audenaert, A., & Prims, J., & Reniers, G., & Weyns, D., & Mahieu, P., & Audenaert, E. (2010). Evaluation and economic impact analysis of different treatment options for ankle distortions in occupational accidents. *Journal of Evaluation in Clinical Practice*, 16(5), 933-939. Retrieved May 3, 2014 from Wiley Online Library

10. Funk, J. (2011). Ankle injury mechanisms: Lessons learned from cadaveric studies. Clinical Anatomy, 24, 350-361. Retrieved May 4, 2014 from Wiley Online Library

11. McKeon, J., & Bush, H., & Reed, A., & Whittington, A., & Uhl, T., & McKeon, P. (2014). Return to play probabilities following new versus recurrent ankle sprains in high school athletes. *Journal of Science and Medicine in Sports*, 17(1), 23-28. Retrieved May 4, 2014 from Elsevier Journal Database

12. Stecco, A., & Stecco, C., & Macchi, V., & Porzionato, A., & Ferraro, C., & Masiero, S. et al. (2011). RMI study and clinical correlations of ankle retinacula damage and outcomes of ankle sprain. Surgical and Radiologic Anatomy, 33(10), 881-90. Retrieved May 5, 2014 from ProQuest Central Journal database

13. Man, I. O. W., & Morrissey, M. C., & Cywinski, J. K. (2007). Effect of neuromuscular electrical stimulation on ankle swelling in the early period after ankle sprain. Physical Therapy, 87(1), 53-56. Retrieved May 5, 2014 from ProQuest Central Journal database

14. Fong, D. T. P., & Chan, Y., & Mok, K., & Yung, P. S. H., & Chan, K. (2009). Understanding acute ankle ligamentous sprain injury in sports. *Sports Medicine, Arthroscopy, Rehabilitation, Therapy and Technology: SMARTT,* (1). Retrieved May 8, 2014 from ProQuest Central Journal database

15. Glenn, N. W., & Allen, J. E. (2010). Rehabilitation of Syndesmotic (High) Ankle Sprains. *Sports Health,* 2(6), 460-470. Retrieved May 11, 2014 from http://www.ncbi.nlm.nih.gov

16. Lind, C. (2013). Lateral Ankle Sprain Grade I-II Non–Operative Protocol. *Rosenberg Cooley Metcalf.* Retrieved May 11, 2014 from https://www.rcmclinic.com

5.2. Book references

17. DeLisa, A. J., Gans, B. M., & et al. (2005). *Physical Medicine and Rehabilitation: principle and practice (4th ed.).* Philadelphia: Lippincott Williams &Wilkins.

18. Janda, V. (1983). *Muscle Function Testing. (1st ed.).* United Kingdom: Butterworth's Preparations

19. Kendal, F., Kendal, E., & et al. (2013) *Muscles Testing and Function with Posture and Pain. (5th ed.).* Baltimore: Lippincott Williams & Wilkins

20. Lewit, K., & Richard, M. (2009). *Manipulative Therapy: Musculoskeletal Medicine (1st ed.).* Baltimore: Elsevier Limited

21. Clemente, D. (2006). *A Regional Atlas of the Human Body. (6th ed.).* Germany: Lippincott Williams & Wilkins

22. Drake, L., & Vogl, A. (2009). *Gray's Anatomy for Students. (2nd ed.).* United Kingdom: Churchill Livingstone Elsevier

23. Netter, F. (2006). *Atlas of Human Anatomy. (4th ed.).* United States of America: Sounders Elsevier

24. Paulsen, F., Waschko, J., et al. (2011). *Sobotta Atlas of Human Anatomy General Anatomy and Musculoskeletal System.* (15th ed.). Canada: Elsevier Urban & Fischer

25. Feneis, H., & Dauber, W. (2000). *Pocket Atlas of Human Anatomy.* (4th ed.). New York: Thieme Stuttgart

26. Peck, S. R. (1951). *Atlas of Human Anatomy for the Artists.* (1st ed.). New York: Oxford university press

5.3. Lectures

27. Jalovcová, M. (2011). *Examination and basic therapeutic methods I: Anthropometric measurements.* Lecture`s notes. Charles University in Prague

28. Cemusová, J. (2011). *Introduction to rehabilitation: Physiotherapist and patient`s past history.* Lecture`s notes. Charles University in Prague

29. Jelínková, I. (2012). *Examination and basic therapeutic methods II: Goniometry. Lecture`s notes.* Charles University in Prague

30. Jelínková, I. (2012). *Examination and basic therapeutic methods II: Muscle strength testing.* Lecture`s notes. Charles University in Prague

31. Jelínková, I. (2012). *Examination and basic therapeutic methods II: Walking examination.* Lecture`s notes. Charles University in Prague

32. Novakova, T. (2013) *Clinical practice VI:* Lecture's notes. Charles University in Prague

6. SUPPLEMENTS

6.1. List of Tables

6.2. List of Figures

6.3. Abbreviations

CLPA= Centrum Lecby Pohyboveho Aparatu

CaFi= Calcaneofibular ligament

TiCa= Tibiocalcaneal ligament

ATFL= Anterior TaloFibular Ligament

PRICE= Protection Rest Ice Compression Elevation

ROM= Range Of Motion

MRI= Magnetic Resonance Imaging

LE= Lower Extremity

UP= Upper Extremity

Nm= nanometers

mW= microvolts

6.4. Photo Documentation

Photo 1: Lunges on bosu

Photo 2: Wobble board circular movements

Photo3: Walking on wobble boards

Photo 4: Throw catch 2kg ball on bosu

Photo 5: Walking on rope



Photo 6: Alternative lunges on bosu emphasized on ankle stability

6.5. Application for Ethics Board Review

CHARLES UNIVERSITY IN PRAGUE
FACULTY OF PHYSICAL EDUCATION AND SPORT
José Martího 31, 162 52 Praha 6-Veleslavín
tel. +420 2 2017 1111
http://www.ftvs.cuni.cz/

Application for Ethics Board Review

of the undergraduate research, involving human subjects

Project title: Case study of a patient with the diagnosis of ankle distortion.

Nature of the research project: Bachelor thesis
* Please delete as appropriate.

Author (chief investigator): Panayiotis Vryonides
co-investigators:
Supervisor (in case of student research): PhDr. Novakova Tereza, Ph.D.

Research project description also involves the case study of the patient with the ankle distortion was conducted under the supervision of an experienced physiotherapist at Centrum Lecby Pohyboveho Aparatu
Guaranteed safety to be judged by experts: no invasive methods were used
Ethical aspects of the research: personal data obtained during the case study will not be published.
Informed consent (attached)

Date: 3/2/2014 Author's signature:

Faculty of Physical Education and Sport, Charles University in Prague
ETHICS BOARD REVIEW

Ethics Board members: Doc. MUDr. Staša Bartůňková, CSc.
Prof. Ing. Václav Bunc, CSc.
Prof. PhDr. Pavel Slepička, DrSc.
Doc. MUDr. Jan Heller, CSc.

The Ethics Board at the Faculty of Physical Education and Sport, Charles University, approved the research project.
Approval number: 095/2014
Date: 24.2.2014

The Ethics Board at the Faculty of Physical Education and Sport, Charles University, reviewed the submitted research project and **found no contradictions with valid principles**, regulations and international guidelines for biomedical research involving human subjects.

The chief investigator of the project met the necessary requirements for receiving the Ethics Board approval.

Official school stamp

UNIVERZITA KARLOVA v Praze
Fakulta tělesné výchovy a sportu
José Martího 31, 162 52, Praha 6
1

Signature, REB Chairman

INFORMOVANÝ SOUHLAS

V souladu se Zákonem o péči o zdraví lidu (§ 23 odst. 2 zákona č.20/1966 Sb.) a Úmluvou o lidských právech a biomedicíně č. 96/2001, Vás žádám o souhlas k vyšetření a následné terapii. Dále Vás žádám o souhlas k nahlížení do Vaší dokumentace osobou získávající způsobilost k výkonu zdravotnického povolání v rámci praktické výuky a s uveřejněním výsledků terapie v rámci bakalářské práce na FTVS UK. Osobní data v této studii nebudou uvedena. Dnešního dne jsem byla odborným pracovníkem poučena o plánovaném vyšetření a následné terapii. Prohlašuji a svým dále uvedeným vlastnoručním podpisem potvrzuji, že odborný pracovník, který mi poskytl poučení, mi osobně vysvětlil vše, co je obsahem tohoto písemného informovaného souhlasu, a měla jsem možnost klást mu otázky, na které mi řádně odpověděl. Prohlašuji, že jsem shora uvedenému poučení plně porozuměla a výslovně souhlasím s provedením vyšetření a následnou terapií. Souhlasím s nahlížením níže jmenované osoby do mé dokumentace a s uveřejněním výsledků terapie v rámci studie.

Datum:……

Osoba, která provedla poučení:……

Podpis osoby, která provedla poučení:……

Vlastnoruční podpis pacienta /tky:…….