Charles University

Faculty of Physical Education and Sport

Case study of physiotherapy treatment of a patient with the diagnosis total hip replacement

Bachelor Thesis

April 2014

Prague

Author: Simen Schei Eikbu

Supervisor: Mgr. Katerina Holubova

Abstract

Title:

English: Case study of physiotherapy treatment of a patient with the diagnosis total hip replacement

Czech: Kazuistika fyzioterapeuticke pece o pacienta s diagnozou totalni endoproteza kycelniho kloubu

Thesis aim:

This bachelor thesis contains rehabilitation of a patient after total hip replacement due to osteoarthritis. The theoretical part addresses the anatomical, biomechanical and kinesiological aspects of this situation . The practical part continues with the physiotherapetic process about a 53 years old lady after total hip replacement including examination, therapy implementation and the effect of rehabilitation.

Methods:

Soft tissue technique, PIR (Lewit), Strengthening, Thermotherapy, Mobilization (Lewit) and self therapy during 4 days of rehabilitation.

Keywords

Total hip replacement, osteoarthritis, physiotherapy, hip joint

Declaration

I declare that this work is entirely my own, also based on knowledge from books, article, seminars and lectures from attending FTVS. Also no invasive procedures were given during practice and the patient was fully aware of the procedures performed at any given time.

Prague, April 2014

Acknowledgement

I would like to thank my family, girlfriend and my friends for their support during my years here in Prague. With their support I could enjoy my stay here and keeping me motivated in all situations.
I will also thank my fellow classmates for the spreading of good spirit around the class.

I would also give my appreciation to my supervisor Mgr. Pavla Kratochvilova at the location of practice for guidance and advices during my whole bachelor practice.

I also have to show my gratitude to Mgr. Katerina Holubova for guiding me through my bachelor thesis and supervision which is much appreciated.

Thank you!

Simen Schei Eikbu
Prague, April 2014

Table of content

1. Introduction

This thesis concerns the theoretical and practical aspects around a patient after total hip replacement due to osteoarthritis. The patient have been under the same procedure before and are now under a rehabilitation program which will focus on returning to a normal ADL. We must assess postoperative problems after the first hip replacement to correct and improve this rehabilitation in relation to earlier therapy programs.

This bachelor thesis is divided into two parts, one general and one special. The general part address the theoretical knowledge of total hip replacement and osteoarthritis. In addition, several sections including anatomy, kinesiology and biomechanics of the hip joint with the clinical presentation of the disease, epidemiology, etiopathogenesis, current therapeutical approaches and prognosis. The purpose of the general part is to give a brief overview of the hip and its functions according to the anatomy and pathologies.

The most important part is the special part where the examination and treatment of the patient is discussed. The examination and therapy is performed using knowledge from our study program in cooperation with teachers, professors, advisors and supervisors. It concludes an evaluation of the therapy after the given therapy with the emphasized results. In addition, the thesis includes a list of used literature, figures, tables and explanations of abbreviations and application to ethics board review in the end of thesis.

2 General Part

2.1 Anatomy and Kinesiology of the Hip joint

2.1.1 Anatomy

The hip joint is a spheroid or ball-and-socket joint formed by the articulation of the acetabulum of the pelvis with the head of the femur (12). Owing to the shape of the two articulating bones, the joint is a special type of spheroidal (ball-and-socket) joint. The roughly spherical femoral head, which as an average radius of curvature of approximately 2.5 cm, is largely contained within the acetabulum (19).

<u>The acetabulum of the hip joint with the femoral head removed</u>

Lateral view. The cartilage-covered articular surface of the acetabulum is crescent-shaped (lunate surface) and is broadest and thickest over the acetabular roof. The lunate surface is bounded externally by the slightly protruding bony rim of the acetabulum, which is extended by a lip (the acetabular labrum) composed of tough connective tissue and fibrocartilage. The cartilaginous articular surface lines much of the acetabular fossa, which is occupied by loose, fibrofatty tissue and is bounded inferiorly by the transverse acetabular ligament in the area of the acetabular notch. The ligament of the head of femur transmits blood vessels that nourish the femoral head (19).

<u>Ligaments</u>

Ligaments are similar to tendons and fascia since they are built up by connective tissue that connects bone to bone. They acts as «helpers» for joint stability and if rifted or torn can cause pain and abnormal joint function (19).

Iliofemoral ligament

The strongest of the three ligaments, the iliofemoral ligament, arises from the anterior inferior iliac spine and fans out at the front of the hip, attaching along the intertrochanteric line. With a tensile strength greater than 350N, it is the most powerful ligament in the human body and provides an important constraint for the hip joint: it keeps the pelvis from tilting posteriorly in upright stance, without the need for muscular effort. It also limits adduction of the extended limb (particularly the lateral elements of the ligament) and it stabilizes the pelvis on the stance side during gait, i.e it acts with the small gluteal muscles to keep the pelvis from tilting towards the swing side (19).

Ischiofemoral ligament

This is a spiral ligamentous band centrally with flat straight bands above and below this central portion. It passes posterior to the hip joint where it blends with the fibrous capsule. The central fibers (superior ischiofemoral ligament) spiral superiorly around the neck of the femur from the posterior surface of the ischium to the medial surface of the greater trochanter of the femur. Arising from the inferior part of the ischium, the lateral and medial inferior ischiofemoral ligaments attach to the neck of the femur and reinforce the posterior aspect of the joint capsule (19).

Pubofemoral ligament

This ligament is attached above, to the obturator crest and the superior ramus of the pubis, it blends with the capsule and with the deep surface of the vertical band of the iliofemoral ligament (19).

Zona orbicularis

The Zona orbicularis lies like a collar around the narrowest part of the neck of the femur. On the inner surface of the capsule it is to be seen as a distinct circular elevation, and externally it is covered by the other ligaments, which partly radiate into it. The head of the femur projects into the zona orbicularis like a button in a buttonhole. Together with the acetabular lip and atmospheric pressure, the zone orbicularis serves as an additional arrangement to maintain contact between the head and the socket (18).

Muscular Anatomy

The anterior group of thigh muscles includes the sartorius, tensor fascia lata, and quadriceps. The quadriceps muscle group consists of the four anterior thigh muscles: rectus femoris, vastus lateralis, vastus intermedius, and vastus medialis. The rectus femoris is the only two orgins of the rectus include a direct head that arises from the anterior inferior iliac spine, and an indirect head that blends with the superior acetabular labrum. The vastus lateralis is the largest of the quadriceps group (4).

Posteriorly, the massive gluteus maximus muscle arises from the posterior gluteal line, iliac crest, and a portion of the posterior surface of the sacrum and coccyx, the tendinosus aspect of the sacrospinous and sacrotuberosus ligament, and the underside of the gluteus aponeurosis. The iliotibial tract crosses both the hip and the knee joints and is thickened between the iliac crest tubercle and the tibia. This band overlies the trochanteric bursa against the greater trochanter to assist in stabilizing the pelvis and abduction of the hip. One fourth of the gluteus maximus tendon inserts directly into the proximal femur to function as the prime decelerator of the hip during gait (4).

The gluteus medius arises from both the external surface of the ilium and the underside of the tensor fascia. The extensive origin of the gluteus medius serves as a powerful anchor for the muscle and maximizes the abductor function by directing

tension laterally along the iliac crest through the fascia latae and iliotibial tract. Although it is a prime abductor, its anterior insertion in the greater trochanter also makes it an internal rotator of the hip. Hip reconstructions that increase the tension of gluteus medius may also cause internal rotation as a result (4).

The gluteus minimus lies beneath the gluteus medius and contributes about one fifth of the abductor power to the hip. The muscle arises from the ilium between the anterior and inferior gluteal lines. the muscle becomes tendinosus over the anterior capsule and inserts partially into the capsule and the anterior portion of the greater trochanter (4).

The piriformis muscle and tendon exits through the greater sciatic notch in a downward oblique direction as it inserts into the piriformis fossa of the greater trochanter. Its location defines the superior and inferior located neurovascular structures that exit through the sciatic notch (4).

The obturator internus tendon exits the lesser sciatic notch from its origin on the inner wall of the pelvis and inserts caudad to the piriformis tendon on the greater trochanter. It is often conjoined with the piriformis tendon. When released, it can be seen to be multibennate on its deep surface, unlikely any other short rotator. The small fleshy muscles of the gemelli lie superior and inferior to the obturator internus tendon (4).

The obturator externus muscle arises from the outer bone and membrane to the obturator foramen and inserts inferior to the obturator internus tendon. The iliopsoas is a combination of the intrapelvic muscles: the iliacus and the psoas major. They function together to flex and externally rotate the femur (4).

2.1.2 Kinesiology

Movements and Muscle Use

Open-chain movements involve stabilization of the muscle origin, concentric concentric contraction, and movement of the muscle insertion. This combination yelds motion of the distal end of the extremity. Many functional movements involving lifting of objects or movement of the hands in carious personal hygiene and home-management tasks use open chain movements.
The phrase open-chain helps differentiate specific movements. Muscles shorten but cannot control whether the proximal or distal attachments move. With the proximal attachment (origin) stabilized, a concentric contraction moves the distal segment in relation to more proximal segments and the trunk. For example, the forearm, whereas the entire upper extremity flexes in relation to the trunk through open-chain shoulder flexion (10).

Closed-chain movements do not follow this scheme. In a push-up or pull-up, the hand, as distal end of the chain, remains stable and the trunk moves in relation to the hand for closed-chain elbow flexion. In a sit-up, the trunk flexes over the hip onto the thigh for closed-chain hip flexion. A deep-knee bend brings the anterior leg to the dorsum of the foot in closed-chain dorsiflexion. In each case the insertion remains stable and the origin moves (10).

As for all other joints, muscles function of the hip according to their relationship with the axes of motion. Flexors concentrically contract anterior to the side-to-side axis, initiating open-chain hip flexion. Flexors include the rectus femoris, sartorius, pectineus, tensor fascia latae and iliopsoas. The posterior hip extensors include the gluteus maximus and hamstrings (biceps femoris, semitendinosus and semimembranosus). Open-chain functions move the thigh in relation to the trunk at the hip joint. The same muscles adjust the verticality of the trunk through their pelvic attachments in closed-chain hip movement (10).

Closed-chain movements play large roles in the lower extremities because weight bearing stabilizes the foot. Each step of gait occurs with closed-chain ankle dorsi flexion and hip extension pulling the body over the grounded foot. To sit upright in bed from a supine position, hip flexors bring the trunk toward the thighs in closed-chain hip flexion. While sitting, gravity´s downward pull on the trunk causes closed chain hip flexion or extension controlled by eccentric constractions of the hip extensors and flexors, respectively. Hip flexors counteract a posterior, extension pull by gravity. When gravity pulls the upper trunk anteriorly, hip extensors are activated and prevent forward movement of the trunk (closed-chain hip flexion). Control at the hip accompanies similar activation in the trunk flexors and extensors (10).

Besides moving the thigh or trunk, hip flexors and extensors influence the lumbar curve. The iliopsoas pulls anteriorly on its origins at the lumbar vertebrae and pelvis ilium to reinforce both the lumbar curve and anterior pelvic tilt associated with food posture. On the opposite side of the hip axis, the hamstrings affect pelvic tilt via their attachments to the ichial tuberiosity. Open- and closed-chain hip abduction and adduction interact with gravity´s pull on the upper body at the hip in the frontal plane. The gluteus medius and minimus, together with the adductor group, the pectineus, gracilis and adductor magnus, longus and brevis maintain lateral stability of the pelvis and trunk over one leg as an individual walks, runs, and perform other movements. They also maintain active sitting balance in side-to-side and diagonal weight shifts. Closed-chain antigravity actions involve the two gluteal muscles pulling the trunk away from the body´s midline, while the adductor group pulls toward the midline. Activation reverses when eccentric contraction control gravity´s effect on the upper trunk (10).

Six small rotator muscles hold the femur firmly in the hip joint just as the rotator cuff muscles of the flenohimeral joint hold the humerus in place. The obturators internus and externus, gemellur superior and inferior, quadratus femoris and piriformis all originate on the lower pelvis and insert onto or near the greater trochanter of the femur. The neck of the femur serves as a long lever arm, allowing the muscles to generate large amounts of torque. Open-chain movements by these six muscles laterally rotate the femur; closed-chain actions contribute to pelvic and trunk balance over the lower extremity.

Open-chain actions of the hip adductors also medially rotate the hip. They vary in length and attach along the shaft of the femur in front of that muscle´s mechanical axis for rotation. Depending on the femur position, hip abductors also have effective movement arms for medial rotation. Together, the medial rotators turn the thigh inward and assist in diagonal balance and weight shifts (10).

Neuroanatomy

The hip and pelvis are innervated by the lumbrosacral plexus. The lumbosacral plexus is formed from the lumbar plexus and the sacral plexus in the abdomen. The lumbar plexus lies in the abdomen and divides into anterior and posterior branches. The main anterior division becomes the obturator nerve, and the posterior division becomes the femoral nerve. The sacral plexus is formed in the pelvis and recieves connections from the fourth and fifth lumbar nerve roots known as the lumbosacral trunk. The posterior branches supply the muscles of the buttock and also form the peroneal portion of the sciatic nerve. The anterior branches contribute major supply to the tibial portion of the sciatic nerve. The tibial portion of the sciatic supplies the muscles of the thigh, calf and foot (4).

The superior and inferior gluteal nerves arise from posterior divisions of the lumbosacral plexus. The superior gluteal nerve passes through the greater sciatic notch, above the piriformis. It the coruses deep to the gluteal medius. The inferior gluteal nerve passes through the notch with the sciatic nerve to the lower edge of the piriformis to enter into the gluteus maximus.

The posterior femoral cutaneous nerve (lesser sciatic nerve) arises from the sacral plexus and travels deep to the piriformis to supply skin of the lower buttock and posterior thigh (4).

2.2 Biomechanics of the Hip Joint

The hip is one of the largest and most stable joints in the body. If it is injured or exhibits bathology, the lesion is usually immediately perceptible during walking. Because pain from the hip can be referred to the sacroiliac joints or the lumbar spine, it is imperative, unless there is evidence of direct trauma to the hip, that these joints be examined along with the hip (3).

The hip joint is a multiaxial ball-and-socked joint that has maximum stability because of the deep insertion of the head of the femur into the acetabulum. In addition, the hip, like the shoulder, has a labrum, which helps to deepen and stabilize the hip. It has a strong capsule and very strong muscles that control its actions. The acetabulum is formed by fusion of part of the ilium, ischium and pubis, which taken as a group are sometimes called the innominate bone or pelvis. The acetabulum opens outward, forward, and downward. It is half of a sphere, and the femoral head is two thirds of a sphere (3).

<u>The axes of motion in the hip</u>

As a spheroidal joint, the hip has three principal axes of motion, all of which pass through the center of the femoral head (the rotational center of the hip) and are mutually perpendicular. Accordingly, the joint has three degrees of freedom allowing movement in six principal directions:

1. Transverse axis: Flexion and Extension
2. Sagittal axis: Abduction and Adduction
3. Longitudinal axis: Internal rotation and external rotation (19).

Active Movement	Degree
Flexion	110-120
Extension	10-15
Abduction	30-50
Adduction	30
Internal rotation	30-40
External rotation	40-60

Table 1 Movements of the hip

The hip, already a stable joint because of its bony configuration, is supported by three strong ligaments: the iliofemoral, the ischiofemoral, and the pubofemoral ligaments. The ilifemoral ligament is considered to be the strongest ligament in the body. It is positioned to prevent excessive extension and plays a significant role in maintaining upright posture at the hip. The ischiofemoral ligament, the weakest of these three strong ligaments, winds tightly on extension, helping to stabilize the hip in extension. The pubofemoral ligament prevents excessive abduction of the femur and limits extension. All three ligaments also limit medial rotation of the femur.

Under low loads, the joint surfaces are incongruous; under heavy loads, they become congruous, providing maximum surface contact. The maximum contact brings the load per unit area down to a tolerable level. Depending on the activity, the forces exerted on the hip will vary (16).

Gait analysis

A normal walking pattern requires hip motion in the sagittal, frontal, and horizontal planes. In the sagittal plane, about 10 to 20 degrees of hip extension is required at terminal stance and 30 degrees of hip flexion is required at the end of swing phase and the beginning of stance phase as the limb is advanced forward to take the next step. With the feet fixed on the ground, the femoral heads can act as fulcrum for the pelvis as it tilts anteriorly and posteriorly. The pelvis can also tilt laterally, causing the iliac crest to move either superiorly or inferiorly. Lateral tilting of the pelvis occurs when

one leg is off the ground, the hip joint of the supporting leg acts as a fulcrum, and the tilting results in relative abduction and adduction at the hip joints. When walking, there is a lateral tilt of the pelvis inferiorly on the unsupported side during the swing phase of the gait cycle. This dropping of the pelvis on the unsupported side results in abduction at the hip on the same side. As the pelvis drops, the inferior aspect of the pelvis moves toward the femur of the stance leg, producing hip adduction on this side. About 7 degrees of hip abduction is required at initial swing, and 5 degrees of hip adduction is required at the end of the stance phase of the gait cycle (6).

Pelvis rotation occurs in the horizontal plane about a vertical axis. Rotations of the thigh occur relative to the pelvis. As the swinging leg advances during locomotion, the pelvis rotates forward on the same side. The fulcrum for this forward rotation of the pelvis is the head of the femur on the supporting leg. As the supporting or stance leg is fixed on the ground, the pelvis rotates around the femoral head, resulting in internal rotation at the hip joint. As the pelvis moves forward on the swing side, the swinging leg moves forward in the sagittal plane in the line of progression, resulting in external rotation of the hip during the swing phase of the gait cycle. During the normal gait cucle about 5 degrees of internal rotation and 9 degrees of external rotation are required at the hip joint. External rotation occurs at the end of the stance phase and through most of the swing phase, and internal rotation occurs at terminal swing before initial contact to the end of the stance phase (6).

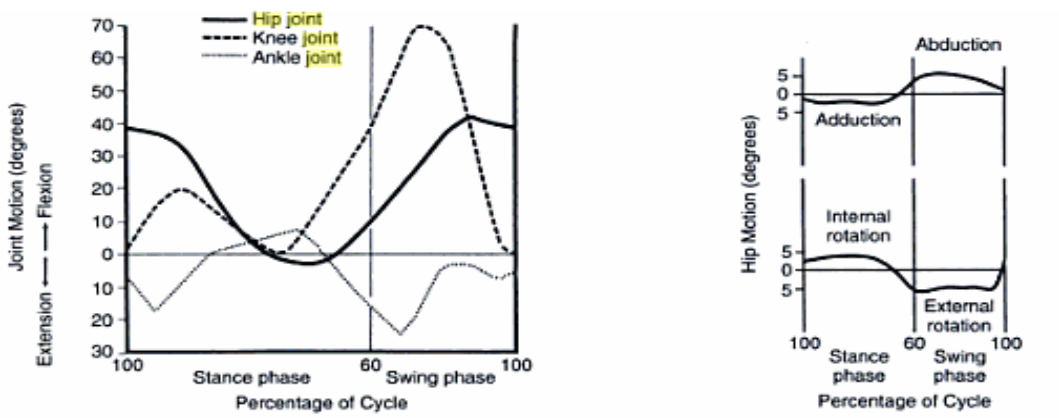

Figure 1 Hip joint movement during gait

Activity	Average Range of Motion Necessary
Shoe tying	120 of flexion
Sitting (average seat height)	112 of flexion
Stooping	125 of flexion
Squatting	115 of flexion /20 of abduction / 20 of internal rotation
Ascending stairs (average stair height)	67 of flexion
Descending stairs (average stair height)	36 of flexion
Putting foot on opposite thigh	120 of flexion / 20 of abduction / 20 of external rotation
Putting on trousers	90 of flexion

Table 2 Range of motion necessary at the hip for selected activities

Loads on the right hip joint during the stance phase of gait

Anterior view. In one-legged stance or during the stance phase of gait, the partial-body center of gravity is shifted towards the opposite swing side so that the partial body weight acts along a line that runs medial to the hip joint. This eccentric load produces a rotational moment, or torque, which tends to tilt the part of the body above the joint toward the side of the swing leg. To maintain stable balance, a counterforce must be applied (e.g., muscles and ligaments) that is sufficient to counteract the torque. In the hip joint, this force is supplied mainly by the muscular force of the hip abductors (gluteus medius and minimus). This force, however acts upon the hip joint with a lever arm that is only about one-third the lever arm of the muscular force to that of the partial body weight is approximately 1/3. Consequently, the muscular force needed to stabilize the hip in one-legged stance is equal to about three times the body weight. This means that the compressive force that the hip joint must be able to withstand

(e.g., during walking) is approximately four times greater than the partial body weight (according to Pawels). As a result, the hip joint is constantly subjected to extreme loads which predispose the joint to osteoarthritic changes (19).

Position	Percent body weight
Standing	0.3 times the body weight
Standing on one limb	2.4 to 2.6 times the body weight
Walking	1.3 to 5.8 times the body weight
Walking up stairs	3 times the body weight
Running	4.5 + times the body weight

Table 3 Position and bodyweight

Actions of the ligaments as a function of joint position

a) Right hip joint in extension, lateral view. The capsular ligaments of the hip joint form a ringlike collar that encircles the femoral neck. When the hip is extended, these ligaments become twisted upon themselves, pushing the femoral head more firmly into the acetabulum (joint stabilizing function of the ligaments)

b) Lateral view. During flexion the ligament fibers are lax and press the femoral head less firmly into the acetabulum, allowing greater degree of femoral mobility.

c) The twisting mechanism of the capsular ligaments can be represented by a model consisting of two disks interconnected by parallel bands. When one of the two disks rotates, the bands become twisted and draw the two discs closer together. When the ligaments are no longer twisted, the distance between the two disks increases (19).

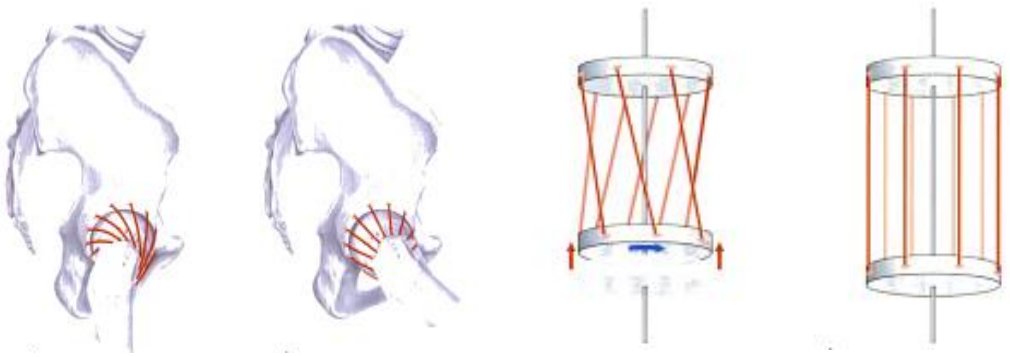

Figure 2 Actions of the ligaments as a function of joint position

2.3 Disease

Hip osteoarthritis

We know less about the prognosis of hip osteoarthritis than we do about the knee, even though it is one of the most common areas of involvement. Hip joint degeneration occurs at a rather early age (around 40) in individuals born with a abnormal geometry of the hip such as dysplasias of either the acetabulum or the femur. These congenital abnormalities result in hip osteoarthritis from an abnormal hip joint at an early age.

For individuals who develop hip disease later in life, the outcome can be favorable or progressive. As with knee osteoarthritis, the degree of joint degeneration depends on the rate of articular cartilage loss. Pain from hip osteoarthritis is highly individualized in that a person can experience pain with very little joint space loss or when the joint space is nearly gone. Generally, as hip disease worsens, walking becomes painful and the hip is painful at night. Use of pain medications and a cane can help for a while, but over time the pain becomes worse and the hip joint needs to be replaced (13).

The rate in which hip osteoarthritis progressive is not well-known. The few studies performed suggest that weight-bearing activities and physical labor increase the rate of joint degeneration in the hip. Low blood levels of vitamin D are also associated with hip joint degeneration. However, unlike knee osteoarthritis, patient with hip disease usually come to their doctor with a more advanced form of osteoarthritis and pain. Therefore, it is often just a matter of a year or two before they require a joint replacement. Studies performed in Europe found that nearly 60% of patients had a hip replacement within one or two years of first seeing their physician (13).

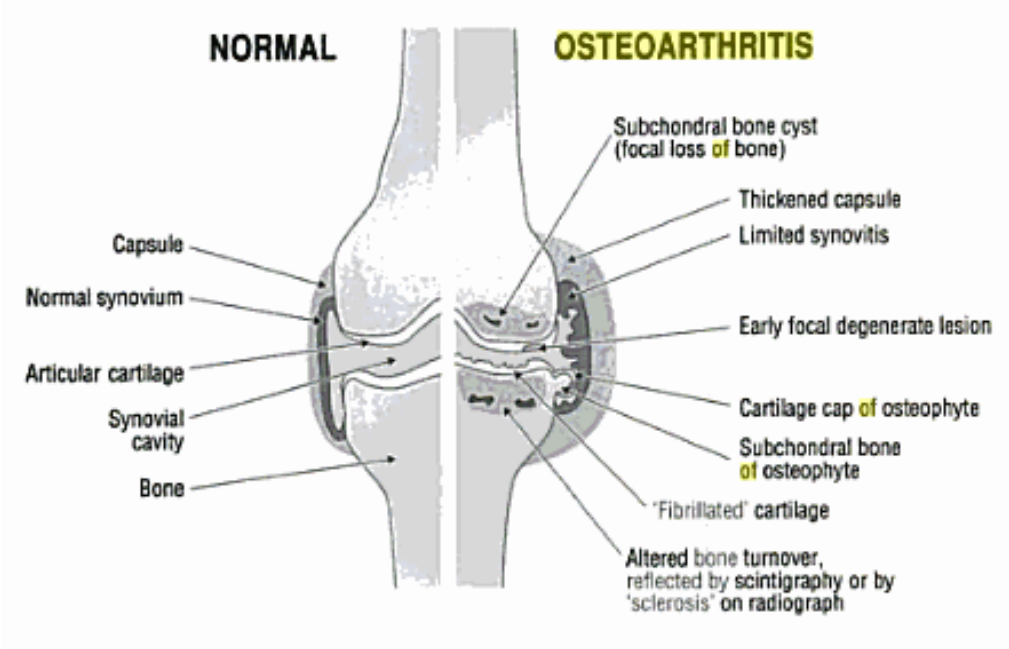

Figure 3 Hip Osteoarthritis

Symptoms	Signs
Pain	Discomfort or abnormality with motion
Stiffness	Limitation in stamina or endurance
Swelling	Color changes
Achy muscles or joint	Swelling
Fatique	Warmth or tenderness to touch
Weakness	Crepitation
Deformity	Abnormal posture or gait

Table 4 Signs and symptoms associated with osteoarthritis

Developing Osteoarthritis

Osteoarthritis is like many chronic diseases. With heart disease, for example, narrowing of the arteries begins many years before a patient develops chest pain, the chief symptom of atherosclerotic heart disease. A doctor evaluates the coronary arteries of someone with chest pain to find out how much narrowing is present. Osteoarthritis is very similar to heart disease in that articular carticage begins to degenerate silently, and it is many ears after this process has begun that a patient develops joint pain and consults a doctor. When the joint pain begins there is usually irreversible cartilage damage. However, the amount of cartilage damage at the time joint pain develops varies with each person. Some people do not develop joint pain until all of the articular cartilage has been destroyed, while others develop it very early in the disease process. However, by the time someone develops joint pain, cartilage damage has already begun.

Once joint pain from osteoarthritis begins, the course is also variable. In some people the remaining cartilage is rapidly destroyed, their joint pain becomes very severe, and they need to have a joint replacement. However, other individuals may develop pain from osteoarthritis that remains very mild for many years. All of the reasons why joints degenerate at different rates is not known, but it is the subject of intense research today. This chapter will review the principal symptoms and signs of osteoarthritis, and contrans them with other rheumatic processes which can coexist or be confused with the disorder (13).

The clinical presentation of Osteoarthritis

Osteoarthritis of a joint or a number of joints has characteristic signs and symptoms. Usually, osteoarthritis sufferers are mature adults, aged 50 or more before symptoms start to appear. However, osteoarthritis symptoms can appear much earlier if the patient has previously injured a joint. Patients with osteoarthritis will usually experience joint pain during or after joint use. For example, if you have hip osteoarthritis the joint will be painful when walking and sometimes afterwards, but not before walk. Often one will experience a few minutes of joint stiffness and pain when

arising in the morning. This usually goes away in a few minutes. One may also notice that joints swell up a little bit after using them awhile or overusing them. These are the most common symptoms of osteoarthritis.

If a joint is swollen, then the doctor may aspirate some joint fluid. The joint fluid from someone with osteoarthritis usually has a few hundred inflammatory cells or some crystals, and is otherwise normal. If blood tests are taken to try to find out if someone has another type of arthritis, the blood tests should be normal (13).

2.3.1 Epidemiology

The total number of total hip replacements performed annually has grown dramatically over the past 20 years. The estimated number of procedures performed annually in the United States grew from 80,000 in 1976 to 125,000 in 1993. The utilization rate of these procedures per 100,000 persons per year is similar to rates from Scandinavian countries. It is estimated that 300,000 to 400,000 total hip replacements were performed worldwide in 1985. The greatest incidence of total hip replacements is in patients between the ages of 65 and 79. Variations in usage exist by geographic location, age, sex and race. The highest rates of utilization were found in the Northwest and Midwest, and the lowest rates were in the East and South. Approximately 65% of recipients are female. There is also a higher prevalence of these procedures in Caucasians and in those with a higher income (7).

2.4 Etiopathogenesis

Osteoarthritis.

Osteoarthritis is a condition that represents a pathological imbalance of degradative and reparative processes involving the whole joint and its component parts, with secondary inflammatory changes, particularly in the synovium, but also in the articular cartilage itself. Idiopathic primary OA may involve one particular joint, or it may be generalized or involve multiple joints in erosive inflammatory forms. The presentation of this pathological condition in joints may be a consequence of the biomechanics within the joint which reveal otherwise masked systemic genetically determined changes. The mechanical pressure within the joint may therefore reveal weaknesses in tissue maintenance that are more widespread than previously considered. Most forms of OA fall into two categories, depending on the predominant background: those that are primary, and often idiopathic, with abnormalities of joint biomaterial and biomechanically faulty joint structure that may result from recognizable mutation, and those that are secondary and result from superimposed risk factors affecting distribution and severity of loading forces acting on specific joints, such as joint injury (17).

2.5 Current Therapeutic Approaches

The goal of any rehabilitation program following total hip replacement is not only to maximize the patient´s functional status with respect to mobility and activities of daily living but also to minimize postoperative complications. In addition, medical and nursing personnel must be vigilant in preventing iatrogenic complications such as sacral and heel decubiti, tape burns, and the adverse effects of drug interactions. Use of narcotic analgesics, parenteral iron, and prolonged bed rest may be the basis of which severe constipation may develop, particularly in the elderly, and it should be guarded against, as should other deleterious effects of prolonged immobilization. Finally, the rehabilitation program, no matter what the setting, should provide the basis for a safe return to the home setting, allow resumption of premorbid activities, and integrate patients back into the social fabric of their communities (7).

In hip replacement surgery, the femoral head and the acetabulum are replaced by a metal stem and head, and a plastic acetabular component. Variations of this basic design include alternative joint surfaces made of ceramics and other materials. The femoral stem can be cemented or «press fit» in the place. Hip replacement is highly effective in relieving pain and improving function. The mean implant life is from 10 to 20 years. The surgery indicated in any person with advanced hip disease that is refractory to conservative management, and who has low to moderate surgical risks. Those with uncomplicated surgery and cemented components can start full weight bearing the day after surgery, and progress rapidly to independent ampulation and discharge. Non-cemented components traditionally require delayed weight bearing, although recent studies challenge this notion. Revision surgery (to place the old implant) and surgery involving femoral osteotomies or intraoperative complications require more prolonged rehabilitation (3).

Most hospitals now have established standard protocols for the rehabilitation of patients with an uncomplicated hip replacement. Typical programs start with a preoperative visit to assess the patient´s situation, clarify expectations, and instruct patients on a home exercise program (with emphasis on hip muscles and the

quadriceps) and necessary environmental modifications to allow discharge as soon as possible. In the postopereative period, activity training progresses rapidly from bed to chair transfers to standing, and then to ambulation with aids and chair climbing. Rehabilitation continues at home with the assistance of relatives or community care providers. The rehabilitation approach to those who require more prolonged rehabilitation in an inpatient facility is the same, but the progression from one stage to the next is slower. The complication of hip replacement surgery are well known, and the rehabilitation program includes measures to prevent falls, deep vein thrombosis, hip dislocation, wound infection, and dehiscence. Nerve palsies of the sciatic or common peroneal nerves sometimes complicate hip replacement surgery and can require use of an ankle-foot orthosis (3).

Delayed complications include septic arthritis, aseptic loosening of the implant, heterotopic ossification, and premature implant failure. The usual posterolateral surgical approach requires postoperative hip precautions to avoid hip dislocation. They include avoiding hip flexion beyond 90 degrees, and adduction and internal rotation. Twisting of the trunk when getting up from the toilet or a car seat, or trying on shoes are typical risk activities. A postoperative abduction pillow or hip abduction brace is used in some centers (3).

Rehabilitation goals

1. To restore back the hip and knee movements to normal or at least obtain the functional range.
2. To improve and regain the strength of the hip flexors, extensors, adductors, abductors, internal and external rotators, quadriceps and hamstrings group or muscles.
3. To attain the functional if not normal limits of hip and knee movements.
4. Return to previous ADL (8).

	Knee				Hip			
Movements	Flexion	Ext	Fl	Ex	IR	ER	Ad	Ab
Normal	135-140°	0°	125-130°	0-20°	40-45°	45°	40-45°	45-50°
Functional	110°	0°	90-110°	0-5°	0-20°	0-15°	0-20°	0-20°

Figure 4 Functional range of hip and knee motion

Active postoperative therapy starts from day 1, remembering that the abduction pillow or wedge should remain in situations where the patient is lying supine or on the non-operated side. Also, the patient should be discouraged from performing a straight leg raise on the operated side until full qudriceps and iliopsoas control has returned. The treatment goals at this time do not differ greatly from those of a patient following a fracture around the hip. These are: (1)

- Restoration of:
- Joint motion: Hip extension, abduction and rotation are all lost preoperatevly therefore these are the most important to start re-educating.
- Muscle strength: hip abductors, extensors and rotators in particular, but hip flexors must also be strengthened for climbing a stair or step or for putting on a shoe. Quadriceps and hamstrings activity should also be encouraged.

- Maintenance of:
- Vascular function: Foot and ankle pumps, quadriceps activity and deep breathing will all help.
- Respiratory function.

- Education about:
- Joint preservation techniques to prevent dislocation, loosening and fracture.
- Bed mobility
- Weight bearing: gait and sitting to standing (1).

Post isometric relaxation (Lewit)

In the case of total hip replacement, muscles or muscle group around the hip can become hypertonic due to overcompensation and/or overloading. The explanation if the excellent results furnished by this method may be sought in the fact that during resistance of minimal force only very few muscle fibers are active, the other remaining inactive, while during relaxation the stretch reflex is avoided, a reflex which is brought about even by passive and non-painful stretch. After the procedure, there is analgesia. This method demonstrates very clearly the close interrelation between tension and pain, and relaxation and analgesia (14).

PNF

The goal of proprioceptive neuromuscular facilitation is to promote functional movement through facilitation, inhibition, strengthening and relaxation of muscle groups. The techniques use concentric, eccentric, and static muscle contraction. These muscle contraction with properly graded resistance and suitable facilitatory procedures are combined and adjusted to fit the needs of each patient.
For hip replacement patients we can use PNF relaxation techniques such as contraction-relaxation and hold-relaxation. Since there is contraindicated movements after total hip replacement in adduction, internal and external rotation, hyperextention and flexion above 90 degrees in the hip joint we can perform PNF gradually avoiding these movements (14).

Muscle strengthening

Muscle strengthening programs after total hip replacement must respect surgeon-imposed restrictions, as well as tissue healing and pain. This is achieved by starting with exercises that place the least amount of stress on the joint and soft tissue envelope, progressing to functional activities. A progression of isometrics followed by isotonic antigravity activities, such as knee extension exercises, then progressing to

pulleys, weights and elastic resistance bands is recommended. Closed-chain activities, such as step-ups and mini-squats, allow for a progression to functional ADLs and recreational activities. These activities most often involve some degree of weight bearing and muscle co-contractions, which often adds to joint stability (5).

Most exercise programs begin with safe range of motion activities and muscle strengthening exercises. Patients should avoid high-impact activities, such as basketball, running, and tennis. These activities can damage the replacement or cause loosening of its parts.
Some recommended exercises are low impact such as cross-country skiing, swimming, walking, and stationary bicycling. These exercises can increase muscle strength and cardiovascular fitness without injuring the new hip. Some specific exercises are ankle pumps, ankle rotations, buttock contractions, standing hip abduction, straight leg raises. Postural exercises will be incorporated into the program to keep the back and head well aligned and preclude unnecessary stresses on the back as a result of the surgery (21).

Prevention of Thromboses

One of the most common causes of severe complications after joint athroplasty is the formation of intravascular blood clots, which generally form in the deep veins of the legs and can cause severe complications if they embolize to the lungs, resulting in a PE, which is one of the most common causes of death after lower extremity athroplasty. Elastic compression stockings are traditionally used as an adjunct to other methods because other treatment methods have been found to be more effective. At a postoperative state, the patient is usually weak and need bed rest. During this state it is important to move the lower extremity such as dorsal, plantar and circumduction of the ankle joint. This will also be an important aspect of prevention of thrombosis (5).

Manual Therapy

Soft tissue manipulation involves restoration of mechanical function of the soft tissue with its elasticity and mobility relative to other tissues or tissue layers. To understand the importance of soft tissue we have to bear in mind that the motor system is embedded in soft tissue layers, and that even muscles and muscle fibers have their sheaths of connective tissue (14). After total hip replacement soft tissues around the operated area may involve restriction, so as to restore it we can perform skin stretching and shifting of deep fasciae.

Manipulation can be performed to restore normal mobility mainly of joints, including joint play, but also mobility between soft tissue layers, or soft tissue and bone. After total hip replacement other joints than the hip can be restricted, such as knee, ankle, spine and so on (14).

Thermotherapy

Application of thermotherapy is used for a vasomotoric effect which causes myorelaxation and spasmolytc effect. If a patient after total hip replacement has pain, which in most cases there is, it will also have an analgetic effect. Another therapeutic effect is that heat increases the extensibility of collagen tissues while decreasing joint stiffness, reduction of inflammation, edema. We find this procedure effective since in increases blood flow to affected area who will provide proteins, nutrients and oxygen for more efficient healing process (11).

2.5.2 Pharmacotherapy

Osteoarthritis is the most common form of arthritis. Weight-bearing joints are most suspectible, but non-weight-bearing joints, especially the hands, may also be involved. Because of its high prevalence and involvement of joints critical for daily functioning, the disease causes tremendous morbidity and financial burden. OA is the leading cause of chronic mobility disability and the most common reason for total-hip and total-knee replacement.

Anaesthesis for total hip replacement should provide stable intra-operative conditions and allow rapid patient recovery. Analgesic technique should aim to provide optimal pain relief whilst minimizing side effects such as sedation, post-operative nausea and vomiting. Regional anaesthetic techniques have been shown to offer several advantages over general anaesthesia for this type of surgery. Venous thromboembolic complications are reduced by 50% when ventral neuraxial block is compared with general anaesthesia in patients who have not received antithrompotic prophylaxis (9).

Prior to surgery, patients should receive both mechanical (suquential compression devices) and pharmacologic DVT prophylaxis. Examples of preoperative and postoperative pharmacotherapy include warfarin, subcutaneous heparin, and low molecular weight heparin. Pharmacotherapt should be held at midnight prior to surgery to avoid surgical bleeding (15).

2.6 Prognosis

Total hip replacement is considered one of the most successful procedures for alleviation of pain and restoration of hip function, with good to excellent results reported in over 90% of cases. The experience of the past two decades has contributed to a significant improvement in prosthetic design, materials, cementation and the surgical technique of total hip replacement. Unfortunately, postoperative complications still exists in a minority of patients. The most common complications are thromboembolic disease, dislocation, aseptic loosening, osteolysis, and postoperative sepsis. In 1992, the Health Care Financing Center reported the incidence of postoperative infection after total hip replacement to be 1% to 2% in the Medicare patient population.

Treatment with antibiotics alone is rarely successful in the treatment of an infected total hip replacement, this modality may be considered in a small group of patients that are not able to tolerate surgical intervention (2).

3. Special Part

3.1 Methodology

In the special part there will be focus on my patient´s rehabilitation after total endoprotesis of the hip after the diagnosis coxarthritis. The rehabilitation took place at Klinika rehabilitačního lékařství Vinohrady starting 28.01.2014 where the patient attended therapy sessions one to two times a day until 31.01.2014. The duration of the sessions were from 30-60 minutes each depending on the patients physical state and time of day. The patient continued rehabilitation after I finished my bachelor practice which was going to last for 2 more weeks.

For examination of the patient we used muscle length test and goniometry for assessment of ROM according to Janda. Manual muscle testing was done by using techniques according to Kendall. We used hot roll as soft tissue therapy for pain relief and muscle relaxation. Gait examination and exercise was done to improve stability and weight distribution as well as improving stability and efficiency.

At the therapy we used several different techniques to improve functional and structural segments in the patients body. For improvements of soft tissues around the scar we used pressure, C-shape and S-shape motions to increase soft tissue flexibility and reduce swelling, redness and irritability. Fascia stretching was done according to Lewit also for improvement of soft tissue mobility where it was restricted. A combination of stretching, mobilization of blocked joints and post isometric relaxation was used in the sessions after the patients physical assessment was set. Stretching was performed by the patient after educating her on how, where and when it should be done.
For several exercises we used equipment such as overball, stonepit (for proprioception), therabands for both strengthening and stretching. Soft mats and therapy table for a softer and firm surface.

For the patients confidentiality she received a content form and approval by the ethics committee which are found in content 6 (supplement).

3.2 Anamnesis

Examined person: D. B (female)
Date of birth: 1961
Diagnosis: Z966 (Total endoprosthesis hip)

Height 169
Weight 92kg
BMI 32.2

Status presens:

The patient comes in with axillary crutches. She is orientated about her operation and rehabilitation. She does not have pain during walking or sitting. Sudden movements cause pain. She has been under the same procedure with the right hip before.

Anamnesis/History:

Chief complained:

The patient have been diagnosed with arthrosis 6 years ago and 1,5 years ago was the worst time due to the pain. She got pain relief injections after the diagnosis. 6 years ago they told her that she had to stand the pain as long as possible without surgical approach. June last year she got to know that she had to have an operation. Have had problems in left hip for 5 years, has been putting more weight on right leg causing muscle imbalance and faulty postural alignment.

History of injury:

Total endoprotesis left hip for coxarthitis January 10. 2014
Hypertensive disease on medication.
Arthroscopic meniscus surgery on both knees in 2006
Fracture of metatarsal bones in childhood
Elbow dislocation in childhood

Operation:

Total hip replacement left hip 10. Jan 2014

Family history:

On father side is unknown if there is any sign of diseases.
Both daughters and her mother are healthy

Medical history:

Aulin for pain
Injections for pain

Drugs:

Moduretic tbl 1/2-0-0
Xarelto 10mg 1 tbl at 20:00
Aktiferrin cps 1-0-1
Hypnogen tbl for insomnia

Allergies:

PNC
Jod

Abuses:

Smoking 3 cigarettes per day
Alcohol: occasionally

Occupation

Executive secretary (administrative) sits 6 hours/day

Sport history:

Walking
Biking at home (stationary)

ADL:

Lives with her family in an apartment with elevator with mother and 2 daughters, on 2 floor. Takes the elevator

Previous rehabilitation:

Rehab of lumbar spine pain 20 years ago, pain which radiates to left hip. The effects were variable before and after first total hip replacement.

Doctors anamnesis

Indication of rehabilitation:

- Kinesiological analysis, measurements of lower extremities
- Goniometry hip and knee
- Muscle strength test on operated hip
- Breathing gymnastics localized breathing
- Mobilization for peripheral joints and chest
- Isometric exercises abdominal, gluteal muscle, M.quadriceps, abductors of hip
- Fitness exercises, theraband on non-operated leg
- Active and passive exercises on lower extremity to improve mobility of the operated hip observing - Antiluxation principles
- Verticalization - the practice of correct walking stereotype.
- Strengthening devices - bicycle, booster seat
- Occupational therapy - self-care aids with compensation

3.3 Initial Kinesiologic Examination

Examinations were performed January 28, 2014.

3.3.1 Posture Examination

* Posture examination were performed without crutches.

Posterior view

- Flatfoot both legs
- Narrow stance
- Slight external rotation right leg
- Left popliteal fossa higher
- Right infragluteal line lower
- Atrophy right hamstrings
- Pelvis tilted to the right
- Left arm resting on hip
- Whole spine shifted right for plumbline
- Scoliosis dextra Th 1/2 - Th 10/11
- Head slightly lateroflexed and rotated to the left

Lateral view - Right

- Loads lower extremity frontal
- Semiflexion right knee
- Pelvis in anteversion
- Th10 in lordosis
- Flat back C7-Th9
- Kyphosis C spine
- Protraction of head

Lateral view - Left

- The same readings as right side

Anterior view

- Slight external rotation left knee
- Atrophy right quadriceps
- Umbrilicus and trunk shifted right for plumbline
- Left arm rests on pelvis
- Right arm hanging freely
- Left shoulder depressed
- Whole body shifted to the right
- Head slightly shifted to the right

Two scale test

Right: 52kg
Left: 40kg

3.3.2 Gait Examination

* Gait examination were performed with axillary crutches

- Short stance on the left leg (about 10-15cm)
- No curling of toes
- Slight ER both lower extremities
- No extension of both hip joints
- Puts more pressure on right leg
- Whole body shifts to the right side
- Stiff trunk

3.3.3 Pelvis examination

Crests: Left side higher

Psis: Higher on left side

Asis: Higher on left side

Results: Pelvis rotated clockwise with left side elevated

3.3.4 Circumference measurements

Measured	Right (cm)	Left (cm)
Calf	39	39
Knee	40	40
Over head of fibula	37	37
Thigh (15cm above patella)	54	53
Ankle	26	26
Over head of metatarsals	24	24.5

Table 5 Circumference measurements

3.3.5 Range of motion

Movement	Results Right	Results Left
Ankle joint Active		
Plantar Flexion	42	41
Dorsal Flexion	20	20
Ankle joint Passive		
Plantar Flexion	48	45
Dorsal Flexion	25	25
Knee joint Active		
Flexion	90	100
Extension	0	0
Knee joint Passive		
Flexion	95	105
Extension	0	0

Hip joint Active		
Flexion	105	60*
Extension	/	/
External rotation	45	/
Internal rotation	10	/
Abduction	45	25
Adduction	/	/
Hip joint Passive		
Flexion	105	85*
Extension	/	/
External rotation	45	/
Internal rotation	10	/
Abduction	45	30
Adduction	/	/

Table 6 Range of motion

All movement examinations were performed in lying position.

* - Movement which caused pain.

3.3.6 Movement pattern according to Janda

Movement pattern	Result
Hip abduction Left	Tensor and quadratus mechanism
Hip abduction Right	Tensor mechanism

Table 7 Movement patterns according to Janda

3.3.7 Neurological Examination

Light Touch Sensation

Tested Dermatome	Result Right	Result Left
L2 - Medial thigh	Feel touch	Feel touch
L3 - Medial knee	Feel touch	Feel touch
L4 - Medial ankle, 1 toe	Feel touch	Feel touch
L5 - Dorsum of foot	Feel touch	Feel touch
S1 - Lateral foot	Feel touch	Feel touch
S2 - Posteromedial thigh	Feel touch	Feel touch

Table 8 Neurological Examination

Deep Movement Sensation

Tested Direction	Result Right	Result Left
Toe Flexion	Feel direction and position	Feel direction and position
Toe Extension	Feel direction and position	Feel direction and position
Toe Abduction	Feel direction and position	Feel direction and position
Toe Adduction	Feel direction and position	Feel direction and position
Plantar Flexion	Feel direction and position	Feel direction and position
Dorsal Flexion	Feel direction and position	Feel direction and position
Inversion	Feel direction and position	Feel direction and position
Eversion	Feel direction and position	Feel direction and position
Knee Extension	Feel direction and position	Feel direction and position
Knee Flexion	Feel direction and position	Feel direction and position

Hip Extension	Feel direction and position	Feel direction and position
Hip Flexion	Feel direction and position	Feel direction and position
Hip Internal Rotation	Feel direction and position	Feel direction and position
Hip External Rotation	Feel direction and position	Feel direction and position
Hip Abduction	Feel direction and position	Feel direction and position
Hip Adduction	Feel direction and position	Feel direction and position

Table 9 Deep movement sensation

Deep tendon reflexes

Reflex	Grade Right	Grade Left
Patellar	2b	2b
Achilles	2	2

Table 10 Deep tendon reflexes

3.3.8 Scar Examination

Inspection: The scar looks good. It is a closed scar but there is some redness and swelling around scar. We can see a slight hypertrophy around the distal part of the scar.

Palpation: There is a slight restriction in movement around the scar in the distal part. The restriction is in all direction.

3.3.9 Muscle strength testing according to Kendall

Muscle	Grade Right	Grade Left
Tibialis Anterior	4	4
Soleus	4	4
Gastrocnemius	5	5
Peroneus Longus	5	5
Vastus Medialis	5-	4-
Vastus Lateralis	4+	4-
Rectus Femoris	5-	4
Iliopsoas	4	3
Biceps Femoris	4-	3+
Semimembranosus	4	3
Semitendinosus	4	3+
Tensor Fascia Latae	3/4	3-
Adductor Longus/Magnus	3/4	3/4
Gluteus maximus	3	3
Gluteus medius	3	3
Gluteus minimus	3	3
Flexor digitorum longus	4	4-
Extensor digitorum longus	4	4
Flexor hallucis	4/5	4/5
Extensor hallucis	4	4-

Table 11 Muscle strength testing according to Kendall

3.3.10 Palpation

Muscle	Result Right	Result Left
Soleus	Hypertone	Slight hypertone
Gastrocnemius	Hypertone	Slight hypertone
Tibialis anterior	Normal	Normal
Semimembranosus	Hypertone	Hypertone
Semitendinosus	Hypertone	Hypertone
Biceps femoris	Hypertone	Hypertone
Vastus medialis	Hypotone	Hypotone
Vastus lateralis	Normal	Normal
Rectus femoris	Hypertone	Hypertone
Tensor fascia latae	Hypertone	Hypertone
Gluteus maximus	Hypotone	Hypotone
Gluteus minimus/medius	Hypotone	Hypotone
Iliopsoas major	Hypertone	Hypertone
Erector spinae	Slight hypertone	Slight hypertone
Trapezius	Upper hypertone	Lower hypertone

Table 12 Palpation

Palpation of fascia and skin

Shifting the deep gluteal fascia from above: Restricted Left and Right

Shifting the Lumbodorsal fascia upwards: Restricted Left and slightly restricted Right

Kiblers Fold

- Restriction in Th-L junction on both sides

3.3.11 Examination of joint play according to Lewit

Joint	Result Right	Result Left
Phalanges	No blockage	No blockage
Metatarsophalangeal	No blockage	No blockage
Chopart	No blockage	No blockage
Listfranc	No blockage	No blockage
Talocrural	No blockage	No blockage
Fibular head	Blocked ventral direction	Blocked ventrodorsal direction
Knee Lateral gapping	No blockage	No blockage
Knee Medial gapping	No blockage	No blockage
Patella	Blocked in all directions	Blocked in medial + craniocaudal direction
Lumbar spine (springing)	Blocked L2 and L3	
Lumbar spine into retroflexion	Blocked L2 and L3	

Table 13 Examination of joint play according to Lewit

Conclusion of examination

In the posture examination we could clearly see that the patient have shifted whole body towards the right side. The feet were atrophic especially on the right thigh and a narrow stance. Patients pelvis was elevated on the left side with a clockwise rotation. The whole trunk was shifted toward the healthy leg in addition to scoliosis in whole Th spine. Head of patient was retracted causing a kyphotic position and retraction of the head.

In gait examination the patient used axillary crutches. She had a short stance on each leg (about 10-15cm) with no extension on both hips. We could see a clearly shifted center of gravity towards the healthy leg. Her trunk did not move too much.

The scar of the patient was better than expected but with some redness and swelling around the distal part, also some restricted movements of soft tissue around.

In Range of motion we could clearly see a difference from left and right lower extremities. Her left hip was restricted movement in all direction compared with the right leg which was better. Both knees were restricted in extension. There was no significant difference from passive to active movement.

We examined movement patterns of hip abduction which was worse on the left leg causing a tensor and quadratus mechanism in early movement.

The neurological examination did not show any unusual or pathological findings. Muscle strength test showed a clear weakness of both abductors, adductors and extensors of both hips.

We found blockage in joint play of fibular head and patella on both lower extremities. The worst blocked fibula was on the left leg, and worst patella was on right leg.

In palpation examination we could find hypertonicity in both hamstrings and more atrophy in quadriceps. There was a slight difference in hypotonic muscles on right leg compared to a less hypotonic left leg.

3.4 Short-term and Long-term Physiotherapy Plan

The goal of any rehabilitation program following total hip replacement is not only to maximize the patients functional status with respect to mobility and activities of daily living (ADL) but also to minimize postoperative complications.

Goals :

- Improve ROM in hip and knee joint
- Improve muscle strength
- Improve and education in crutch gait
- Aim for better weight bearing distribution
- Reduce swelling and redness around scar
- Improve flexibility of target soft tissue
- Promote relaxation of hypertonic muscles

Short-term rehabilitation plan

- Relieve pain
- Increase ROM in both lower extremities
- Strengthen Hip Flexors, extensors, ADD and ABD
- Relax hypertonic muscles
- Educate crutch gait
- Correction of posture alignment
- Reduce swelling around scar

Long- term rehabilitation plan

- Reduce pain
- Educate in gait
- Improve or return to normal ADL
- Regain ROM in lower extremity
- Reduce hypertonic muscles
- Improve posture
- Increase muscle coordination and strength

3.4.1 Therapy Proposal

- Scar care therapy of with emphasis on caudal part of the scar
- Mobilization of fibula and patella
- Post-isometric relaxation of hypertonic muscles
- Strengthening of muscles below the scale of 5 (Kendall)
- Thermotherapy on hypertonic muscles
- Shifting of restricted fascia in Th-L junction

3.5 Therapy Progress

Date: 28.01.14

Session 1, Week 1

Status before therapy

Subjective: Patient have slept well the past days. She feels no pain, but uncomfortable when changing positions. Are generally in a good mood.

Objective: Patient comes in with axillary crutches. Limping slightly to the right foot. Wear antiembolic socks.

Goal of today´s therapy unit:

- Increase ROM into dorsal F, Hip F and ADD, Knee E.
- Scar care
- Soft tissue therapy
- Mobilization of blocked joints
- Strengthen Triceps surae, Quadriceps, Hip abductors, Glutei, Hamstrings

Therapy procedure:

Soft tissue therapy

- Hot roll whole back according to Brugger
- Fascia stretching gluteal from above
- Scar therapy (Pressure, S and C shape)

Post isometric relaxation

- Dorsi F with knee flexion and knee extension for Soleus and Gastrocnemius
- Hip F sidelying for Iliopsoas

- Hip ADD for Adductor Longus and Brevis
- Knee E for Rectus Femoris

Mobilization

- Patella lateromedial and craniocaudal
- Fibular head ventrodorsal
- Lumbar isometric traction caudal direction

Strengthening

- Plantar F against soft ball
  (Soleus and Gastrocnemius)
- Knee E with soft ball below fossa poplitea
  (Vastus med, lat and intermedius, Rectus Femoris)
- Hip abduction
  (Gluteus medius, minimus and Tensor Fascia latae)
- Knee F with soft ball under the sole of foot
  (Biceps femoris, Semitendinosus and Semimembranosus)

Result

Subjective:

She feels more relaxed after the therapy session and more coordinated when changing positions from sitting to standing and opposite.

Objective:

The soft tissue around scar is more movable than before the soft tissue therapy. Both patellas are still blocked in the same directions, but the tension of quadriceps tendon have decreased causing relaxing feeling in the knee joint. The fibular head on both lower extremities is more movable in ventral and dorsal direction after mobilization.

Tension in the muscles after PIR decreased slightly after the procedure and caused a relaxing effect, and the strength is almost the same as in muscular strength examination.

Self therapy

- Active movement of ankle into dorsi F, plantar F and circumduction
- Isometric contractions in supine position of gluteal muscles against the bed
- Scar care with pressure on deep soft tissue showed by supervisor
- Crutch gait in hallways
- Isotonic strength exercise of hip adductors and abductors supine position without resistance

Date: 29.01.14
Session 2, Week 1

Status before therapy

Subjective: Patient have had some problems with crutch gait caused by sore hands. Have modified the grip on crutches. She is in good mood and don´t have any pain from yesterday´s session. She had no problem performing the self therapy on her own.

Objective: Patient still keep her body toward healthy leg when walking and standing. Manage to take off clothes by herself except socks. She is showing some pain related facial expressions when going from sitting to lying, but says it is not painful.

Goal of today´s therapy unit:

- Increase ROM into dorsal and plantar F, Hip F and ADD, Knee E.
- Scar care
- Soft tissue therapy
- Mobilization of blocked joints
- Strengthen Triceps surae, Quadriceps, Hip abductors, Glutei, Hamstrings

Therapy procedure:

Soft tissue therapy

- Hot roll whole back (Brugger)
- Fascia stretching gluteal from above
- Scar therapy (Pressure, Folding)

Post isometric relaxation

- Hip F outside of table for Iliopsoas
- Hip ADD for Adductor Longus and Brevis
- Plantar F and E for Gastrocnemius, Soleus and Tibialis Anterior
- Knee E for Rectus Femoris

Mobilization

- Patella Lateromedial and craniocaudal
- Lumbar isometric traction caudal direction

Strengthening

- Plantar F against soft ball
  (Soleus and Gastrocnemius)
- Dorsal F active
  (Tibialis Anterior)
- Knee E with soft ball below fossa poplitea
  (Vastus med, lat and intermedius, Rectus Femoris)
- Hip abduction
  (Gluteus medius, minimus and Tensor Fascia Latae)

- Knee F with soft ball under the sole of foot
  (Biceps femoris, Semimembranosus, Semitendinosus)
- Isometric gluteal with fascilitation by brush

Results

Subjective:

She feel relaxed but also a bit tired after therapy. She says the therapy helps her motivation getting able to walk without any support. She have some pain in her lumbar spine after therapy.

Objective:

She is more tired from todays therapy than yesterdays therapy. Her strength in gluteus medius and maximus have increased from 3 to 4 on right leg and 4- on left leg. We can also se an increased strength in soleus approximately from 4 to 5- on both legs. PIR on knee extensors are very effective and releases a lot of tension in quadriceps tendon. ROM in the knee joint into flexion have increased. She tends to go to hip abduction when performing active hip flexion in supine position. This was corrected during the exercise.

Self therapy

- Active hip F supine with focus on not falling into hip abduction
  (Iliopsoas and Rectus Femoris)
- Gravity induced PIR on right hip F
  (Iliopsoas)
- Gravity induced PIR on Knee E
  (Rectus Femoris)
- Active movement of ankle into plantar, dorsi flexion and circumduction
  (Tibialis Anterior, Soleus, Gastrocnemius, Peroneus Longus and Brevis)

Date: 30.01.14

Session 3, Week 1

Status before therapy

Subjective: Patient feels the pain has decreased around knees and lumbar spine but it is still present. She has no problem performing self therapy. Patient have slept well during the night. She feels she can put a little more pressure on her left foot when walking without it causing pain or uncomfortable feelings.

Objective: Patient still keep her body toward healthy leg when walking and standing, but slightly better than previous sessions. Manage to take off clothes by herself except socks. She seems tens when moving the spine, more to lumbar spine.

Goal of today´s therapy unit:

- Scar care
- Soft tissue therapy
- Mobilization of blocked joints
- Strengthen Triceps surae, Quadriceps, Hip abductors/adductors, Glutei, Hamstrings

Therapy procedure:

Soft tissue therapy

- Hot roll whole back (Brugger)
- Fascia stretching gluteal from above
- Scar therapy (Pressure, Folding)

Mobilization

- Patella Lateromedial and craniocaudal

Strengthening

- Hip adduction soft ball between knees
  (Adductor Magnus, Longus and Brevis)

- Hip abduction isometric
  (Tensor Fascia Latae, Gluteus medius and minimus)
- Hip/knee F with soft ball under feet performing rolling
  (Iliopsoas, Semitendinosus, Semimembranosus, Rectus Femoris)
- Knee F teraband prone
  (Biceps femoris, Semimembranosus, Semitendinosus)

- Hip E with overball under knees supine
  (Gluteus maximus)
- Active LF and R sitting
  (Transverse, Oblique internal and external abdominis)

Results:

Subjective:

She feels that the knees are more movable after each therapy. Also the crutch gait is much easier now than before the first therapy session.

Objective:

She still have some bad movement stereotypes in hip flexion and knee flexion. Her stability during hip E with overball under knees in supine is not very bad, but need some help not to roll over to the sides. The patella is still blocked in the same directions, but the barrier is softer than before. She struggles slightly with performing active movements of the spine causing the pelvis to elevate especially to latero flexion.

Self therapy

- Supine hip lift
- Supine hip F with focus on faulty movement into hip adduction
- Active movement ankle into plantar, dorsi flexion and circumduction
- Active movement whole spine lateroflexion and rotation with hands on pelvis for movement confirmation
- Crutch gait in hallway

Date: 31.01.14

Session 4, Week 1

Status before therapy

Subjective:

Patient feels the pain and tension has decreased around knees and lumbar spine. She says it is much easier to walk with crutches and is happy with the improvement in strength and coordination. She is a bit tired after the previous therapy.

Objective:

Patient is now able to keep weight on both legs and does not tend to move much to the strong leg when walking. Manage to take off clothes by herself and dresses her socks with a towel after education in ergotherapy.

Goal of today´s therapy unit:

- Scar care
- Soft tissue therapy
- Mobilization of blocked joints
- Strengthen Triceps surae, Quadriceps, Hip abductors/adductors, Glutei, Hamstrings

Therapy procedure:

Soft tissue therapy

- Hot roll whole back (Brugger)
- Fascia stretching gluteal from above
- Scar therapy (Pressure, Folding)

Post isometric relaxation

- Plantar F with knee in F and E for Soleus and Gastrocnemius
- Hip ADD for Adductor longus and brevis
- Hip F for Iliopsoas
- Knee E for Rectus femoris

Mobilization

- Patella Lateromedia and craniocaudal

Strengthening

- Isometric contraction glutei prone
  (Gluteus maximus)
- Knee F/E using overball below calf
  (Iliopsoas, Semitendinosus, Semimembranosus, Rectus Femoris)
- Hip elevation overball under thighs
  (Gluteus maximus, Adductor longus, brevis, Semimembranosus, Semitendinosus, Rectus femoris)
- Knee E pressing on overball caudally
  (Gluteus maximus, Rectus femoris, Semimembranosus, Semitendinosus)
- Active hip abduction
  (Gluteus medius, minimus, Tensor fascia latae)
- Isometric hip adduction
  (Adductor magnus, brevis and longus)

Results:

Subjective:

She does not have the same pain in lumbar spine as before therapy. She is a bit tired after the strengthening exercises, but can feel that she has become stronger during this week. She has no pain in her knees when walking, and says it is easier to move correctly than before.

Objective:

ROM in hip, more on right leg and both knees have improved in flexion. Knee extension have now improved in ROM and starting position on left leg is 0 degrees and the right leg are -5 degrees. Hip abductors and adductors have improved up to 4/5 on right leg and 4 on left leg. Her faulty movement stereotype in hip F causing hip add in movement have decreased and are now able to perform it without it falling into adduction.

Self Therapy:

- Supine hip lift
- Supine hip F with focus on faulty movement into hip adduction
- Active movement ankle into plantar, dorsi flexion and circumduction
- Active movement whole spine lateroflexion and rotation with hands on pelvis for movement confirmation
- Crutch gait in hallway

3.6 Final Kinesiologic Examination

Examinations were performed January 31. 2014.

3.6.1 Posture Examination

Posterior view

- Flatfoot both legs
- Narrow stance
- Slight external rotation right leg
- Left popliteal fossa slightly higher
- Right infragluteal line slightly lower
- Atrophy right hamstrings (slightly decreased from initial exam)
- Pelvis tilted to the right
- Whole spine shifted right for plumbline but less than initial examination
- Scoliosis dextra Th 1/2 - Th 10/11
- Head slightly lateroflexed to the left

Lateral view - Right

- Semiflexion right knee
- Pelvis in anteversion
- Th10 in slight lordosis
- More curvature in Th spine
- Kyphosis C spine
- Protraction of the head

Lateral view - Left

- The same readings as right side

Anterior view

- Slight external rotation left knee
- Atrophy right quadriceps
- Umbilicus and trunk shifted slightly to the right for plumbline but less than initial examination
- Left arm rests on pelvis
- Right arm hanging freely
- Left shoulder slightly depressed
- Head slightly shifted to the right

Two scale test

Right: 47kg
Left: 45kg

3.6.2 Gait Examination

* Gait examination were performed with axillary crutches

- Limited curling of toes on left foot
- Slight ER of left leg
- Slight extension of both legs
- Puts more pressure on right leg but more symmetrically than initial examination
- Upper extremity slightly shifting to the right
- Slight movement of trunk

3.6.3 Pelvis examination

Crests: Left slightly higher

Psis: Higher on left side

Asis: Higher on left side

Results: Pelvis slightly rotated clockwise

3.6.4 Circumference measurements

Measured	Right (cm)	Left (cm)
Calf	39	39
Knee	40	40
Over head of fibula	37	37

Thigh (15cm above patella)	54	53
Ankle	26	26
Over head of metatarsals	24	24.5

Table 14 Circumference measurements

3.6.5 Range of motion - Active motion

Movement	Results Right	Results Left
Ankle joint Active		
Plantar Flexion	45	45
Dorsal Flexion	22	23
Ankle joint Passive		
Plantar Flexion	50	50
Dorsal Flexion	30	25
Knee joint Active		
Flexion	110	125
Extension	0	0
Knee joint Passive		
Flexion	110	130
Extension	0	0
Hip joint Active		
Flexion	100	60
Extension	/	/
External rotation	45	/
Internal rotation	20	/

Abduction	45	30
Adduction	/	/
Hip joint Passive		
Flexion	100	90
Extension	/	/
External rotation	45	/
Internal rotation	20	/
Abduction	45	30
Adduction	/	/

Table 15 Range of motion

All movement examinations were performed in lying position.

/ - Movement which caused pain and/or not suitable after operation

3.6.6 Movement pattern according to Janda

Movement pattern	Result
Hip abduction Left	Tensor mechanism
Hip abduction Right	Tensor mechanism

Table 16 Movement pattern according to Janda

3.6.7 Neurological Examination

Light Touch Sensation

Tested Dermatome	Result Right	Result Left
L2 - Medial thigh	Feel touch	Feel touch
L3 - Medial knee	Feel touch	Feel touch
L4 - Medial ankle, 1 toe	Feel touch	Feel touch
L5 - Dorsum of foot	Feel touch	Feel touch
S1 - Lateral foot	Feel touch	Feel touch
S2 - Posteromedial thigh	Feel touch	Feel touch

Table 17 Neurological Examination

Deep Movement Sensation

Tested Direction	Result Right	Result Left
Toe Flexion	Feel direction and position	Feel direction and position
Toe Extension	Feel direction and position	Feel direction and position
Toe Abduction	Feel direction and position	Feel direction and position
Toe Adduction	Feel direction and position	Feel direction and position
Plantar Flexion	Feel direction and position	Feel direction and position
Dorsal Flexion	Feel direction and position	Feel direction and position
Inversion	Feel direction and position	Feel direction and position
Eversion	Feel direction and position	Feel direction and position

Knee Extension	Feel direction and position	Feel direction and position
Knee Flexion	Feel direction and position	Feel direction and position
Hip Extension	Feel direction and position	Feel direction and position
Hip Flexion	Feel direction and position	Feel direction and position
Hip Internal Rotation	Feel direction and position	Feel direction and position
Hip External Rotation	Feel direction and position	Feel direction and position
Hip Abduction	Feel direction and position	Feel direction and position
Hip Adduction	Feel direction and position	Feel direction and position

Table 18 Deep movement Sensation

Deep tendon reflexes

Reflex	Grade Right	Grade Left
Patellar	2	2
Achilles	2	2

Table 19 Deep tendon reflexes

3.6.8 Scar Examination

Inspection: The scar looks like it have been healing well. There is no redness or swelling around the scar.

Palpation: There is a slight restriction in movement around the scar inn the distal part, but we can feel a clear difference compared with the first examination.

3.6.9 Muscle strength testing according to Kendall

Muscle	Grade Right	Grade Left
Tibialis Anterior	5-	4
Soleus	5	5
Gastrocnemius	5	5
Peroneus Longus	5	5
Vastus Medialis	5-	4
Vastus Lateralis	4+	4-
Iliopsoas	4+	4
Rectus Femoris	5-	4
Biceps Femoris	4+	4
Semimembranosus	4	4-
Semitendinosus	4	4-
Tensor Fascia Latae	4	4-
Adductor Longus/Magnus	3/4	3/4
Gluteus maximus	4-	4-
Gluteus medius	4	4-
Gluteus minimus	4-	4-
Flexor digitorum longus	4	4-
Extensor digitorum longus	4	4
Flexor hallucis	5-	5
Extensor hallucis	4	4

Table 20 Muscle strength testing according to Kendall

3.6.10 Palpation

Muscle	Result Right	Result Left
Soleus	Hypertone	Slight hypertone
Gastrocnemius	Hypertone	Slight hypertone
Tibialis anterior	Normal	Normal
Semimembranosus	Hypertone	Normal
Semitendinosus	Hypertone	Normal
Biceps femoris	Hypertone	Hypertone
Vastus medialis	Hypotone	Hypotone
Vastus lateralis	Normal	Normal
Rectus femoris	Hypertone	Hypertone
Tensor fascia latae	Hypertone	Hypertone
Gluteus maximus	Hypotone	Hypotone
Gluteus minimus/medius	Hypotone	Hypotone
Iliopsoas major	Hypertone	Hypertone
Erector spinae	Hypertone	Slight hypertone
Trapezius	Upper hypertone	Lower hypertone

Table 21 Palpation

Palpation of fascia and skin

Shifting the deep gluteal fascia from above: Restricted Left and Right

Shifting the Lumbodorsal fascia upwards: Slightly restricted Left and Right

Kiblers Fold

- Restriction in Th-L junction on both sides

3.6.11 Examination of joint play according to Lewit

Joint	Result Right	Result Left
Phalanges	No blockage	No blockage
Metatarsophalangeal	No blockage	No blockage
Chopart	No blockage	No blockage
Listfranc	No blockage	No blockage
Talocrural	No blockage	No blockage
Fibular head	Blocked ventral direction *	Blocked ventrodorsal direction*
Knee Lateral gapping	No blockage	No blockage
Knee Medial gapping	No blockage	No blockage
Patella	Blocked in all directions *	Blocked in medial + craniocaudal direction *

Table 22 Examination of joint play according to Lewit

* - The blockage is still present, but there is slightly more movement of the joints than in initial kinesiological examination. The barrier are more soft than before.

3.7 Evaluation of the Effect of the Therapy

Initial kinesiological examination versus final kinesiological examination

Initial Kinesiological examination	Final Kinesiological examination
Posture examination	Posture examination
Posterior view - Slight external rotation right leg - Left popliteal fossa higher - Right infragluteal line lower - Atrophy right hamstrings - Pelvis tilted to the right - Left arm resting on hip - Whole spine shifted right for plumbline - Scoliosis dextra Th 1/2 - Th 10/11	Posterior view - Slight external rotation right leg - **Left popliteal fossa slightly higher** - **Right infragluteal line slightly lower** - Atrophy right hamstrings - Pelvis tilted to the right - **Whole spine shifted right for plumbline but much less than initial examination** - Scoliosis dextra Th 1/2 - Th 10/11
Lateral view - Semiflexion right knee - Pelvis in anteversion - Th10 in lordosis - Flat back C7-Th9 - Kyphosis C spine	Lateral view - Semiflexion right knee - Pelvis in anteversion - Th10 in slight lordosis - **More curvature in Th spine** - Kyphosis C spine
Anterior view - Slight external left knee - Atrophy right quadriceps - Umbilicus and trunk shifted right for plumbline - Left arm rests on pelvis - Left shoulder depressed	Anterior view - Slight external left knee - Atrophy right quadriceps - **Umbilicus and trunk shifted slightly to the right for plumbline but less than initial examination** - Left arm rests on pelvis - Left shoulder slightly depressed

Gait examination	Gait examination
- Short stance - No curling of toes - Slight ER both lower extremities - No extension of both legs - Puts more pressure on right leg - Whole body shifts to the right side - Stiff trunk	**- Limited curling of toes on left foot** **- Slight ER of left leg** - Slight extension of both legs **- Puts more pressure on right leg but more symmetrically than initial examination** **- Upper extremity slightly shifting to the right**
Pelvis examination **Crests:** Left higher **Psis:** Higher on left side **Asis:** Higher on left side **Results:** Pelvis rotated clockwise with left side elevated	Pelvis examination **Crests: Left slightly higher** **Psis:** Higher on left side **Asis:** Higher on left side **Results: Pelvis slightly rotated clockwise with left side elevated**

Table 23 Initial kinesiological examination versus final kinesiological examination

* The words marked in bold were changes between the examinations.

When we look at the patients posture and comparing what we see from beginning and end of therapy there is a marked difference in several areas. At first aspection in final posture examination we find patient´s shifting of upper extremity has been decreased and are now more in line with the plumb line. Patient´s scoliosis is still present, but it seems that the strengthening exercises of lower extremity has created more stable and supportive structures causing an upright posture. Her pelvis has almost the same position as before, but are slightly more in level now. On the two scale test we found a marked difference from right to left where 52kg on the right and 40kg on the left. This was a result of overusing the healthy limb for a period of time. After the therapy sessions we tested her stance again and it was only 2 kg difference, and this was the test which improved the most.

The condition of the scar has improved during this period, and compared with first aspection of the scar we now find a reduction in redness and swelling especially

around the distal part where it was previously worse. After final examination of soft tissues around the scar the restriction has almost disappeared, also in addition the patient states that she feels less tension around the scar when moving the hip.

We can see after the final kinesiological examination that an improvement in range of motion are in almost all segments, some slightly and other more. In the ankle joint we see the patient has improved 2-5 degrees in both passive and active dorsi and plantar flexion. In the knee joint we see an even bigger improvement where flexion both passive and active flexion have improved 20-25 degrees both right and left knee. The extension have not improved since the blocked patella is still a factor. The hip joint is the least improved joint with only 5 degrees in active flexion and 10 in internal rotation. The passive movement have decreased 5 degrees in right hip flexion and increased in the left leg. Internal rotation have improved 10 degrees also in passive motion. Further work must be done to achieve a physiological ROM in the lower extremity. If the patient will

Movement	Results Right	Results Left
Ankle joint Active		
Plantar Flexion	45 (+3)	45 (+4)
Dorsal Flexion	22 (+2)	23 (+3)
Ankle joint Passive		
Plantar Flexion	50 (+2)	50 (+5)
Dorsal Flexion	30 (+5)	25
Knee joint Active		
Flexion	110 (+20)	125 (+25)
Extension	0	0
Knee joint Passive		
Flexion	110 (+15)	130 (+25)
Extension	0	0
Hip joint Active		
Flexion	100 (-5)	60

Extension	/	/
External rotation	45	/
Internal rotation	20 (+10)	/
Abduction	45	30 (+5)
Adduction	/	/
Hip joint Passive		
Flexion	100 (-5)	90 (-5)
Extension	/	/
External rotation	45	/
Internal rotation	20 (+20)	/
Abduction	45	30
Adduction	/	/

Table 24 Range of motion results

Gait has improved as well from an analgetic crutchgait where the body was shifted to her right side to a more stable crutch gait with a wider stance. In the beginning the patient used small steps, about 10-15cm, in addition to no extension in hips or curling of toes. After some days with correction of the gait the patient used the crutches more as walking aid which made it more safe for her to use them, both mentally and physically. At the final gait examination her steps became symmetrically, the grip on the crutches was more stable, and we could see a clear difference in coordination in her ankle, knees and hips.

The only improvement in movement patterns is hip abduction left leg where we no longer can see the quadratus mechanism which was shown at initial kinesliological examination. When we look at how she performs several movements which was difficult at the beginning, she has improved drastically. When going from lying to sitting, sitting to standing and opposite, it seems to be a lot easier now than before. Much more coordination and fluent movement, instead of rigid movements with pain.

We can observe and feel the patients improvement in muscle strength in almost all muscle tested. Her coordination and movement rhythm is improved as well and can clearly say that she have gain muscle strength during her rehabilitation. The grading of improvements were variably, most improved and some were the same after the period. The numbers in between the parentheses in the table are from initial kinesiological examination.

Muscle	Grade Right	Grade Left
Tibialis Anterior	5- (4)	4
Soleus	5 (4)	5 (4)
Gastrocnemius	5	5
Peroneus Longus	5	5
Vastus Medialis	5-	4 (4-)
Vastus Lateralis	4+	4-
Iliopsoas	4+	4
Rectus Femoris	5-	4
Biceps Femoris	4+ (4-)	4 (3+)
Semimembranosus	4	4- (3)
Semitendinosus	4	4- (3+)
Tensor Fascia Latae	4 (3/4)	4- (3-)
Adductor Longus/Magnus	3/4	3/4
Gluteus maximus	4- (3)	4- (3)
Gluteus medius	4 (3)	4- (3)
Gluteus minimus	4- (3)	4- (3)
Flexor digitorum longus	4	4-
Extensor digitorum longus	4	4
Flexor hallucis	5- (4/5)	5 (4/5)
Extensor hallucis	4	4 (4-)

Table 25 Muscle strength testing results

Since the patients left leg was the weakest to begin with, it had to improve more than

the healthy leg to compensate with unstability and the causing of muscle imbalance after a period of limited exercise. We found the most improved muscle group were knee flexors, hip extensors and hip abductors. There was still some limitation in strength in hamstrings and abductors of both hips. I visited the clinic one week after my bachelor practice, my supervisor expressed a further improvement in muscular strength and coordination in lower extremities.

Palpation

Muscle	Right IKE	Left IKE	Right FKE	Left FKE
Semimembranosus	Hypertone	Hypertone	Hypertone	Normal
Semitendinosus	Hypertone	Hypertone	Hypertone	Normal
Erector spinae	Slight hypertone	Slight hypertone	Hypertone	Slight hypertone

Table 26 Palpation results

These are the only changes in target muscles where only semitendinosus and membranosus were changes in her left leg. The patients erector spinae became worse at final kinesiologic examination. I think these results show that the therapy may have been too intensive for this patient.

In the initial kinesiological examination we found blockage in both fibular heads and both patellas. After we performed therapy for immobile joints (Lewit) we found the same results in final kinesiological examination but we could feel a slight improvement in the barrier of both joints. They were still blocked, but the tension around the joints were also decreased.

There were many aspects of the therapy which helped the patient both in performance

and decreasing in pain, and some which I feel did not help much. Those who I felt helped the patient was the post isometric relaxation techniques, stretching. She could feel more relaxed and could perform exercises for a longer duration without the presence of pain than before. Also the soft tissue techniques helped her in relaxing and feeling better. The strengthening exercises gave her improvements in strength, but also had a effect of tiring and post-exercise weakness. From the first day of rehabilitation my patient have been more motivated than I expected before my practice. She have been very eager to learn about the rehabilitation regarding why, how and when we are doing our techniques. I think this will affect the patients prognosis in a positive way, since she was very positive continuing with a therapy program at home. She have had much improvement the first week of rehabilitation, and I visited the clinic one week after my supervisor told me she have improved further, especially with coordination, muscle strength and posture.

Due to the patients osteoarthritis, I think this will limit returning to a fully physiological state, but for the patients ADL, I think she will be able to perform most of her daily activities after one-four months depending on post-rehabilitation program. If she will be strict with an upright posture and correct the previous faulty weight distribution I think she will return to a functional life. If I would have more time with my patient I would maybe focus more on sensomotoric training and stabilization of pelvis and trunk.

4. Conclusion

I was introduced to my patient the second week of my two-week bachelor practice at Klinika rehabilitačního lékařství. When I came to the clinic, my supervisor told me that she had prepared a patient after total hip replacement who would come early the second week. We had one day of initial kinesiological examination and four therapy-sessions. Due to some communication problems regarding language barriers, we were able to cooperate very well. At the end of therapy we saw a lot of improvements but also some results became worse. I think this is due to the intensive therapy-program, especially from strengthening exercises. Almost all of my knowledge from our practice at school was used, with additional therapeutic methods which my supervisor added to the program. I am however satisfied with the results we have achieved during this week and would recommend a similar rehabilitation program for this type of diagnosis.

5. List of Literature

1. Atkinson, K., & Coutts, F. (2005). Total joint replacements. *Physiotherapy in orthopaedics: a problem-solving approach* (2nd ed., p.245). Edinburgh: Elsevier/ Churchill Livingstone.
2. Bono, J. V. (1999). Postoperative infection. *Revision total hip athroplasty* (p. 371). New York: Springer.
3. Braddom, R. L., & Bruschbacher, R. M. (2000). *Physical medicine and rehabilitation* (2nd ed.). Philadelphia: Saunders.
4. Callaghan, J. J. (2007). *The adult hip* (2. ed.). Philadelphia [u.a.: Lippincott Wiliams & Wilkins.
5. Cameron, M. H., & Monroe, L. G. (2007). Exercise. *Physical rehabilitation: Evidence-based examination, evaluation, and intervention* (p. 107). St. Louis, Mo.: Saunders/Elsevier
6. Clarkson, H. M. (2000). *Musculoskeletal assessment: joint range of motion and manual muscle strength* (2nd ed.). Philadelphia: Lippincott Williams & Wilkins.
7. DeLisa, J. A., & Gans, B. M. (1998). *Rehabilitation medicine: principles and practice* (3rd ed.). Philadelphia: Lippincott-Raven.
8. Ebnezar, J. (2003). *Essentials of orthopaedics for physiotherapists.* New Dehli: Jaypee Bros
9. Grant, C. R., & Checketts, M. R. (2008). Analgesia for primary hip and knee athroplasty: the role of regional anaesthesia. *Continuing Education in Anaesthesia, Critical Care & Pain,* 8(2), 56-61
10. Greene, D. P., & Roberts, S. L. (1999). *Kinesiology: movement in the context of activity.* St. Louis: Mosby.
11. Hnatova, I. (2009). Introduction in Rehabilitation, *Types of thermotherapy*, Powerpoint presented and retrieved from FTVS UK, Dep. of physiotherapy, Prague Czech Republic
12. Kendall, F. P. (2005). Lower Extremity. *Muscles: Testing and function with posture and pain* (5th ed., p. 372). Baltimore, MD: Lippincott Wiliams & Wilkins.
13. Lane, N. E., & Wallace, D. J. (2002). *All about osteoarthritis the devinitice resource for atrhritis patients and their families.* Oxford: Oxford University Press.
14. Lewit, K. (1999). Therapeutic techniques. *Manipulative therapy in*

rehabilitation of the locomotor system (3rd ed., pp. 209-210). Oxford: Butterworth-Heinemann

15. Lubin, M. F. (2012). Hip fractures. *Medical management of the surgical patient: a textbook of perioperative medicine* (5th ed., p. 654). Cambridge: Cambridge University Press
16. Magee, D. J. (2008). *Orthopedic physical assessment* (5th ed.). St. Louis, Mo.: Saunders Elsevier
17. Moskowitz, R. W. (2007). *Osteoarthritis: diafnosis and medical/surgical management* (4th ed.). Philadelphia: Wolters Kluwer Health/Lippincott Wiliams & Wilkins.
18. Platzer, W. (2009). *Color atlas of human anatomy* (6th rev. and enlarged ed.). Stuttgart: Thieme.
19. Schuenke, M., Ross, L. M., Lamperti, E. D., Schulte, E., & Schumacher, U. (2006). *Atlas of anatomy: general anatomy and musculoskeletal system.* Stuttgart, New York: Thieme.
20. Wei, N. Arthritis-treatment-and-relief.com [online]. 2004 [cit. 2011-01-17]. Hip replacement exercise therapy. Dostupne z http://www.arthritis-treatment-and-relief.com/hip-replacement-exercise-therapy.html

Supplement 1

List of Tables

List of figures

Figure 1: Nortin, M., & Frankel, V. H. (2001). Biomechanics of joints. *Basic biomechanics of the musculoskeletal system* (3rd ed., p. 208). Philadelphia: Lippincott Wiliams & Wilkins

Figure 2: Schunke, M., Schulte, E., Schumacher, U., Ross, L. M., & Lamperti, E. D. (2006). Lower limb. *Thieme atlas of anatomy* (p. 381). Stuttgart: Thieme

Figure 3: Heike, A., Michaelis, M. (April 2005). Articular structures that are affected in osteoarthritis. *Nature reviews Drug Discovery* (p. 331) Macmillan

Figure 4: Ebnezar, J. (2003). Injuries around the hip. *Essentials of orthopaedics for physiotherapists* (p. 122). New Dehli: Jaypee Bros

Supplement 2

ABD = Abduction

ADD = Adduction

ADL = Activities of daily living

ASIS = Anterior superior iliac spine

BMI = Body mass index

C = Cervical

Cm = Centimeter

DVT= Deep Vein Thrombosis

E = Extension

E.g. = For example

ER = External rotation

F = Flexion

IR = Internal rotation

JOD = Iodine

Kg = Kilograms

L = Lumbar, e.g. L2 = Second Lumbar vertebra

M = Muscle

N = Newton

OA = Osteoarthritis

PE= Pulmonary embolism

PNC= Pencillin

ROM= Range of motion

PSIS = Posterior superior iliac spine

S = Sacral, e.g. S2 = Second Sacral vertebra

Th= Thoracic

Supplement 3

INFORMOVANÝ SOUHLAS

V souladu se Zákonem o péči o zdraví lidu (§ 23 odst. 2 zákona č.20/1966 Sb.) a Úmluvou o lidských právech a biomedicíně č. 96/2001, Vás žádám o souhlas k vyšetření a následné terapii. Dále Vás žádám o souhlas k nahlížení do Vaší dokumentace osobou získávající způsobilost k výkonu zdravotnického povolání v rámci

praktické výuky a s uveřejněním výsledků terapie v rámci bakalářské práce na FTVS UK. Osobní data v této studii nebudou uvedena. Dnešního dne jsem byla odborným pracovníkem poučena o plánovaném vyšetření a následné terapii. Prohlašuji a svým dále uvedeným vlastnoručním podpisem potvrzuji, že odborný pracovník, který mi poskytl poučení, mi osobně vysvětlil vše, co je obsahem tohoto písemného informovaného souhlasu, a měla jsem možnost klást mu otázky, na které mi řádně odpověděl.

Prohlašuji, že jsem shora uvedenému poučení plně porozuměla a výslovně souhlasím s provedením vyšetření a následnou terapií. Souhlasím s nahlížením níže jmenované osoby do mé dokumentace a s uveřejněním výsledků terapie v rámci studie.

Datum:..... Osoba, která provedla poučení:..... Podpis osoby, která provedla poučení:..... Vlastnoruční podpis pacienta /tky:.....