CHARLES UNIVERSITY IN PRAGUE

FACULTY OF PHYSICAL EDUCATION AND SPORT

DEPARTMENT OF PHYSIOTHERAPY

Case Study of Physiotherapy Treatment of a Patient with the Diagnosis of Total Endoprothesis of Hip

BACHELOR DEGREE IN PHYSIOTHERAPY

SPECIALIZATION IN HEALTH CARE

Author: Pyrillos Tryfonas

Supervisor: Mgr. Agnieszka Dudova Ph.D

April 2014, Prague

Abstract

Title: **Case Study of Physiotherapy Treatment of a Patient with the Diagnosis of Total Endoprothesis of Hip**

Název: **Kazuistika fyzioterapeutické péče o pacienta s diagnózou totální endoprotéza kyčelního kloubu**

Summary

The abstract of my study concerns the treatment of the case of a patient who had an operation of total endoprothesis of hip on the right hip joint, caused by osteoarthritis. My practice was performed at Ústřední Vojenská Nemocnice.

My Bachelor Thesis is divided in two parts: 1) Theoretical part 2) Practical part.

The first part is the theoretical one which consists of a brief description of the anatomy, biomechanics and kinesiology of the hip which helps for better understanding of the mechanism of total endoprothesis of hip. Additionally, description of the osteoarthritis which caused the operation is mentioned. Also there is information about every detail related to total endoprothesis of hip.

On the other most important part of this thesis, the second part is the practical one which includes the anamnesis and the kinesiologic examinations of the patient, after total endoprothesis of hip caused by osteoarthritis. Then six physiotherapeutic sessions also were performed and all physiotherapeutic procedures are described in detail on a daily base. Additionally, final kinesiologic examination was evaluated.

Finally in the evaluation of the effect of the therapy the improved results of the patient are mentioned and it is available for the reader to evaluate.

Key words: hip joint, osteoarthritis, total endoprothesis, physiotherapy, range of motion, exercise.

Declaration

I declare that this bachelor thesis was managed by me independently and by the instructions of my supervisor Mgr. Agnieszka Dudova Ph.D. It is an original research which is based on casuistic practice with patient after total endoprothesis of right hip in Ústřední Vojenská Nemocnice, under the supervising of Dis. Petr Smejkal.

I also state that all the information, examination and therapeutic procedures, which are presented on this bachelor thesis, were performed based on my knowledge that I received from the professors of the Charles University in Prague, department of Physiotherapy. The information that I use to write this bachelor thesis was sourced from the list of literature which take place at the end of this thesis below.

Finally a proposed informed approval was assigned by the patient and me, and the patient was informed before every examination and therapeutic procedure that I was going to apply.

Pyrillos Tryfonas

April 2014, Prague

Acknowledgment

First of all I would like to express my respect and the special thanks to my professors for all their help, understanding and for all the knowledge they transmitted me during the past three years of my academic life, which I will try to use during my entire career.

I would like also to give my grateful thanks to my supervisor Mgr. Agnieszka Dudova Ph.D for her important help, direction and organized approach she afforded me towards my bachelor thesis. Also to the Dis. Petr Smejkal and the other physiotherapists of Ústřední Vojenská Nemocnice with whose help, guidance and experience help me to completed the practical part of my bachelor thesis which was a great experience for me.

Also I want to thanks my classmates for the nice cooperation that we had all these three years and that I will remember the nice memories that we had together.

Finally, I would like to express my special thanks to my family for all the support that they gave to me and I want to mentioned that without them my studies it were be something very difficult and I really appreciate what they have done for me.

CONTENTS

1.

INTRODUCTION

(PREFACE)

1. Introduction

The aim of this study is to explain from theoretical and practical aspect as much as possible about total endoprothesis of hip and how important is the physiotherapeutic rehabilitation after such orthopedic cases. In the text below are being described all the parameters which are related to a total endoprothesis of hip caused by osteoarthritis are in two main parts.

The theoretical part is the chapter which helps the reader to understand better the structural and functional role of the hip joint. The anatomy of the hip is mentioned and a brief description of the other body structures which are directly related to it, such as bones, muscles, ligaments, soft tissue, arteries and nerves as well as the biomechanical and kinesiologic aspect of the hip in relation to pelvis and lumbar spine is also described for a better awareness of the role of the hip. Additionally, in this chapter the cause of operation is explained, definition of the disease, etiology, pathogenesis and clinical picture. Finally the different types of treatment of osteoarthritis are mentioned with total endoprothesis of hip joint described in more details.

The second and most important part of this bachelor thesis, case study of the patient after total endoprothesis of hip caused by osteoarthritis. A male patient diagnosed with osteoarthritis five months ago without receiving any treatment about it. But due to pain and functional limitations patient undergoes for operation of his right hip five months after the diagnosis. Then he receives physiotherapeutic treatment in the orthopedic department of Ústřední Vojenská Nemocnice. In this chapter of my thesis there is a completely analysis of the state of my patient: present state, anamnesis, previous rehabilitation, differential diagnosis, indication for rehabilitation, initial examinations, conclusion, short term and long term rehabilitation plans, day to day procedures, therapy results, final kinesiologic examination and conclusion of the progress of the therapy

In this bachelor thesis I tried to deliver to the reader a clear view from both theoretical and practical aspect important information about total endoprothesis of hip caused by osteoarthritis.

2.

GENERAL PART

2. General Part

2.1 Hip joint in general

The hip joint forms the connection between the lower limb and the pelvic girdle. It is a strong and stable multiaxial ball and socket type of synovial joint. The head of the femur is the ball, and the acetabulum is the socket. The hip joint is designed for stability over a wide range of movement. During standing, the entire weight of the upper body is transmitted through the hip bones to the heads and necks of the femurs (Moore & Dalley, 2010).

2.1.2 Anatomy of hip joint

The hip joint is a sturdy ball-and-socket diarthrosis that permits flexion, extension, adduction, abduction, circumduction, and rotations. The acetabulum, a deep fossa, accommodates the head of the femur. The acetabular labrum, a projecting rim of fibrocartilage, increases the depth of the joint cavity (Clemente, 2006) (Martini & Nath, 2012).

2.1.3 Bones of hip joint

The mature hip bone (coxae) is the large, flat pelvic bone formed by the fusion of three primary bones: ilium, ischium, and pubis. Each of the three bones is formed from its own primary center of ossification (Rogers, 1982).

Ilium: The ilium forms the largest part of the hip bone and contributes the superior part of the acetabulum (Rogers, 1982).

Ischium: The ischium forms the posterior-inferior part of the hip bone (Rogers, 1982).

Pubis: The pubis forms the anterior-medial part of the hip bone, contributing the anterior part of the acetabulum, and provides proximal attachment for muscles of the medial thigh (Rogers, 1982).

The **Femur** is the longest and heaviest bone in the body. It transmits body weight from the hip bone to the tibia when a person is standing. Its length is approximately a quarter of the person's height. The femur consists of a shaft (body) and two ends. The proximal end consists of a head, neck and two projections called trochanters. The distal end consists of two condyles and epicondyles (Rogers, 1982).

The **acetabulum** is the large cup-shaped cavity or socket on the lateral aspect of the hip bone that articulates with the head of the femur to form the hip joint. All three primary bones forming the hip bone contribute to the formation of the acetabulum (Moore & Dalley, 2010).

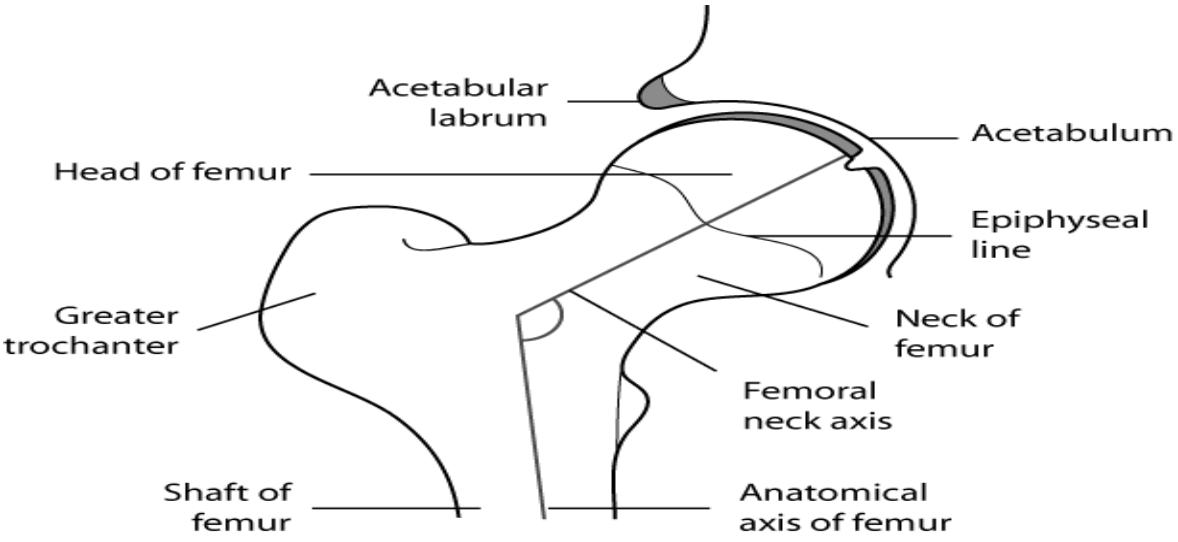

Picture 1- Cross-sectional view of the normal hip joint (Byrne, et al. 2010).

2.1.4 **Ligaments of hip joint**

The ligaments of the hip joint are the iliofemoral, pubofemoral, ischiofemoral, transverse acetabular and the ligamentum teres. As the hip moves so the capsular ligaments, as capsular thickenings, wind and unwind, tightening around the hip, affecting stability, excursion and joint capacity (Drake & Volg, 2009).

Iliofemoral: Its apex is attached between the anterior inferior iliac spine and acetabular rim, its base to the intertrochanteric line.

Pubofemoral: The pubofemoral ligament is triangular, its base attaching to the iliopubic eminence, superior pubic ramus, obturator crest and obturator membrane

Ischiofemoral: Consists of three distinct parts. The central part, the superior ischiofemoral ligament, spirals superolaterally from the ischium. Lateral and medial inferior ischiofemoral ligaments embrace the posterior circumference of the femoral neck.

Transverse acetabular: Is part of the labrum but has no cartilage cells. Its strong, flat fibres cross the acetabular notch forming a foramen through which vessels and nerves enter the joint.

Ligament of head of femur: is a flat band of delicate connective tissue that attaches at one end to the fovea on the head of the femur and at the other end to the acetabular fossa, transverse acetabular ligament, and margins of the acetabular notch.

Lingamentum teres: Its base is principally attached on both sides of the acetabular notch, between which it blends with the transverse ligament. It also receives weaker contributions from the margins of the acetabular fossa (Drake & Volg, 2009).

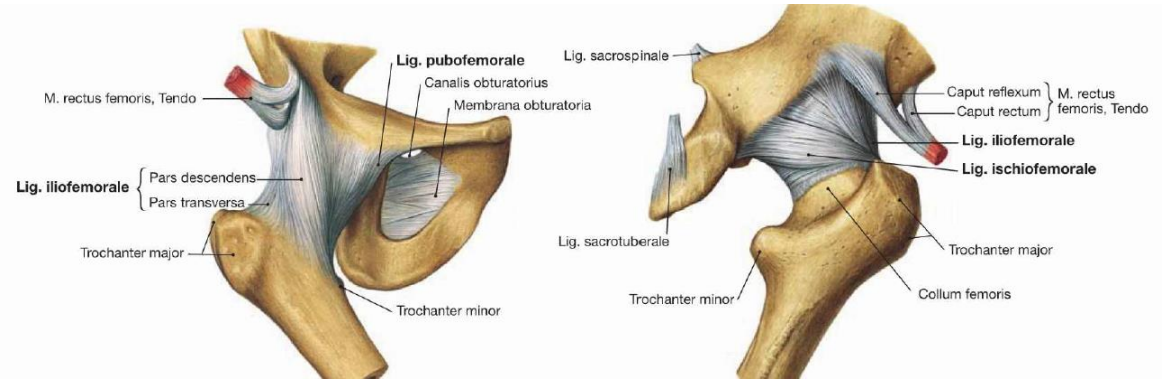

Picture 2 - Ligaments of hip joint (Paulsen & Waschkc, 2010).

2.1.5 **Synovial membrane, cartilage and labrum of hip joint**

The femoral head is covered by articular cartilage, except for a rough pit for the ligamentum teres. Cartilage thickness is maximal anterosuperiorly in the acetabulum and anterolaterally on the femoral head. The acetabular fossa within it is devoid of cartilage but contains fibroelastic fat largely covered by synovial membrane (Drake & Volg, 2009).

Acetabular depth is increased by the acetabular labrum, a fibrocartilaginous rim attached to the acetabular margin. The labrum is triangular in section, attaching by the base of the triangle to the acetabular rim while the apex is its free margin (Standring, 2008).

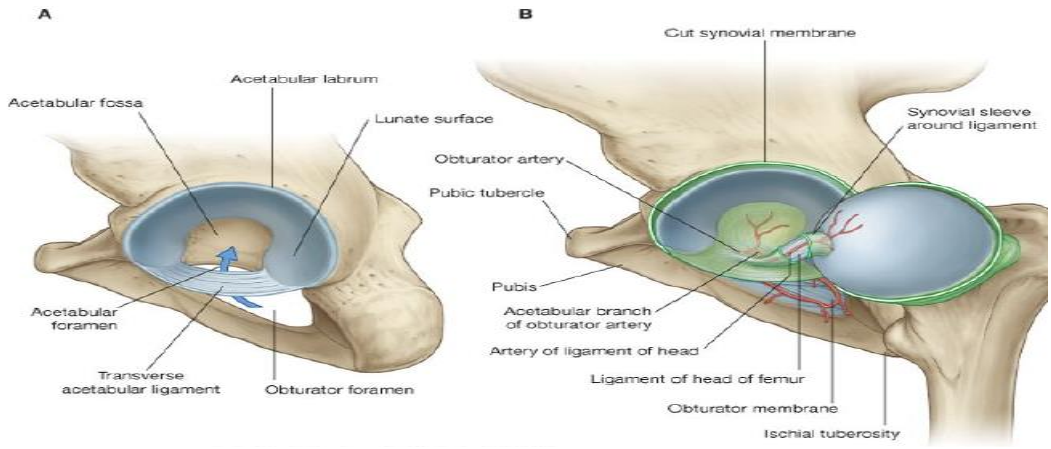

Picture 3 - Acetabular foramen of hip joint (Drake & Volg, 2009).

2.1.6 **Innervation related to the hip joint**

The **femoral nerve** carries contributions from the anterior rami of **L2 to L4** and leaves the abdomen by passing through the gap between the inguinal ligament and superior margin of the pelvis to enter the femoral triangle on the anteromedial aspect of the thigh. The femoral nerve innervates all muscles in the anterior compartment of the thigh. Also innervates skin over the anterior aspect of the thigh, anteromedial side of the knee, the medial side of the leg, and the medial side of the foot (Standring, 2008).

The **obturator nerve** originates from **L2 to L4**. It descends along the posterior abdominal wall, passes through the pelvic cavity and enters the thigh by passing through the obturator canal. The obturator nerve innervates all muscles in the medial compartment of the thigh, except the part of adductor magnus muscle the obturator externus muscle and skin on the medial side of the upper thigh (Standring, 2008).

The **sciatic nerve** is the largest nerve of the body and carries contributions from **L4 to S3**. It leaves the pelvis through the greater sciatic foramen inferior to the piriformis muscle, enters and passes through the gluteal region and then enters the posterior compartment of the thigh where it divides into its two major branches fibular nerve and the

tibial nerve. Sciatic nerve innervates all muscles in the posterior compartment of the thigh, the part of adductor magnus originating from the ischium and all muscles in the leg and foot (Standring, 2008).

The **gluteal nerves** are major motor nerves of the gluteal region. The **superior gluteal nerve** carries contributions from the anterior rami of **L4 to S1**, leaves the pelvis through the greater sciatic foramen above the piriformis muscle, and innervates the gluteus medius and minimus muscles and tensor fasciae latae muscle (Standring, 2008).

The **inferior gluteal nerve** is formed by contributions from **L5 to S2**, leaves the pelvis through the greater sciatic foramen inferior to the piriformis muscle, and enters the gluteal region to supply the gluteus maximus (Standring, 2008).

The **lateral cutaneous nerve of thigh** originates from **L2 and L3**. It leaves the abdomen either by passing through the gap between the inguinal ligament and the pelvic bone just medial to the anterior superior iliac spine or by passing directly through the inguinal ligament. It supplies skin on the lateral side of the thigh (Drake & Volg, 2009).

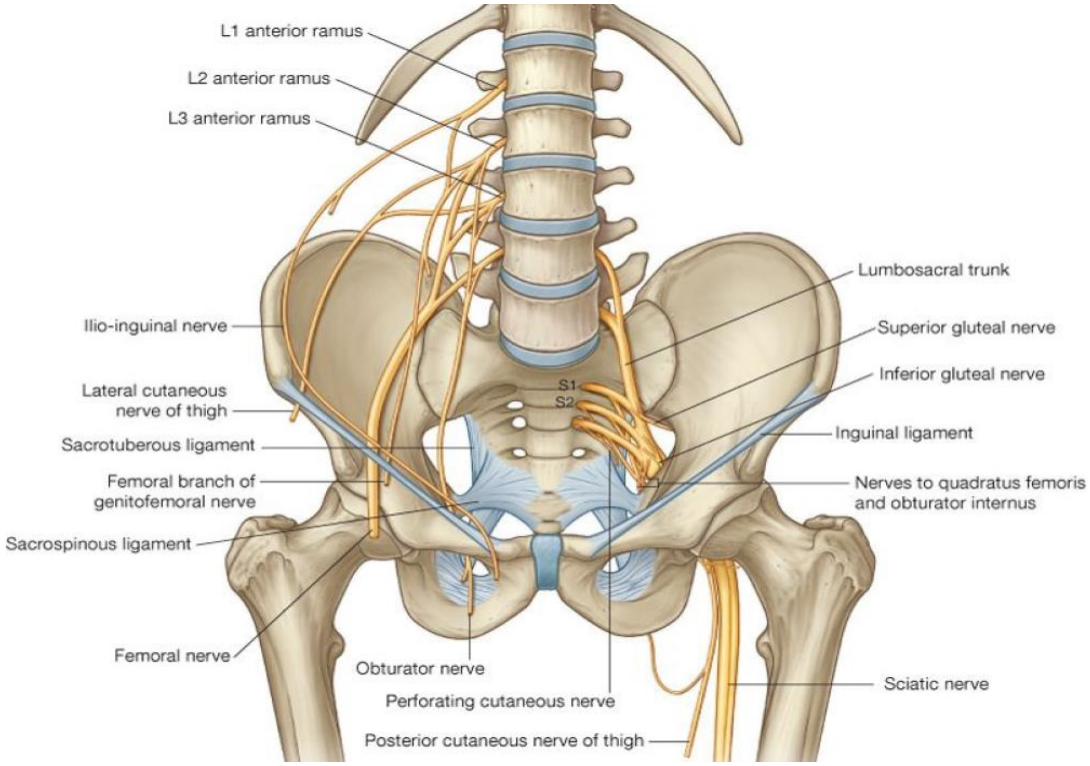

Picture 4 - Nerves passing through hip area (Drake & Volg, 2009).

2.1.7 **Cutaneous Innervation of Lower Limb**

Dermatomes are areas of the skin which are supplied by cutaneus branches from a single spinal nerve. The cutaneous nerves of the lumbar and sacral plexus are supplying the dermatomes of the lower extremities. The L1 through L5 dermatomes are positioned as a series of lines from the posterior midline of the trunk into the lower extremities. They continue inferiorly and laterally around the medial and anterior side of the lower extremeties (Moore & Dalley, 1999).

Furthermore, the dermatomes S1 and S2 follow a caudal direction and pass to the posterior aspect of the LE. Distally they are being separated near to the ankle joint so that the S1 dermatome passes from the lateral side of the foot and the S2 from the medial side of the foot (Moore & Dalley, 1999).

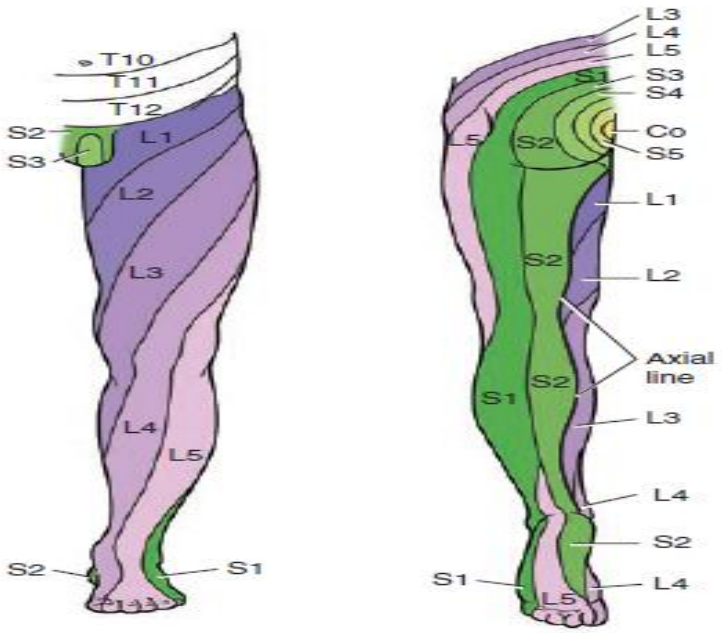

Picture 5 - The dermatome pattern of the lower limb according to Keegan and Garrett (Moore & Dalley, 2010).

2.1.8 **Muscles attached to the hip joint**

Gluteal muscles: Cover the lateral surfaces of the ilia. The **gluteus maximus** muscle is the largest and most posterior of the gluteal muscles. Its origin includes parts of

the ilium, the sacrum, coccyx, and associated ligaments and also the thoracolumbar fascia. Acting alone, this massive muscle produces extension and lateral rotation at the hip joint. The **gluteus medius** and **gluteus minimus** muscles originate anterior to the origin of the gluteus maximus muscle and insert on the greater trochanter of the femur. Gluteus medius and minimus act to abduct the hip joint (Moore & Dalley, 2010).

Hamstrings: Consist of three different muscles (semitendinosus, semimembranosus, and biceps femoris) at the posterior thigh are called the hamstrings. All three attach superiorly to the ischial tuberosity, the lowest part of the pelvis. Semitendinosus and semimembranosus inserts tibia, while biceps femoris has as an insertion the head of fibula. These muscles have two different activities to flex the knee joint and to extend also the hip joint (Paulsen & Waschkc, 2010).

Quadriceps: In relation with the hip joint **rectus femoris** muscle which originated to the anterior inferior iliac spine is part of the quadriceps femoris with the three vastus muscles **(**medialis, lateralis, intermedious**) .** All four muscles insert on the patella via the quadriceps tendon. Main function is to extend the knee joint and flex hip joint (Moore & Dalley, 2010).

Ilipsoas: The iliopsoas is the strongest flexor of the hip. It is a blending of two muscles, the psoas major and the iliacus. The psoas major is a powerful flexor muscle of the thigh at the hip joint. Iliopsoas attach the lower part of the spine and pelvis, then cross the joint and insert into the lesser trochanter of the femur (Drake & Volg, 2009).

Adductor muscles: Consists of adductor longus, adductor brevis, adductor magnus, gracilis and pectineus. They are attaching to the pubis and inserting the medial side of the thigh, exept of gracilis which inserts tibia (Moore & Dalley, 2010).

Some other muscles that are attached and have relation with the hip area are the external rotators of the hip which are: Obturator internus and externus, Gemelli, Piriformis, Quadratus femoris (Rodgers, 1982).

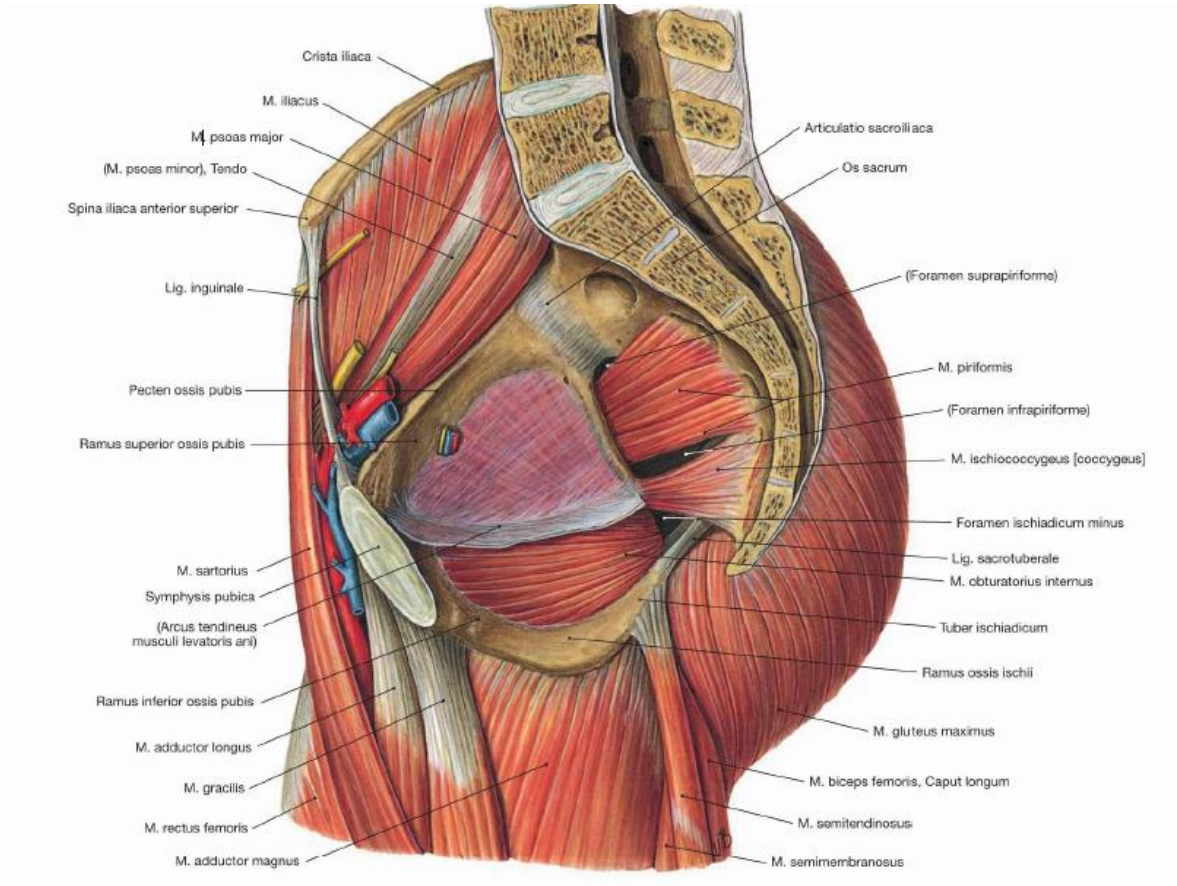

Picture 6 - Muscles of the hip and thigh (Paulsen & Waschkc, 2010).

2.1.9 **Blood supply of hip joint**

The main blood supply of the hip joint is from the retinacular arteries arising as branches of the circumflex femoral arteries. Retinacular arteries arising from the medial circumflex femoral artery are most abundant, bringing more blood to the head and neck of the femur because they are able to pass beneath the unattached posterior border of the joint capsule. Retinacular arteries arising from the lateral circumflex femoral must penetrate the thick iliofemoral ligament and are smaller and fewer (Moore & Dalley, 2010).

- The medial and lateral circumflex femoral arteries, which are usually branches of the deep artery of the thigh but occasionally, arise as branches of the femoral artery.
- The artery to the head of the femur, which is a branch of the obturator artery of variable size; it traverses the ligament of the head (Moore & Dalley, 2010).

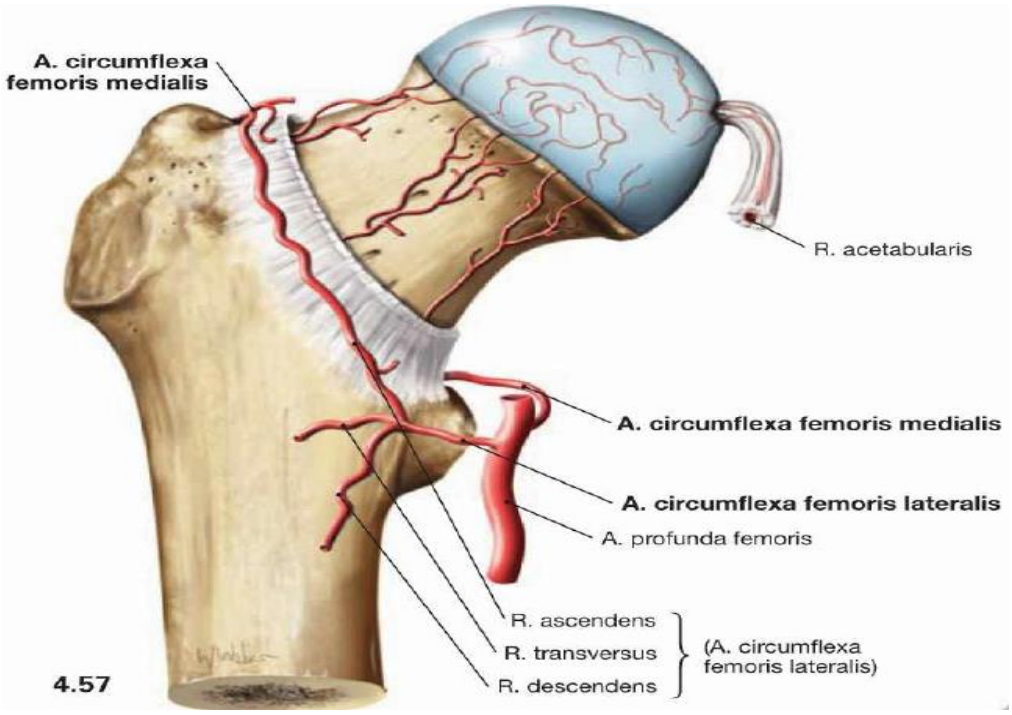

Picture 7 - Blood supply of hip area-anterior view (Paulsen & Waschkc, 2010).

2.2 **Biomechanics of hip joint**

The hip joint connects the upper and lower parts of the human body, bearing our entire upper body weight and thus playing an important role in the musculoskeletal system. An understanding of the biomechanics of the hip is vital to advancing the diagnosis and treatment of many pathologic conditions (Byrne, et al. 2010).

2.2.1 **Relevance of anatomy to biomechanics**

Most hip replacements are performed to treat osteoarthritis, and in most cases the hip will have been normal prior to the development of osteoarthritis. In such cases the aim of joint replacement is to restore the soft tissues to their pre-disease tension, position and anatomy, which can only be achieved by recognizing the original anatomy and correct placement of the implants (Sariali, et al. 2008).

2.2.2 **Basics of hip biomechanics**

Forces and their lever arms acting around the hip joint during single leg stance are shown in picture below (Pic 8). When the body is in equilibrium, the sum of the rotational torque acting around the hip will be zero (Sariali, et al. 2008).

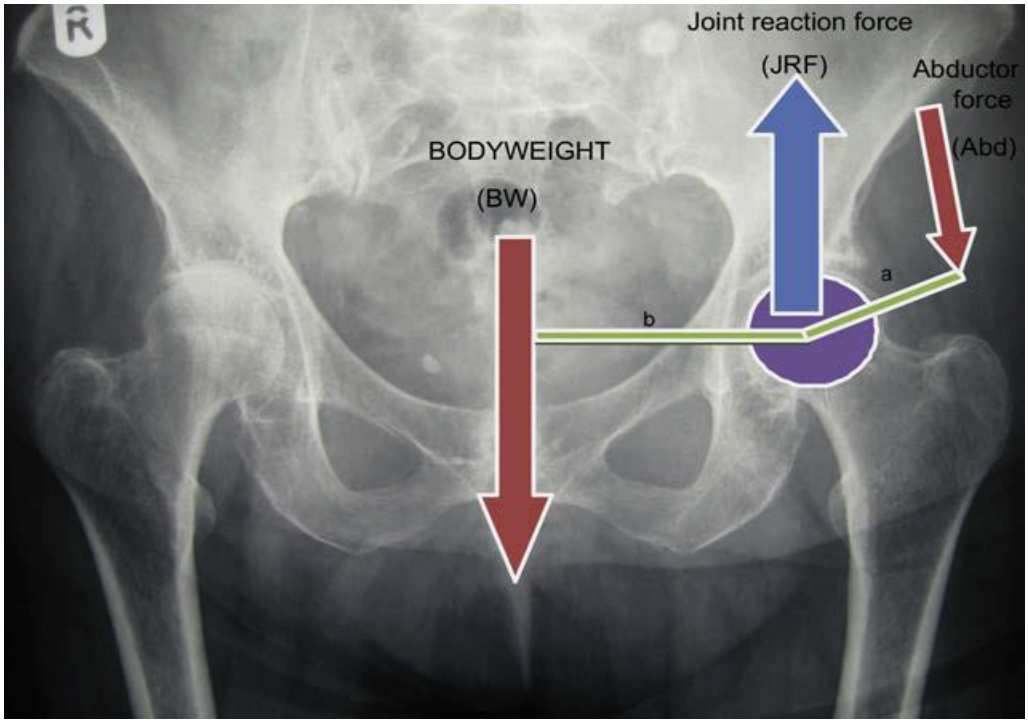

Picture 8 - Schematic of acting on hip forces during one leg stand (Sariali, et al. 2008).

Forces acting on the hip joint: The body weight can be depicted as a load applied to a lever arm extending from the body's center of gravity to the center of the femoral head (Pic-8). The abductor musculature, acting on a lever arm extending from the lateral aspect of the greater trochanter to the center of the femoral head, must exert an equal moment to hold the pelvis level when in a one-legged stance and a greater moment to tilt the pelvis to the same side when walking (Canale & Beaty, 2012).

The estimated load on the femoral head in the stance phase of gait is equal to the sum of the forces created by the abductors and the body weight and has been calculated to

be three times the body weight. The load on the femoral head during straight-leg raising is estimated to be about the same (Canale & Beaty, 2012).

2.2.3 **Biomechanics of hip during walking**

The walking cycle is characterized by two peaks of load at heel-strike and at toe-off which generally range from 3–4 times our body weight. Between these two loading peaks the body's mass (head and torso) is moving smoothly and is not translated vertically a large amount. As such the reaction force at the hip between heel-strike and toe-off is relatively small and in the region of body weight. At toe-off the hip is extended 15 degrees. The quadriceps muscle acts to stabilize the knee whilst the gastrocnemius muscle produces plantar flexion at the ankle. These muscle forces combine to accelerate the body forward producing the second peak of load in the reaction force curve (Steward & Halla, 2006).

2.2.4 **Measurements of hip joint forces after total endoprothesis of hip**

On this part of biomechanics I would like to mention about a special research for hip biomechanical forces. On this research a group of scientist and physician try to measure the forces acting to the hip joint in a variety of different movements. On this research the participants were patients after total endoprothesis of hip. Scientists with a special vivo measurements and endoprothesis instrumented with transducers tried to calculate the biomechanical forces acting to the hip joint and find the differences in each movement (Byrne, et al. 2010).

Activity	Typical Peak Force (BW)	Total Number of Patients	Time Since Surgery (Months)
Walking, slow	1.6-4.1	9	1-30
Walking, normal	2.1-3.3	6	1-31
Walking, fast	1.8-4.3	7	2-30
Jogging, running	4.3-5.0	2	6-30
Ascending stairs	1.5-5.5	8	6-33
Descending stairs	1.6-5.1	7	6-30
Standing up	1.8-2.2	4	11-31
Sitting down	1.5-2.0	4	11-31
Knee bend	1.2-1.8	3	11-14
Stumbling	7.2-8.7	2	4-18

Picture 9 - Hip Contact Forces Measured In Vivo in Patients with Instrumented Implants (Byrne, et al. 2010).

The results of the research shows that the patients in early postoperative period can execute their activities of daily living without too much contact forces acting to the hip joint. But as you can see to the table above (Pic 9) there is some unexpected movement or activities such as stumbling when the hip joint is in unstable position which can produce resultant forces around the hip up to eight times of the body weight (Byrne, et al. 2010).

2.3 **Kinesiology of hip joint**

The hip joints realize the link between the pelvis and the legs. Hip joint is a ball and socket joint. The deep pan of acetabulum with surrounding labrum interlocks the head of femur and restricts the mobility in comparison with the similar ball and socket joint. The capsule of the hip joint is strengthened by very strong ligaments, which ensures this movable connection before disarticulation. The femur is connected to the pan of the hip joint throw the femoral neck and the angle between the shaft and the neck is normally 125°. This angle plays an important role for the function of lower limbs (Panek, 2012).

Between the lower extremity and the lumbar spine exists near relations. A fault in the hip joint may project into the lower back as well as the fault in the lower back may

project into the hip joint and in the lower extremity because the muscles of the lower extremity innervated by spinal nerves arising from the lumbar spine.

Pelvis creates an adaptable currying and supporting base for the trunk. From the position of the pelvis in upright standing we can assess the function of muscles connecting the pelvis with the trunk and with lower limbs and evaluate their interplay (Panek, 2012).

Pelvic mobility: Possible movements are anteflexion, retroflexion, lateral flexion, torsion (in standing) and rotation (in walking) (Neumann, 2010).

Muscle groups operating within the pelvic girdle:

Hip flexors (iliopsoas, rectus femoris, pectineus): Flex the hip joint in combination with adduction and internal rotation. If the femur is fixed, the pelvis is tilted forward. Shortening of this muscles inreases lumbar lordosis combined with overloading the hip joint. This may initiate the coxarthrosis (Neumann, 2010).

Hip extensors: Extend the hip joint. M. gluteus maximus is the strongest muscle of this group. It participates also on the propulsion force developed during walking together with M. triceps surrae acting as the leading proposal (Panek, 2012).

Hamstrings: Are activated in standing and in walking on plain ground. Activity of knee flexors depends on the range of extension of the knee joint. Feeble knee flexors worsen the balance, which must be kept in standing throw dorsal muscles (Neumann, 2010).

Hip abductors: Anterior group (tensor fascie latae, gluteus medius and minimus) execute abduction combined with flexion and internal rotation. Posterior group (gluteus medius posterior part, minimus and the part of gluteus maximus execute abduction combined with extension and external rotation. Gluteus medius is responsible for stability of pelvis in horizontal position during walking. Unilateral weakening of this muscle cause lateral tilt of the pelvis and bilateral weakening cause the rocking duck walk (Panek, 2012).

Hip adductors: They stabilize also the pelvis in walking and running but they play an important role in postural adaptation. These muscles react earlier than other muscles

because of their increased excitability and they have also tendency to shortening (tested by the Patrick sign). They are very sensible and participate in the stabilization of the upright standing.

External rotators: They perform external rotation of femur and press the head of the femur into the acetabulum of the hip joint. They have the tendency to shortening and this causes limitation of the internal rotation. This limitation considers Cyriax (Cyriax's articular pattern) as the first symptom of arthritic changes in the hip joint even if all other movements in hip joint are still in normal range. He considers this limitation of internal rotation as articular pattern, typical for beginning of coxarthrosis (Panek, 2012).

Internal rotators: From this group is important muscle tensor fasciae latae with a tendency to shortening which influences the function of the knee joint (Neumann, 2010).

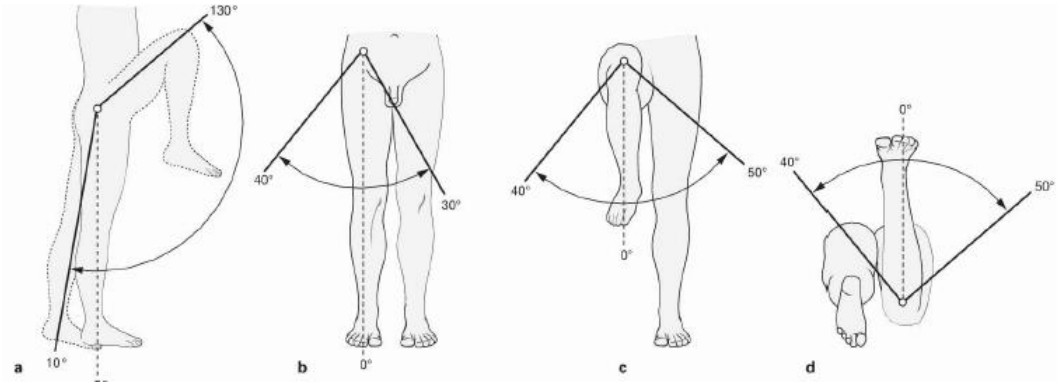

Picture 10 - Range of movement on hip joint (Paulsen & Waschkc, 2010).

2.4 Arthritis

Arthritis comprises more than 100 different rheumatic diseases and conditions, the most common of which is osteoarthritis. Other frequently occurring forms of arthritis include rheumatoid arthritis, lupus, fibromyalgia, and gout. Common symptoms include pain, aching, stiffness, and swelling in or around the joints (Marks, 2009).

2.4.1 **Definition of the disease**

As I mentioned above arthritis is a group of diseases and conditions with the most common type to be osteoarthritis. And because my patient in my case study was suffering from osteoarthritis in the hip joint I would like to mention below the definition of osteoarthritis (McAlindon & Dieppe, 2014).

Osteoarthritis (OA) is the most common form of chronic arthritis. Osteoarthritis means a heterogeneous group of conditions that lead to joint symptoms and signs which are associated with defective integrity of cartilage, in addition to the related changes in underlying bone and at the joint margin (McAlindon & Dieppe, 2014).

2.4.2 **Etiology**

There are multiple factors that interact to cause osteoarthritis. In the text below there is some of the most important general reasoning of the disease (Cibulka, et al. 2009).

Age: Although advance osteoarthritis may occur in many young people, the frequency of condition escalates markedly in advancing years. Furthermore, older people are found to have rapid radiological progression of osteoarthritis.

Genetic: Hip osteoarthritis has a significant genetic component. Nodal generalized osteoarthritis is a polyarticular form of osteoarthritis characterized by Heberden's nodes.

Bone density: Negative association has been reported between osteoporosis and osteoarthritis at certain sites particularly the hip.

Joint location: OA is more common in hip and knee joint but occur rarely in ankle. Alteration in chondrocyte responsiveness to different cytokines is one of the reasons.

Sports Exposure: Epidemiological studies have demonstrated participation in certain competitive sports to increase the risk for osteoarthritis (Cibulka, et al. 2009).

Leg length disparity: Several studies have suggested a difference in leg lengths may be an important etiological factor in hip OA. A few studies have demonstrated the

biomechanical and clinical problem of leg length disparity and its relationship to hip OA (Cibulka, et al. 2009).

*Also there are some other factors which can lead and be the causing of osteoarthritis: Prolonged immobilization, joint hypermobility or instability and also peripheral neuropathy (Mahajan, 2005).

2.4.3 **Etiopathology**

Normally, cartilage undergoes a remodeling process, stimulated by joint movement or use. In osteoarthritis, this process is altered by a combination of mechanical, cellular, and biochemical processes, resulting in abnormal reparation of cartilage and an increase in cartilage degradation (Dewing, et al. 2012).

Osteoarthritis is primarily characterized by progressive cartilage loss, accompanied by an increased thickness of the subchondral plate, osteophytes and subchondral bone cysts (Pic 11). With disease progression, vascular invasion and further calcification of nearby articular cartilage may occur, leading to decreased thickness of articular cartilage and, over time, bone remodeling and enhanced cartilage deterioration (Dewing, et al. 2012).

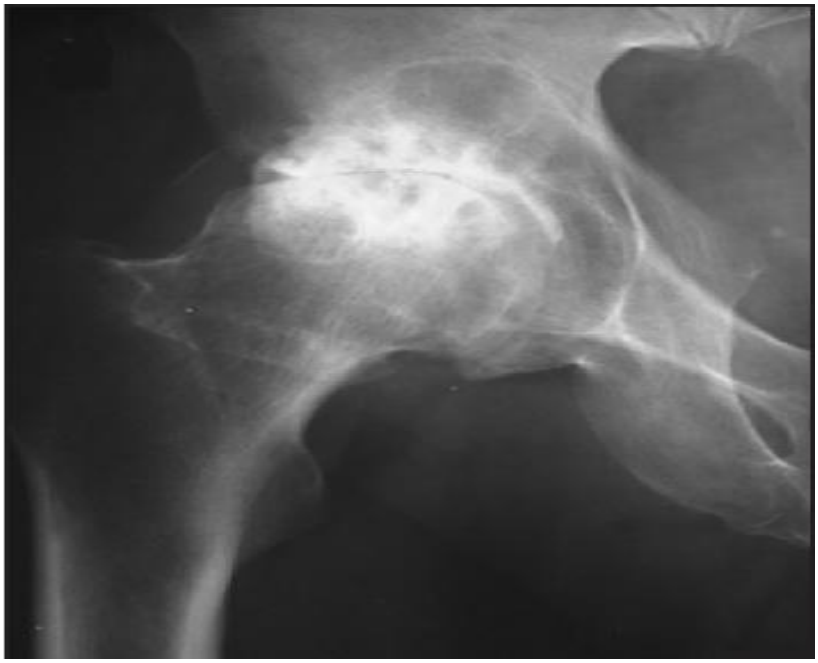

Picture 11- Anteroposterior radiograph of the right hip showing end-stage osteoarthritis with complete loss joint space, osteophyte formation, and subchondral cysts (Pivec, et al. 2013).

2.4.4 **Clinical picture**

Osteoarthritis as I mentioned above is characterized by destruction of articular cartilage and reactive bone changes and is associated clinically with regional pain, stiffness and dysfunction (Dagenais, et al. 2009).

The first symptom of hip OA is often groin pain, which may also be referred to a wide area, including the buttock, lateral or anterior thigh, medial side of the knee, and occasionally as distally as the ankle joint (Dagenais, et al. 2009).

Signs of hip OA on clinical picture include a painful restriction of both active and passive hip motions which leads to an antalgic gait (Dagenais, et al. 2009).

2.5 **Physiotherapeutic examination**

Anamnesis – history

This is one of the most important parts of examination which can help and lead the physiotherapist to an almost correct diagnosis before even has physical contact with the patient. On this part of the examination physiotherapist asks from the patient to describe how he or she feels right now and also to describe the mechanism of injury. Physiotherapist also asks about how and when the pain started and during which circumstances has the felling of pain. Also he or she will be asked patient about what kind of symptoms and if these symptoms affect his or her activities of daily living.

Additionally, in this part of the examination which is the base for a correct diagnosis there are questions about personal anamnesis of the patient, social anamnesis, previous operation and injuries. Also therapist asks about family anamnesis and if any member of patient's family suffers from similar medical state. Finally there are some questions about allergies, abuses and medication which can be helpful for physiotherapist to organize the therapeutic plan (Čemusová, 2011).

Observation of the scar

This examination is significant for patients after total endoprothesis of hip or any surgical intervention. In this examination therapist want to observe any possible complication around the scar. After the operation there is possibility in the area around the scar will be swelling with differences in the soft tissues. Also differences in the temperature and color of the skin may be present due to unwanted inflammation (Satrapova, 2012).

Postural examination

Postural examination is essential because faulty alignment results in exerting excessive stress on bones, joints, ligaments and muscles. An assessment of joint positions indicates which muscles are in shortened and which are in elongated position.

For patient after total endoprothesis of hip joint there will be antalgic position of standing due to difference in weight bearing in lower extremities. Operated lower limb may be in semi flexion in the knee due to pain and as I mentioned before because of difference in bearing. Also due to operation there is a possibility that patient's trunk to be tilt to non-operated side and one shoulder can be higher than the other according the side of the operation (Jalovcová, 2011).

Dynamic examination

Dynamic examination of the spine in all the possible directions to identify the function of trunk muscles and generally the movement of the spine which is closely related to pelvis and in continue to the hip joint (Jalovcová, 2011).

Gait examination

Gait examination informs us about the quality of normal or pathological motoric function. In case of total endoprothesis of hip due to arthritis there can be observe antalgic type of gait because of the operation and the pain. Asymmetry of step's length and slower rhythm of gait can be present. Additionally quality of gait phases can be disturbed because

of muscle weakness in lower limbs. In this case gait examination is provided with the patient holding crutches and walk into the corridor under investigation (Jelinkova, 2011).

Basic movement pattern examination

Evaluation of basic movement pattern (hip abduction & extension) can be done in case of osteoarthritic hip joint. It is useful because physiotherapist can observe if the movement stereotype is the proper and also to check if the activation of the muscles is in right order (Pavlů, 2012).

Anthropometric measurements

Physiotherapist is competent to examine the anthropometric measurements of the length, height and circumference of the lower limbs. Compare the difference in case of swelling in the operated lower limb. Patient in this examination must be totally relaxed. And in case of osteoarthritis in hip joint must be important any asymmetric length of lower limbs (Jalovcová, 2011).

Range of motion (ROM)

The amount of motion which is available in the joint refers to the range of motion. Range of motion is a result of the function of all components surrounding the joint (capsules, ligaments, muscles, tendons and soft tissues).

After total endoprothesis of hip physiotherapist is competent to provide measurement of ROM in hip joint (flexion till 90 degrees-extension, abduction) no contraindicated rotational motions and adduction, knee joint (flexion-extension) but also ankle joints (dorsal-plantar flexion, inversion-eversion).

ROM classification: SFTR method (Jalovcová, 2011).

Palpation and Muscle Tone examination, according to Lewit

By palpation and muscle tone examination physiotherapist looking for any differences in tone of muscles of lower limbs.

For stage after total endoprothesis of hip joint physiotherapist is able to control the tone of the muscles in lower limbs (hamstrings, quadriceps, tensor fascia late, adductors, gluteal muscles, ilopsoas, piriformis, triceps surrae and also paravertebral muscles of lumbar and thoracic spine. Therapist also checks about presence of any trigger point in these muscles that I mentioned above (Lewit & Richard, 2009).

Muscle strength test, by Kendall

Muscle strength is a condition when muscle exerts physical force. There are three types of contraction: isometric, eccentric and concentric.

Physiotherapist in case of total endoprothesis of hip can evaluate the strength test of muscles: quatriceps femoris, gluteus maximus, gluteus medius, gluteus minimus, tensor fasciae latae, tibialis anterior, gastrocnemius, soleus and other muscles of lower leg and foot if it is necessary (Kendal, et al. 2005).

The grading for measuring the muscle strength, by Kendal: 0 to 5 (0-gone, 1-trace, 2-poor, 3-fair, 4-good and 5-normal).

Soft tissue examination, by Lewit

The soft tissues surrounding the motor system must adapt to all the changes of shape during any movement or any posture. As I mentioned above after total endoprothesis of hip there will be possible changes in soft tissues in both legs. On the operated side due to operation and long immobilization and to the non-operated side because of abnormal using and more weight absorption.

After the surgery therapist can provide examination of soft tissues on skin, subskin and fasciae around hip area, anteriorly and posteriorly to the thigh and lower leg (Lewit & Richard, 2009).

Joint play examination, by Lewit

Joint play is the passive small movement between two bones in one articulation (joint). After state of total endoprothesis of hip usually there is restriction of joint play in the joint of lower limbs in both sides.

Physiotherapist is able to examine all the joints of the lower limb except the operated hip joint-Knee, tibiofibular, talocrural, Chopart, Lisfranc, metatarsophalangeal and interphalangeal joints (Lewit & Richard, 2009).

Neurological examination

Physiotherapist is also able to provide neurological examination which is very important after total endoprothesis of hip because after the surgery there is possibility of nerve paresis. This examination includes:

Therapist uses the fingers to touch the skin of the patient lightly on both sides simultaneously. He/she tests several areas on lower extremities and patient mentioned if the sensation is the same in both sides and if is normal or pathological feeling.

General principle: Patient's eyes should be closed during the examination. Physiotherapist compares symmetrical areas on the two sides of the body (Panek, 2012).

Deep sensation test

On this test firstly physiotherapist asks the patient to close his/her eyes. Then the therapist move passively one limb of patient. Finally patient asked if is able to reach the same position with approximately same range of motion.

Also in neurological examination physiotherapist can be examine the deep tendon reflex (Panek, 2012).

Special tests

Trendelenburg test is given to investigate the stability of the hip joint while walking. This test examine if gluteus medius is weak or if the function it is proper or not. The patient was asked to stand in one leg with the contralateral one being flexed at 90° at the knee and hip joints. During the examination, if the examined hip joint loses its balance, the test is positive and expresses the instability of the target joint.

2.5.1 **Physician examination**

Characterized by degenerative changes in the bones, cartilage, ligaments, and synovial tissue, osteoarthritis (OA) has evolved to be considered a disease of the whole joint. Using imaging, OA has traditionally been diagnosed by:

Radiography: Despite the development of newer imaging techniques, the radiograph remains the most accessible tool in the evaluation of the OA joint. There are certain x-ray signs which can help specialist formulate impressions and diagnose osteoarthritis. The findings include: joint space narrowing, development of osteophytes, subchondral sclerosis and subchondral cyst formation (Braun & Gold, 2011).

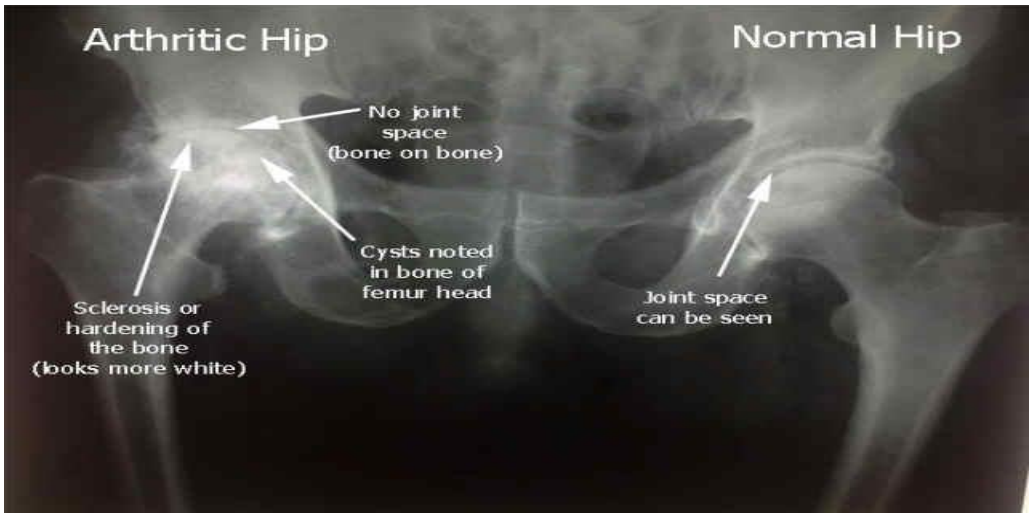

Picture 12- X-ray imaging of osteoarthritic hip (Wolgin, 2012).

MRI: Manipulates image contrast to highlight different tissue types. Common contrast methods include 2D or multi-slice- weighted proton density, and weighted imaging. Spinecho and Fast-spinecho imaging techniques are useful in evaluating focal cartilage defects (Braun & Gold, 2011).

OCT: Optical coherence tomography captures cross-sectional echographs of infrared light and acquires near-real time images of articular cartilage**.** This method requires placement of the endoscope immediately on the cartilage, so is done at the time of arthroscopy. OCT has been shown to be sensitive to collagen structural changes resulting

from degeneration and OA-associated changes in cartilage birefringence. But it is a new technique not used so often in clinical practice (Braun & Gold, 2011).

CT (computed tomography): Is used for demonstrating the degree of osteophyte (bone spur) formation and its relationship to the adjacent soft tissues. CT examinations are also useful in providing guidance for therapeutic and diagnostic procedures.

Ultrasound: is extremely sensitive for identifying synovial cysts that can form in association with osteoarthritis (Braun & Gold, 2011).

2.6 **Treatment**

2.6.1 **Non-surgical treatment-Physiotherapeutic**

Exercise is an important component of management of OA as both a preventive strategy and to treat symptoms. Physical exercise of a light to moderate intensity increases muscle strength as well as range of motion, aerobic capacity, and endurance that contributes to improved physical functioning and pain reduction (Cvjeticanin, et al. 2009).

Traction: Traction is a force that is used therapeutically to produce elongation or stretch of joint structures which is indicated for osteoarthritis. Traction may be applied manually or mechanically by device, static weights or positional distraction may also be used. The effects that traction produced are relief of pain, stretching of tight musculature, and improved circulation. These techniques are suitable for patients who do not have signs of severe hip OA such as osteophytes and significant joint space narrowing (Cibulka, et al. 2009).

Physical therapy modalities:

Electrical stimulation: Many types of electrical stimulation modalities are currently available for use in treatment of osteoarthritis because they have the ability to reduce pain [Trascutaneous electrical nerve stimulation (TENS)] (Kendall, et al. 2005).

Thermotherapy: Involves the application of heat or cold (heat or ice pack, ice massage) to treat symptoms of OA. Cold has an effect by reducing swelling and inflammation, numbing pain and blocking nerves impulses and muscle spasms to the joint. The therapeutic effects of heat include relief of pain, decreased joint stiffness and increased extensibility of collagen tissue which are the main symptoms of osteoarthritis (Kendall, et al. 2005).

Massage therapy: Massage is also appropriate when a patient suffering from osteoarthritis. The goal is to relieve excessive edema that restricts motion in the affected joint. Swelling usually occurs in acute phase of osteoarthritis (Kendall, et al. 2005).

Acupuncture: Can reduce pain and improve both physical function and related quality of life, and is widely used by patients suffering from osteoarthritis (Henrotin, et al. 2012).

Pulsed Electromagnetic Field Therapy: Suggested as an alternative treatment for OA. Physical stress on bone leads to the appearance of piezoelectric potentials that may act as the transduction signals that promote bone formation. It is thought that similar mechanism exists in cartilage that stimulates chondrocytes to increase proteoglycan synthesis (Henrotin, et al. 2012).

Hydrotherapy and Spa: An analgesic effect of mineral baths it is used to treat patients who are suffering from osteoarthritis. Also special exercises into the water can be beneficial because of buoyancy and there is significant decrease of pressure which acts on the affected joint (Henrotin, et al. 2012).

2.6.2 **Pharmacological treatment**

Except the physiotherapeutic treatment of osteoarthritis some physicians suggests also as a complementary approach, the pharmacological treatment to relief pain and reduce inflammation.

According these patients who are indicated to use this special medications are using the following types of medicament: simple analgesics, topical analgesic and non-steroidal anti-inflammatory drugs (Moskowitz, et al. 2006).

2.6.3 **Indication for surgical intervention**

Total hip replacement is one of the most successful and effective interventions in medicine. It offers reliable relief of pain and considerable improvement in function in patients suffering with osteoarthritis. There are some specific indications which must be present which leads to a total endoprosthesis operation (Crowford & Murray, 1997).

Pain is the principal indication for hip replacement and is reliably relieved as early as one week after surgery. Pain from an arthritic hip is classically located in the groin and buttock.

Functional limitations: In osteoarthritis functional limitations are usually associated with pain. Capsular contractions and joint deformity cause a decreased range of motion in the hip, which typically leads to patients complaining of problems in activities of daily living. Severe disability, particularly if it is threatening employment or having important psychosocial consequences, may also be an indication for surgery (Dieppe, 1995).

Radiographic changes: The severity of the radiographic changes of arthritis within the hip joint usually but not always reflects the severity of the patients' disability.

Age: Most hip replacements are performed in patients between 60 and 80 years of age, older or younger age is not a contraindication to surgery. Elderly patients with osteoarthritis are undergoing total hip replacement to have a greater life expectancy than the average (Crowford & Murray, 1997).

The general adage that surgery is indicated if a patient cannot work, sleep, walk, or exercise gives some idea of the issues other than severity of pain that should be considered (Dieppe, 1995).

2.6.4 **Surgical treatment**

In most cases people with severe progress of osteoarthritis can manage their symptoms by choosing the surgical intervention. Among the well-known and used surgical approaches are: arthroscopy, arthrodesis, hip resurfacing surgery, osteotomy and joint

replacement. The latter one is the most commonly used for patients suffering from what it comes along with osteoarthritis in the manner of pain and joint dysfunction (Canale & Beaty, 2012).

Many variations have evolved in the surgical approaches and techniques used for total hip endoprothesis. The surgical approaches differ chiefly as to whether the patient is operated on in the lateral or the supine position and whether the hip is dislocated anteriorly or posteriorly. The surgical protocol for a given total hip system may advocate a certain approach (Canale & Beaty, 2012).

Amstutz advocated the anterolateral approach with osteotomy of the greater trochanter, but with the patient in the lateral rather than the supine position. The Müller technique also uses the anterolateral approach with the patient in the lateral position but includes release of only the anterior part of the abductor mechanism. The Hardinge direct lateral approach is done with the patient supine or in the lateral position (Canale & Beaty, 2012).

Selection of total hip components

Total hip femoral and acetabular components are commonly marketed together as a total hip system. The primary function of the femoral component is the replacement of the femoral head and neck after resection of the arthritic segment. The ultimate goal of a biomechanically sound, stable hip joint is accomplished by careful attention to restoration of the normal center of rotation of the femoral head. Acetabular components can be broadly categorized as cemented or cementless. The original sockets for cemented use were thick-walled polyethylene cups with vertical and horizontal grooves and wire markers. Most cementless acetabular components are porous coated over their entire circumference for bone ingrowth. There has been a trend toward cementless fixation of acetabular components in most patients. The simplicity and low cost of all-polyethylene components make them a satisfactory option in older, low-demand patients (Canale & Beaty, 2012).

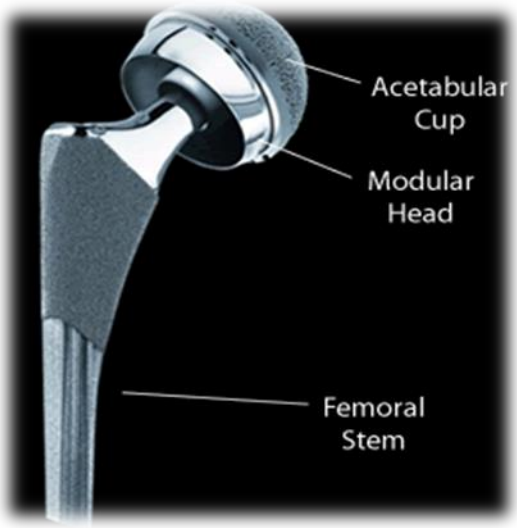

Picture 13- Femoral and acetabular components (Stevens, 2012)

Hip Replacement Implant Materials

There are a large number of hip implant devices. Each manufacturer has different models but each style falls into one of three basic material categories:

Highly crosslinked polyethylene – According test data from contemporary hip simulators have shown an 80% to 90% reduction in wear with highly crosslinked polyethylenes (Canale & Beaty, 2012).

Metal on metal - High-carbon cobalt-chromium alloy has been demonstrated to have lower wear rates than low carbon alloys. The clinical experience with metal-on-metal hip arthroplasty now exceeds 40 years. Some implants have survived with a remarkably low wear rate (Canale & Beaty, 2012).

Ceramic on ceramic - Alumina ceramic has many properties that make it desirable as a bearing surface in hip arthroplasty. Because of its high density, implants have a surface finish smoother than metal implants. This implant is recommended in patients with demonstrated metal hypersensitivity (Canale & Beaty, 2012).

Picture 14- Hip Replacement Implant Materials (Cambon, 2014).

2.6.5 **Complication of surgical treatment**

Complications associated with total hip endoprothesis can be divided into those that are directly related to the surgical procedure in the intraoperative, early postoperative and late postoperative periods and others that may affect non musculoskeletal organ systems in the perioperative period. There are the most frequent complications after total endoprothesis of hip:

Formation of hematoma: Common sources of bleeding are the branches of the obturator vessels that may be cut when the ligamentum teres, transverse ligament, and osteophytes are removed from the inferior aspect of the acetabulum (Canale & Beaty, 2012).

Thromboembolism: Thromboembolic disease is one of the most common serious complications arising from total hip endoprothesis. Thromboembolism can occur in vessels in the pelvis, thigh and calf (Skinner & Fitzpatrick, 2008).

Nerve injuries: The sciatic, femoral, obturator and superior gluteal nerves can be injured by direct surgical trauma, traction, pressure from retractors or components, extremity positioning, limb lengthening, and thermal injury from cement (Skinner & Fitzpatrick, 2008).

Limb length discrepancy: Ideally, the leg lengths should be equal after total hip endoprothesis, but leg length is difficult to determine accurately at the time of surgery.

Overlengthening is more common than a residually shortened leg, and a lengthened limb is more poorly tolerated (Skinner & Fitzpatrick, 2008).

Lengthening may result from insufficient resection of bone from the femoral neck, from use of prosthesis with a neck that is too long or from inferior displacement of the center of rotation of the acetabulum (Canale & Beaty, 2012).

2.6.6 **Postoperative rehabilitation**

It is essential as in every surgical procedure the recovery period that follows. The physician introduces a plan which the patient should obey in order to recover as fast as possible.

The goal of physical therapy during the early post-operative phase is to educate the patient regarding contraindication movements, increase independence with function and prevent postoperative surgical impairments. These impairments may include:

- Edema
- Pain
- Decreased range of motion
- Impaired muscle control and strength in the involved lower extremity
- Balance
- Decreased proprioception (Ellis & Petrik, 2011).

Total hip precautions after surgery should be followed for 3 months and include:

- Avoid hip flexion more than 90°
- Avoid internal rotation of the hip joint
- Avoid crossing the midline of the body (adduction)
- Avoid sitting on low, soft surfaces (Beagan, 2011).

Another important fact that must be controlled after total endoprothesis of hip is how weight bearing should distributed always according to the type of the material that is used from the surgeon.

- Partial weight-bearing: 20-50% of body weight
- Weight-bearing as tolerated: 50-100% of body weight
- Full weight-bearing: 100% of body weight

In patients with cemented hip replacements include stable fixation that allows immediate full weight bearing on the operative hip. On the other hand, in non-cemented hip replacements require partial weight bearing for four to six weeks. Patients allow walking without any assistive device and putting full weight bearing usually after 3 months (Mont & Tankersley, 1997).

The therapeutic plan is divided into 4 phases which aim to decrease pain and edema, restore muscle strength, and increase range of movements as it will be mentioned bellow.

Phase 1 – Initial phase: Weeks 1-3

During this period concerning the therapeutic activity and functional mobility patient deals with active movements in the involved and injured hip so that to gain strength and prevent DVT, passive movements in order to achieve increase in ROM, isometric exercises for muscle group in hip region, lower extremity ROM as indicated and strengthening, bed mobility with instructions about transferring and gait training in the room and corridor depending on the condition of the patient by using an assistive device (Ellis & Petrik, 2011) (Beagan, 2011).

Phase 2 – Intermediate phase: Weeks 4-6

According to this phase the exercises progress to be more demanding and complex including strengthening exercises for all the muscle groups of the operated lower extremity in all directions within the limitations, proprioceptive training to improve body/spatial awareness of the operative extremity in functional activities, endurance training to increase cardiovascular fitness as in walking, functional training to promote independence in activities of daily living and mobility and managing to climbing stairs (Ellis & Petrik, 2011) (Beagan, 2011).

Phase 3 – Advanced phase: Week 7 – 3 months

Continue with previous or modified versions of previous exercises, but may add resistance with the use of elastic bands and weights for the performance of the exercises as indicated and mentioned above, provide patients with open/closed chain activities that are appropriate for each patient's individual needs, initiate endurance program (walking and/or pool), initiate and progress age-appropriate balance and proprioception exercises (Ellis & Petrik, 2011) (Beagan, 2011).

Phase 4 – Final phase: 3 months +

As it's the final stage of the overall rehabilitation plan it may consist of exercises with progression of resistance and repetitions for the entire body, increased duration of endurance activities, initiate return to specific recreational activity: golf, doubles tennis, progressive walking, biking program, aquatic exercise, low impact aerobics, yoga, Tai Chi, theraball exercises and also using lower extremity weight machines (Ellis & Petrik, 2011) (Beagan, 2011).

3.

SPECIAL PART

3.1 **Methodology**

My clinical work practice took place in Ústřední Vojenská Nemocnice in Prague. It started on Monday 3rd of February 2014 and finished on Friday 14th of February 2014 (10days). Each day had the duration of 8 hours. The total amount of the hours of my practice was 80.

My clinical work placement was supervised by Dis. Petr Smejkal. The diagnosis of my case is Total Endoprothesis of right hip joint. The sessions with my patient were six in total. They started on Tuesday 4th of February 2014 and continued on a daily basis. The last session took place on Tuesday 11th of February 2014.

Mainly the therapeutic procedures that I used were manual therapy, which took place in a room of the orthopedic department and also in an exercise room. I utilized mostly my hands for the examination and therapy. Goniometer, measurement tape and neurological hammer were the tools that I needed for the examination procedures. For the therapeutic procedures I also used a Swedish ball. The patient had stiches during the first days of the therapeutic sessions.

The patient was fully aware of the examination and therapeutic procedures at any given time, no invasive methods were used and a proposed informed consent was also assigned by the patient and me.

My work has been approved by the Ethics Committee of the Faculty of Physical Education and Sport at Charles University, under the approval number 103/2014.

3.2 **Anamnesis:**

Examined person: E.J, 1943, MALE

Diagnosis: Total endoprothesis of hip joint. (Right side)

Personal characteristics of the patient:

Height: 1.81 meters

Weight: 87 kilograms

BMI: 26.6

Family anamnesis: Both of his parents were healthy with not any serious illness.

Personal anamnesis: Patient had normal childhood diseases. He suffered from arthritis and the pain started in the right hip joint five months ago. Patient visited the doctor who diagnosed him with osteoarthritis, but patient did not receive any specific therapy or rehabilitation by a specialist. Patient firstly had an operation of total endoprothesis of hip in his left side in 2011 and was treated with physical therapy. On the 27th of January, 2014 patient had an operation for total hip endoprothesis for his right hip.

Social anamnesis: He has one child. He lives alone in a house which includes 3 stairs with an elevator.

Occupational anamnesis: He works as a sport organizer of a tennis club in Prague. He spends most of his time at work in a sited position.

Operation anamnesis: Total endoprothesis of left hip in 2011.Total hip endoprothesis operation once more but of the right hip in 2014.

Pharmacological anamnesis: He was receiving medication for prevention of DVT via injection two days after the surgery. Now he is receiving painkillers once a day at night.

Hobbies: He was playing tennis semiprofessionally for a lot of years daily and he also likes to listen to music.

Allergies: None

Previous injuries and trauma: None

Abuses: He drinks a glass of red wine occasionally. Patient does not smoke.

3.2.1 **Previous rehabilitation:**

He undergone rehabilitation sessions after the first operation that he had three years ago on his left hip (total endoprothesis), in order to relieve pain, regain ROM in the operated side and be able to return to his ADL. Pain was controlled and therapies were effective. He was treated with manual techniques, electrotherapy, mechanotherapy (US) and ice-therapy as he mentioned.

3.2.2 **Statement from the patient's medical documentation:**

MRI statement of the patient showed that he suffered from osteoarthritis on the right hip joint. Patient after that had an operation of total endoprothesis on right hip joint which was successful and during the operation time there were not any complications.

3.2.3 **Indication of rehabilitation:**

Doctor suggested a physiotherapeutic program which includes first of all verticalization of the patient and instructions about the contraindicated movements and how to get in and out of the bed. In addition, he gave advices to improve and regain the proper walking stereotype by educating the patient on how to walk with crutches and how to load each leg at that time being. Furthermore he suggested some exercises in order to avoid deep vein thrombosis. Isometric exercises for muscles whose strength was decreased. Also active and passive exercises for the right hip and knee joint were introduced, soft tissue techniques for skin and fascia on the thigh and scar, on top of that.

3.2.4 **Differential diagnosis:**

- Presence of pain in the right hip joint after operation of total endoprothesis of hip.
- The right lower extremity may be swollen after such an operation and stitches holding the scar.
- ROM in right hip joint in the directions of F, E and ABD will be restricted. Rotations will be restricted also but are contraindicated movements after total endoprothesis of hip joint.
- Proper gait pattern is affected after the operation.
- Expecting hypertonicity or hypotonicity in muscles around hip joint region and especially in the operated lower extremity (right).
- Weakened muscles after the operation, mostly on the right operated side. (gluteus maximus, gluteus medius, quadriceps, tensor fascia late) .
- Soft tissue may be affected due to operation on the right operated side (skin, sub skin, fascia) including the area of the scar. Also soft tissue can be affected on the non-operated leg because of an asymmetrical loading.
- Possible restricted joint play on both lower extremities. On the operated leg due to the long immobilization and on the non-operated left leg there may be restriction of joint play due to overusing and overloading, as well.
- The sensation of the right leg can be altered also as a consequence of the surgery.

Subjective feeling of the patient:

Patient feels pain on the right operated extremity. Also feels the scar being stretched during the movements. ROM is affected on right hip and slight on right knee joint.

But generally patient is in a good mood, in a good state of mind and very optimistic about his rehabilitation. Due to the fact that the patient had already passed through this

operation before, he is able to control the situation as much as possible and have a positive attitude which will help him a lot to deal with it.

Present state: Patient lies on the bed after the operation of total endoprothesis on his right hip joint. The operation occurred on 27/1/2014, so patient is on the seventh day after surgery. Pain on his right leg started five months ago due to arthritis, as it was diagnosed. Now seven days after surgery patient feels the pain in his right operated leg and the pain is categorized according to Visual Analog Scale (VAS), as 8 out of 10 but he is in a good state. He also feels pain around the scar as he mentioned. Scar is still covered with stiches. Also slight swelling of the whole operated right leg is present. Patient uses the crutches and does not have any problem with it.

- Pain level: 8 out of 10 (ten is considered to be maximum)
- Heart rate: 60 beat/ min
- Blood Pressure: 120/75 mmHg
- Temperature: 36.8 ˚C

3.3 **Initial kinesiologic examination:**

I. Observation of the scar

II. Postural examination

III. Examination of pelvis

IV. Gait examination

V. Evaluation of Basic Movement Pattern

VI. Anthropometric measurements

VII. ROM examination, by Kendall

VIII. Muscle strength test, by Kendall

IX. Muscle tone examination (palpation), by Lewit

X. Soft tissue examination, by Lewit

XI. Joint play examination, by Lewit

XII. Neurological examination

3.3.1 **Observation of the scar:**

Hip region-Lateral side of right thigh.

- No inflammation
- No secretion
- Slight swelling
- Normal colour
- Scar is 15cm long
- Scar is covered with stitches

3.3.2 **Postural examination:**

Posterior view:

- Left ankle externally rotated.
- Calf looks symmetrical.
- Valgosity in both knees.
- Whole trunk tilted to the left.
- Totally flat lumbar and thoracic spine.
- Right shoulder is higher.

- Head tilted to the right.

Side view: (both sides)

- Slight flexion of right knee.
- Slight anterior tilt of pelvis
- Flat lower thoracic spine.
- Flat lumbar spine.
- Whole trunk leans forward.
- Head forward.

Anterior view:

- Patient leans more the left leg**.**
- Left leg external rotated.
- Slight flexion of right knee.
- Valgosity in the knees.
- Ribs floated out.
- Right shoulder is higher.
- Head tilt to the right.

*Patient was cooperative and he did not complaint about any pain. Also patient used crutches during this examination.

3.3.3 **Examination of pelvis:**

- Iliac crest: Right iliac crest is higher
- PSIS: Right posterior iliac spine is higher.
- ASIS: Right anterior superior iliac spine is lower.
- PIIS & ASIS in transversal plane- right and left side: Slight anterior tilt of pelvis

3.3.4 **Gait examination**:

- Patient walks with the crutches (3 point gait)
- Weight loading 80 % on left leg and 20% on operated side, as instructed
- Feels safe and balanced while using the crutches
- Tends to lean his trunk forward (antalgic position)
- Slight flexion in hip and knee joint (right)
- Patient does not feel any pain or discomfort
- Able to have good posture during walking with limited motion of right ankle in DF.
- Short steps
- Slow tempo

3.3.5 **Movement Patterns:**

- **Hip extension (prone position) :**

- First activation of hamstrings and then gluteus maximus muscle in both sides.

- **Hip abduction (side lying position) :**

- Tensor mechanism in both lower extremities.
- Activity of hip flexors
- Patient feels pain in the operated side but he was able to do it.

3.3.6 **Anthropometric Measurements**

The examinations were performed in lying position. (Supine position)

- **Lower extremities length**

	Sinister	**Dexter**
Functional length	98cm	99cm
Anatomical length	95cm	96cm
Thigh	50cm	51cm
Lower leg	45cm	45cm
Sole	25cm	25cm

Table 1-Anthropometric measurements for length of lower extremities

- **Lower extremities circumference**

	Sinister	**Dexter**
10cm above knee (vastus medialis)	39cm	42cm
15cm above knee (quadriceps)	40cm	44cm
Knee	39cm	41cm
Lower leg	35cm	38cm

Table 2- Anthropometric measurements for circumference of lower extremities

3.3.7 R.O.M. Examination, by Kendall

- Evaluation by SFTR method.
- The examinations were performed in lying position

HIP JOINT				
Plane	**Sinister**		**Dexter**	
	Active Movement	**Passive Movement**	**Active Movement**	**Passive Movement**
S	10 -0- 105	15 -0- 110	10 -0- 55	10 -0- 60
*S	10 -0- 120	20 -0- 125	10 -0- 60	15 -0- 65
F	40 -0- 5	45 -0- 10	25 -0- 0	30-0-0

*With flexed knee

Table 3- Range of motion examination (hip joint), by Kendall

KNEE JOINT				
Plane	**Sinister**		**Dexter**	
	Active Movement	**Passive Movement**	**Active Movement**	**Passive Movement**
S	0 – 0 – 110	0 – 0 - 120	0 – 0 - 100	0 – 0 –110

Table 4- Range of motion examination (knee joint), by Kendall

ANKLE JOINT				
Plane	**Sinister**		**Dexter**	
	Active Movement	**Passive Movement**	**Active Movement**	**Passive Movement**
S	40 -0- 10	40 -0- 20	40 -0- 10	40 -0- 15
R_s	20 -0- 30	25 -0- 35	20 -0- 30	25 -0- 35

Table 5- Range of motion examination (ankle joint), by Kendall

3.3.8 **Muscle Strength Test, by Kendall**

Tested muscle	**Sinister**	**Dexter**
Quatriceps femoris	5	4+
Gluteus maximus	5	4+
Gluteus medius	4+	4+
Gluteus minimus	5	4+
Tensor fasciae latae	4+	4+
Tibialis anterior	5	4+

Gastrocnemius	5	5
Soleus	5	5

Table 6- Muscle strength examination, by Kendall

3.3.9 **Muscle Tone Examination, by Lewit (palpation)**

Muscle	**Sinister**	**Dexter**
Rectus Femoris	Eutone	Eutone
Vastus medialis	Hypertonic	Hypertonic
Vastus lateralis	Hypertonic	Hypertonic
Adductors (short)	Eutone	Hypotonic
Adductors (long)	Eutone	Hypotonic
Tensor Fascie Late	Eutone	Hypertonic
Iliopsoas	Hypertonic	Hypertonic
Errector spinae (thoracic part)	Eutone	Eutone
Errector spinae (lumbar part)	Eutone	Eutone
Quadratus lumborum	Eutone	Eutone
Gluteii	Eutone	Eutone
Piriformis	Eutone	Eutone
Hamstrings	Hypertonic	Hypertonic

Gastrocnemius	Eutone	Eutone
Soleus	Eutone	Eutone
Tibialis anterior	Eutone	Eutone

Table 7 - Muscle tone examination, by Lewit

3.3.10 **Soft tissue examination, by Lewit:**

- Examination of skin and sub-skin in all directions (caudal, cranial, medial and lateral) of LE: There is no restriction in any direction in both legs
- Examination of fascia by wave technique of LE (rotation direction around longitudinal axis of the leg: restricted barrier in the right thigh.

3.3.11 **Joint play examination, by Lewit:**

- Patellar in all directions (cranial, caudal, medial, lateral): not restricted/both sides
- Knee joint in latero-lateral direction (laterolateral springing): not restricted/both sides
- Tibiofibular joint in dorsal and ventral direction: restriction in dorsal direction of right side.
- Taloclurar joint in dorsal and ventral direction: not restricted/both sides
- Chopart joint in all directions (dorsal, plantar): not restricted/both sides
- Lisfranc joint in all directions (dorsal, plantar): not restricted/both sides
- Metatarsophalangeal joints, in all the directions (dorsal, plantar, and lateral side): not restricted/both sides

- Interphalangeal joints of toes, in all the directions (dorsal, plantar and lateral side): not restricted/both sides

3.3.12 **Neurological examination:**

Superficial sensation/dermatomes

	Sinister	**Dexter**
Dermatome of L1 segment	Normal sensation	Normal sensation
Dermatome of L2 segment	Normal sensation	Normal sensation
Dermatome of L3 segment	Normal sensation	Normal sensation
Dermatome of L4 segment	Normal sensation	Normal sensation
Dermatome of L5 segment	Normal sensation	Normal sensation
Dermatome of S1 segment	Normal sensation	Normal sensation
Dermatome of S2 Segment	Normal sensation	Normal sensation

Table 8- Neurological examination- dermatomes examination

Deep Tendon reflexes

Type of reflex	**Sinister**	**Dexter**
Knee jerk reflex L3-L4	3	3
Ankle reflex L5-S2	3	3

Table 9- Neurological examination- Deep tendon reflexes

*Evaluation grades, according to Vele, where 3 it is consider a normal grade

3.3.13 **Conclusion of examination:**

- Patient had an operation of total endoprothesis of the right hip due to osteoarthritis with the stitches still on.
- He uses crutches in order to walk around and feel safe.
- Patient feels pain on the right operated leg around the area of hip joint where the scar is located. Based on that there is an important decreased of the mobility and elasticity of soft tissues (fascia) on the right thigh in rotational directions. Another reason which led to reflex changes in soft tissues is due to the fact that the whole operated leg is swollen having as a result the poor elasticity and mobility of the fascia on the right thigh.
- Because he was loading more his non operated left leg, that had as a result the increased tension and hypertonicity of muscles (vastus medialis, vastus lateralis, tensor fascia late, iliopsoas and hamstrings). On the right leg were the same foundings as well since it was the operated and injured one.
- According to the foundings from the muscle strength test, a group of muscles of lower extremities are weak (quadriceps, glutei, tensor fascia late and tibiallis anterior) on the right side which is associated with the limitation of the range of motion in hip joint in the directions of F, E and ABD.
- Muscle weakness and muscular instability causing whole trunk to lean forward during standing and walking. (antalgic position)
- Lower tension and hypotonicity of muscles (adductors short and long) on the right side.
- Restriction of joint play in tibiofibular joint in dorsal direction on right leg.

3.4 Short-term and Long-term rehabilitation plan

3.4.1 Short-term rehabilitation plan

- Decrease pain and swelling.
- Avoid deep vein thrombosis.
- Improve mobilization of the scar when the stitches will be removed.
- Increase mobility of fascia of the right thigh
- Improve mobilization of restricted head of fibula in dorsal direction.(right side)
- Increase ROM in right hip joint F, E and ABD.
- Relax hypertonic muscles (vastus medialis, vastus lateralis, tensor fascia late, iliopsoas and hamstrings).
- Regain muscle strength for muscles that are weak (quadriceps, glutei, tensor fascia late, tibiallis anterior)
- Education of the patient how to walk with crutches (3 point gait)
- Instruct of the patient about the contraindicated movements (adduction of hip, hip flexion more than 90^0 and rotations of the hip).

3.4.2 Long-term rehabilitation plan

- Maintain and improve results from short rehabilitation plan.
- Correct walking pattern of patient in order to be able to walk without crutches and be independent.
- Give instructions to the patient so that to avoid sitting on low, soft surfaces as a preparation for him to return home.
- Help patient to return back to his ADL and continue doing what he used to do.

3.5 **Therapy progress**

3.5.1 Day: 4/2/2014

Goal of today's therapy unit:

- Education of patient how to get in and out of the bed. (verticalization)
- Instruct the patient to avoid contraindication movements and also instruct the patient how to turn from supine to prone position and vice versa.
- Prevent deep vein thrombosis by active movement in ankles.
- Facilitation of hypotonic muscles.
- Increase the mobility of fascia on right thigh.
- Mobilization of head of fibula in dorsal direction.
- Increase ROM in right hip joint.
- Strengthening exercises of quadriceps femoris and gluteus maximus.
- Education of patient how to walk with crutches.
- Decrease pain and oedema in operated side by applying ice pack.

Execution:

- At the beginning of the session I instructed the patient how to stand up from and return to the bed. Then I showed him the contraindicated movements that he must avoid (flexion of hip more than 90 degrees, adduction of hip and external rotation) and also how to turn from supine to prone position with the use of a special pillow in between the knees.
- Active dorsal/plantar flexion and circular movements in ankle joint to avoid deep vein thrombosis-10 repetitions/ both legs.

- Facilitation of hypotonic muscles (adductors) on the right side using my fingertips in an upward direction.
- Soft tissue techniques to improve the mobility of fascia on the right thigh where restriction occurs by aplying pressure at the end of the barrier and then waiting for the release.
- Joint play mobilization (repetitive movements) in dorsal direction of head of fibula on the right side.
- Passive movement on right hip joint in the directions of F, E and ABD-each movement 10 repetitions.
- Repetitive isometric contractions of quadriceps femoris and gluteus maximus in both sides-10 repetitions.
- Walking with the crutches for around 25 meters. I instruct the patient how to provide the 3 point gait with crutches.
- At the end of the therapy session ice pack for 15 min was applied around the operated area of right hip.

Results:

Subjective: Patient after the session felt tired but he was very happy with the progress of our therapy. He was able to follow my instructions. Pain decreased but not to a high level.

Objective: ROM from today's therapy was increased in direction of flexion, abduction and extension of hip for a few degrees. Also fascia of right thigh was moving slightly more free.

3.5.2 Day: 5/2/2014

Goal of today's therapy unit:

- Prevent deep vein thrombosis by active movement in ankles, knees and hips.
- Release tension from soft tissues in right thigh and increase elasticity and extensibility.
- Mobilization of head of fibula in dorsal direction.
- Increase ROM in right hip joint.
- Strengthening exercises for quadriceps femoris and gluteus maximus.
- Improve walking pattern.
- Attempt to climb stairs.
- Decrease pain and oedema in operated side by applying ice pack.

Execution:

- Active dorsal/plantar flexion and circular movements in ankle joint and flexion and extension of knee to avoid deep vein thrombosis-10 repetitions/both legs.
- Soft tissue techniques to improve the mobility of fascia on the right thigh where restriction occurs by apllying pressure at the end of the barrier and then waitting for the release.
- Joint play mobilization (repetitive movements) in dorsal direction of head of fibula on the right side.
- Passive movement on right hip joint in the directions of F, E and ABD-each movement 10 repetitions.

- Active movement on hip joint in directions of F, E and ABD with patient in supine and prone position till pain threshold for the right hip (both LEs).
- Active movement on knee joint in the directions of F and E with the patient sitting at the edge of the bed-10 repetitions (both LEs).
- Repetitive isometric contractions of quadriceps femoris and gluteus maximus in both sides-10 repettitions.
- Walking with the crutches for around 30 meters.
- Walking on stairs (both directions-6 stairs)
- At the end of the therapy session ice pack for 15 min was applied around the operated area of right hip.

Results:

Subjective: Patient after the session was tired but day by day the pain especially in hip joint is less. Patient is optimistic about his progress and is very pleased with our therapy session.

Objective: There is again an increase of ROM in direction of flexion, abduction and extension of hip for a few degrees. Also fascia of right thigh shows higher elasticity. Additionally we managed to unblock the right head of fibula.

3.5.3 Day: 6/2/2014

Goal of today's therapy unit:

- Avoid deep vein thrombosis by active movement in ankles, knees and hips.
- Release tension from soft tissues on right thigh and increase elasticity and extensibility, by apllying soft tissue techniques according to Lewit.
- Relaxation of hypertonic muscles by Post Isometric Relaxation, according to Lewit.

- Increase ROM in right hip.
- Strengthening of quadriceps femoris and gluteus maximus.
- Improve walking pattern.
- Climbing stairs.

Execution:

- Active dorsal/plantar flexion and circular movements in ankle joint to avoid deep vein thrombosis-10 repetitions
- Soft tissue techniques, to improve the mobility of fascia on the right thigh where restriction occurs by apllying pressure at the end of the barrier and then wait for the release.
- Post Isometric Relaxation techniques for relaxation of hypertonic quadriceps femoris, tensor fascia late, iliopsoas and hamstring on the right side and iliopsoas, quadriceps femoris on left side.
- Passive movement in right hip joint in the directions of F, E and ABD-each movement 10 repetitions.
- Active movement on hip joint in directions of F, E and ABD with patient in supine and prone position. (both LEs)
- Active movement on knee joint in the directions of F and E with the patient sitting at the edge of the bed-10 repetitions. (both LEs)
- Repetitive isometric contractions of quadriceps femoris and gluteus maximus in both sides-10 repetitions.
- Walking with the crutches for around 35 meters.
- Walking on stairs (both directions- 10 stairs)

Results:

Subjective: Patient after the session was tired but day by day the pain in hip joint is even less. Patient was in a good mood and he was following my commands.

Objective: Day by day ROM is increasing gradually and hypertonic muscles are much more relaxed. Also there is release of tension after the application of soft tissue techniques on right thigh. Finally the distance of walking with the crutches is increased 5 meters.

3.5.4 Day: 7/2/2014

Goal of today's therapy unit:

- Soft tissue technique of the scar for better elasticity of the skin around that region, by Lewit.
- Prevent deep vein thrombosis by active movement in ankles, knees and hips.
- Relaxation of hypertonic muscles by Post Isometric Relaxation techniques, by Lewit.
- Increase ROM in right hip.
- Strengthening exercises for tensor facie late, gluteus medius and minimus.
- Improve walking pattern.
- Climbing stairs

Execution:

- Soft tissue techniques by pressure and scissors technique around the scar with patient supine lying position. (first day that scar is without stiches)
- Active dorsal/plantar flexion and circular movements in ankle joint to avoid deep vein thrombosis-10 repetitions/both sides
- Post Isometric Relaxation techniques for relaxation of hypertonic quadriceps femoris, tensor fascia late, iliopsoas and hamstring on the right side and iliopsoas, quadriceps femoris on left side.
- Active movement on hip joint in directions of F, E and ABD with patient in supine and prone position. (both LEs)
- Active movement on knee joint in the directions of F and E with the patient sitting at the edge of the bed-10 repetitions.
- Repetitive isometric contractions of tensor fascie latae, gluteus minimus and medius in both sides-10 repetitions
- Walking with the crutches for about 40 meters.
- Walking on stairs (both directions-14 stairs)

Results:

Subjective: Patient feels pain but in a lower level after the therapy. He feels stronger now and he is able to complete the therapy session with no problem and without being tired as he used to be in previous sessions.

Objective: Most important is that ROM is increasing in hip joint in the direction of F, E and ABD and also there is almost no pain during active movement on right hip. Relaxation of hypertonic muscles is achieved.

3.5.5 Day: 10/2/2014

Goal of today's therapy unit:

- Soft tissue techniques for better elasticity of the skin around the scar, according to Lewit.
- Relaxation of hypertonic muscles by Post Isometric Relaxation techniques, by Lewit.
- Strengthening exercises for quadriceps femoris and tensor fascia latae.
- Strengthening exercises using the Swedish ball by flexing and extending the knee and hip joint.
- Increase ROM in right hip joint.
- Improve walking pattern.
- Climbing stairs.

Execution:

- Soft tissue method by pressure and scissors technique around the scar with patient in supine lying position.
- Post Isometric Relaxation techniques for relaxation of hypertonic quadriceps femoris, tensor fascia late, iliopsoas and hamstring on the right side and iliopsoas, quadriceps femoris on left side.
- Exercises with the Swedish ball: Patient was lying supine on the bed. Swedish ball was under the patient's heels. Then patient was trying to flex hip not more than 90 degrees and also flex knees while gliding the ball along the bed. After that patient was trying to extend hip and knees. 10 repetitions.
- Repetitive isometric contractions of quadriceps femoris and tensor fascia latae in both sides-10 repetitions.
- Walking with the crutches for around 50 meters.

- Walking on stairs (both directions-16 stairs).

Results:

Subjective: Patient does not feel pain any more during the therapy. He was walking with confidence and more safe.

Objective: Patient is able to walk with crutches with no problem and muscles that were hypertonic are almost relaxed and ROM is improving day to day on right operated hip joint in all the possible directions (F, E and ABD). Also there is increasing of muscle strength because patient is now able to finish the therapeutic exercises tireless.

3.5.6 Day: 11/2/2014

Goal of today's therapy unit:

- Soft tissue technique for better elasticity of the skin around the scar, according to Lewit.
- Relaxation of hypertonic muscles by Post Isometric Relaxation techniques, by Lewit.
- Increase ROM in right hip joint.
- Strengthening exercises using the Swedish ball by flexing and extensing of knee and hip joint.
- Improve walking pattern.
- Climbing stairs

Execution:

- Soft tissue method by applying pressure and scissors technique around the scar with patient in supine lying position.
- Post Isometric Relaxation techniques for relaxation of hypertonic quadriceps femoris, tensor fascia late, iliopsoas and hamstring on the right side and iliopsoas, quadriceps femoris on left side.
- Exercises with the Swedish ball: Patient was lying supine on the bed. Swedish ball was under the patient's heels. Then patient try to flex hip not more than 90 degrees and also flex knees. After that patient try to extend hip and knees. 10 repetitions
- Walking with the crutches for around 55 meters.
- Walking on stairs (both directions-20 stairs)

Results:

Subjective: Today was the last therapy session with the patient. Patient feels very comfortable and he was satisfied from our therapy during whole week. The pain now belongs to the past and patient is looking forward to recovering in a fully manner.

Objective: There is no higher tension in the muscles at all. ROM increased generally on hip joint in all the possible directions (F, E and ABD). Also muscles are now stronger and scar therapy was successful because patient said that after today's therapeutic unit he does not feel the scar during movement as it used to be. Additionally walking pattern is now better and more comfortable with the proper posture and rhythm. Climbing on stairs without any discomfort and also hypertonicity in muscles is absent.

3.6 Final Initial kinesiologic examination:

I. Observation of the scar

II. Postural examination

III. Examination of pelvis

IV. Gait examination

V. Evaluation of Basic Movement Pattern

VI. Anthropometric measurements

VII. ROM examination, by Kendal

VIII. Muscle strength test, by Kendal

IX. Muscle tone examination(palpation), by Lewit

X. Soft tissue examination, by Lewit

XI. Joint play examination, by Lewit

XII. Neurological examination

3.6.1 **Final Observation of the scar:**

Hip region - Lateral side of right thigh.

- No inflammation.
- No secretion.
- **No swelling.**
- Normal colour.
- Scar is 15cm long.
- **Scar is without stiches.**

3.6.2 **Final Postural examination:**

Posterior view:

- Left ankle external rotated.
- Calf looks symmetrical.
- Valgosity in the knees.
- Whole trunk tilt to the left.
- Totally flat lumbar and thoracic spine.
- **Right shoulder in the same level with the left.**
- **Head in midline.**

Side view: (both sides)

- **Slight less flexion of right knee.**
- Flat lower thoracic spine.
- Flat lumbar spine.
- **Whole trunk in vertical line without lean forward.**
- **Head in line.**

Anterior view:

- **Patient leans slight less now to the left leg.**
- Left leg external rotated.
- **Less flexion of right knee.**

- Valgosity in the knees.
- Ribs floated out.
- **Right shoulder is now in symmetry.**
- **Head in midline.**

*Patient was cooperative and he did not complaint about any pain. Also patient used again crutches during this examination.

3.6.3 **Final Examination of pelvis:**

- Iliac crest: Right iliac crest is higher
- PSIS: Right posterior iliac spine is higher.
- ASIS: Right anterior superior iliac spine is lower.
- PIIS & ASIS in transversal plane- right and left side: Slight anterior tilt of pelvis

3.6.4 **Final Gait examination**:

- Patient walking with the crutches (3 point gait).
- Loading 70% on left leg and 30% on operated side.
- Balance walking with the crutches.
- Patient does not feel any pain.
- **There is no flexion in hip and knee joint during walking at this time.**
- **Able to have better upright posture during walking.**
- **Normal length of steps**.

- **More confident walking with faster tempo**.

3.6.5 Final Movement Patterns:

- **Hip extension (prone position) :**

- Proper activation of muscles now, **firstly activation of gluteus maximus m. and then hamstrings.**

- **Hip abduction (side lying position) :**

- Tensor mechanism in both lower extremities.
- Activity of hip flexors
- **Patient feels less pain in the operated side**

3.6.6 Final Anthropometric Measurements

The examinations were performed in lying position. (Supine position)

- **Lower extremities length**

	Sinister	**Dexter**
Functional length	98cm	99cm
Anatomical length	95cm	96cm
Thigh	50cm	51cm
Lower leg	45cm	45cm
Sole	25cm	25cm

Table 10-Final Anthropometric measurements for length of lower extremities

- **Lower extremities circumference**

	Sinister	**Dexter**
10cm above knee (vastus medialis)	**37cm**	**36cm**
15cm above knee (quadriceps)	40cm	**40cm**
Knee	39cm	**38cm**
Lower leg	35cm	**35cm**

Table 11- Final Anthropometric measurements for circumference of lower extremities

3.6.7 Final R.O.M. Examination, by Kendall

- Evaluation by SFTR method.
- The examinations were performed in lying position

HIP JOINT				
Plane	**Sinister**		**Dexter**	
	Active Movement	**Passive Movement**	**Active Movement**	**Passive Movement**
S	10 -0- 105	15 -0- 110	10 -0- **80**	**15**-0- **85**
S*	10 -0- 120	20 -0- 125	10 -0- **85**	15 -0- **90**
F	40 -0- 5	45 -0- 10	**35** -0- 0	**40** - 0 -0

Table 12- Final Range of motion examination (hip joint), by Kendall

*With flexed knee

KNEE JOINT

Plane	Sinister		Dexter	
	Active Movement	**Passive Movement**	**Active Movement**	**Passive Movement**
S	0 – 0 - 110	0 – 0 - 120	0 – 0 - **110**	0 – 0 –**120**

Table 13- Final Range of motion examination (knee joint), by Kendall

ANKLE JOINT				
Plane	**Sinister**		**Dexter**	
	Active Movement	**Passive Movement**	**Active Movement**	**Passive Movement**
S	40 -0- 10	40 -0- 20	40 -0- 10	40 -0- **20**
R_s	20 -0- 30	25 -0- 35	20 -0- 30	25 -0- 35

Table 14- Final Range of motion examination (ankle joint), by Kendall

3.6.8 Final Muscle Strength Test, by Kendall

Tested muscle	Sinister	Dexter
Quatriceps femoris	5	**5**
Gluteus maximus	5	**5**
Gluteus medius	4+	**5**
Gluteus minimus	5	**5**
Tensor fasciae latae	4+	**5**
Tibialis anterior	5	4+

Gastrocnemius	5	5
Soleus	5	5

Table 15- Final Muscle strength examination, by Kendall

3.6.9 Final Muscle Tone Examination, by Lewit (palpation)

Muscle	**Sinister**	**Dexter**
Rectus Femoris	Eutone	Eutone
Vastus medialis	**Eutone**	**Eutone**
Vastus lateralis	**Eutone**	**Eutone**
Adductors (short)	Eutone	**Eutone**
Adductors (long)	Eutone	**Eutone**
Tensor Fascie Late	Eutone	**Eutone**
Iliopsoas	**Less tension**	**Less tension**
Errector spinae (thoracic part)	Eutone	Eutone
Errector spinae (lumbar part)	Eutone	Eutone
Quadratus lumborum	Eutone	Eutone
Gluteii	Eutone	Eutone
Piriformis	Eutone	Eutone
Hamstrings	**Less tension**	**Less tension**

Gastrocnemius	Eutone	Eutone
Soleus	Eutone	Eutone
Tibialis anterior	Eutone	Eutone

Table 16 - Final Muscle tone examination, by Lewit

3.6.9 **Final Soft tissue examination, by Lewit:**

- Examination of skin and sub-skin in all directions (caudal, cranial, medial and lateral) of LE: There is no restriction in any direction in both legs
- Examination of fascia by wave technique of LE (rotation direction around longitudinal axis of the leg: **There is better (normal) elasticity of fascia on right thigh now.**

3.6.10 **Final Joint play examination, by Lewit:**

- Patellar in all directions (cranial, caudal, medial, lateral): not restricted/both sides
- Knee joint in latero-lateral direction (laterolateral springing): not restricted/both sides
- Tibiofibular joint on dorsal and ventral direction**: Achieved unblocked in dorsal direction of right side.**
- Taloclurar joint in dorsal and ventral direction: not restricted/both sides
- Chopart joint in all directions (dorsal, plantar): not restricted/both sides
- Lisfranc joint in all directions (dorsal, plantar): not restricted/both sides
- Metatarsophalangeal joints, in all the directions (dorsal, plantar, and lateral side): not restricted/both sides

- Interphalangeal joints of toes, in all the directions (dorsal, plantar and lateral side): not restricted/both sides

3.6.11 **Final Neurological examination:**

Superficial sensation/dermatomes

	Sinister	**Dexter**
Dermatome of L1 segment	Normal sensation	Normal sensation
Dermatome of L2 segment	Normal sensation	Normal sensation
Dermatome of L3 segment	Normal sensation	Normal sensation
Dermatome of L4 segment	Normal sensation	Normal sensation
Dermatome of L5 segment	Normal sensation	Normal sensation
Dermatome of S1 segment	Normal sensation	Normal sensation
Dermatome of S2 Segment	Normal sensation	Normal sensation

Table 17- Final Neurological examination- dermatomes examination

Deep Tendon reflexes

Type of reflex	**Sinister**	**Dexter**
Knee jerk reflex L3-L4	3	3
Ankle reflex L5-S2	3	3

Table 18- Final Neurological examination- Deep tendon reflexes

*Evaluation grades, according to Vele

3 it is a normal grade

3.7 Evaluation of effect of the therapy

Patient was after total endoprothesis of right hip joint. The surgery took place on the 27th of January, 2014. Seven days after operation I had my first contact with the patient and immediately started our cooperation. During the first session I took the initial kinesiologic examination and right after I continued to the therapy progress.

From the beginning right after the first examination we set some tasks always according to the individuality of the case and also according to the progress of the patient. The therapeutic sessions that I had with my patient it was very effective in compare of the initial and final kinesiologic examination findings. Patient's condition was improving day by day. Level of pain was decreased in a high level. (From 8 at the beginning to 2 out of 10 at the end according to Visual Analog Scale)

We achieved to prevent deep vein thrombosis and also through the therapeutic procedures that I had chosen, there was an increase in ROM of hip joint in the directions of F, E and ABD. From the foundings of the initial kinesilogic examination F was 55-60°, E was 10° and ABD 25-30°. Then according to the final kinesiologic examination F was 85-90°, E 15° and ABD 35-40°.

Also high tension in muscles was decreased thanks to PIR techniques. Facilitation of hypotonic muscles was effective because now they have normal tone.

Additionally focus as well on the release and increase of the mobility of the fascia the elasticity and the mobility improved importantly. After the removing of the stiches, with the application of soft tissue techniques scar is smoother and the patient does not feel it at all during movement.

Regain the strength of the muscles that were weak achieved by the strengthening exercises and now they are in a good condition of strength able enough to improve muscle stability around the right hip. According the results of the initial examination of muscle strength test quadriceps, gluteus maximus,medius and minimus, tensor fascia latae of right operated side was evaluated with grade 4+. Then to the final muscle strength test evaluation these muscles that I referred above was in normal grade 5.

The increasing of muscular strength help a lot the patient to be able to walk with crutches with better posture and more fluent walking with higher rhythm.

Finally patient was very cooperative with me and we enjoyed the time we have been together. Also patient was satisfied from my therapeutic units and he felt much better.

3.8 **Prognosis**

My personal opinion is that the patient have done great progress from the first day that I met him until our last session. If the patient follows step by step the instructions that I and my supervisor gave to him and continues with the same passion and awareness his therapeutic sessions in a matter of time he will be able to return in his normal activities of daily living.

4.

CONCLUSION

4. **Conclusion**

My clinical work placement took place in UVN for two weeks' time. During this period I had to work with a patient who underdone a surgery of total hip endoprothesis. I retrieved all my knowledge that I gained through the years while studying and applied them for the best of my patient.

I had a very pleasant cooperation with my patient and the task that I was given to deal with, it was completed with success. Based on the instructions and guidance of my supervisor Mgr. Agnieszka Dudova Ph.D and instructor Dis. Petr Smejkal at the clinic I managed to complete the protocol and the whole bachelor thesis encouraging me to continue and carry on having on mind how to treat in the best way my patient. My goals have been accomplished while seeing the patient's attitude and smile and I wish to continue in the future as a professional in the orthopaedic area of physiotherapy. This field has turned out to be challenging and interesting bringing new things in, changing my way of thinking and giving me the motivation to learn even more about it and struggle for the best.

Many special thanks to my supervisor Mgr. Agnieszka Dudova Ph.D for her precious help and professional approach. Her guidelines and suggestions have shown me the direction that I should follow and accomplish the goal that I set.

5.

BIBLIOGRAPHY

5. **Bibliography:**

BOOKS:

1. Canale, T., & Beaty, J. (2012). Cambell's Operative Orthopedics. (12thed.). Philadelphia: Elsevier Inc
2. Clemente, D. (2006). A Regional Atlas of the Human Body. (6th ed.). Germany: Lippincott Williams & Wilkins
3. Cvjeticanin, V., Cooke, C., & Barrow, S. (2009). Guideline for the non-surgical management of hip and knee osteoarthritis, (1st ed.). Melbourne: The Royal Australian College of General Practitioners
4. Dewing, K., Setter, S., & Slusher, B. (2012). Osteoarthritis and Rheumatoid Arthritis: Pathophysiology, Diagnosis and Treatment. (1st ed.). Houston: Practitioner Health Care Foundation Ltd
5. Drake, L., & Vogl, A. (2009). Gray's Anatomy for Students. (2nd ed.). United Kingdom: Churchill Livingstone Elsevier
6. Henrotin, Y., Bennell, K., & Rannou, F. (2012). Nonpharmacological Therapies in the Management of Osteoarthritis, (1st ed.). Belgium: Bentham Science
7. Kendall, F., Kendall, E., & et al. (2005). Muscles Testing and Function with Posture and Pain. (5th ed.). Baltimore: Lippincott Williamns & Wilkins
8. Lewit, K., & Richard, M. (2009). Manipulative Therapy: Musculoskeletal Medicine, (1st ed.). Baltimore: Elsevier Limited
9. Marks, J. (2009). Arthritis Meeting the Challenge. (1st ed.). Atlanta: Cdc Inc
10. Martini, F., & Nath, J. (2012). Fundamentals of Anatomy & Physiology. (9th ed.). United States of America: Pearson Education
11. Mont, M., & Tankersley, W. (1997). Rehabilitation Secrets. (1st ed.). Philadelphia: Hanley and Belfus
12. Moore, L., & Dalley, A. (1999). Clinically Oriented Anatomy. (4th ed.). Philadelphia: Lippincott Williams & Wilkins
13. Moore, L., & Dalley, A. (2010). Clinically Oriented Anatomy. (6th ed.). United States of America: Lippincott Williams & Wilkins

14. Moskowitz, R., Altman, R., & Buckwalter, J. (2006). Osteoarthritis: Diagnosis and Medical/Surgical Management, (4th ed.). Philadelphia: Lippincott Williams & Wilkins
15. Paulsen, F., & Waschkc, J. (2010). Sobbota Atlas of Human Anatomy. (15th ed.). Munchen: Elsevier Urban & Fischer
16. Rogers, S. (1982). Atlas of human Anatomy for the Artist. (2nd ed.). United States of America: Oxford University Press
17. Skinner, H., & Fitzpatrick, M. (2008). Current Essentials Orthopedics, (1st ed.). New York: The McGraw-Hill Companies, Inc
18. Standring, S. (2008). Gray's Anatomy the Anatomical Basis of Clinical Picture. (39th ed.). London: Churchill Livingstone Elsevier

ELECTRONIC ARTICLES:

19. Braun, H., & Gold, G. (2011). Diagnosis of osteoarthritis: Imaging. Bone, 3, 1-11. doi: 10.1016/j.bone.2011.11.019

20. Byrne, D., Mulhall, K., & Baker, J. (2010). Anatomy & Biomechanics of the Hip. The Open Sports Medicine Journal, 4, 51-57. doi: 1874-3870/10

21. Cibulka, M., White, D., & Woehrle, J. (2009). Hip Pain and Mobility Deficits – Hip Osteoarthritis. Journal of Orthopaedic & Sports Physical Therapy, 39, 1-47. doi: 10.2519/jospt.2009.0301

22. Crowford, R., & Murray, D. (1997). Total Hip Replacement: Indications for Surgery and Risk Factors for Failure. Annals of the Rheumatic Diseases, 56, 455-457. doi: 10.1136/ard.56.8.455

23. Dagenais, S., Garbedian, S., & Wai, E. (2009). Systematic Review of the Prevalence of Radiographic Primary Hip Osteoarthritis. The Association of Bone and Joint Surgeons, 467, 623-637. doi: 10.1007/s11999-008-0625-5

24. Dieppe, P. (1995). Management of Hip Osteoarthritis. Education & Dabate, 311, 853-857. doi: 10.1136/bmj.311.7009.853

25. McAlindon, T., & Dieppe, P. (2014). Osteoarthritis: Definitions and Criteria. Annals of the Rheumatic Diseases, 48, 531-532. doi: 10.1136/ard.48.7.531

26. Neumann, D. (2010). Kinesiology of the Hip: A Focus on Muscular Actions. Journal of Orthopaedic & Sports Physical Therapy, 40(2), 82-94. doi: 10.2519/jospt.2010.3025

27. Pivec, R., Johnson, A., & Harwin, S. (2013). Differentiation, Diagnosis, and Treatment of Osteoarthritis, Osteonecrosis, and Rapidly Progressive Osteoarthritis. Rubin Institute for Advanced Orthopedics, 36(2), 118-125. doi: 10.3928/01477447-20130122-04

28. Sariali, E., Veysi, V., & Stewart, T. (2008 Biomechanics of the Human Hip-Consequences for Total Hip Replacement. Current Orthopaedics, 22, 371-375. doi: 10.1016/j.cuor.2008.10.005

29. Stewart, T., & Halla, R. (2006). Basic biomechanics of human joints: Hips, Knees and the Spine. Current Orthopaedics, 20, 23-31. doi: 10.1016/j.cuor.2005.12.004

ELECTRONIC WEBSITES:

30. Beagan, C. (2011, March 5). Total Hip Arthroplasty/ Hemiarthroplasty Protocol. Retrieved April 17, 2014, from www.brighamandwomens.org

31. Ellis, J., & Petrik, M. (2011, April 5). Total hip arthroplasty. Retrieved April 17, 2014, from www.mattpricemd.com
32. Mahajan, A., Verma, S., & Tandon, V. (2005, July 5). Osteoarthritis. 53, 634-641. Retrieved February 12, 2014, from www.japi.org
33. Wolgin, M. (2012, April 10). Osteoarthritis. Retrieved February 10, 2014, from http://www.drwolgin.com/Pages/Osteoarthritis.aspx

LECTURES:

34. Čemusová, J. 2011. *Introduction to rehabilitation: Physiotherapist and patient`s past history.* Lecture`s notes. Charles University in Prague.
35. Jalovcová, M. 2011. *Examination and basic therapeutic methods I: Anthropometric measurements.* Lecture`s notes. Charles University in Prague.

36. Jalovcová, M. 2011. *Examination and basic therapeutic methods I: Postural examination and muscle balance.* Lecture`s notes. Charles University in Prague.

37. Jalovcová, M. 2011. *Examination and basic therapeutic methods I: Spine. Lecture`s notes.* Charles University in Prague.

38. Jelinkova, I. 2011. *Examination and basic therapeutic methods II: Gait examination.* Lecture`s notes. Charles University in Prague.

39. Panek, D. 2012. *Clinical kinesiology: Introduction.* Lecture`s notes. Charles University in Prague.

40. Panek, D. 2012. *Clinical kinesiology: The pelvis gridle*. Lecture`s notes. Charles University in Prague.

41. Panek, D. 2012. *Examination and basic therapeutic methods III: Neurological examination.* Lecture`s notes. Charles University in Prague.

42. Pavlů, D. 2012. *Examination and basic therapeutic methods III: Evaluation of basic movements patterns.* Lecture`s notes. Charles University in Prague

43. Satrapova, L. 2012. Examination and basic therapeutic methods III: Changes of muscle tone and musculoskeletal dysfunction. Lecture`s notes. Charles University in Prague.

6.

SUPPLEMENTS

6.1 **List of pictures**

6.2 **List of tables**

6.3 **Abbreviations**

ABD - Abduction

ADL – Activities of Daily Living

E - Extension

ER - External Rotation

F - Flexion

LE - Lower Extremities

OA – Osteoarthritis

PIR - Post Isometric Relaxation

ROM - Range Of Motion

DVT – Deep vein thrombosis

US – Ultrasound

VAS – Visual Analog Scale

C – Celsius

PSIS – Posterior Superior Iliac Spine

ASIS – Anterior Superior Iliac Spine

PIIS – Posterior Inferior Iliac Spine

SFTR – Sagittal-Frontal-Transversal-Rotational

6.4 **Application for Ethics Board Review**

CHARLES UNIVERSITY IN PRAGUE
FACULTY OF PHYSICAL EDUCATION AND SPORT
José Martího 31, 162 52 Praha 6-Veleslavín
tel. +420 2 2017 1111
http://www.ftvs.cuni.cz/

Application for Ethics Board Review

of the undergraduate research, involving human subjects

Project title: Case study of a patient with the diagnosis of total endoprothesis of hip caused by arthritis.

Nature of the research project: Bachelor thesis
* Please delete as appropriate.

Author (chief investigator): Tryfonas Pyrillos
Co-investigators:
Supervisor (in case of student research): Mgr. Agnieszka Dudova Ph.D

Research project description also involves the case study of the patient who had an operation of total endoprothesis on the right hip joint, caused by arthritis. My practice was performed at Ústřední Vojenská Nemocnice. The patient was operated at 27th of January, and he was transferred to orthopedic department. Since the patient transferred to orthopedic department, was following a special physiotherapeutic treatment. Goals of the therapy was to decrease pain, increase range of motion of the movement, increase mobility and elasticity of skin and also improve strength of the muscles that are affected and relax them also from hyper tonicity according to the examinations I provided to the practical part . Physiotherapy program started on Monday 3rd of February 2014 and ended on Friday 14th of February 2014.
Guaranteed safety to be judged by experts: no invasive methods were used
Ethical aspects of the research: personal data obtained during the case study will not be published.
Informed consent (attached)

Date: Author's signature:

Faculty of Physical Education and Sport, Charles University in Prague
ETHICS BOARD REVIEW

Ethics Board members: Doc. MUDr. Staša Bartůňková, CSc.
Prof. Ing. Václav Bunc, CSc.
Prof. PhDr. Pavel Slepička, DrSc.
Doc. MUDr. Jan Heller, CSc.

The Ethics Board at the Faculty of Physical Education and Sport, Charles University, approved the research project.
Approval number: 103/2014
Date: 3.5.2014

The Ethics Board at the Faculty of Physical Education and Sport, Charles University, reviewed the submitted research project and **found no contradictions with valid principles**, regulations and international guidelines for biomedical research involving human subjects.

The chief investigator of the project met the necessary requirements for receiving the Ethics Board approval.

UNIVERZITA KARLOVA v Praze
Fakulta tělesné výchovy a sportu
José Martího 31, 162 52, Praha 6
1

Official school stamp

Signature, REB Chairman

INFORMOVANÝ SOUHLAS

V souladu se Zákonem o péči o zdraví lidu (§ 23 odst. 2 zákona č.20/1966 Sb.) a Úmluvou o lidských právech a biomedicíně č. 96/2001, Vás žádám o souhlas k vyšetření a následné terapii. Dále Vás žádám o souhlas k nahlížení do Vaší dokumentace osobou získávající způsobilost k výkonu zdravotnického povolání v rámci praktické výuky a s uveřejněním výsledků terapie v rámci bakalářské práce na FTVS UK. Osobní data v této studii nebudou uvedena. Dnešního dne jsem byla odborným pracovníkem poučena o plánovaném vyšetření a následné terapii. Prohlašuji a svým dále uvedeným vlastnoručním podpisem potvrzuji, že odborný pracovník, který mi poskytl poučení, mi osobně vysvětlil vše, co je obsahem tohoto písemného informovaného souhlasu, a měla jsem možnost klást mu otázky, na které mi řádně odpověděl. Prohlašuji, že jsem shora uvedenému poučení plně porozuměla a výslovně souhlasím s provedením vyšetření a následnou terapií. Souhlasím s nahlížením níže jmenované osoby do mé dokumentace a s uveřejněním výsledků terapie v rámci studie.

Datum:……

Osoba, která provedla poučení:……

Podpis osoby, která provedla poučení:……

Vlastnoruční podpis pacienta /tky:…….