Charles University in Prague

Faculty of Physical Education and Sports

Case Study of the Physiotherapeutic Treatment on a Patient Post-Microdiscectomy on L5/S1

Bachelor's Thesis

September 2013, Prague

Author: Trisita Sanguanbun

Advisor: Mgr. Pavla Kratochvilova

Supervisor: PhDr. Tereza Novakova

Abstract

Title: Case Study of the Physiotherapeutic Treatment on a patient Post-Microdiscectomy on L5/S1

Thesis Aim: This thesis follows the physiotherapeutic treatment for a patient post-microdiscectomy on the level of L5/S1. The first part, general part, explains the anatomy of the whole spine. Additionally, it provides information on lumbar disc herniation, the conservative treatment for lumbar disc herniation, and the surgical procedure for microdiscectomy. The second part, special part, includes the anamnesis, the initial kinesiological examination and the therapies done in detail. The conclusion and the effects of therapy are also included in this part.

Methods: The special part follows a 41-year-old female patient, 3 months post-microdiscectomy, who feels pain around the operated area, which also sometimes radiates down to both of her heels. The physiotherapeutic treatments used on the patient include soft tissue techniques, post-isometric relaxation, joint mobilization, dynamic neuromuscular stabilization and senso-motoric stimulation. These methods were non-invasive. There were 6 therapy sessions, which lasted for 45 minutes each.

Results: After 6 therapy sessions, the patient shows very slight improvement in all aspects. Since the therapy sessions were spread over only 7 days, there was no noticeable improvement.

Conclusion: Following the results, the prognosis of this patient would be good over more time. The therapeutic methods used were effective for that very short amount of time that the patient was being treated.

Keywords: microdiscectomy, physiotherapy, disc herniation, lumbar spine

Declaration

I declare that this thesis is my own work with some guidance from my supervisors, PhDr. Tereza Novakova and Mgr. Pavla Kratochvilova. The information gained in this thesis is from the lectures from the university, as well as different resources and books relating to the topic of this thesis.

Trisita Sanguanbun
Prague, September 2013

Acknowledgements

First of all, I would like to thank my best support and motivation; my parents and brothers, for always pushing and helping me get up when I'm at my lowest, especially having to live alone in a foreign country for the past 5 years. Without you guys, I wouldn't have gone through so many struggles and made me become the person I am today. Also, thanks to all my relatives back home for believing in me.

Secondly, I'd like to thank my friends in Prague who've been like my home away from home. Lousin, Carine, Farah and Umit; thank you for being patient with me throughout this very unique university experience. Without you guys, I would've given up a long time ago. I'll cherish our friendship forever. Special thanks to my best friends, Sara, Michelle and Ha Kyung, for also supporting me and giving me personal advice, although we're miles and miles apart. Not to mention, KSH, thanks for giving me full support in everything I've done in the past couple of years.

Last but not least, I'd like to thank all the professors at FTVS that have taught and given me so much knowledge throughout the bachelor's program. I'd also like to thank PhDr. Tereza Novakova for guiding me through this thesis and Mgr. Pavla Kratochvilova for guiding and teaching me so much during my practice for this thesis.

Thank you all.

Trisita Sanguanbun
Prague, September 2013

Table of Contents

General Part **9**

1.1 Disc Herniation – An Introduction **9**

1.2 Anatomy of the Spine **9**

1.2.1 Curvatures of the spine 11

1.2.2 Intervertebral disc 11

1.2.3 The structure of the vertebrae (Tortora & Derrickson, 2009) 12

1.2.4 Function 13

1.2.5 Kinesiology (Lippert, 2006) 13

1.3 Lumbar and Sacral spine **14**

1.3.1 Lumbar region (Tortora & Derrickson, 2009) 14

1.3.2 Sacrum (Tortora & Derrickson, 2009) 15

1.3.3 Muscles of the lumbar spine (Bogduk, 2005) 15

1.3.4 Ligaments of the lumbar spine (Bogduk, 2005) 17

1.3.5 Lumbar spinal nerve (Bogduk, 2005) 19

1.3.6 Bulging of disc (Postacchini, 1999) 21

1.4 Disc Herniation **21**

1.4.1 Classification of disc herniations (Wiesel, 2011) 21

1.4.2 Pathogenesis (Wiesel, 2011) 21

1.4.3 Indications for surgery 23

1.4.4 Contraindications (Haher & Merola, 2003) 23

1.4.5 History and physical findings (Wiesel, 2011) 25

1.4.6 Imaging and other diagnostic studies (Wiesel, 2011) 25

1.4.7 Differential diagnosis (Wiesel, 2011) 25

1.4.8 Conservative and non-invasive management (Wiesel, 2011) 26

1.4.9 Surgical management (Wiesel, 2011) 26

1.4.10 Advantages of microdiscectomy (Haher & Merola, 2003) 26

1.4.11 Surgical procedure (Hanscom, 2012) 27

1.4.12 Post-operative care (Wiesel, 2011) 28

1.4.13 Rehabilitation (McFarland, 2007) 28

1.4.14 DNS – Rehabilitation (Kolar, 2012) 30

1.4.15 Prognosis (Wiesel, 2011) 31

1.4.16 Complications (Wiesel, 2011) 31

2 Special Part – Case study 32
2.1 Methodology 32
2.2 Differential consideration 34
2.3 Anamnesis 35
2.4 Initial Kinesiological Examination 37
2.5 Conclusion of examination 46
2.6 Further examination proposal 47
2.7 Main goals of the therapy 48
2.8 Short-term and long-term rehabilitation plan 48
2.9 Therapy proposal 49
2.10 Therapy progress 50
2.10.1 Date: 1st February 2012 (afternoon) 50
2.10.2 Date: 2nd February 2012 (morning) 51
2.10.3 Date: 3rd February 2012 (morning) 52
2.10.4 Date: 6th February 2012 (morning) 54
2.10.5 Date: 7th February 2012 (morning) 55
2.10.6 Date: 7th February 2012 (afternoon) 57
2.11 Final kinesiologic examination 58
2.12 Final Kinesiological Examination Conclusion 67
2.13 Effect of therapy 68
3 Conclusion 69
4 Bibliography (List of literature) 71
5 Supplement (Annexes) 73

List of Figures

Figure 1 - Herniated Disc (Jean-Jacques Abitbol, Edgar G. Dawson, & Regis W. Haid Jr., 2013) 9
Figure 2 - The Vertebral Column from the Anterior, Posterior and Left Lateral View (Netter, 2006) 10
Figure 3 - Curvatures of the Spine (Zieve & Ma, 2009) 11
Figure 4 - Intervertebral Disc (Jean-Jacques Abitbol, Edgar G. Dawson, & Regis W. Haid Jr., 2013) 11
Figure 5 - General Structures of the Vertebrae (Cherms, 2012) 12
Figure 6 - Anatomy of the Lumbar Spine (Netter, 2006) 14
Figure 7 - Ligaments of the Lumbar Spine (Reid, 2012) 18
Figure 8 - Localizing Neurologic Levels for the Lumbar Segment (Gregory, Seto, Wortley, & Shugart, 2008) 19
Figure 9 - Dermatomes of all Spinal Levels (Netter, 2006) 20
Figure 11 - Algorithm for Treatment of Acute Lumbar Disc Herniation (Gregory, Seto, Wortley, & Shugart, 2008) (Jean-Jacques Abitbol, Edgar G. Dawson, & Regis W. Haid Jr., 2013) 24
Figure 12 - Removing the lamina (laminotomy) and the excess of the disc (microdiscectomy) (Unknown, Herniated Disc - Lumbar, 2013) 27

List of Tables

Table 1 - Myotomes of the Lower Extremity (Unknown, 2010) 20
Table 2 - Clinical Features of Lumbar Herniation (Netter, 2006) 22
Table 3 - Anthropometry of the Lower Extremities (Length in cm) 41
Table 4 - Anthropometry of the Lower Extremities (Circumference in cm) 41
Table 5 - Range of Motion in Hip Joint (°) 42
Table 6 - Range of Motion in Knee Joint (°) 42
Table 7 - Palpated Muscles 42
Table 8 - Muscle Length Test of the Lower Extremity 43
Table 9 - Muscle Strength Test 44

Table 10 - Joint Play of Lower the Extremities.....44
Table 11 - Anthropometry of the Lower Extremities (Length in cm).....63
Table 12 - Anthropometry of Lower Extremities (Circumference in cm) 63
Table 13 - Range of Motion of Hip Joint (°).....63
Table 14 - Range of Motion of Knee Joint (°) 64
Table 15 - Muscle Palpated 64
Table 16 - Muscle Length Test of the Lower Extremity 65
Table 17 - Muscle Strength Test 65
Table 18 - Joint Play of the Lower Extremities.....66

List of Abbreviations

cm – Centimetres

CT – Computer-tomography

DNS – Dynamic neuromuscular stabilization

FNKV – Fakultní nemocnice Královské Vinohrady

HNP – Herniated nucleus pulposus

IP – Interphalangeal (joint)

ISS – Integrated Stability System

ISSS – Integrated Stability System of the Spine

L – Lumbar

MRI – Magnetic resonance imaging

MTP – Metatarsophalangeal (joint)

PIR – Post-isometric relaxation

PNF – Proprioceptive neuromuscular facilitation

ROM – Range of motion

SIAS – Spina iliaca anterior superior

SIPS – Spina iliaca posterior superior

SMS – Senso-motoric stabilization

VAS – Visual Analogue Scale

General Part

1.1 Disc Herniation – An Introduction

Herniated discs occur when there is a weakness or degeneration of the annulus fibrosus (the outer layer of the intervertebral disc). This allows the portion of the nucleus pulposus to bulge, or herniate through the annulus fibrosus (fig 1). It becomes symptomatic when the herniation puts pressure on the spinal cord, or more commonly, the nerve root. L4 and L5 are the most common sites for disc lesion, and L4 and L5 lumbar nerve roots are the most commonly affected nerve roots. (Lippert, 2006)

Clinically significant lumbar disc herniations are characterized by a focal distortion of the normal anatomic configuration of discal material resulting in compression and subsequent dysfunction of the lumbar nerve root. (Wiesel, 2011)

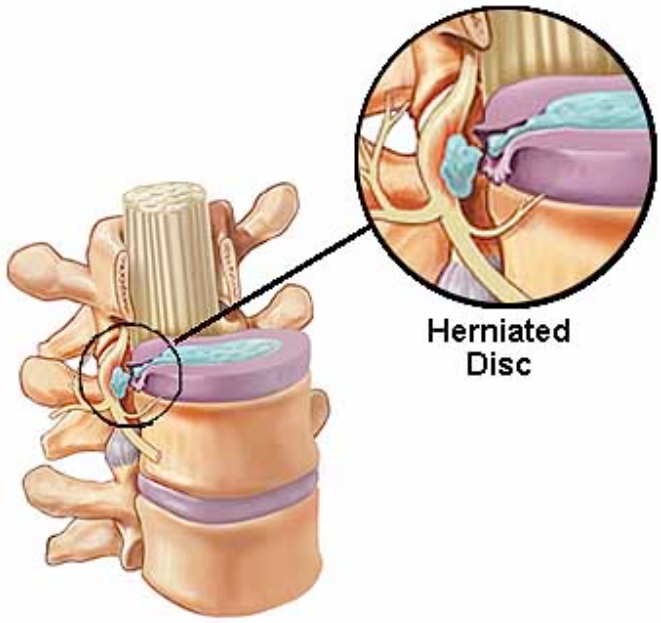

Figure 1 - Herniated Disc (Jean-Jacques Abitbol, Edgar G. Dawson, & Regis W. Haid Jr., 2013)

The anatomy and kinesiology perspective will be discussed as well as the surgical and conservative approaches for disc herniation.

1.2 Anatomy of the Spine

The vertebral column, also called the spine, backbone, or spinal column, makes up about two-fifths of a person's total height and is composed of vertebrae, a series of bones. The vertebral column consists of bone and connective tissue; the spinal cord that is surrounds and protects consists of nervous and connective tissues. (Tortora & Derrickson, 2009)

The adult vertebral column typically contains 26 vertebrae, distributed as follows:

- 7 cervical vertebrae are in the neck region
- 12 thoracic vertebrae are posterior to the thoracic cavity
- 5 lumbar vertebrae support the lower back
- 1 sacrum consists of five fused sacral vertebrae
- 1 coccyx ususally consists of four fused coccygeal vertebrae (Kendall, 2005) (Lewit, 2000)

The movable vertebrae are the cervical, thoracic, and lumbar, whereas the sacrum and coccyx are not. (Tortora & Derrickson, 2009)

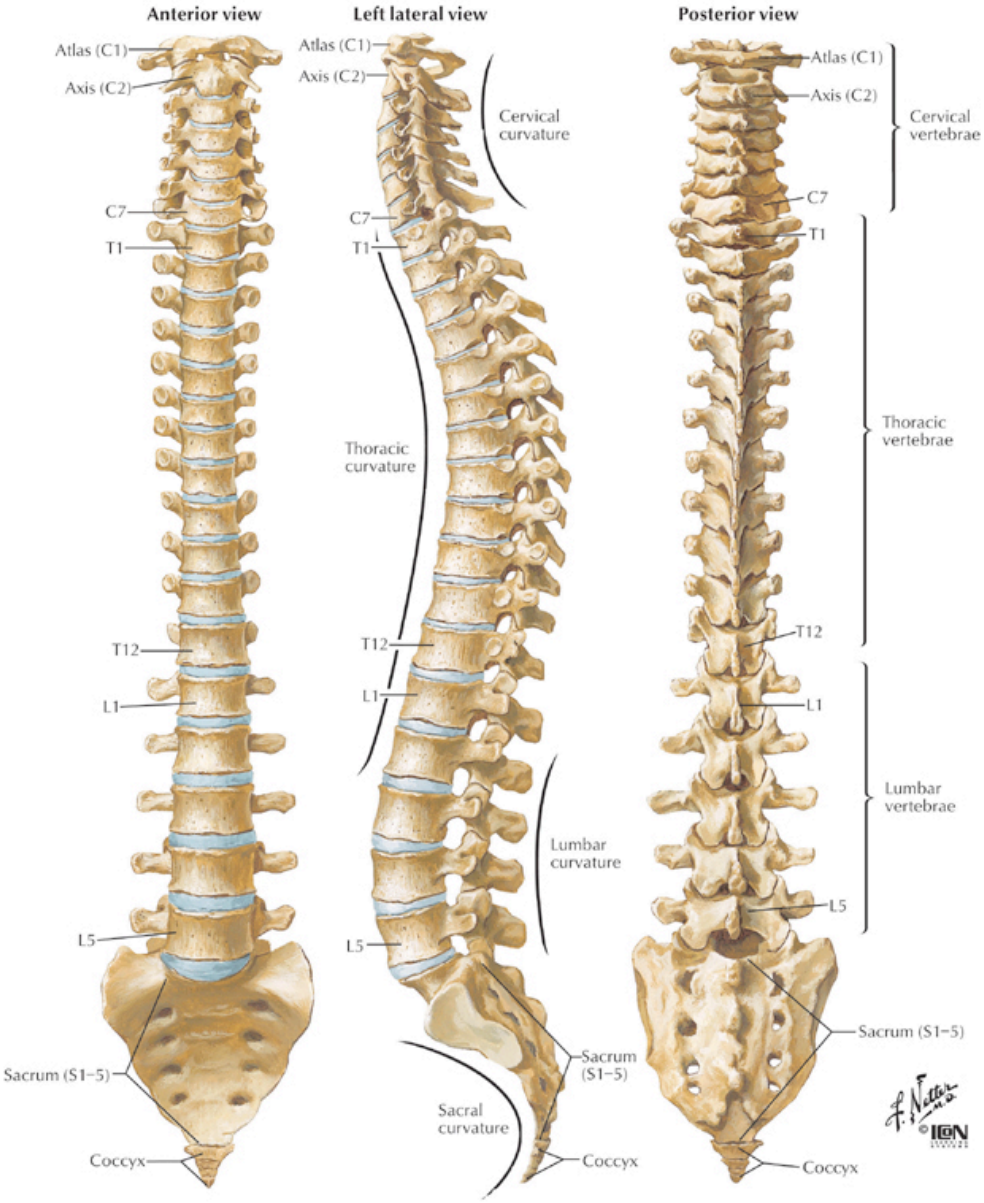

Figure 2 - The Vertebral Column from the Anterior, Posterior and Left Lateral View (Netter, 2006)

1.2.1 Curvatures of the spine

The vertebrae are arranged in such a way as to form anterior-posterior curves in the vertebral column, which can be seem from the side. These curves provide the vertebral column with much more strength and resilience, approximately 10 times more than if it were a straight rod. (Lippert, 2006)

In the sagittal plane, the vertebral column shows the following curvatures:

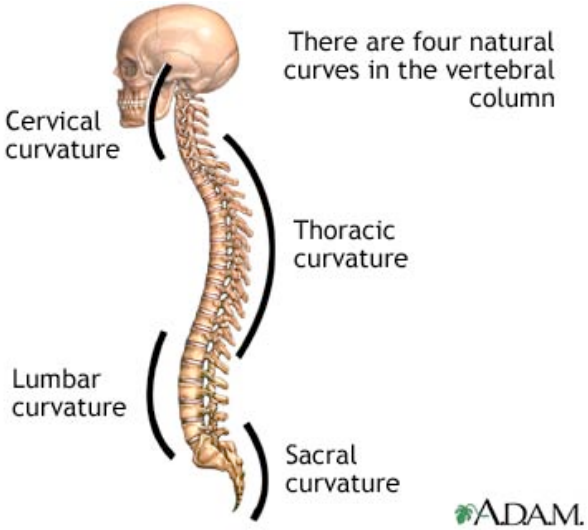

Figure 3 - Curvatures of the Spine (Zieve & Ma, 2009)

1. Cervical curvature, concave posteriorly (lordosis).
2. Thoracic curvature, convex posteriorly (kyphosis).
3. Lumbar curvature, concave posteriorly (lordosis).
4. Sacral curvature, concave posteriorly (kyphosis). The sacral is fixed as a result of fusion of the sacral vertebrae. (Kapandji, 2004)

1.2.2 Intervertebral disc

The joint between 2 vertebrae is a symphysis. (Kapandji, 2004) The intervertebral discs are found between the bodies of adjacent vertebrae from the second cervical vertebra to the sacrum. They account for about 25% of the height of the vertebral column. Each disc has an outer fibrous ring consisting of fibrocartilage called the annulus fibrosus and an inner soft, pulpy, highly elastic

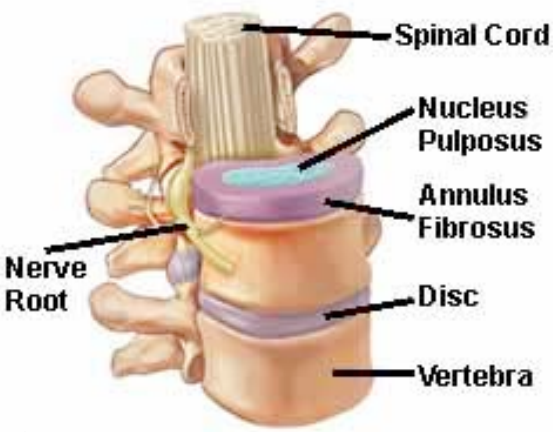

Figure 4 - Intervertebral Disc (Jean-Jacques Abitbol, Edgar G. Dawson, & Regis W. Haid Jr., 2013)

substance called the nucleus pulposus. The discs form strong joints, permit various movements of the vertebral column, and absorb vertical shock. Under compression, they flatten and broaden. (Tortora & Derrickson, 2009)

1.2.3 The structure of the vertebrae (Tortora & Derrickson, 2009)

Vertebrae typically consists of a body, vertebral arch and several processes. The body, the thick, disc-shaped anterior portion, is the weight-bearing part of a vertebra. Its superior and inferior surfaces are roughened for the attachment of cartilaginous intervertebral discs. The anterior and lateral surfaces contain nutrien foramina, openings through which blood vessels deliver nutrients and oxygen and remove carbon dioxide and wastes from bone tissue.

The vertebral arch is fromed by two short, thick processes, the pedicles, project posteriorly from the vertebral body to unite with the flat laminae. The vertebral arch extends posteriorly from the body of the vertebra; together, the body of the vertebra and the vertebral arch surround the spinal cord by forming the vertebral foramen. The vertebral foramen contains the spinal cord, adipose tissue, areolar connective tissue, and blood vessels. Collectively, the vertebral foramina of all vertebrae form the spinal canal. The pedicles exhibit supeior and inferior indentations called vertebral notches. When the vertebral notches are stacked on top of one another, they form an opening, called intervertebral foramen, between adjoining vertebrae on both sides of the column. Each opening permits the passage of a single spinal nerve that passes to a specific region of the body.

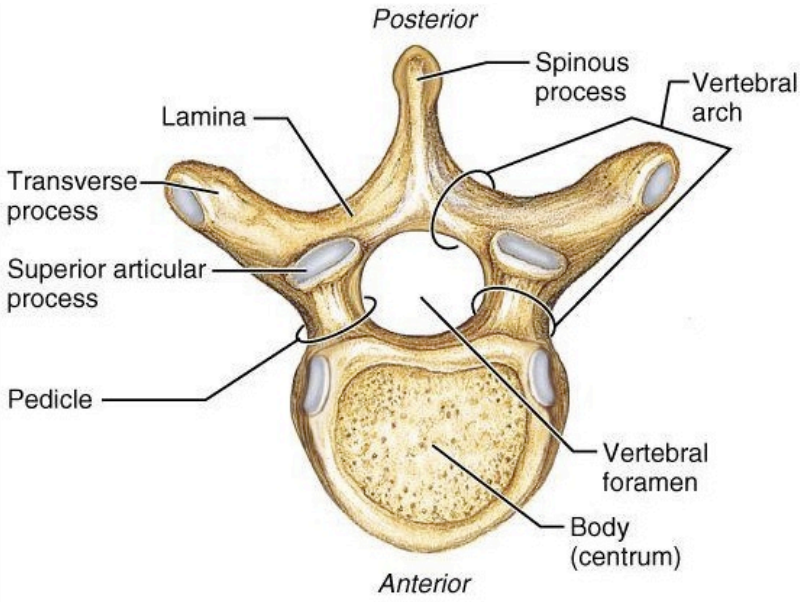

Seven processes arise from the vertebral arch. At the point where a lamina and pedicle join, a transverse process extends laterally on

Figure 5 - General Structures of the Vertebrae (Cherms, 2012)

each side. A single spinous process projects posteriorly from the junction of the laminae. These three processes serve as points of attachment for muscles. The remaining four processes form joints with other vertebrae above or below. The two superior articular processes of a vertebra articulate with the two articular processes of the vertebra immediately above them. In turn, the two inferior articular processes of that vertebra articulate with the two superior articular processes of the vertebra immediately below them, and so on. The articulating surfaces of the articular processes, called facets, are covered with hyaline cartilage. The articulations formed between the bodies and articular facets of successive vertebrae are termed intervertebral joints.

1.2.4 Function

The vertebral column is able to provide protection to the spinal cord because it encases it. Not only does this multijointed rod provide movement, it the arrangement of the different segments also provide effective shock absorption and transmission. The vertebral column functions as a strong, flexible rod with elements that can move forwar, backward, and sideways and rotate. (Lippert, 2006)

The functional components of the intervertebral disc are the annulus fibrosus enclosing the central nucleus pulposus and the vertebral endplates. The anatomical unit of the lumbar spine is the vertebral body with its attached posterior elements and the disc below. The nerve roots travel within the common dural sac (cauda equina) and they exit at each level. They are numbered according to the pedicle beneath which they pass. (Wiesel, 2011)

The spinal canal is divided into zones from medial to lateral in the following order: central canal, subarticular zone, foraminal zone and extraforaminal zone. (Wiesel, 2011)

1.2.5 Kinesiology (Lippert, 2006)

The vertebral column maintains and establishes the longitudinal axis of the body. Because it is a multijointed rod, the vertebral column's motions occur as the result of the combined motions of individual vertebrae. The vertebral column

provides a pivot point for motion and support of the head at the cervical region. The weight of the head, shoulder girdle, upper extremities and trunk are transmitted through the vertebral column.

1.3 Lumbar and Sacral spine

1.3.1 Lumbar region (Tortora & Derrickson, 2009)

The lumbar vertebrae are the largest and strongest of the unfused bones in the vertebral column because the amount of body weight supported by the vertebrae increases toward the inferior end of the backbone. Their various projections are short and thick. The superior articular processes are directed medially instead of superorly, and the inferior articular processes are directed laterally instead of inferiorly. The spinous processes are quadrilateral in shape, thick and broad, and project nearly straight posteriorly. The spinous processes are well adapted for the attachment of the large back muscles.

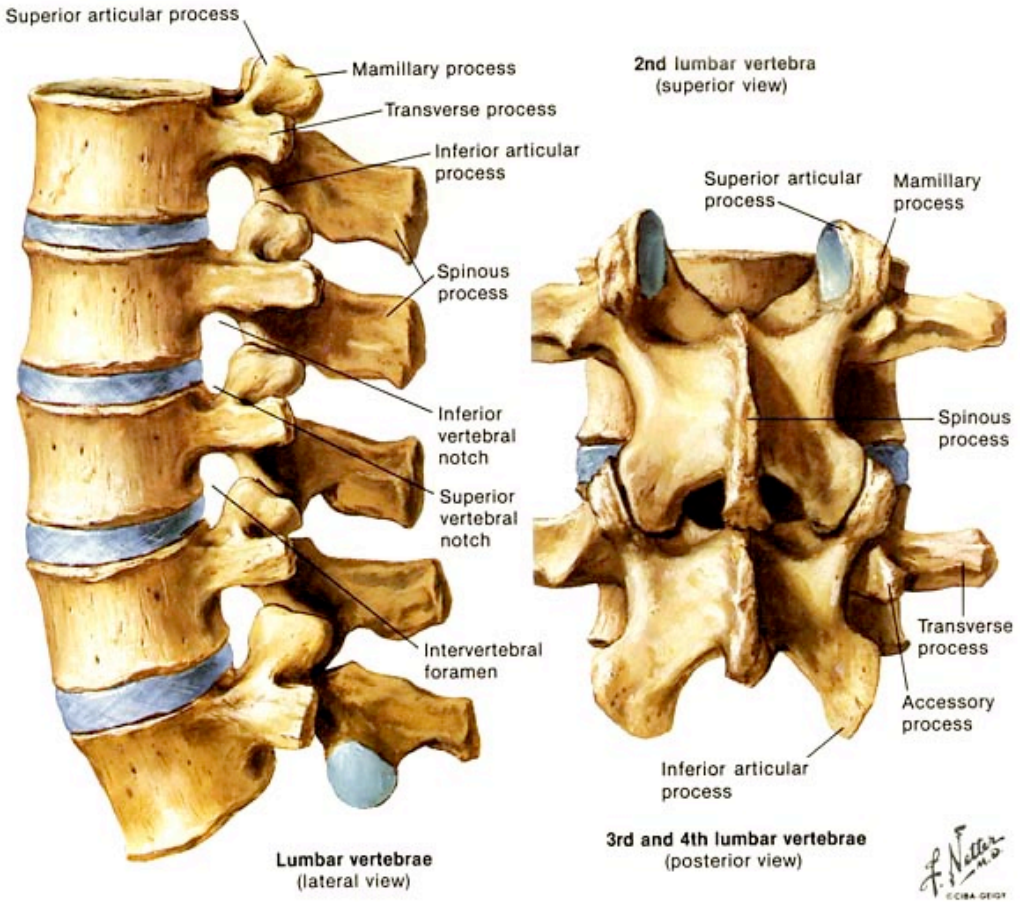

Figure 6 - Anatomy of the Lumbar Spine (Netter, 2006)

1.3.2 Sacrum (Tortora & Derrickson, 2009)

The sacrum is a triangular bone formed by the union of five sacral vertebrae. Positioned at the posterior portion of the pelvic cavity medial to the two hipbones. The sacrum serves as a strong foundation for the pelvic girdle. The concave anterior side of the sacrum faces the pelvic cavity. It is smooth and contains four transverse lines that mark the joining of the sacral vertebral bodies. At the ends of these lines are four pairs of anterior sacral foramina. The lateral portion of the superior surface of the sacrum contains a smooth surface called the sacral ala, which is formed by the fused transverse processes of the first sacral vertebra. The convex, posterior surface of the sacrum contains a median sacral crest, the fused spinous processes of the upper sacral vertebrae; a lateral sacral crest, the fused transverse processes of the sacral vertebrae; and four pairs of posterior sacral foramina. These foramina connect with anterior sacral foramina to allow passage of nerves and blood vessels.

The broad superior portion of the sacrum is called the base. The sacral promontory, anteriorly projecting border of the base, is one of the points used for measurements of the pelvis. On both lateral surfaces, the sacrum has a large ear-shapes auricular surface that articulates with the ilium of each hipbone to form the sacroiliac joint. Ligaments are attached to the sacral tuberosity, which is a roughened surface posterior to the auricular surface. The sacral tuberosity unites with the hipbones to form the sacroiliac joints. The superior articular processes of the sacrum articulate with the inferior articular processes of the fifth lumbar vertebra, and the base of the sacrum articulates with the body of the fifth lumbar vertebra to form the lumbosacral joint.

1.3.3 Muscles of the lumbar spine (Bogduk, 2005)

The muscles that move the vertebral column are very complex because they have multiple origins and insertions and there is considerable overlap among them. (Tortora & Derrickson, 2009) The lumbar spine is surrounded by muscles, which can be divided into three groups (for descriptive purposes and on functional grounds. They are:

1. Psoas major, which covers the anterolateral aspects of the lumbar spine.

2. Intertransversarii laterals and quadratus lumborum, which connect and cover the transverse processes anteriorly.
3. The lumbar back muscles, interspinales, intertransversarii mediales, multifidus and lumbar erector spinae, which lie behind and cover the posterior elements of the lumbar spine.

Psoas major is a long muscle which arises from the anterolateral aspect of the lumbar spine and descends over the brim of the pelvis to insert into the lesser trochanter of the femur. The action of this muscle is to flex the hip.

The intertransversarii laterals consists of two parts: the intertransversarii laterals ventrales and the intertransversarii laterals dorsales. The ventral intertransversarii connect the margins of consecutive transverse processes, while the dorsal intertransversarii each connect an accessory process to the transverse process below. The function of the intertransversarii laterals has never been determined experimentally but it may be like that of the posterior, intersegmental muscles.

Quadratus lumborum is a wide, more or less rectangular, muscles that covers the lateral two-thirds or so of the anterior surface of the L1 to L4 transverse processes and extends laterally a few centimetres beyond the tops of the transverse processes. The muscle connects the lumbar transverse processes, the ilium and the 12th rib. The irregular and inconstant structure of the quadratus lumborum makes it difficult to discern exactly its function. The major action of the muscle would be lateral flexion of the lumbar spine although this muscle is said to be to fix the 12th rib during respiration.

The lumbar interspinales are short paired muscles that lie on either side of the interspinous ligament and connect the spinous processes of adjacent lumbar vertebrae. Although the interspinales are quite small and would not contribute appreciably to the force required to move a vertebrae, it is said to produce posterior sagittal rotation of the vertebra above.

The intertransversarii mediales arise from an accessory process, the adjoining mammillary process and the mamillo-accessory ligament that connects these two processes. They insert into the superior aspect of the mammillary process of the vertebra below. Similar to the lumbar spinales, the intertransversarii mediales are very small muscles that would not be able to produce such force to move a vertebra. They lie very close to the axis of lateral

flexion and behind the axis of sagittal rotation, making them questionable whether they could contribute to either lateral flexion or posterior sagittal rotation of the lumbar vertebra.

The multifidus is the largest and most medial of the lumbar back muscles. It consists of a repeating series of fascicles, which stem from the laminae and spinous processes of the lumbar vertebrae and exhibit a constant pattern of attachments caudally. The fibres of multifidus are arranged in such a way that their principal action is focused on individual lumbar spinous processes. The action for the multifidus is posterior sagittal rotation of the lumbar spine, although the larger muscles need to be first produce the movement. The secondary action is to increase the lumbar lordosis and the compressive and tensile loads on any vertebrae and intervertebral discs interposed between its attachments.

The lumbar erector spinae consists of two muscles, which are the longissimus thoracis and the iliocostalis lumborum. Each of these mucscles has two components being, a lumbar part, consisting of fascicles arising from lumber vertebrae, and a thoracic part, consisting of fascicles arising from thoracic vertebrae or ribs. These muscles main action is to extend the vertebral column.

1.3.4 Ligaments of the lumbar spine (Bogduk, 2005)

The lumbar spine ligaments can be classified as follows:

- Ligaments that interconnect the vertebral bodies.
- Ligaments that interconnect the poserior elements.
- Iliolumbar ligament.

Anuli fibrosi's inner fibres are attached to the vertebral endplate forming an internal capsule that envelopes the nucleus pulposus. The outer fibres are attached to the ring apophysis which constitute the ligamentous portion of the anulus fibrosus.

Anterior longitudinal ligament is a long band which covers the anterior aspects of the lumbar vertebral bodies and intervertebral discs. Inferiorly, the anterior longitudinal ligament extends into the sacrum, and superiorly, it continues into the thoracic and cervical regions to cover the anterior surface of the entire vertebral column.

The posterior longitudinal ligament forms a narrow band over the backs of the vertebral bodies but expends laterally over the backs of the intervertebral discs to give it a serrated, or saw-toothed, appearance.

The ligamentum flavum is a short but thick ligament that joins the laminae of consecutive vertebrae. At each intersegmental level, the ligamentum flavum is a paired structure, being represented symmetrically on both left and right sides. On each side, the upper attachment of the ligament is to lower half of the anterior surface of the lamina and the inferior aspect of the pedicle.

The interspinous ligaments connect adjacent spinous processes. There are three parts of the collagen fibres to the ligaments. The ventral part consists of fibres passing posterocranially from the dorsal aspect of the ligamentum flavum to the anterior half of the lower border of the spinous process above. The middle part forms the main component of the ligament, and consists of fibres that run from the anterior half of the upper border of one spinous process to the posterior half of the lower border of the spinous process above. The dorsal part consists of fibres from the posterior half of the upper border of the lower spinous process which pass behind the posteior border of the upper spinous process, to form the supraspinous ligament.

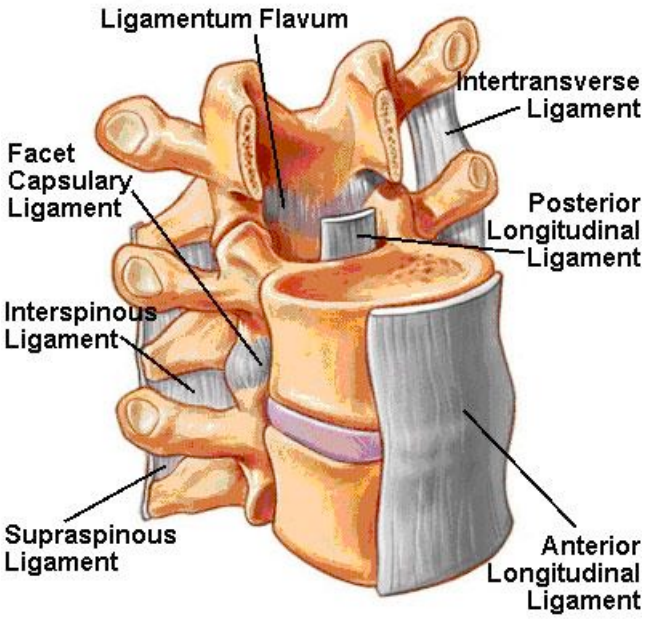

Figure 7 - Ligaments of the Lumbar Spine (Reid, 2012)

The supraspinous ligament lies in the midline. It runs posterior to the posterior edges of the lumbar spinous processes, to which it is attached, and bridges the interspinous spaces.

The iliolumbar ligaments are present bilaterally, and on each side they connect the transverse process of the fifth lumbar bertebra to the ilium. Each ligament extends from the tip of its transverse process to an area on the anteromedial surface of the ilium and the inner lip of the iliac crest. The iliolumbar ligament forms a strong bond between L5 vertebra and the ilium, with different parts

subserving different functions. As a whole, the ligament is disposed to prevent forward sliding of the L5 vertebra on the sacrum. It also resists twisting, and forward, backward and lateral bending of the L5 vertebra.

1.3.5 Lumbar spinal nerve (Bogduk, 2005)

The lumbar spinal nerves lie in the intervertebral foramina and are connected to the spinal cord by the spinal nerve roots, which occupy the vertebral canal. The spinal nerves can be divided into these branches; the ventral and dorsal rami.

The lumbar spinal nerves lie in the intervertebral foramina and are numbered according to the vertebra beneath which they lie. For example, the L1 spinal nerve lies below the L1 vertebra in the L1-L2 intervertebral foramen. Centrally, each spinal nerve is connected to the spinal cord by a dorsal and ventral root.

The dorsal root of each spinal nerve transmits sensory fibres from the spinal nerve to the spinal cord. The ventral root largely transmits motor fibres from the cord to the spinal nerve but may also transmit some sensory fibres. The ventral roots of the L1 and L2 spinal nerves additionally transmit preganglionic, sympathetic, efferent fibres. Table 1 summarizes the myotomes of the lumbar and sacral spinal levels.

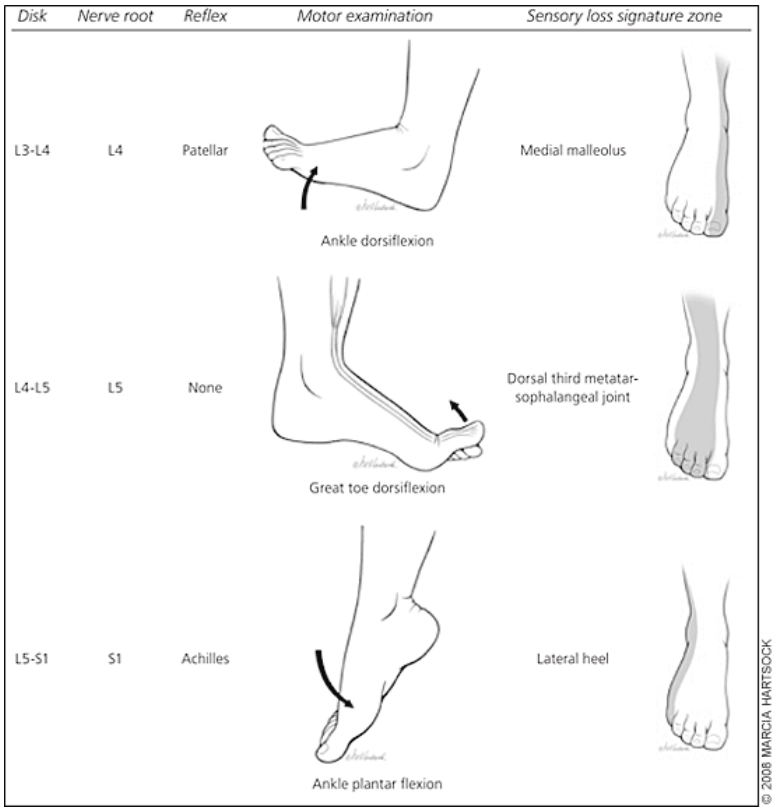

Figure 8 - Localizing Neurologic Levels for the Lumbar Segment (Gregory, Seto, Wortley, & Shugart, 2008)

Figures 8 and 9 show the localization of the neurological levels for the lumbar spine and the dermatomes of all the spinal level, respectively.

Table 1 - Myotomes of the Lower Extremity (Unknown, 2010)

Myotome	Spinal Level
Hip flexion	L1,2
Hip Extension	L5, S1
Knee Flexion	L5. S1
Knee Extension	L3,4
Ankle Dorsiflexion	L4
Ankle Plantarflexion	S1,2
1st Metatarsal Extension	L5

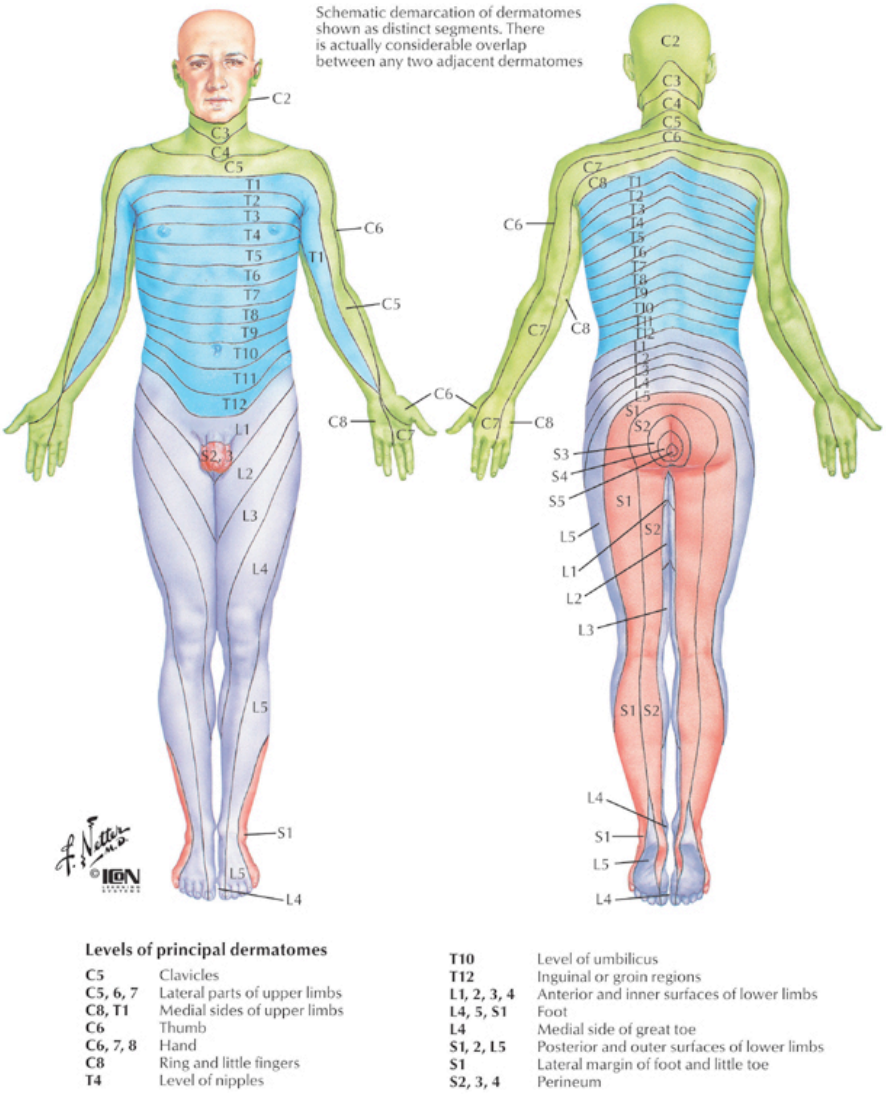

Figure 9 - Dermatomes of all Spinal Levels (Netter, 2006)

1.3.6 Bulging of disc (Postacchini, 1999)

Under flexion loading, the annulus is submitted to compressive stresses in the region where the compressive force is applied and to tensile stresses in the opposite zone. Thus, anterior-flexion loading causes compressive stresses in the anterior part of the disc and tensile stresses in the posterior part, whereas the opposite occurs under extension loading. On lateral bending, compressive stresses take place on the concave side of the spinal curve and tensile stresses on the convex side.

Upon flexion-extension loading, the nucleus pulposus moves away from the zone the disc submitted to compressive force, i.e., it moves posteriorly during flexion and anteriorly during extension. Possibly, this shifting of the nucleus provides a better distribution of the load across the disc during vertebral motion.

Upon flexion loading, the disc bulges anteriorly during anterior-flexion, posteriorly during extension and on the convex side of the spinal curve during lateral bending; thus, disc bulging occurs in the zone of the disc submitted to compressive stresses.

1.4 Disc Herniation

1.4.1 Classification of disc herniations (Wiesel, 2011)

1. The integrity of the annulus fibrosus and whether there is a connection of herniated discal material with the disc space.
2. The anatomic location of the herniated material relative to the disc space, the canal, the compressed nerve root using the classification above.

Accurate anatomic classification of disc herniations facilitates preoperative planning and can minimize the risk of surgical complications such as missed pathology and iatrogenic nerve root injury.

1.4.2 Pathogenesis (Wiesel, 2011)

In the normal disc, the nucleus pulposus absorbs and releases water to balance mechanical loads. The annulus fibrosus converts these loads to hoop

stresses, thereby containing the nuclear material. The endplates allow diffusion of nutrition into the nucleus as well as waste products out of it. Together, they allow for the three basic spinal segmental functions: mobility, stability, and protection of nearby neurological structures. With early or immediate disc degeneration (natural aging with or without repetitive trauma), the endplates fail to allow adequate diffusion, the nucleus fails to replace degraded proteoglycans, and annular support weakens. Biomechanical dysfunction occurs, with possible herniation of nuclear material. Many disc herniations do not cause pain or neurological symptoms. A combination of herniation, nerve root compression, and an imflammatory interface is required for nerve root dysfunction and associated radiculopathy and sciatica. Table 2 shows the clinical features of herniated lumbar nucleus pulposus.

Table 2 - Clinical Features of Lumbar Herniation (Netter, 2006)

Level of herniation	Pain	Numbness	Weakness	Atrophy	Reflexes
L4-5 disc; 5th lumbar nerve root	Over sacro-iliac joint, hip, lateral thigh and leg	Lateral leg, first 3 toes	Dorsiflexion of great toe and foot; difficulty walking on heels; foot drop may occur	Minor	Changes uncommon in knee and ankle jerks, but internal hamstring reflex diminished or absent
L5-S1 disc; 1st sacral nerve root	Over sacro-iliac joint, hip, postero-lateral thigh and leg to heel	Back of calf, lateral heel, foot to toe	Plantar flexion of foot and great toe may be affected; difficulty walking on toes	Gastrocne-mius and soleus	Ankle jerk diminished or absent

1.4.3 Indications for surgery

Many studies have shown that with time and nonoperative treatment, over 90% of patients with a first-time lumbar disc herniation will get better without surgery. (Wiesel, 2011) Accordingly, to propose surgery requires clear indication as follows:

Absolute indication

- Bladder and bowel involvement secondary to a massive disc hernation and cauda equina syndrome: immediate surgical intervention.
- Progressive neurological deficit: the earlier the better prognostically

Relative indication

- Failure of conservative measures greater than 6 weeks to 3 months
- Multiply recurrent sciatica
- Significant neurological deficit

In each case, the properly informed patient must clearly understand the current best evidence: long-term (5-year) outcomes are similar between surgery and non-operative treatment, but surgery can afford more rapid and resolution of symptoms. (Wiesel, 2011)

1.4.4 Contraindications (Haher & Merola, 2003)

The two contraindications are:

- Inconclusive diagnosis of herniated nucleus pulposus (HNP)
- Symptom amplification

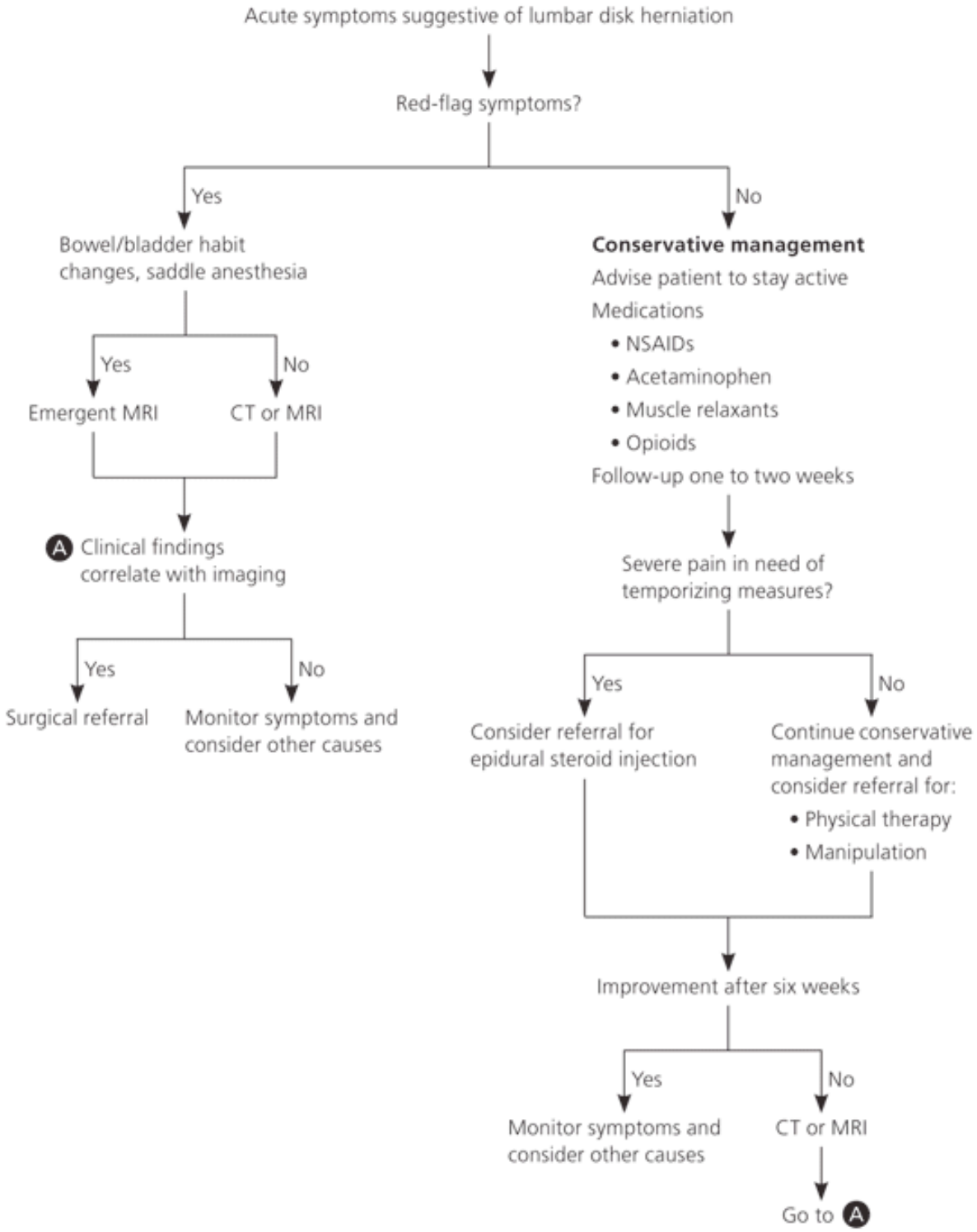

Figure 10 - Algorithm for Treatment of Acute Lumbar Disc Herniation (Gregory, Seto, Wortley, & Shugart, 2008) (Jean-Jacques Abitbol, Edgar G. Dawson, & Regis W. Haid Jr., 2013)

1.4.5 History and physical findings (Wiesel, 2011)

The most common complaint in pain with or without associated paraesthesia or weakness in a specific monoradicular anatomic distribution.

1.4.6 Imaging and other diagnostic studies (Wiesel, 2011)

Magnetic Resonance Imaging (MRI) is the imaging study choice for the diagnosis and anatomic classification of lumbar disc herniations. It is highly sensitive and specific and provides, along with the clinical picture, adequate information for detailed pre-operative planning.

Computer Tomography (CT)-myelography is invasive and less specific than MRI but provides excellent sensitivity when MRI is unavailable or contraindicated.

Plain radiographs may slow disc space narrowing, early formative of osteophytes, or a "sciatic scoliosis". While providing no direct evidence of a herniated disc, they may be helpful to rule out unexpected destructive pathology in patients who have failed to respond to non-operative intervention or those with red flags. They also allow excellent delineation of bony anomalies that may prove vital to pre-operative planning and intra-operative localisation, such as transitional lumbosacral articulations or spina bifida occulta.

1.4.7 Differential diagnosis (Wiesel, 2011)

- Intraspinal, extrinsic compression or irritation at the level of the nerve root: spinal stenosis, osteomyelitis or discitis, neoplasm, epidural fibrosis (scar).
- Intraspinal, extrinsic compression or irritation proximal to the nerve root: conus and cauda lesion such as neurofibroma or ependymoma.
- Intraspinal, intrinsic nerve root dysfunction: neuropathy (diabetic, idiopathic, alcoholic, iatrogenic [chemotherapy]), herpes zoster, arachnoiditis, nerve root tumor.

- Extraspinal sources distal to the nerve root: pelvic or more distal neoplasms with associated sciatic or femoral nerve compression, sacroiliac disease (e.g., infection, osteoarthritis), osteoarthritis of the hip, peripheral vascular disease.

1.4.8 Conservative and non-invasive management (Wiesel, 2011)

Although the evidence base is still slightly unclear, these are the following recommendations:

- Rest: bed rest (no more than two or three days), activity or job modification and weight loss
- Medication: analgesics, non-steroidal anti-inflammatories, and tapered doses of oral steroids
- Exercise: physical therapy
- Injections: epidural or selective root blocks (may provide some temporary relief)
- Time: 6 weeks to 3 months (unless absolute indications for surgery exist)

1.4.9 Surgical management (Wiesel, 2011)

The evidence base is clear that discectomy and microdiscectomy are the operative techniques with the best-documented long-term results and are the gold standards of surgery for lumbar disc herniation.

1.4.10 Advantages of microdiscectomy (Haher & Merola, 2003)

Microdiscectomy allows the surgeon to perform the procedure with greater accuracy and with less risk of complications due to the surgical misadventures of excessive bleeding, nerve root damage, dural laceration, and missed and retained disc fragments.

The post-operative course is so predictable and benign that the surgeon can confidentially release the patient from the hospital the day of surgery.

Relatively few instruments are required for the procedure.

1.4.11 Surgical procedure (Hanscom, 2012)

During surgery, the patient would be lying face down on a padded frame. The patient is carefully positioned so that the space between his/her vertebrae can be opened as widely as possible.The surgeon creates an opening in one of two way. The first is via a small incision, about 1 inch to 1 ½ inches, made with a scalpel. The second is via a small tube that is inserted through the muscle. The muscles are dissected over to the side to allow a view of the lamina. A small amount of bone is trimmed from the lamina to create a space between the two vertebrae. The part where the lamina is trimmed is called laminotomy. Some ligaments between the vertebrae will also have to be removed. The surgeon uses a microscope to view the nerve, which is then retracted towards the middle of the spine. The disc material may be easily seen and removed or it can be hidden under the nerves in almost any direction. The surgeon will look in every possible place for the ruptured disc. Sometimes, only the fragment outside the disc is removed. Other times, a window is made in the ring of the disc and any loose material within the disc is also removed. Occasionally, the bulging disc is firm enough so that just the laminotomy is performed and no disc material has to be removed to relieve pressure from the nerve. In certain instances, the disc can rupture to one side of the spine instead of the central canal. If this occur, the surgery is performed outside of the main spinal canal.

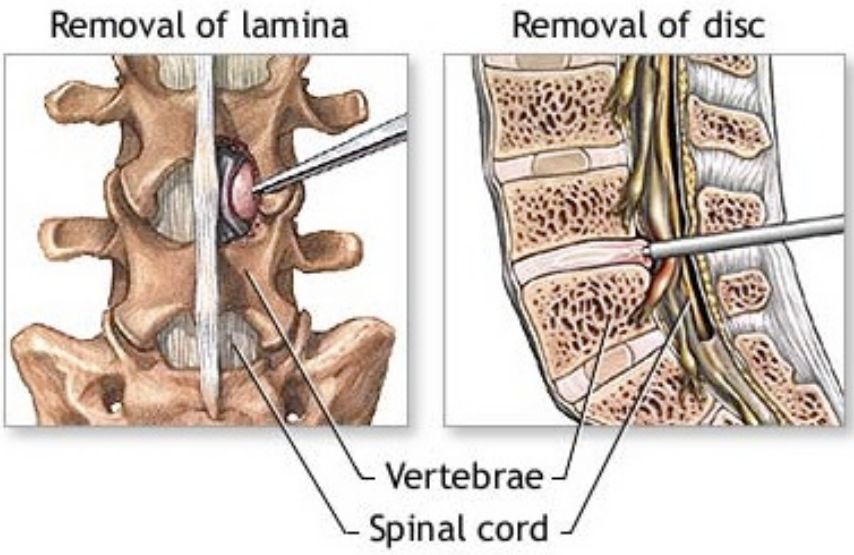

Figure 11 - Removing the lamina (laminotomy) and the excess of the disc (microdiscectomy) (Unknown, Herniated Disc - Lumbar, 2013)

1.4.12 Post-operative care (Wiesel, 2011)

After surgery, patients may be fitted with a light lumbar corset if desired and are encouraged to walk once anesthesia has worn off and pain permits. About 85% are discharged as out-patients. 15% will be older or have nausea and vomiting requiring an overnight stay and 23-hour observation.

When the patient gets home, he/she can engage in a program of progressive walking, stretching, and corset use for comfort. For those progressing slowly, physical therapy could be introduced. Contraindications for the first few weeks include heavy lifting and excessive bending and twisting.

If all is well, they may drive in about a week and return to light work once they feel up to it. Heavy labor should be avoided for 6 to 12 weeks to ensure proper soft tissue healing. Long-term activities are not restricted.

1.4.13 Rehabilitation (McFarland, 2007)

In order to maximize recovery and to prevent further problems, it is very important that muscle function is at its best after a surgery. After a spinal surgery, spine specific training is generally recommended because it is important to protect patients from having a vulnerable localized weakness. Additionally, re-education on posture, body mechanics and back protection is very critical to maximize return of function for patients post-operation.

There are varieties of ways to control pain post-microdiscectomy. Physical therapy such as ice, hot towel or electrical stimulation may be used to decrease pain temporarily. The use of ice would be superficial on the skin, which has an effect of local pain relief. Using hot towel would decrease pain and inflammation locally. Diadynamic and middle frequency currents have analgetic effects could also be used. Additionally, soft tissue techniques, strengthening of core muscles and relaxation of tense muscles could help reduce pain and increase ROM. The most important is re-education of posture.

Manual methods of physiotherapy are used before correcting of the posture. Locally, soft tissue techniques are used on the scar to increase the mobility of the skin around it since the skin, connective tissues, fascias, muscles and bones are somehow interconnected with each other, which intern helps with ROM. Stretching of shortened muscles and relaxation of hypertonic muscles are also

essential before strengthening the weaker ones. These therapies will then improve ROM and so re-education of posture can begin.

Faulty posture can cause pain; therefore, having a good posture will help with prevention of more pain that will appear after the operation. Posture education can teach patients about disc protection that can be associated with good spine alignment.

Strengthening deep trunk muscles that support the spine is a type of physical therapy, called segmental stabilization of the spine, focuses on addressing localized weakness in the deeper trunk muscles, which can protect individual segments of the spine. This type of therapy has similar concept to Dynamic Neuromuscular Stabilization, which will be explained briefly in the next chapter. The patients who have gone through minimally invasive spine procedures, like microdiscectomy, can recover the muscles' function maximally. Many therapists use the techniques for segmental stabilization as an essential part of spine programs, especially, when disc pathology has involved, such as a herniated disc.

The two muscle group that fire first to stabilize the spine are multifidus and transverse abdominis. There are evidence multifidus atrophies at the level of a disc herniation. Most importantly, the recovery of this muscle function must be specifically retained, as it does not occur automatically when the disc pathology is resolved. Training of the multifidus and transverse abdominis requires concentration from the patient. Transverse abdominis is recruited by drawing the abdomen in, creating a pressure toward the back of lumbar spine. The patient can also learn to practice the motion lying on their back, creating a downward pressure with the lumbar spine. Once the patient is able to do this, they would try to maintain pressure while doing different movements with their upper and lower extremities to train the muscles to maintain spinal stability during those movements. The goal of this training is to provide enough practice and repetition so the function of these muscles is automatic and will start to occur during all other activities and exercises.

After spine stabilization training has begun, adding strength training with resistance exercises is helpful for functional movement. It is recommended the patient have spine stabilization capabilities and symptoms under control before increasing this.

Addition to strength training, endurance is also important. Both aspects have shown to be related to incidence in low back pain, therefore, improving them can prevent pain from recurring.

Gaining mobility and flexibility are also factors that help prevent conditions from worsening after surgery. Working on the mobility of various joint areas that a given nerve pathway may cross can be helpful for restoring full excursion of that pathway.

1.4.14 DNS – Rehabilitation (Kolar, 2012)

DNS is developed by Assoc. Prof. Pavel Kolar, PaedDr., Ph.D. from the 2nd Medical Faculty at Charles University in Prague. DNS is a unique manual rehabilitative approach to activate the "Integrated Stabilizing System" (ISS) for the purpose of achieving exciting levels of improved function. Its concept is based on the scientific principles of developmental kinesiology.

The Integrated Stabilizing System of the Spine (ISSS) consists of short intersegmental spinal muscles (multifidi), deep neck flexors, diaphragm, abdominal wall, and pelvic floor. These muscles typically automatically activate prior to purposeful movement to establish a stable base ('Feedforward Mechanism'). Each movement initiates with the stabilization of body segments to provide balance, efficient coordination and stability to the participating elements. Activation of the stabilizing muscles during any movement is subconscious. All of the stabilizing muscles act as a functional unit, which ensures stabilization of the spine and torso during any phasic movement.

The DNS system's diagnosis is based on comparing the patient's stabilizing pattern with the stabilization developmental pattern of a healthy baby. The treatment for patients is to train ideal patterns as defined by developmental kinesiology.

The concept's ultimate strategy is to teach the brain to maintain central control and stability of the movement restored during the therapy. This could be achieved by activation/stimulation of the stabilizers when placing the patient in primal developmental positions. The spinal and extremity joints reach centration during activation. The inta-abdominal pressure is activated and the spine becomes axially extended. The foundation of healthy movement is formed when

there is stability in all of the body segments. As the program advances and becomes more challenging, these ideal movement patterns fall under the patient's voluntary control, which would require less assistance from the physiotherapist. Through the repetition of the exercises, eventually the central control establishes an automatic model that becomes a fundamental part of everyday movement.

Patients can be both assessed and treated by the functional ISSS Tests. They include the diaphragm tests (inspiration and expiration), hip flexion, intra-abdominal pressure, trunk and neck flexion, arm lifting, and extension tests.

1.4.15 Prognosis (Wiesel, 2011)

There is an 85% likelihood of an excellent or good outcome 5 years postoperatively.

Patients with significant medical or social comorbidities, such as diabetes and heavy smoking, worker's compensation or litigation and psychological problems, like depression, are less likely to do well. Each factor is associated with a 15% reduction in the likelihood of an excellent or good outcome.

1.4.16 Complications (Wiesel, 2011)

Surgeon-dependent aspects such as wrong level, wrong side, missed pathology, iatrogenic instability, battered root syndrome, dural tear, haemorrhage, positioning (e.g. eyes, ulnar nerve) may cause complications. Additionally, operative environment or patient-dependent aspects for causing complications are would infection, disc space infection, urinary retention, thrombophlebitis or pulmonary embolism.

2 Special Part – Case study

2.1 Methodology

This case study has been completed at the rehabilitation centre at FNKV (Fakultní nemocnice Královské Vinohrady) on Mrs. T. H., born on 09.02.1971, diagnosed with post microdiscectomy along the segments of L5/S1, from 01.02.2012 to 07.02.2012. The initial kinesiological examination was conducted on the patient on the first day of therapy, with 6 therapy sessions and a final kinesiological examination in succession on the last day of therapy. Each therapy session lasted 45 minutes.

The physiotherapists at the rehabilitation center mostly treat the in-patients who are admitted to the rehabilitation center, from stroke to total hip replacement patients, as well as some additional out-patients, from myopathy to Marfan syndrome patients, that come for treatment once or twice a week. The rehabilitation center is equipped with treatment rooms, a small gym and patients' accommodation rooms. The patients whom are able to independently transfer themselves would be treated in the treatment rooms and the patients whom are dependent on help would be treated in their accommodated rooms. The gym consists of treadmills, bikes, gym balls, mats, senso-motoric tools and weight machines. The treatment rooms have a therapy table, solux lamp and also some additional gym balls, over-balls, senso-motoric tools, terra-bands as well as towels for the use of hot roll (Brugger methods). The physiotherapists assist the patients when they are using any equipment to prevent any further injuries.

The physiotherapists themselves would use methods such as, post-isometric relaxation (PIR), proprioceptive neuromuscular facilitation (PNF), soft tissue techniques, dynamic neuromuscular stabilization (DNS), joint mobilization, senso-motoric stimulation (SMS), Vojta techniques, Brugger methods and some exercises to treat the patients.

The methods used in this case study are hot roll by Brugger methods, soft tissue techniques, PIR, joint mobilization, DNS and SMS.

The devices used in the case study are the therapy table, gym ball, and towel for hot roll.

The supervisor for my practice and case study is Mgr. Pavla Kratochvilova. She closely watches the therapies done on the patient. Mgr. Kratochvilova performed and supervised the Dynamic Neuromuscular Stabilization exercises done on the patient.

The Ethics Committee of the Faculty of Physical Education and Sport, Charles University in Prague, Czech Republic has approved this case study (approval number: 052/2012) and the patient has been informed before any examinations and therapies were carried out.

2.2 Differential consideration

The pain that the patient has been complaining about is mostly on and around L5/S1 and also deep into the scar. Sometimes the pain that she has been complaining about radiates to both lower extremities. This shows that radiculopathy could be present.

The shortened and sometimes painful piriformis could be connected to the restricted sacro-iliac joint.

The muscle imbalance around the pelvic floor muscles, muscles providing hip movements and the essential breathing muscles could cause the restrictions of the sacro-iliac joint, which in turns causes the pain on the lower lumbar section.

The pain that the patient has could be from the restricted scar itself. Additionally, the connective tissues around it would be restricted. Restrictions between the connective tissues could cause stretching pain since the connective tissues are not mobile/elastic enough and have barriers when providing a movement, such as walking. The restrictions between the connective tissues and the fascia and muscles could also be the cause of muscle imbalance. The agonist muscle providing a specific movement could be weakened and so the synergists would, instead, provide that specific movement for the agonist muscle. The synergists could be overused which leads to the characteristics of hypertonicity and shortness of that muscle.

After the surgery, the muscles around the operated area such as, erector spinae along the L/S region, paravertebral muscles along the L/S region, quadratus lumborum, and the pelvic floor muscles would be weakened since the patient would not want to move to worsen the pain. The patient uses antalgic position around the pelvis, which alters the pelvic tilt to anteversion. This then causes muscle imbalance around the pelvis area and could affect the breathing pattern.

Muscle imbalance could proceed cranially by flat feet that are present in the patient.

2.3 Anamnesis

Examined person: T.H.

Sex: Female

Date of birth: 09.02.1971

Diagnosis: Post microdiscectomy on L5/S1 (63030)

Present state (Status presents):

Height: 158 cm
Weight: 62 kg
BMI: 24.8
BP: 110/70

A 41-year-old patient diagnosed with post microdiscectomy (operated on 10.10.11) was admitted to the hospital on the 31st January 2012 at 8.50 am. She feels pain around the operated area (lumbar area). In addition, the pain is present in the coccyx but only when sitting down. Sometimes the pain from the lumbar area radiates to both legs. The pain gets worse during movement, for example when walking. The pain isn't present when lying down. She usually sleeps well at night but sometimes wakes up due to the pain. The pain is about 4-5 on the visual analogue scale (VAS).

Family Anamnesis:
Her mother has hypertension, her father has glaucoma, her sister has psoriasis and her other siblings and children are healthy.

Personal Anamnesis:
She used to have asthma when she was younger and pancreatitis in 2007.

Social Anamnesis:

She lives with her family on the 3rd floor of an apartment, which has no elevator. She currently doesn't play any sports but she used to run (race) when she was younger.

Work Anamnesis:

She works in the kitchen at a school but now is on hold because she is hospitalised.

Abuses:

She neither smokes, nor drinks.

Gynaecological Anamnesis:

Her period comes regularly. She has two children and both birth were natural with no complications. Her daughter is 20 years old and her son is 11 years old.

Operations:

She had microdiscectomy on L5/S1 on 10.10.11.

Pharmacological Anamnesis:

- DHC tbl. Sos
- Miflonid inh. 1-0-1

Allergies:

She has no allergies.

Previous rehabilitation:

She had some previous physical therapy treatments of magnetotherapy.

Indication of rehabilitation:

The doctor indicated to reduce the low back pain that the patient has. In addition, the therapist should improve the muscle imbalance by using soft tissue techniques, exercises and mobilisation on the patient.

2.4 Initial Kinesiological Examination

*Examination provided on 01.02.12 in the morning.

1. Observation

A very independent patient who's able to ambulate herself.

She has no troubles understanding and communicating.

There seems to be no weakness or limited range of motion (ROM) on both of her upper and lower extremities.

2. Breathing Examination

The patient uses her chest to breathe (chest breathing). There is slight elevation of the shoulders when she inhales.

3. Postural Examination (Kendall, 2005)

Anterior view:

- Flat feet (bilateral)
- No arches visible
- Left knee is higher than right knee
- Right knee is more extended (slight hyperextension)
- Umbilicus faces more to the right side
- Pelvis rotate of the left side
- Shoulder of left side is longer and lower
- Shoulder of right side is shorter and higher

Posterior view:

- There is a slight external rotation of left feet
- Legs are aligned
- Gluteal line on left side is slightly higher
- Right knee is slightly lower than left knee
- Pelvis shifts to left side

- Triangle on left side is bigger than the right side
- Spine is shifted to the left side (mid-head and mid-heels are in line)
- Flat spine
- Visible scar on the lower lumbar area (caudo-cranial direction, 3 cm)
- Left shoulder is more depressed than the right shoulder (which is elevated)
- Head is slightly laterally rotated to the right side

Lateral view:

- Cervical spine is in lordosis
- Thoracic spine is flat
- Lumbar spine is in slight lordosis
- Trunk of patient is leaning forward

Modified Posture:

Standing on tip toes: no problem

Standing on heels: slightly unstable

4. Pelvis

Crista: left is slightly higher

Spina iliaca anterior superior (SIAS): left is higher

Spina iliaca posterior superior (SIPS): aligned

Tilt: anteversion of pelvis

5. Gait Examination (Kendall, 2005)

- Very slight pelvic movement
- Good movement of the arms
- Narrow base
- Slightly stiff trunk
- No rolling of the feet

Modified Gait

- Backwards (Gluteal): Normal. A lot of rotation of trunk and arms.

6. Spine Distances

- Stibor's distance: 5 cm
- Thomayer's distance: +51 cm
- Shober's distance: 12.5 cm
- Otto's distance: 3.5 cm
- Latero-flexion:
  - Left: 12.5 cm
  - Right: 17 cm
- Cepoj's distance: 1 cm
- Flesch de Forestier: 0 cm

7. Dynamic Test of the Spine

Flexion:

- Flat thoracic
- Lumbar is slightly restricted
- Pain is present when doing flexion in the lumbo-sacral region around the scar
- Range of motion is restricted

Extension:

- Patient feels slight pain when providing this movement around the scar
- Thoracic is restricted
- Range of motion is restricted in extension

Latero-flexion to the right side:

- Range of motion is restricted
- Arms are along side the trunk
- Thoracic is restricted
- Movement mostly on the lumbar spine

Latero-flexion to the left side:

- Range of motion is restricted, decreased compared to the right side
- Arms are along side the trunk
- Movement is mostly on the lumbar region
- Thoracic is restricted

8. Altered Movement Patterns by Janda (Liebenson, 1996)

Trunk flexion: synkinesis is good but abdominals is slightly weak

Shoulder abduction:

- Right side uses the upper scapula fixators
- Left side uses the upper scapula fixator

Hip abduction:

- Right side has good use of gluteus medius and minimus. Not much stability of trunk.
- Left side has good use of gluteus medius and minimus but the timing of activation is slightly off.

Hip extension:

- Right side is good. Pelvis is lifted after 5 degrees of extension.
- Left side is good. Pelvis is also lifted after 5 degrees of extension.

9. Neurological Examinations

Superficial (dermatome) sensation:

- Result: normal on both lower extremities

Deep (proprioception) sensation:

- Result: normal on both lower extremities

Deep tendon reflexes:

- Patella (L2-L4): normal (bilateral)
- Achilles (S1-S2): absent (bilateral)

Lasegue's sign:

- Result: positive on both sides. (There's tension of the muscle at 45° on both sides.)

Reverse Lasegue's sign:

- Result: negative

Rhomberg's sign:

- Result: positive

10. Soft Tissue Examination (Lewit, 2000)

The skin, sub-skin and fascias are restricted around the scar area (lumbar and lower thoracic areas) and also on the scar.

The skin, sub-skin and fascias are normal around the upper thoracic, cervical and scapula areas.

The Kibler's fold on the lumbar and lower thoracic area are restricted but the upper thoracic and cervical areas are normal.

The scar is slightly warmer than the skin around it.

It is hypertrophy.

The patient feels pain when pressing deeply on the scar.

The patient doesn't feel any pain when touching the scar superficially.

11. Anthropometry

Table 3 - Anthropometry of the Lower Extremities (Length in cm)

	Left	**Right**
Anatomical	77	76.5
Functional	83	82
Thigh	43	41.5
Mid-leg	35.5	35.5
Foot	22.5	23

Table 4 - Anthropometry of the Lower Extremities (Circumference in cm)

	Left	**Right**
Thigh (15 cm)	48	50
Thigh (10 cm)	44	44.5
Knee	35	35
Calf	34	34
Ankle	22	23
Foot	21	21

12. Range of Motion of the Lower Extremities (Kendall, 2005)

Table 5 - Range of Motion in Hip Joint (°)

	Left		**Right**	
	Active	**Passive**	**Active**	**Passive**
S	5-0-110	5-0-115	5-0-80	5-0-100
F (with knee extended)	20-0-15	25-0-20	20-0-15	25-0-20
R90	35-0-25	40-0-25	25-0-20	25-0-25

*Pain restricted the range of motion.

Table 6 - Range of Motion in Knee Joint (°)

	Left		**Right**	
	Active	**Passive**	**Active**	**Passive**
S	0-0-115	5-0-125	5-0-110	5-0-120

13. Muscle Palpation (Kendall, 2005)

Table 7 - Palpated Muscles

Muscle	**Left**			**Right**		
	Tone	**Pain**	**Trp**	**Tone**	**Pain**	**Trp**
Sternocleidomastoid	Normal	No	No	Normal	No	No
Subscapularis	Normal	No	No	Hypertonic	Yes	No
Levator Scapulae	Normal	No	No	Hypertonic	No	No
Trapezius (Upper part)	Normal	No	No	Hypertonic	No	No
Hamstrings	Normal	No	No	Normal	No	No
Tensor fasciae latae	Normal	No	No	Normal	No	No
Iliopsoas	Normal	No	No	Normal	No	No

Gluteus (maximus)	Normal	No	No	Normal	No	No
Gluteus (medius)	Normal	No	No	Normal	No	No
Quadratus lumborum	Normal	No	No	Normal	No	No
Quadriceps	Normal	No	No	Normal	No	No
Adductor brevis	Hypertonic	No	No	Normal	No	No
Piriformis	Hypertonic	Yes	No	Hypertonic	Yes	No
Gastrocnemius	Normal	Slight	No	Normal	No	No
Abdominals (rectus abdominis)	Normal tone but slightly painful					

*Levator scapulae, subscapularis and trapezius (upper part) were examined on 02.02.2012 since the patient was complaining about pain around the shoulders.

14. Muscle Length Test

Table 8 - Muscle Length Test of the Lower Extremity

Muscles	**Left**	**Right**
Iliopsoas	0	0
Quadriceps	0	0
Tensor fasciae latae	0	0
Piriformis	2	2
Adductor brevis	1	1
Hamstrings	0	0
Gastrocnemius	0	0
Soleus	0	0

15. Muscles Strength Test (Kendall, 2005)

Lower extremity:

Table 9 - Muscle Strength Test

Muscles	**Left**	**Right**
Gluteus maximus	4	4+
Gluteus medius	4-	4
Gluteus minimus	4-	4
Tensor fasciae latae	4	4
Iliopsoas	4+	4+
Hip adductors	4	4
Medial rotators	4+	4+
Lateral rotators	4+	4+
Quadriceps	4	4
Biceps femoris	4+	4+
Semitendinosis + semimembranosus	4+	4+
Gastrocnemius	5	5
Soleus	5	5
Abdominals	3	

16. Joint Play (Lewit, 2000) (Liebenson, 1996)

Table 10 - Joint Play of Lower the Extremities

Joint		**Left**	**Right**
Head of Fibula	**Dorsal direction**	Normal	Normal
	Ventral direction	Normal	Normal
Tibiofibular joint	**External rotation**	Normal	Normal
	Internal	Normal	Normal

	rotation		
Patella	**Lateral direction**	Restricted	Restricted
	Medial direction	Normal	Normal
	Cranial direction	Normal	Normal
	Caudal direction	Normal	Normal
Talocrural joint	**Dorsal direction**	Normal	Normal
Lisfranc	**Dorsal direction**	Normal	Normal
	Plantar direction	Normal	Normal
	Rotations	Normal	Normal
Dorsal fans		Normal	Normal
Plantar fans		Normal	Normal
Sacro-iliac joint	**Springing according to Stoddard**	Restricted	Restricted

*Unable to perform lumbar joint play examination due to pain.

17. Special Tests

Scale test

- Left: 22 kg
- Right: 39 kg
- Result: Positive. Patient's weight bearing is not physiological. She puts more weight on the right lower extremity.

Trendelenburg's test

- Left: there was compensation by rotation of the trunk
- Right: better than left side
- Result: The control of both sides is unstable but more controlled on the right side. Left side is slightly weaker than the right side.

2.5 Conclusion of examination

A 41-year-old female patient, 3 months after microdiscectomy on L5/S1, was admitted to the hospital after complaining about feeling pain in the lumbar area, or more specifically, on the scar, which also happens to sometimes radiate to both lower extremities at the level of the heel. The scale of the pain around the scar is 4-5 out of 10 from the VAS.

The postural examination shows that there are some muscle dysbalance especially with the presence of the flat feet and the anteversion of the pelvis. There are no visible arches on the feet. She compensates the pain by leaning her trunk forward. The patient's pelvis is higher on the left side. The position of her pelvis is also in anteversion. The piriformis are hypertonic bilaterally and the adductor brevis on the left side is hypertonic

The patient's breathing pattern has to be corrected because she uses her chest to breathe.

The Thomayer's distance shows that she has a stiff spine, but this could also be due to the pain she has on the lumbar area. To confirm this, the other spine distance tests show that there's restriction in all of the spinal segments.

The result of the Lasegue's sign being positive tells us that the disc herniation is present in the L5/S1 segment. As for the deep tendon reflex of the Achilles, it shows that the absence of this is due to the disc herniation as well.

The scar from the microdiscectomy is very hypertrophy and red in color. The patient feels a lot of pain when palpating the scar deeply. The soft tissue examination around the scar area is restricted on all levels (skin, sub-skin and fascias).

The range of motion for the hips shows that it is slightly less than physiological due to the pain.

The patient's muscle strength seems to be physiological. There are no weaknesses but the patient has very painful piriformis and abdominal muscles. The shortened muscles are the piriformis and the gastrocnemius, which is just slightly shortened.

The joint play in the lower extremities does not show any blockages, but only the patella in lateral direction and the sacro-iliac joint. The joint play examination for the lumbar was unable to perform due to the patient's pain.

The scale test reflects that she puts more loading to the right lower extremity.

2.6 Further examination proposal

These further examinations are to be done due to the patient's complaint of shoulder pain.

1. Altered movement patterns by Janda (Liebenson, 1996)

- Neck flexion
- Shoulder abduction
- Push-up

2. Muscle length test

- Pectoralis minor
- Pectoralis major
- Trapezius (middle part)

3. Muscle Strength test (Kendall, 2005)

- Pectoralis minor
- Pectoralis major
- Infraspinatus
- Supraspinatus
- Subscapularis
- Trapezius (upper + middle + lower)
- Levator scapulae
- Rhomboids
- Serratus anterior

4. Joint play by (Lewit, 2000)

- Shoulder joint
- Scapula
- Cervical spine
- Thoracic spine

5. Range of motion (Kendall, 2005)

- Shoulder joint

6. Palpation of muscles (Kendall, 2005)

- pectoralis minor
- Pectoralis major
- Infraspinatus
- Supraspinatus

2.7 Main goals of the therapy

The main goal of the therapy is to reduce the pain that the patient has been complaining about by reducing her pain from 4-5 on the VAS. She should also be able to sleep throughout the night without being disturbed by the pain. Other main goals are to decrease the hypertrophy of the scar, improve her posture as well as the breathing stereotype.

2.8 Short-term and long-term rehabilitation plan

Short-term plan

- Decrease pain on and around the scar area
- Correct the muscle imbalance
  - Lengthen the shortened muscles such as the piriformis and gastrocnemius
  - Relax the hypertonic muscles such as the piriformis, adductor brevis, subscapularis, levator scapulae and upper trapezius
- Correct the position of the posture by using SMS
- Correct the breathing stereotype by using DNS

- Improve mobility of the spine in all directions (flexion, extension, lateral flexion and rotations)

Long-term plan

- Maintain the exercises done in the short-term plan
- Improve the condition of the patient's flat feet by applying the small foot techniques from SMS and also strengthen the intrinsic foot muscles
- Senso-motoric training for dysbalance muscles and posture
- Maintain the muscle strength to prevent atrophy of muscle

2.9 Therapy proposal

- Decrease the pain around the scar area and also the whole back and lower extremities with a hot roll by Brugger (Liebenson, 1996), also to relax her back and lower extremities (this could vary from day to day depending on the patient's feeling)
- Soft tissue techniques (Lewit, 2000) on the scar and along the spine.
  - S-wave on the scar
  - C-wave on the scar
  - Deep pressure on the scar
  - Hold and release (stretching) on the scar
  - Kibler's fold in caudo-cranial direction along the spine
  - Traction of lumbar section
- PIR (Lewit, 2000) on piriformis
- DNS exercises (Kolar, 2012) for the breathing stereotype by training the deep stabilizing system of the spine in supine position
- Traction (Lewit, 2000) of the lumbar section for relaxation
- Manipulation (Lewit, 2000) of the sacro-iliac joint
- SMS by Janda (Liebenson, 1996) to correct the posture and also the flat feet
- Continuation of the exercises done in the therapy sessions for self-therapy

2.10 Therapy progress

2.10.1 Date: 1st February 2012 (afternoon)

Completed the examination in the afternoon. The therapy is done after the examination.

Goal of today's therapy unit:

- Reduce pain around the scar
- Scar therapy (soft tissue technique)
- Relaxation of lower extremities since she feels some tension on the posterior side of both lower extremities

Procedure:

- Hot roll on the posterior side of both lower extremities
- Hot roll on the scar and the whole back area
- Soft tissue techniques on the scar and along the spine
  - S-wave on the scar
  - C-wave on the scar
  - Deep pressure on the scar
  - Hold and release on the scar
  - Kibler's fold along the spine in caudo-cranial direction

Results:

- Patient feels less pain and more relaxed after the hot towel therapy
- She feels pain around 3-4 on the VAS, which decreased from when she first came in.

Self-therapy:

- No exercises were done today so there's no auto-therapy since there was limited amount of time.

2.10.2 Date: 2nd February 2012 (morning)

Subjective information:

- Patient feels pain on the scar
- Patient feels some slight tension around the shoulders and scapula on the right side

Goal of today's therapy unit:

- Reduce pain
- Scar therapy (soft tissue technique)
- Relax and stretch the muscle with increased tension
- Correct the breathing stereotype
- Relaxation of the shoulders and scapula since the patient feels some slight tension there. (Examination mentioned in the initial kinesiological examination.)

Procedure:

- Hot roll on the scar and the whole back area
- Soft tissue techniques on the scar and along the spine
  - S-wave on the scar
  - C-wave on the scar
  - Deep pressure on the scar
  - Hold and release on the scar
  - Kibler's fold along the spine
  - Stretching of the different segments in medio-lateral direction
- PIR of the piriformis on both sides
- DNS training of the deep stabilizing system of the spine by proportionally activating the diaphragm, pelvic floor muscles, abdominal walls and the spinal extensors in supine position. This is done 3 times with rests in between each time.

- Mobilization of the scapula against the thorax in clockwise and anti-clockwise directions for relaxation of the muscles around the scapula.

Results:

- Patient feels that the pain is decreased and more relaxed after the hot roll
- Patient feels that the shoulders and scapula are less tense after the hot roll application and the mobilization of the scapula against the thorax
- The piriformis on both sides are less tensed and increased in length after providing PIR on them
- The flexibility of the skin around the scar has improved after the soft tissue technique is done.

Self-therapy:

- DNS training of the deep stabilizing system of the spine in supine position as done in therapy today. This is to be done 3 times.

2.10.3 Date: 3rd February 2012 (morning)

Subjective information:

- Patient feels pain on and around the scar
- Patient feels pain around the right shoulder

Goal of today's therapy unit:

- Reduce pain around scar and also pain around the right shoulder
- Scar therapy (soft tissue technique)
- Relax and stretch the muscle with increased tension
- Correct the breathing stereotype with DNS training
- Improve mobility of the sacro-iliac joint

Procedure:

- Hot roll on the scar, the whole back area, and around the right shoulder
- Soft tissue techniques on the scar and the whole back
  - S-wave on the scar
  - C-wave on the scar
  - Deep pressure on the scar
  - Hold and release on the scar
  - Kibler's fold along the spine
  - Stretching of the different segments in medio-lateral direction
  - Traction of the lumbar section by fixating the lower thoracic with one hand and using the contralateral hand to stretch in caudal direction
- PIR of the piriformis on both sides
- DNS training of the deep stabilizing system of the spine by proportionally activating the diaphragm, pelvic floor muscles, abdominal walls and the spinal extensors in supine position. This is done 3 times with rests in between each time.
- Joint play of the sacroiliac joint according to Stoddard

Results:

- Patient feels that the pain is decreased and more relaxed after the hot roll therapy
- Patient feels pain on and around the scar when doing the traction of the lumbar section
- The piriformis on both sides are less tensed and increased in length after providing PIR on them
- The soft tissue technique improved the flexibility of the skin around the scar.

Self-therapy:

- DNS training of the deep stabilizing system of the spine in supine position as done in therapy today. This is to be done 3 times.

2.10.4 Date: 6th February 2012 (morning)

Subjective information:

- Patient feels pain on and around the scar
- Patient feels pain around the right shoulder and the anterior side of thighs where the fold of the hip is.
- Patient feels there's something missing on here back when she lies down on her back.

Examination before therapy:

- Subscapularis is hypertonic and is also painful when palpated
- Iliopsoas is hypertonic and is also painful when palpated

Goal of today's therapy unit:

- Reduce pain around the scar and also the subscapularis and iliopsoas muscles
- Scar therapy (soft tissue technique)
- Relax and stretch the muscle with increased tension
- Improving the mobility of the spine

Procedure:

- Hot roll on the scar, subscapularis, iliopsoas and the whole back
- Soft tissue techniques on the scar and the whole back
  - S-wave on the scar
  - C-wave on the scar
  - Deep pressure on the scar
  - Hold and release on the scar
  - Kibler's fold along the spine
  - Stretching of the different segments in medio-lateral direction
  - Traction of the lumbar section by fixating the lower thoracic with one hand and using the contralateral hand to stretch in caudal direction
- PIR of the piriformis on both sides
- Exercise to improve the mobility of the spine in flexion, extension and lateroflexion. Patient is asked to be on all fours, with the whole spine in line with

the head. For flexion, the patient is to slowly flex her head to her cervical spine to her thoracic and then the lumbar spine. She is told to breathe in and out 3 times and relax. For extension, the patient is to slowly extend her head back, extend her cervical spine to her thoracic and then the lumbar spine. She is told to breathe in and out 3 times and relax. For lateroflexion, the patient is to look at her right heel by maintaining the straight position of the spine and alternating by looking at her left heel. This is done 3 times.

Results:

- The pain around the scar has decreased after the application of the hot roll
- The mobility of the skin around the scar has increased after the soft tissue technique
- The pain around the right shoulder (subscapularis) is still the same
- The pain decreased slightly for the iliopsoas
- The piriformis on both sides are less tensed and increased in length after providing PIR on them
- The patient feels better and more relaxed after the therapy but slightly tired

Self-therapy:

- Training of spine mobility as she had done in the therapy session today. This is to be done 3 times
- DNS training of the deep stabilizing system of the spine in supine position as done in therapy from the past two days. This is to be done 3 times.

2.10.5 Date: 7th February 2012 (morning)

Subjective information:

- Patient feels pain on and around the scar
- Patient complains about having painful left buttocks.

- Patient feels pain on the coccyx when sitting (unable to examine her coccyx because she has her period.)

Goal of today's therapy unit:

- Reduce pain on and around the scar as well as the painful joint and muscles
- Scar therapy (soft tissue technique)
- Relax and stretch the muscle with increased tension
- Improve the spinal mobility

Procedure:

- Hot roll on the scar and the whole back area as well as the piriformis on the left side
- Soft tissue techniques on the scar and the whole back
  - S-wave on the scar
  - C-wave on the scar
  - Deep pressure on the scar
  - Hold and release on the scar
  - Kibler's fold along the spine
  - Stretching of the different segments in medio-lateral direction
  - Traction of the lumbar section by fixating the lower thoracic with one hand and using the contralateral hand to stretch in caudal direction
- PIR of the piriformis on both sides
- PIR of the gluteal maximus on both sides
- Exercise to improve the mobility of the spine in flexion, extension and lateroflexion. Patient is asked to be on all fours, with the whole spine in line with the head. For flexion, the patient is to slowly flex her head to her cervical spine to her thoracic and then the lumbar spine. She is told to breathe in and out 3 times and relax. For extension, the patient is to slowly extend her head back, extend her cervical spine to her thoracic and then the lumbar spine. She is told to breathe in and out 3 times and relax. For lateroflexion, the patient is to look at her right heel by maintaining the straight position of the spine and alternating by looking at her left heel. This is done 3 times.

Results:

- The piriformis on both sides are less tensed and increased in length after providing PIR on them although the pain is still present on the left side
- The spinal mobility increased, which is an improvement from yesterday.
- Patient feels less pain around the scar but the sacroiliac joint is still painful
- Patient feels slightly tired after the therapy session
- Patient's gait after this therapy session has changed. Her pelvis is shifted more to the left than before. This may be due to her compensating because of the pain of the left piriformis.

2.10.6 Date: 7th February 2012 (afternoon)

Patient has urinary tract infection so she has the inability to control her bladder. Therefore, the normal therapy could not be preceded so an alternative therapy is provided instead.

Goal of today's therapy unit:

- Educating the patient with SMS exercises to improve her posture and muscle dysbalance

Procedure:

- Preparation of the feet for SMS to increase the proprioception of the feet by
  - Mobilization of the joints of the feet
    - Interphalangeal (IP)1 and IP2 joints in dorsal, plantar and lateral
    - Metatarsophalangeal (MTP) joint in dorsal, plantar, lateral and rotation (only of the 1st MTP)
    - Metatarsal heads in dorsal and plantar
    - Dorsal and plantar fans of the metatarsal heads
    - Tarsometatarsal joints (Lisfranc) in dorsal, plantar and rotation

- Calcaneus traction manipulation in figure 8 direction (patient is in prone)
  - Massaging of the feet
  - Stimulating the whole feet up to the knees with sponge ball and spikey ball
- From SMS
  - Small foot training
  - Postural correction
  - Corrected stance
  - Corrected stance on one leg

Results:

- Patient feels slightly tired
- She had some cramps while providing the small foot training

Self-therapy:

- Training of spine mobility as she had done in the previous therapy sessions. This is to be done 3 times
- Dynamic neuromuscular stabilization training of the deep stabilizing system of the spine in supine position as done in therapy. This is to be done 3 times.
- Self-PIR of piriformis (taught)
- Small foot training, postural correction, corrected stance and corrected stance on one leg from SMS

2.11 Final kinesiologic examination

*Examination provided on 07.02.12 in the afternoon

1. Breathing Examination

The patient uses her chest to breathe (chest breathing). There is slight elevation of the shoulders when she inhales.

2. Postural Examination (Kendall, 2005)

Anterior view:

- Slight flat feet
- No arches visible
- Left knee is higher than right knee
- Right knee is more extended (slight hyperextension)
- Umbilicus faces more to the right side
- Pelvis rotate of the left side
- Shoulder of left side is longer and lower
- Shoulder of right side is shorter and higher

Posterior view:

- There is a slight external rotation of left feet
- Legs are aligned
- Gluteal line on left side is slightly higher
- Right knee is slightly lower than left knee
- Pelvis shifts to left side
- Triangle on left side is bigger than the right side
- Spine is shifted to the left side (mid-head and mid-heels are in line)
- Flat spine
- Visible scar on the lower lumbar area
- Left shoulder is more depressed than the right shoulder (which is elevated)
- Head is slightly laterally rotated to the right side

Lateral view:

- Cervical spine is in lordosis
- Thoracic spine is flat
- Lumbar spine is in slight lordosis
- Trunk of patient is still slightly leaning forward

Modified Posture:

Standing on tip toes: no problem

Standing on heels: slightly unstable

3. Pelvis

Crista: left is slightly higher

SIAS: left is higher

SIPS: aligned

Tilt: slight anteversion of pelvis (improved)

4. Gait Examination (Kendall, 2005)

- Very slight pelvic movement
- Arms in sync
- Narrow base
- Pelvis shifts to the left (could be from compensation of pain)
- Slightly stiff trunk
- No rolling of the feet
- Synkinesis of arms is good

Modified Gait

- Backwards (Gluteal): Normal. A lot of rotation of trunk and arms.

5. Spine Distances

- Stibor's distance: 6 cm
- Thomayer's distance: 45 cm
- Shober's distance: 12.5 cm
- Otto's distance: 3.5 cm
- Latero-flexion:
  - Left: 14 cm
  - Right: 18 cm
- Cepoj's distance: 1 cm
- Flesch de Forestier: 0 cm

6. Dynamic Test of the Spine

Flexion:

- Flat thoracic
- Lumbar is slightly restricted
- Pain is present when doing flexion in the lumbo-sacral region around the scar
- Range of motion is restricted

Extension:

- Patient feels slight pain when providing this movement around the scar
- Thoracic is restricted
- Range of motion is restricted in extension

Latero-flexion to the right side:

- Range of motion is restricted
- Arms are along side the trunk
- Thoracic is restricted
- Movement mostly on the lumbar spine

Latero-flexion to the left side:

- Range of motion is restricted, decreased compared to the right side
- Arms are along side the trunk
- Movement is mostly on the lumbar region
- Thoracic is restricted

7. Altered Movement Patterns by Janda (Liebenson, 1996)

Trunk flexion: synkinesis is good but abdominals is slightly weak

Shoulder abduction:

- Right side uses the upper scapula fixators
- Left side also uses the upper scapula fixator

Hip abduction:

- Right side has good use of gluteus medius and minimus. Not much stability of trunk.

- Left side has good use of gluteus medius and minimus but the synkinesis is slightly off.

  Hip extension:

- Right side is good. Pelvis is lifted after 5 degrees of extension.
- Left side is good. Pelvis is also lifted after 5 degrees of extension.

8. Basic Neurological Examinations

Superficial (dermatome) sensation:

- Result: both lower extremities are physiological

  Deep (proprioception) sensation:

- Result: both lower extremities are physiological

  Deep tendon reflexes:

- Patella (L2-L4): normal
- Achilles (S1-S2): absent

  Lasegue's sign:

- Result: positive on both sides. (There's tension of the muscle at 45° on both sides.)

  Reverse Lasegue's sign:

- Result: negative

  Rhomberg's sign:

- Result: positive

9. Soft Tissue Examination (Lewit, 2000)

The skin, sub-skin and fascias are restricted around the scar area (lumbar and lower thoracic areas) and also on the scar but better than first examined

The skin, sub-skin and fascias are normal around the upper thoracic, cervical and scapula areas.

Able to perform slight Kibler's fold on the lumbar and lower thoracic area but the upper thoracic and cervical areas are normal.

The scar is slightly warmer than the skin around it.

It is still in hypertrophy and red in color.

The patient feels pain when pressing deeply on the scar.

The patient doesn't feel any pain when touching the scar superficially.

10. Anthropometry

Table 11 - Anthropometry of the Lower Extremities (Length in cm)

	Left	Right
Anatomical	77	76.5
Functional	83	82
Thigh	43	41.5
Mid-leg	35.5	35.5
Foot	22.5	23

Table 12 - Anthropometry of Lower Extremities (Circumference in cm)

	Left	Right
Thigh (15 cm)	48	50
Thigh (10 cm)	44	44.5
Knee	35	35
Calf	34	34
Ankle	22	23
Foot	21	21

11. Range of Motion of the Lower Extremities (Kendall, 2005)

Table 13 - Range of Motion of Hip Joint (°)

	Left		Right	
	Active	**Passive**	**Active**	**Passive**
S	5-0-115	5-0-120	5-0-90	5-0-110
F (with knee extended)	20-0-15	25-0-20	20-0-15	25-0-20
R90	35-0-25	40-0-25	30-0-20	30-0-25

*Pain restricted the range of motion.

Table 14 - Range of Motion of Knee Joint (°)

	Left		**Right**	
	Active	**Passive**	**Active**	**Passive**
S	5-0-120	5-0-125	5-0-110	5-0-120

12. Muscle Palpation (Kendall, 2005)

Table 15 - Muscle Palpated

Muscle	Left			Right		
	Tone	Pain	Trp	Tone	Pain	Trp
Sternocleidomastoid	Normal	No	No	Normal	No	No
Subscapularis	Normal	No	No	Hypertonic	Yes	No
Levator Scapulae	Normal	No	No	Hypertonic	No	No
Trapezius (Upper part)	Normal	No	No	Hypertonic	No	No
Hamstrings	Normal	No	No	Normal	No	No
Tensor fascia latae	Normal	No	No	Normal	No	No
Iliopsoas	Normal	No	No	Normal	No	No
Gluteus (maximus)	Normal	No	No	Normal	No	No
Gluteus (medius)	Normal	No	No	Normal	No	No
Quadratus lumborum	Normal	No	No	Normal	No	No
Quadriceps	Normal	No	No	Normal	No	No
Adductor brevis	Hypertonic	No	No	Normal	No	No
Piriformis	Normal	Yes	No	Normal	Yes	No
Gastrocnemius	Normal	Slight	No	Normal	No	No

Abdominals (rectus abdominis)	Normal tone but slightly painful

13. Muscle Length Test

Table 16 - Muscle Length Test of the Lower Extremity

Muscles	**Left**	**Right**
Iliopsoas	0	0
Quadriceps	0	0
Tensor fasciae latae	0	0
Piriformis	1	1
Adductor brevis	1	1
Hamstrings	0	0
Gastrocnemius	0	0
Soleus	0	0

14. Muscles Strength Test (Kendall, 2005)

Table 17 - Muscle Strength Test

Muscles	**Left**	**Right**
Gluteus maximus	4	4+
Gluteus medius	4-	4
Gluteus minimus	4-	4
Tensor fasciae latae	4	4
Iliopsoas	4+	4+
Hip adductors	4	4
Medial rotators	4+	4+
Lateral rotators	4+	4+
Quadriceps	4	4
Biceps femoris	4+	4+

Semitendinosis + semimembranosus	4+	4+
Gastrocnemius	5	5
Soleus	5	5
Abdominals	3	

15. Joint Play (Lewit, 2000)

Table 18 - Joint Play of the Lower Extremities

Joint		**Left**	**Right**
Head of Fibula	**Dorsal direction**	Normal	Normal
	Ventral direction	Normal	Normal
Tibiofibular joint	**External rotation**	Normal	Normal
	Internal rotation	Normal	Normal
Patella	**Lateral direction**	Restricted	Restricted
	Medial direction	Normal	Normal
	Cranial direction	Normal	Normal
	Caudal direction	Normal	Normal
Talocrural joint	**Dorsal direction**	Normal	Normal
Lisfranc	**Dorsal direction**	Normal	Normal
	Plantar direction	Normal	Normal

	Rotations	Normal	Normal
Dorsal fans		Normal	Normal
Plantar fans		Normal	Normal
Sacro-iliac joint	**Springing according to Stoddard**	Restricted but improved	Restricted but improved

16. Special Tests

Scale test

- Left: 26 kg
- Right: 35 kg
- Result: Positive. Patient's weight bearing is still not physiological. She puts more weight on the right lower extremity.

Trendelenburg's test

- Left: there was compensation by rotation of the trunk
- Right: better than left side
- Result: The control of both sides is unstable but more controlled on the right side. Left side is slightly weaker than the right side.

2.12 Final Kinesiological Examination Conclusion

In conclusion of this final kinesiological examination, there are some slight improvements of all the aspects. The patient's flat feet improved slightly as well as her leaning forward of the trunk, which is leaning forward less than when first being examined. The patient's pelvis is still in anteversion but slightly improved. The pelvis shifts to the left side during the gait examination and there is still no rolling of the feet for the patient. The spine distances improved but they are still not physiological. The mobility of the skin, sub-skin and fascias,

overall, improved slightly for the lumbar and lower thoracic section. The muscles around the shoulders are still hypertonic and painful. As for the piriformis on both sides, there is still pain but it has decreased after using PIR. The piriformis decreased in tension and increased in length (less shortened). The joint play of the sacro-iliac joint is resolved. The weight bearing from the scale test still shows that the patient puts weight on her right lower extremity more than on her left lower extremity.

2.13 Effect of therapy

The therapy sessions have been slightly effective. After each therapy, the pain that the patient complains about have decreased. The patient's piriformis had decreased in pain on both sides. The length of the piriformis on both sides increased. The sacro-iliac joint had improved but is still slightly restricted. The patient doesn't lean forward as much as in the initial kinesiological examination. The soft tissue on the scar and around the scar improved. The tissues at the level of the skin, sub-skin and fascias are more mobile and less restricted after providing the soft tissue techniques along the whole spine.

Using the hot towel along with the soft tissue techniques have helped decrease the pain that the patient had first complained about. She is now able to sleep through the night without waking up due to the pain around the operated area. Although the pain has decreased, it is still present when she's walking. The pain has now decreased to 3 out of 10 on the VAS scale, which the patient is satisfied about.

3 Conclusion

This thesis comprises of research relating to the case study being a 41-year-old patient post-microdiscectomy at the level of L5/S1 and the case study itself. The anamnesis, initial kinesiological examination, therapy done on the patient, and the effects of therapy are included in this thesis to show the progress of therapy being done within 7 days in full detail.

The case study is on a patient post-microdiscectomy, therefore, the general part has to contain vital information on the disc herniation that the patient had acquired before being operated. This consists of the anatomy of the whole spine and its function and the intervertebral disc. Since the patient's level of disc herniation is at the level of L5/S1, the anatomy of the lumbar spine as well as the sacrum has to be included in the general part. The muscles and ligaments of the lumbar spine and the different innervations through the lumbar segments and the mechanism of disc bulging are mentioned. The most important segment in the general part is the disc herniation and the surgical procedure of microdiscectomy itself. This comprises of the classification, indication, contraindication and diagnosis of disc herniation. Additionally, there is also information on how the patient could care for him/herself after the surgical procedure microdiscectomy. The results and the complications that may arise post-op are built into this segment.

The special part is the case study itself. This part includes the anamnesis, initial kinesiological examination, therapy proposal, short and long-term therapy plans, detailed day-to-day therapy sessions, final kinesiological examination and the effects of therapy. The therapy sessions were done within 7 days.

The patient's main complaint is the pain on and around the operated area, L5/S1, which sometimes radiates to both heels. The pain on the VAS is 4-5 out of 10. The kinesiological examination shows that there's some muscle imbalance and an antalgic position of the hip, which translates to the forward leaning of the trunk. The neurological signs that are positive show that disc herniation is present on the level of L5/S1. The most noticeable problem was the scarring after the operation; therefore, the soft tissues around the area will most likely be restricted.

The therapeutic methods used on the day-to-day therapy for 6 sessions were mainly hot rolls, soft tissue techniques, PIR, joint mobilization, DNS, and SMS.

There were slight improvements after the therapy but the most significant one was the reduction of the pain after each therapy session, since that was the patient's main complaint.

As a result, the therapeutic methods used were effective, although the results could be more effective over a longer period of time. Since the therapy sessions were done over just 7 days, additional therapy sessions will give clearer and more noticeable improvements of the patient's problems, if given more time. If the patient continues with the proposed self-therapy in her last session, her prognosis would be good and she would be able to continue living her life normally while she has to be very careful when loading her back to prevent herself from worsening the condition of the disc herniation she has.

4 Bibliography (List of literature)

1. Unknown. (2013). *Herniated Disc - Lumbar*. Retrieved April 18, 2013, from UF|Department of Neurosurgery: http://neurosurgery.ufl.edu/patient-care/diseases-conditions/herniated-disc-lumbar/
2. Unknown. (2010). *Myotomes*. Retrieved April 18, 2013, from Anatomy and Physiology MCQS: http://www.cambridgequestions.co.uk/diagrams/Myotomes%20(basic).png
3. Zieve, D., & Ma, B. (2009, September 17). *Diseases & Conditions*. Retrieved April 18, 2013, from AllRefer.com: http://health.allrefer.com/health/scoliosis-spinal-curves.html
4. Wiesel, S. W. (2011). *Operative Techniques in Orthopaedic Surgery* (Vol. 4). Philadelphia: Lippincott Williams & Wilkins.
5. Abitbol, J.-J., Dawson, E., & Jr., R. H. (2013, January 25). *Lumbar Herniated Disc.* Retrieved April 18, 2013, from Spine Universe: http://www.spineuniverse.com/conditions/herniated-disc/lumbar-herniated-disc
6. Bogduk, N. (2005). Clinical Anatomy of the Lumbar Spine and Sacrum. China: Elsevier Limited.
7. Cherms, C. (2012, August 30). *Vertebral Column and Vertebrae Flash Cards*. Retrieved April 18, 2013, from StudyBlue: http://www.studyblue.com/notes/note/n/vertebral-column-and-vertebrae-flash-cards/deck/3418997
8. Fox, S. I. (2006). *Human Physiology.* New York: McGraw-Hill.
9. Gregory, D., Seto, C., Wortley, G., & Shugart, C. (2008, October 1). *Acute Lumbar Disk Pain: Navigating Evaluation and Treatment Choices*. Retrieved April 18, 2013, from AAFP: http://www.aafp.org/afp/2008/1001/p835.html
10. Haher, T., & Merola, A. (2003). *Surgical Techniques for the Spine.* New York: Thieme Medical Publishers.
11. Hanscom, D. (2012). *Back in Control.* Retrieved April 18, 2013, from Taking Charge of Your Chronic Pain Treatment: http://www.drdavidhanscom.com/wp-content/uploads/2011/11/Microdisc-Patientcopy.pdf
12. Kapandji, I. A. (2004). The Physiology of the Joints: The Trunk and the Vertebral Column (Vol. 3). China: Elsevier Limited.

13. Kendall, F. P. (2005). *Muscles: Testing and Function, with Posture and Pain.* Philadelphia: Lippincott Williams & Wilkins.
14. Kolar, P. (2012, April). Introduction to DNS: A Developmental Kinesiology Model. Prague, Czech Republic: 2nd Faculty of Medicine, Charles University, Motol Hospital.
15. Lewit, K. (2000). *Manipulative Therapy in Rehabilitation of the Locomotor System.* Great Britain: Reed Educational and Professional Publishing Ltd.
16. Liebenson, C. (1996). *Rehabilitation of the Spine: A Practitioner's Manual.* Baltimore: Lippincott Williams & Wilkins.
17. Lippert, L. S. (2006). *Clinical Kinesiology and Anatomy.* Philadelphia: F. A. Davis Company.
18. Netter, F. (2006). *Atlas of Human Anatomy.* Philadelphia: Saunders.
19. McFarland, C. M. (2007, August 17). *Physical Therapy After Minimally Invasive Back Surgery*. Retrieved August 29, 2013, from Spine-Health: http://www.spine-health.com/wellness/exercise/physical-therapy-after-minimally-invasive-back-surgery
20. Postacchini, F. (1999). *Lumbar Disc Herniation.* Ljubljana: Springer-Verlag/Wien.
21. Reid, M. (2012, October 7). *Gross Anatomy Muscles*. Retrieved April 18, 2013, from StudyBlue: http://www.studyblue.com/notes/note/n/gross-anatomy-muscles-/deck/3961082
22. Tortora, G., & Derrickson, B. (2009). Principles of Anatomy and Physiology: Organization, Support and Movement, and Control Systems of the Human Body (Vol. 1). Asia: John Wiley & Sons.

5 Supplement (Annexes)

Ethics board approval and patient's consent form are in the following pages.