CHARLES UNIVERSITY IN PRAGUE

Faculty of physical education and sport

Department of Physiotherapy

CASE STUDY OF PATIENT WITH ANTERIOR CRUCIATE LIGAMENT TEAR TWO WEEKS BEFORE SURGERY

Bachelor Thesis

Prague 2013

Author: Grace Sarah Chulu

Supervisor: Mgr. K. Marsakova

ABSTRACT

Title: Anterior Cruciate Ligament tear two weeks before surgery

Objective: The aim of this Bachelor Thesis research is based on understanding the functional features of the knee joint, the mechanism of tear of the anterior cruciate ligament and focusing on the main principles and procedures of the therapy before reconstruction.

Methods: the study lasted for a period of two weeks. The rehabilitation plan which was executed during the two weeks for five sessions went accordingly. PIR as well as sesnsomotoric and proprioreceptive stimulation exercises were performed on each day, including mobilization of restricted joints and strengthening and stretching exercises for weak and short muscles respectively.

Results: after the five therapeutic sessions, I took a final kinesiological examination in order to compare the results with the initial examination and the results showed an increase in the range of motion of the knee in both extension and flexion.

KEY WORDS: Anterior Cruciate Ligament, Range of Motion, Quadriceps, Hamstrings, Sensormortoric training, Post Isometric Relaxation

DECLARATION

I declare that this Bachelor Thesis is based on my own individual work during my two weeks of clinical practice at C.L.P.A (Centrum léčby pohybového aparátu) that was done between the 21st of January 2013 and the 1st of February 2013. The information used in the writing of this Bachelor Thesis was sourced from the literature provided at the end of the project.

.....

Grace Sarah Chulu

DEDICATION

This Bachelor Thesis is dedicated to my family, most especially my parents who have been a source of strength, encouragement and support throughout my years of study and through my toughest times in Czech Republic.

To the lecturers of Charles University, Faculty of Sport and Physical Education, my completion of my studies would not have been possible without the help from each one of you.

Lastly to all my dear friends, the list is endless, your support and friendship made this a much easier journey and to you all, I say thank you.

ACKNOWLDGEMENTS

I would like to thank my supervisor Mgr. Katerina Marsakova for the advice and help she gave during the preparation of my Bachelor Thesis. I would also like to thank the patient I worked with for her cooperation and patience during the two weeks of my practice that I worked with her. Lastly, I thank my supervisor Dr. Edwin Mahr who assisted me during my clinical work placement at C.L.P.A (Centrum léčby pohybového aparátu)

Table of Contents

1. Introduction (preface)

1. INTRODUCTION

This Bachelor Thesis research is based on the rupture of the anterior cruciate ligament of the knee joint. It will involve an overview of the knee joint, the biomechanical principles of the knee joint and the anterior cruciate ligament in particular, mechanisms of ruptures on the anterior cruciate ligament, the clinical examination of the knee joint, symptoms of injuries of the anterior cruciate ligament , surgical and conservative ways of treatment. All these will be discussed in the theoretical part of the thesis.

The practical part which is the case study will include the therapeutic unit applied on the patient and the progress of the therapy. This will include the following:

i. Present state of the patient
ii. Anamnsesis
iii. Previous rehabilitation
iv. Initial kinesiological examination
v. Conclusion of the initial examination
vi. Therapy proposal
vii. Short and long term rehabilitation plan
viii. Day to day therapy applied (for five days) and the subjective and objective results for each day
ix. Final kinesiological examination
x. Conclusion of the kinesiological examination and progress of the therapy applied

The main aim of the thesis is for the reader to get an overview on the subject of the anterior cruciate ligament rupture from a theoretical and practical point of view.

2. General part

2.1 ANATOMICAL OVERVIEW OF THE KNEE JOINT

2.1.1 BONES OF THE KNEE JOINT

The knee joint, which is the largest joint in the body, is made up of three bones which are the femur, the tibia and the patella. It is primarily a hinge joint and is very complex. Despite being the largest joint in the body, it is also one of the most susceptible when it comes to injuries.

The three bones that make up the knee joint are the femur from above, the tibia below and the patella which is located in front of the femoral condyles. The fibula which is located lateral to the tibia does not belong to the articulations that make up the knee joint and is not directly involved in weight transmission.

The longest and strongest bone in the human body is the femur. The proximal part forms the head and articulates with the acetabulum while the distal part is wider and forms a double condyle that articulates with the tibia and the patella. It articulates with the distal, lateral and medial femoral condyles. The patella lies anterior to the femoral condyles in the region of the intercondylar fossa (trochlear groove) and can easily be palpated and moved cranially, caudally, laterally and medially.

The tibia is distal to the femur and medial to the fibula. The proximal end consists of medial and lateral condyles, an intercondylar area and the tibial tuberosity that articulates with the medial and lateral condyles of the femur while the distal part articulates with the ankle. The distal and proximal ends articulate with the fibula.

The patella which is the largest sesamoid bone in the human body is flat, proximally curved and distally tapered. However the shape of the patella may vary from individual to individual. The posterior part of the patella articulates with the femur while the apex sits proximal to the line of the knee joint. The articular surfaces

of the patella differ according to the angle of flexion due to the sliding of the patella on the trochlear groove. The quadriceps femoris tendon surrounds on holds the patella within. The main function of the of the patella is that it increases the mechanical advantage of the quadriceps femoris muscle and also protects the knee joint. (16,18,20)

2.1.2 JOINT CAPSULE AND THE SYNOVIAL MEMBRANE OF THE KNEE JOINT

All the articulating bodies that form the knee joint are covered by a joint capsule. The articular capsule consists of a thin but strong fibrous membrane which is strengthened in almost its entire extent by bands inseparably connected to it. It has an external fibrous layer and an internal synovial membrane. The fibrous layer is thin apart from the thick parts that make up the intrinsic ligaments of the knee. On the posterior aspect, it encloses the condyles and the intercondylar fossa. Distally it attaches to the margin of the superior articular surface of the tibia.

Since there is no capsule in front of the joint, it causes the membrane to pouch upward beneath the quadriceps tendon therefore forming the spurapatella bursa. The capsule is strengthened by the m.vastus lateralis and m.vastus medalis on either side while the posterior side of the capsule is strengthened by the an extension of the m.semimebranosus muscle called the popliteal ligament.

The synovial membrane lines all the surfaces of the articular cavity that are not covered with the articular cartilage. It lines the internal surface of the fibrous layer laterally and medially and becomes separated from the fibrous layer centrally. It is attached to the peripheral of the articular cartilage which covers the femoral and tibial condyles, the posterior surface of the patella and the popliteal surface of the femur.

All joints in the human body that are moveable have some synovial fluid in them, the synovial fluid originates from the plasma that is filtered by the capillary net and diffuses into the knee along the hyaluronic acid that is locally synthesized. The

synovial fluid transports nutrients, assists in the joints defense and lubricates the joint. (17,19)

2.1.3 LIGAMENTS OF THE KNEE JOINT (8,16,18)

The ligaments of the knee are responsible for keeping the stability of the knee. The surround the knee and support the joint passively since they are loaded only in tension against abnormal motion. The location of each of the ligaments determines the direction in which it is capable of resisting the dislocation of the knee. This is further discussed under the biomechanics of the knee.

The ligaments are divided into two; the extracapsular ligaments and the intra-articular ligaments. The extracapsular ligaments are the patellar ligament, medial collateral ligament (MCL), the lateral collateral ligament (LCL), the oblique popliteal ligament and the arcuate popliteal ligament. The intra-articluar ligaments consist of the anterior cruciate ligament (ACL), the posterior cruciate ligament (PCL) and the posterior meniscofemoral ligament.

2.1.3.1 EXTRA-CAPSULAR LIGAMENTS

The patella ligament is a strong and thick fibrous band that strengthens the anterior surface of the knee joint. It is an anterior ligament of the knee which is part of the quadriceps tendon distally and attaches to the tibial tuberosity from the apex of the patella. In contribution to the patella ligament are the m.vastus medialis and the m.vastus lateralis which run medially and laterally through the medial and lateral retinacula which make up the joint capsule of the knee on either side of the patella as stated earlier. The retinacula also maintain the alignment of the patella relative to the patella surface of the femur.

The MCL, also known as the tibial collateral ligament is flattened into a band with two layers- deep and superficial. The deeper layer is attached to the medial meniscus while the superficial layer is attached to the tibia. These layers contribute to the joint capsule. The MCL, plays a significant role in stabilizing the knee when in

flexion against any valgus force (a force tending to force the joint open on the inner aspect).

The lateral collateral ligament also known as the fibular collateral ligament is a pencil like cord and stretches from the lateral epicondyle of the femur to the lateral surface of the fibula head. It does not form part of the capsule because the popliteal tendon passes under it and separates it from the capsule. The lateral collateral ligament also splits the tendon of the m.biceps femoris into two parts.

The oblique popliteal ligament is broad and flat and extends from the intercondylar fossa of the femur to the head of the tibia. This ligament strengthens the posterior surface of the joint together with the tendon of the semimembranosus muscle.

The arcuate popliteal ligament has the function of strengthening the lower lateral part of the posterior surface of the joint and extends from the lateral condyle of the femur to the styloid process of the head of the fibula

2.1.3.2 INTRACAPSULAR LIGAMENTS

The intraccapsular ligaments are named according to their origin relative to the intercondylar area of the tibia. The main role of the intracapsular ligaments is to prevent the tibia from sliding anteriorly or posteriorly off the femur when a force is applied to the joint. The two intracapsular ligaments are the anterior cruciate ligament (ACL) and the posterior cruciate ligament (PCL).

The ACL is a well vascularised ligament that is surrounded by synovium and contains proprioreceptive nerve endings. The ACL extends from the posterior and lateral point, anterior to the intercondylar area of the tibia to the posterior part of the medial surface of the lateral condyle of the femur. It also has the function of limiting hyperextension of the knee joint and prevents the tibia from sliding anteriorly off the femur. Tear of this ligament accounts for approximately 70 percent of knee injuries

The PCL prevents the posterior movement of the tibia in relation to the femur when the knee is flexed. The PCL plays a very important role especially when going

up and down stairs. It extension is anterior and medial from a depression on the posterior intercondylar area of the tibia and lateral meniscus to the anterior part of the lateral surface of the medial condyle of the femur.

The structure of the knee allows bearing of tremendous loads as well as the mobility required for locomotor activities as discussed in the biomechanics of the knee later in the thesis. The stability of the knee largely depends in the surrounding muscles which are the quadriceps and the hamstrings and the four main ligaments of the knee which are the medial collateral ligament, the lateral collateral ligament, the anterior cruciate ligament and the posterior cruciate ligament. These four ligaments play a vital role in keeping the knee stable and are discussed in detail later in the thesis.

Although the main movements of the knee joint are flexion and extension, it also allows for the femur to rotate on tibia. This rotation contributes to what is termed as the "locking" of the knee when it is in full extension more especially when in standing position. The movements of the knee joint will be discussed further in the chapter.

2.1.4 THE MENISCI

Integral to the knee's function is the meniscus. These are two half-moon, wedge shaped pieces of cartilage. There is the medial meniscus and the lateral meniscus. These act as a lubricant and elastic buffer and distribute forces evenly between the femur and the tibia. The peripheral borders of the menisci are thick and are attached to the capsule while the inner borders are thin and are unattached.

The anterior and posterior meniscule horns are firmly attached to the bone via insertional ligaments. The anterior insertional ligament of the medial meniscus inserts to the tibial plateau at the anterior intercondylar fossa. The posterior insertional ligament of the medial meniscus attaches to the posterior intercondylar fossa of the tibia between the posterior enthesis of the lateral meniscus and the tibial enthesis of the posterior cruciate ligament. The anterior insertional ligament of the lateral meniscus attaches to the anterior intercondylar fossa of the tibia, anterior to

the lateral intercondylar eminence right behind the tibial enthesis of the anterior cruciate ligament. Some of its fibers blend with the ACL. The posterior insertional ligament of the lateral meniscus attaches to the tibia posterior to the lateral intercondylar eminence to the posterior enthesis of the medial meniscus.

The medial meniscus is less moveable than the lateral meniscus because it is firmly attached to the TCL which is a slender fibrous band that joins the anterior edges of the menisci thus allowing them to move together during knee movements.

The menisci bear 40 to 50 percent of the total load that is transmitted across the joint in extension and 85 percent of the compressive load is transmitted through the menisci at 90 degrees of flexion. They meniscus is classified as a secondary stabilizer and help in compensating for congruence of the bones. They also appear to be involved in rotation by moving on the tibia. (8,16,18)

2.2 PHYSIOLOGY OF LIGAMENTS

2.2.1 STRUCTURE AND COMPOSITION OF LIGAMENTS

In order to better understand mechanisms of injury of the knee joint when it come to the ligaments tear, a brief overview of the structure and composition of the ligaments is discussed. The ligaments are basically dense connective tissue that are largely comprised of collagen which is a fibrous protein consisting of about one third of the total protein in our bodies. Collagen itself consists of a large part of the organic matrix of bone and cartilage and therefore has a unique mechanical supportive function. The mechanical stability of collagen gives the ligaments the characteristics of strength and stability. Ligaments also contain a protein known as elastin. (8,17)

2.2.2 STRUCTURE OF THE ACL

The ACL consists of two bundles which are the anteromedial bundle (AM) and the posterolateral bundle (PL). The anatomy of the ACL as discussed earlier allows for either one or both bundles to be loaded in response to external loads

applied to the knee throughout the range of motion. Thus the primary function of the bundles is to resist tension.

2.3 KINSEIOLOGY OF THE KNEE JOINT

2.3.1 MOVEMENTS OF THE KNEE JOINT

The main movements of the knee joint are flexion and extension and in addition to this, there is a rotational component. This motion is an accessory motion that accompanies flexion and extension. The convex femoral condyles move on the concave tibial condyles or vise versa depending on whether the activity is an open or closed chain activity. The posterior glide of the medial condyle of the tibia during the last few degrees or weight bearing extension cause the femur to rotate medially on the tibia as seen below. The same rotational movement is noted during non weight bearing extension where the tibia rotates laterally on the femur. The term *screw-home mechanism* is used describe the last few degrees of the locking motion of the knee while it goes into extension. During flexion, the knee is unlocked when the femur rotates laterally on the tibia. The reason why we do not refer to the knee as a true hinge joint is because of this rotational movement that occurs.

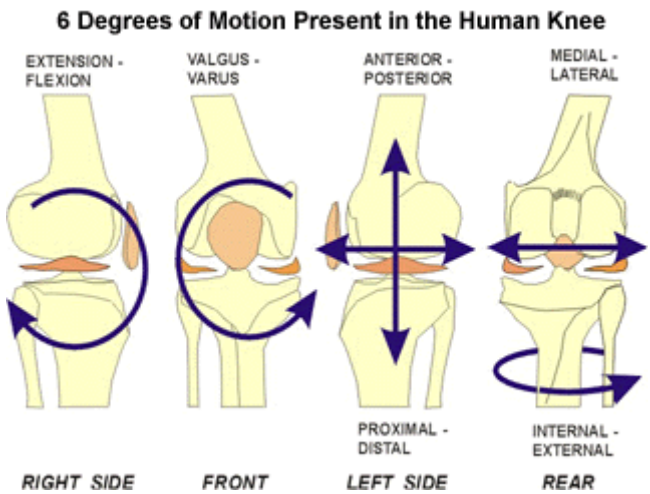

Figure 1: Movements of the knee joint (23)

2.3.2 MUCLES ACTING ON THE KNEE JOINT (13,17)

Anterior muscles

The anterior muscles include the quadriceps muscles which are divided into four muscles that cross the anterior surface of the knee. Below is a table of these muscles including their origin, insertion, action and innervation.

Muscle	Origin	Insertion	Action	Nerve
Rectus femoris	Anterior inferior liliac spine	Tibial tuberosity through patellar tendon	Knee extension, hip flexion	Femoral nerve (L2, L3, L4)
Vastus lateralis	Lateral lip of linea aspera	Tibial tuberosity through patellar tendon	Extends knee	Femoral nerve (L2, L3, L4)
Vastus medialis	Medial lip of linea aspera	Tibial tuberosity through oatellar tendon	Extends knee	Femoral nerve (L2, L3, L4)
Vastus intermedialis	Shaft of femur	Tibial tuberosity through patellar tendon	Extends knee	Femoral nerve (L2, L3, L4)

Table 1: Anterior muscles acting on the knee joint (17)

Posterior muscles

The posterior muscles that act on the knee joint are called the hamstrings and are divided into three; the semitendinosus, semimebranosus and the biceps femoris.

Muscle	Origin	Insertion	Action	Innervation
Semitendinosus	Ischial tuberosity	Medial condyle of tibia	Flexes knee, extends hip	Tibial sciatic
Semimembranosus	Ischial tuberpsity	Medial surface of tibia	Flexes knee, extends hip	Tibial sciatic
Biceps femoris	Long head: ischial tuberosity Short head: linea aspera	Head of fibula	Flexes knee, extends hip	Long head: tibial sciatic Short head: peroneal sciatic
Popliteus	Lateral condyle of femur	Tibia	Flexes knee, medially rotates tibia, laterally rotates femur	tibial

Table 2: Posterior muscles acting on the knee joint (17)

Medial muscle

Gracilis	Body of pubis	Medial surface of tibia	Adducts hip, flexes knee	obturator

Table 3: Medial muscles acting on the knee joint (17)

2.3.3 BLOOD SUPPLY OF THE KNEE

Blood supply to the knee comes from the popliteal artery which stems from the femoral artery. From the popliteal artery are four branches of supply; the medial and lateral superior genicular and the medial and lateral inferior genicular arteries which all supply the knee joint. (16)

2.3.4 INNERVATION OF THE KNEE JOINT

The knee is innervated by the branches of the obturator, femoral and sciatic nerves. We have anterior and posterior innervations groups:

i. The posterior group; posterior articulate the nerve of the tibial nerve which crosses the posterior capsule at the level of the oblique popliteal ligament. The posterior groups also supplies the capsule and the meniscal synovial junction, the cruciate ligaments and the infrapatella fat pad.
ii. Anterior group; they are the femoral nerve, the common peroneal nerve and the saphenous nerves. (3,16)

2.3.5 BURSAE OF THE KNEE JOINT

Bursae of the knee are basically fluid sacs and synovial pockets that surround and sometimes communicate with the joint cavity. There are many bursae that surround the knee joint and their arrangement is complex and variable. Below is the list of bursae of the knee and their location.

<u>Anterior bursae</u>

i. One large one interposed between the patella and the skin
ii. A small one between the upper part of the tibia and the patella ligament
iii. One between the lower part of the tuberosity of the tibia and the skin
iv. The last between the anterior surface of the lower part of thr femur and the deep surface of the quadriceps femoris which communicates with the knee joint

<u>Lateral bursae</u>

i. One between the lateral head of the gastrocnemius and the capsule
ii. Between the fibular collateral ligament and the tendon of the biceps
iii. Between the fibular collateral ligament and the tendon of the popliteus
iv. The last between the tendon of the popliteus and the lateral condyle of the femur and is usually an extension from the synovial membrane of the joint

Medial bursae

i. Between the medial head of the gastrocnemius and the capsule. It sends a prolongation between the tendon of the medial head of the gastrocnemius and the tendon of the semimembranosus and foten communicates with the joint
ii. one superficial to the tibial collateral ligament , between it and the tendons of the Sartorius, gracilis and semitendinosus
iii. one deep to the tibial collateral ligament between it and the tendon of the semimembranosus
iv. one between the tendon of the semimembranosus and the head of the tibis
v. occasionally there is a bursae between the tendons of the semimembranosus and semitendinosus (3,16,18)

2.4 BIOMECHANICS OF THE KNEE

The biomechanics of the knee describes the function of the knee joint in terms of its mechanical components. The information provided concerning the biomechanics of the knee joint is vital in helping us understand the behavior of the joint when some disorder exists within the knee joint. It is also very important especially as physiotherapists to understand the mechanical functioning of the knee joint when it comes to rehabilitating patients with disorders of the knee after trauma or after surgery. Despite the fact that some articles have tried to describe the biomechanics of the knee joint in terms of a set of external measurements that allow prediction of the loads carried in the knee joint and the influences of different kinds of ligaments, muscles and tendons as a unit, the kinds of methods used in the analysis are unreliable. This is simply due to the complexity and overlapping of the function of ligamentous and musculotendonous units around the knee joint and the inadequacy of testing the various functions on cadaver's knees.

The knee, as stated previously is made up of three basic types of structures:

1. Ligaments: passive elastic fibers that can only be loaded in tension
2. Musculotendinous units: active elastic structures that can only under tension
3. Bone: none elastic and serves to take the compressive loads in the joint

The relative positions of the bones in a loaded joint are partially controlled by the shape of the joint surfaces. During weight bearing, the tibial spine inserts into the femoral intercondylar notch thus creating an effective stabilizer. The shape of the spine provides self centering (laterally) during the transition from non-weight bearing to full weight bearing. On the other hand, the shape of the femorotibial joint does not provide such great stability in the anterior-posterior directions. Normally, the femur should slide off the tibia either anteriorly or posteriorly if there is no bony structure hindering it from doing so. Although there is no bony structure that prevents the femur from sliding posteriorly off the tibia, the patella serves effectively as bearing structure that prevents the femur from sliding anteriorly off the tibia. In these conditions, the patella can be considered as part of the tibia because they are connected by an elastic tendon.

The elastic tendinous connection of the patella to the tibia together with the active qudriceps femoris mechanism proximal to the tibia serves as a shock absorber in buffering the patellofemoral joint against high deceleration forces. If other joints in the body had to be subjected to these shock loadings during rapid change in acceleration, they would be constrained by a rigid bone to bone contact. Such joints include the hip joint with a ball and socket construction or the spinal column which consists of several vertebral bodies aligned one on top of the other. These types of joints are protected by the correct action of the knee joint in allowing these high shock loads be absorbed by the quadriceps femoris mechanism and the patellar.

The ligaments of the knee as mentioned earlier are also responsible for keeping the relative position of the femur and the tibia within bounds so that the contact between the two surfaces occur at the appropriate places from non weight bearing to weight bearing stage. When the tibia is suspended below the femur, the forces that are applied to the femur are resolved into vertical and horizontal components. The horizontal components being in direct opposition to the vertical components serve as a self centering mechanism to keep the femur and the tibia in a good relative position to one another. The ligaments also serve as a passive load-carrying structures to back up the active load-carrying elastic structures which are the musclutendinous units.

The muscles of the thigh control rotation and deceleration as well as function as primary movers. There are two synergistic muscle groups which are the quadriceps femoris and the hamstrings. The quadriceps femoris muscle is responsible for extension

of the knee and deceleration of the forward motion of the femur on the tibia. The hamstrings muscles act as flexors of the knee and have some rotational control of the femur on the tibia. (9,19)

2.4.1 PATELLOFEMORAL JOINT FORCES

This is a unique joint because it protects the body's other joints by the way it distributes shock loading in the knee. Compressive forces from the femur are absorbed by the patellar. These forces are then transformed into tension forces in the quadriceps femoris and the patellar tendons instead if being transferred directly as a compressive load and because the quadriceps femoris muscle is really powerful, it acts as a retainer for the femur. During vigorous activity, very high deceleration forces are imposed on the body.

2.4.2 FEMEROTIBIAL JOINT FORCES

The femur and the tibia carry compressive loads across the knee joint and can also carry a tensile load because they are a solid structure. The relative load carried on the tibia as opposed to the loas carried by the quadriceps femoris muscles and by the patellofemoral joint is determined by the shapes of the surfaces of contact and the angle of the force applied to the tibia by the femur relative to the long axis of the tibia.

The anterior cruciate ligament is angled in the direction to help keep the femur from sliding back off the tibia as stated earlier. the menisci and the meniscotibial ligaments also help in preventing this movement. The posterior horns of the menisci curl around the femur therefore providing a backstop and the menisci are held tightly by the meniscotibial ligaments. Due to the fact the collateral ligaments are attached at a distance thus making them long, and also because of their elasticity, they are not so effective in keeping the femur on the tibial surface. So the two primary structures that keep the femur on the tibial surface are the anterior cruciate ligaments and the mensicotibial ligaments through the menisci.

If any of the two structures either the anterior cruciate ligament or the menisci are no so effective in their role, or if any one of the structures is playing the role on its own then the remaining structure will eventually deteriorate. So in order to minimise the

stress to the meniscotibial ligaments, the anetror cruciate ligament or the menisci, the patient must keep the tibia in a position in which the femur slides anteriorly on the tibia.

Meanwhile, the posterior cruciate ligament is angled in a way that keeps the femur from sliding too far anteriorly off the tibia. However, the main force for keeping the femur on the tibia anteriorly is the patella and the quadriceps femoris mechanism. (9,10,19)

2.5 MECHANISMS OF INJURY

The ACL is goes through the knee in an oblique manner, therefore allowing a part of its structure to resist the extremes of almost all the movements of the knee. Despite the fact that the spatial orientation is ideal for providing a wide range of stability, it also renders the ligament vulnerable to injury from many forms of extreme movements of the knee. One of the most common injuries is one that involves a high velocity stretch to the ligament that is already under tension thus leading to the rupture of the ligament when its tensile stress has exceeded the physiologic strength.

ACL injury may lead to instability of the knee and stressful kinematics. This may also lead to deterioration of other structures and may leave the knee vulnerable to injuries. Since the ligament is not able to heal on its own, a surgical approach is usually recommended. The type of surgical approaches is described further in the chapter. Studies show that approximately 70 percent of sport ACL injuries are non contact or minimal contact injuries. The non contact injuries may occur from a jump, a quick and forceful deceleration, cutting or pivoting over a single planted lower limb. These mechanisms of injury are usually very quick and are unpredictable thus the exact position and direction of the forces applied to the knee during the injury are not always certain. (2,17,21)

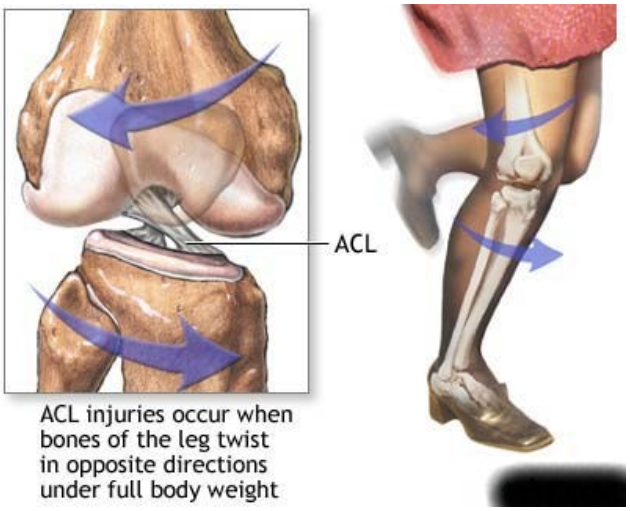

Figure 2: Mechanism of ACL injury(24)

2.6 CLINICAL EXAMINATION OF THE KNEE LIGAMENTS (2,5,10)

2.6.1 HISTORY TAKING

Just like any other clinical examination one would do, it is always important to begin by taking a full history of the patient's problem including the date of the injury, the mechanism of the injury, any previous rehabilitation the patient underwent if any. Some of the information taken from patients includes data on age, sex, height, weight, socio-economic status, history of previous knee injuries and/or operations, present symptoms, mechanisms of injury (the direction of the impact, load or deformation predicts which structure was injured), level of activity in work, household, study and sports and pain severity. The patient should rate the pain on a scale of 0 to 10 with 0 being no pain and 10 being the worst pain. The therapist should ask the patient about the onset of the swelling, how it was managed, if they was any popping sound, instability of locking.

As for the patients with chronic symptoms, it is important to rule out systemic illnesses as the etiology of the knee problem. Infectious, neurology, vascular, inflammatory and arthritic causes must all be considered.

A systemic approach is important when examining the knee. This prevents the examiner from missing pathology and allows him to recognize which signs indicate a possible abnormality. Observation, range of motion (ROM), palpation, special tests and a neurovascular examination are the major parts that make up a comprehensive examination. The healthy knee is also examined and both are compared. The pain in the knee might be referred from the back or the hip so the examination of both of these areas is important too.

2.6.2 INSPECTION

The examiner must inspect the knee and must not forget to inspect the whole extremity. The gait of the patient should be observed. A normal gait should be extended when the heel touches the floor and should be flexed during the swing and stance phase. Gait must be observed from the time the patient walks in because during the examination when gait is provided the patient may be self aware. The gait may provide information about the location of the pain and its effect on activities of daily living. Things to look for in the knee are genu varum (bowleg), genu valgum (knock knee) and genu recurvatum (hyperextension). The examiner should also look for any swelling, redness, effusion, deformities or muscle atrophies.

2.6.3 PALPATION

During palpation, the patient must be in a relaxed position. This examination should always begin superficially. Check for any tenderness, temperature (an increase in heat indicates an inflammatory response to heat). Soft tissue and all boney land marks such as medial and lateral femoral condyles, patella tibial tubercle and the fibular head must be palpated and the most painful areas should be palpated last. Muscles acting on the knee joint such as the quadriceps, biceps femoris and hamstrings must also be palpated to check for tone of the muscle. Anthropometric measurements can also be used to measure the circumferences of the extremities to evaluate any swelling or hypotrophy. (11)

2.6.4 PATELLA TAP

This is a simple test that is used to determine if there is any effusion at the knee joint. It is performed while the patient is supine lying. The therapist slides the index finger and the thumb form about 15cm above the knee to the level of the upper border of the patella in order to squeeze out any excess fluid from the suprapatellar pouch. Then jerk the patella quickly downwards with the tips of the thumb and the three fingers of the other hand placed on the patella. If there is a click sound heard then this indicates the presence of effusion. If the effusion is gross and tense then the test is negative.

2.6.5 RANGE OF MOTION

For the range of motion measurement, a goniometer is needed. The examiner should start by measuring the active ROM (done without the help of the examiner) then the passive ROM (done with the help of the examiner). The passive ROM is normally slightly more than the active ROM.

Flexion and extension are the movements that must be measured in the knee joint. During flexion, the patient is in prone position. The therapist places the stationary arm along the femur and the movable one is aligned with the fibular. During extension, the patient is in supine position and the goniometer is placed in the same way as it was during the flexion examination. (12)

Normal range of motion according to the SFTR method:

S	5-0-140
F	-
T	-
Rs	45-0-30

Table 4: SFTR method for ROM of knee(12,13)

2.6.6 EXAMINATION OF KNEE LIGAMENTS

Listed below is a list of stability tests to access the anterior cruciate ligament including a brief description of how each of them is carried out.

2.6.6.1 LACHMAN TEST

Procedure: patient is supine with knee flexed at 15-30 degrees. The therapist holds the femur with one hand while pulling the tibia anteriorly with the other hand. Note that during this examination, the quadriceps muscles and the knee flexors must be relaxed completely. During the examination, we evaluate the end point of the movement when the tibia is pulled anteriorly. A hard end point within 3mm suggests that there is stability of the ACL. When there is a soft or no endpoint then there is suspected to be ACL injury.

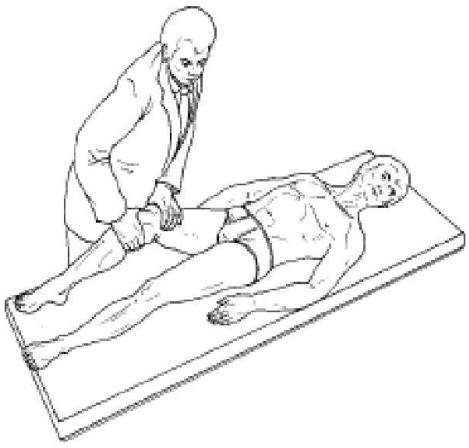

Figure 3: Lachman test (4)

2.6.6.2 ANTERIOR DRAWER SIGN

The patient is supine with the hip flexed at 45 degrees and the knee flexed to 90 degrees. The examiner sits on the patients forefoot while the foot is in neutral

rotation. With the hands placed around the proximal tibia, the tibia is drawn forward. If the tibia moves more than 6mm anteriorly then the test is positive and may indicate ACL injury.

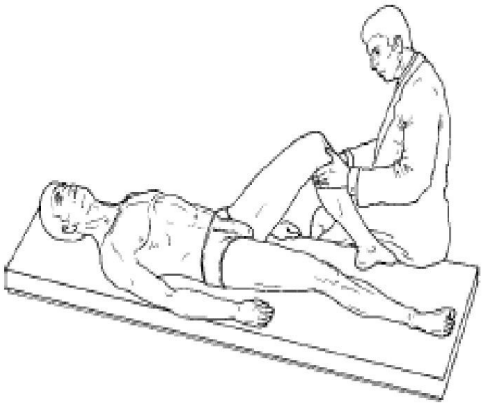

Figure 4: Anterior Drawer Sign (4)

2.6.6.3 PIVOT SHIFT TEST

The patient is in supine. The therapist holds and stabilizes the lateral femoral condyle with one hand and palpates the proximal tibia with the thumb while the other hand holds the patients lower leg in internal rotation and abduction. The knee is moved from extension into flexion. In the case that there is an ACL injury, the valgus stress applied during the examination will cause the tibia to subluxate in anterior direction while the knee is in extension.

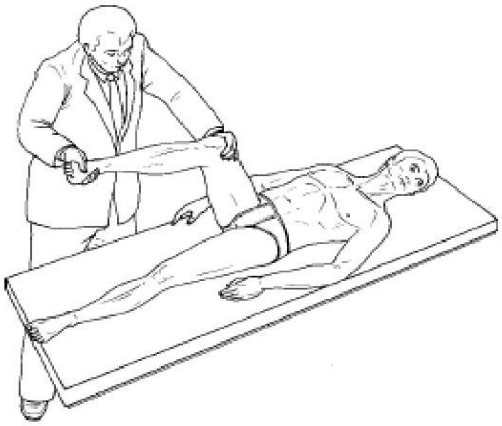

Figure 5: Pivot shift test (4)

2.6.6.4 GRADING OF LIGAMENT INJURIES

Ligament injuries can be graded according to the severity if the injury. There are three grades:

Grade I: tearing within the microstructure but no obvious stretching of the ligament

Grade II: ligament is stretched and there is a partial tear

Grade III: complete tear causing the ligament to separate into two parts.

2.6.7 SURGICAL TREATMENT OF ACL RUPTURES

Intraarticular ACL reconstruction is performed using a min- arthrotomy technique. An arthroscopy is performed on the ACL deficient knee in order to evaluate and treat meniscus tears and articular damage.

In the case that one or more ligaments have been torn or there is a complete tear of the ACL and there are signs of ongoing knee instability, pain and swelling, ACL surgery may be recommended. If the patient is an active sportsperson, and they would like to return to their sports activities such as soccer, tennis, basketball or football, the ACL reconstruction would be the best option.

ACL reconstruction is almost always performed atrhroscopically with one or two incisions where the fragments of the damaged ACL are removed and replaced by another form of tissue called a graft. A graft can either be from the patients own tissue (from the patella or hamstrings) which is highly recommended because the tissue heals faster and reduces other risks or in cases where the patient is older or the patient has had similar injuries in the past and may not have enough tissue for grafting, an allograft may be used and this is tissue donated by an individual at the time of death. (22)

2.6.8 CONSERVATIVE TREATMENT OF ACL INJURY

Usually, non surgical approaches of the ACL injuries depend on the degree of the injury, associated injuries to the menisci or other ligaments and the patients functional demands as stated earlier. In most cases, patients who have either partial ACL tears and have a less active life are treated conservatively.

Patients who are treated conservatively require aggressive treatment in order to reduce swelling and pain, regain their full range of motion of the knee, increase strength and endurance and also functional training and education so as to lower the chances of further injury and degeneration of the knee joint. Patients with acute ACL injuries must immediately use the "RICE" method; rest, ice, compression and elevation in order to reduce swelling and pain. ROM restoration must be started at an early stage but while at it, patients must be careful as not to perform exercises that will further aggravate soft tissue injury and prolongation of inflammation and swelling.

It is also advisable to begin isometric strengthening exercises of the quadriceps especially, hamstrings and gastrocnemius and soleus muscles in order to prevent or minimize muscle atrophy even when the knee is in a brace. Patients must work towards regaining full active extension and normal gait within seven to ten days after injury. Inflammation usually disappears within three weeks.

Once the inflammatory phase has been resolved and the full range of motion has been restored, then the therapist can advise the patient on what kinds of exercises the patient can do. The open chain quadriceps exercises must be avoided so as avoid patellofemoral syndromes. Exercises such as mini squats, seated leg presses, and cycling are recommended as they minimize anterior tibial translation. Most importantly is the stretching of the hamstrings muscles as this helps in restoring full range of motion as well.

Proprioreceptive neuromascular facilitation (PNF) techniques are recommended as soon as the strength and endurance levels have increased to about 70 percent of the healthy leg. PNF techniques must be performed precisely according to the movement exact movement patterns and must be done in a progressive way so that we can enhance dynamic knee joint stability.

Although in many cases, functional knee braces are provided for patients with ACL injuries as patients feel that they have better stability and feel more confident, studies have shown that the braces do not provide adequate mechanical stability. Although they do work towards preventing the knee from further injuries. Patients must be educated on activities that they must avoid in order to prevent further injury to the knee and also reduce the risk of early degenerative joint disease.

As for chronic patients, the case differs in that they tend to have full range of motion and usually have a modified kind of lifestyle but just as in the acute ACL injuries, patients with chronic ACL injuries also require a program that emphasizes on muscle strengthening and endurance, neuromascular control and avoidance of activities that may case instability of the knee. (7,22,14)

3. Special part (Case Study)

3.1 METHODOLOGY

My clinical work practice was carried out at C.L.P.A (Centrum léčby pohybového aparátu), a medical institute mostly specialized in orthopedics and rehabilitation in Prague, Czech Republic. The practice was carried out over a ten working day period from the 21st January 2013, Monday to the 1st of February 2013, Friday and consisted of 8 hours each day making a total of 80 hours in ten days.

My clinical work placement was supervised by PhD. Edwin Mahr. I had a total of 5 sessions with my patient during the two week period the first of which started on the 23rd of January 2013 and continued day by day. The last session was carried out on the 1st of February 2013.

My course of therapeutic procedures was mainly done using manual methods. These took place in the individual therapy room in the department of orthopedics and rehabilitation. For the examination and therapy I used mostly my hands and some of the rehabilitation equipment. As for the examinations procedures, I used a goniometer, measuring tape, and a neurological hammer.

The patient was fully aware of the examination and therapeutic procedures at all given times. There were no invasive methods used and there was a consent form signed between me and the patient.

My research project has been approved by the Ethics Board Committee of the Faculty of Sport and Physical Education at Charles University, under the approval number 038/2013

Date: 25/01/2012

3.1.1 SPECIFICATION OF STUDY

Examined person: M.C. 1973, female

Diagnosis: Tear right side of anterior cruciate ligament three weeks before surgery

Diagnosis code: M2351

3.2 ANAMNESIS

Present state: Patient came in for a second session of therapy. She is an outpatient. On the 14th of December 2012 she was playing basketball and hurt her knee. She did not fall. Knee was just moved to the side with force. Later that night she applied an ice pack through the night to try and bring down the swelling. The next day (15th December) she went to the hospital in Bulovka and was given an injection for the oedema. On the 17th of December 2012, she was given a knee stabiliser which she had on for two weeks of which she was using crutches. Patient then came to CLPA on the 24th of January 2013 for therapy. She was limping but not using crutches. Patient does not feel any pain at the moment.

Weight: 64kg

Height: 165cm

BMI: 23.5

Personal anamnesis:

- All common childhood diseases
- No operations or similar injuries from the past

Family anamnesis:

- No one in the family suffers from any diseases related to injury
- Father, Mother and siblings are all healthy

Social anamnesis:

- Patient has three healthy children and is married. Lives with all three children and her husband. They live on the second floor of the building with no elevator
- Patient is cooperative and oriented

Occupational anamnesis:

- .Works as a sales manager. Spends most of her time sitting at her desk in the office

Gyneocolocal anamnesis:

- Delivered all three children with no complications
- Has normal menstrual cycle

Pharmacological anamnesis:

- Patient is not taking any medication.
- She is not taking any contraceptives

Hobbies-ADL:

- Basketball, cycling, swimming (other different kind of sports). She is a very active sports woman

Allergic anamnesis:

- None

Previous trauma/injuries:

- none

Abuses:

- Takes alcohol occasionally, does not smoke

Previous rehabilitation:

- None

Statement from the patient's medical documentation:

- Medical documentation from the physiotherapist states that she has an anterior cruciate ligament tear

Indication of rehabilitation:

- Sensomotoric training
- Mobilisation of peripheral joints
- PIR
- Magnetotherapy

3.3 INITIAL KINESIOLOGIC EXAMINATION

3.3.1 POSTURE EXAMINATION

Stance

- Normal base (one foot length apart)

Posterior view

- Left leg more forward
- Left side of medial malleolus is slightly more protruded
- More loading of heel medially on both feet
- Achilles tendon slightly bigger on right side
- Right calf smaller
- Right knee in slight flexion
- Right gluteus is lower
- Left scapular more protruded
- Left shoulder higher
- Head is in midline

Lateral view

- Left foot more forward
- Right knee in slight flexion
- Prominence of abdominal wall
- Slight lodorsis of lumbar part
- Slight kyphosis of thoracic spine
- Elbows semi flexed in both upper extremities
- Shoulders slightly protracted forward
- Slight lodorsis of cervical spine
- Trunk slightly rotated to the right
- Head in midline

Anterior view

- Left foot more forward
- More loading on medial side of right foot
- Right knee is in slight flexion
- Left side of pelvis higher
- Umbilicus is shifted more to left
- Left shoulder is higher and more forward
- Right clavicle more protruded
- Head in midline

3.3.2 TRENDELENBURG TEST

- **left leg:** negative
- **right leg:** negative

3.3.3 RHOMBERG TEST

- **Rhomberg I:** negative
- **Rhomberg II:** negative
- **Rhomberg III:** negative

3.3.4 GAIT EXAMINATION

- no good rolling of right foot, doesn't use heel then toes
- more loading on medial side of both feet
- right knee is in slight flexion
- first contact with ground is heel then toes (left side better than right)
- left step slightly shorter than right one
- slight external rotation in hip
- normal swing of arms
- trunk rotation more to the left
- symmetrical swing of arms

Tip toe walking: able to provide with very little instability

Walking on heels: able to provide with stability

Squat walking: able to provide but with pain in the right knee

3.3.5 PELVIS PALPATION

- **iliac crest**: higher on left side
- **anterior iliac spine**: slightly higher on left side
- **posterior iliac spine**: slightly higher on left side

3.3.6 SPECIAL SCALE TEST:

Right 30 Left 35kg difference: 5kg

3.3.7 ANTHROPOMETRIC MEASUREMENTS

Lengths of lower extremity

Measurement	**Right(cm)**	**Left(cm)**
Anatomical length	80	80
Functional length		
• Ant.iliac crest	85	85

Table 5-Initial examination: Lengths of L.E

Circumferences of lower extremity

Measurement	**Right(cm)**	**Left(cm)**
Circumference of thigh	50	53
Circumference 15cm above the knee	40	40
Circumference on the knee	37	36.5
Circumference below the knee	33	33
Circumference of calf	37	37
Circumference of ankle	22	22

Table 6- Initial examination: Circumferences of L.E

3.3.8 SOFT TISSUE EXAMINATION

Skin and fascia: both slightly restricted on the right side of the thigh both in caudal cranial and lateral lateral directions. And the calf in all directions but mostly in lateral lateral directions

3.3.9 MUSCLE TONE EXAMINATION

Muscle	Left	Right
Rectus femoris	Eutone	Slight hypotone
Vastus medialis, vastus intermedialis, vastus lateralis	Eutone	Eutone
Adductors	Eutone	Eutone
Iliopsoas	Eutone	Eutone
Piriformis	Eutone	Slight hypertone
Tensor fasciae latae	Eutone	Eutone
Gluteii	Eutone	Eutone
Hamstrings	Eutone	Slight hypertone
Gastrocnemius	Eutone	Slight hypertone
Tibialis anterior	Eutone	Eutone

Table 7-Initial examination: Muscle tone examination

3.3.10 ROM EXAMINATION BY KENDALL

HIP JOINT

Plane	Left		Right	
	Active Movement	Passive Movement	Active Movement	Passive Movement
S*	10-0- 120	15 -0- 125	10 -0- 110	10 -0- 115
F	40-0-15	45-0-15	40-0-15	45-0-15
R	40-0-40	45-0-45	40-0-40	45-0-45

Table 8-Initial examination: ROM of hip joint (SFTR)

*With flexed knee

KNEE JOINT

Plane	Left		Right	
	Active Movement	Passive Movement	Active Movement	Passive Movement
S	0 – 0 – 125	0 – 0 - 130	15 – 0 - 75	15 – 0 –80(with pain)

Table 9-Initial examination: ROM of knee joint

ANKLE JOINT

	Left		Right	
	Active Movement	Passive Movement	Active Movement	Passive Movement
S	10-0-40	15-0-45	5-0-35	10-0-40

Table 10-Initial examination: ROM of ankle joint

3.3.11 MUSCLE LENGTH TEST BY JANDA

Examined muscle	**left**	**right**
Hamstrings	0	1
Tensor fasciae latae	0	0
Iliopsoas	0	0
Gastrocnemius	0	1
Soleus	0	1
Rectus femoris	0	0

Table 11-Initial examination: Muscle length test

3.3.12 MUSCLE STRENGTH TEST BY KENDALL

Examined muscle	**Left**	**Right**
Quadriceps femoris	5	4-
Gluteii	5	4+
Tibialis anterior	5	4+
Gastrocnemious	5	4+
Hamstrings	5	4-
Adductors	5	5
Abuductors	5	5

Table 12-Initial examination: Muscle strength test

3.3.13 JOINT PLAY EXAMINATION BY LEWIT

- Interphalangeal joints of toes, in all the directions (dorsal, plantar and lateral side): no restriction
- Metatarsophalangeal joints, in all the directions (dorsal, plantar and lateral side): no restriction
- Chopart joint: no restriction on both sides
- Ankle joint: no restriction on both sides
- Lisfranc joint is restricted in both dorsal and plantar directions on right side
- Patella slightly restricted to the lateral side and in caudal direction on right side
- Fibula is lightly restricted in dorsal direction on right side

3.3.14 LACHMAN TEST

- Tested positive on right side (Grade I)

3.3.15 NEUROLOGICAL EXAMINATION

Superficial sensation in lower extremities:

- Dermatomes of L2 segment in both extremities- patient felt the same
- Dermatomes of L3 segment in both extremities- patient felt the same
- Dermatomes of L4 segment in both extremities- patient felt the same
- Dermatomes of L5 segment in both extremities- patient felt the same
- Dermatomes of S1 segment in both extremities- patient felt the same
- Dermatomes of S2 segment in both extremities- patient felt the same

Deep sensation in lower extremities:

- Tested negative

Deep tendon reflexes:

Evaluation grades for deep tendon reflexes:

0-absecnt

1-hypoactive or present only with reinforcement

2-normal response

3-brisk with or without evidence of spread of the neighbouring roots

4-unsustained clonus

5-sustained clonus

Reflexes	**Right**	**Left**
Knee jerk reflex	2	2
Achilles tendon reflex	2	2
Plantar reflex	2	2

Table 13-Initial examination: Deep tendon reflexes of L.E

3.4 CONCLUSION

According to the results of the examination, it was established that the patient has got a tear of the anterior cruciate ligament on the right lower extremity therefore causing the limitation of range of motion in both flexion and extension. Lachman test was positive with grade I. There is also shortness of hamstrings, gastrocnemious and soleus. Generally, her muscle strength is good.

3.5 SHORT-TERM REHABILITATION PLAN

- Relaxation of muscles
- Strengthening of muscles
- Stretching of muscles
- Release tension of skin and fascia
- Mobilization of joints
- Increase range of motion
- Sensomotoric training

3.6 LONG-TERM REHABILITATION PLAN

- Correct walking pattern after operation
- Decrease swelling after operation
- Sensomotoric training
- Restore full range of motion
- Maintain muscle strength
- Maintain results from short-term rehabilitation plan

3.7 THERAPY SUGGESTION

- Soft tissue techniques according to Lewit to release the skin and fascia of thigh and calf
- Active exercises
- PIR by Lewit to release the tension in muscles
- Isometric exercises using soft ball to strengthen muscles
- Sensomortoric training by Janda to improve proprioreception
- Joint play techniques of restricted joints by Lewit
- Exercises on bicycle
- Strengthening exercises for lower extremity (active exercises)

3.8 DAY TO DAY THERAPY

3.8.1 First therapeutic unit

Wednesday 23.01.13

Goals of today's therapeutic unit:

- Release tension of skin and fascia around the thigh and calf
- Relaxation of tense muscles (gastrocnemius, hamstrings and piriformis)
- Increase range of motion in both flexion and extension
- Mobilization of restricted joints
- Sensomotoric training

Therapy suggestion:

- soft tissue techniques
- PIR according to Lewit

- Active exercises
- Joint play techniques by Lewit
- Sensomotoric training

Execution:

- Soft tissue techniques according to Lewit: applied on the right side of the thigh and calf on the anterior part in all directions (caudocranial, mediolateral)
- PIR techniques according to Lewit: applied on the right side for relaxation of tense muscles by stretching of hamstrings, gastrocnemius, soleus and pririformis)
- Exercises to increase range of motion in flexion: heel slides: patient is supine lying on a floor mat with both lower extremities extended. She slides the right heel towards the buttocks while keeping the heel on the ground until she reaches maximum flexion as far as she can go and holds this position for six seconds then returns to starting position. (5 repetitions)
- Joint play techniques by Lewit: applied for the lisfranc joint on the right side, dorsal and plantar fan on the right side, patella in lateral and caudal directions on the right side and fibula in dorsal direction on the right side
- Sensomotoric training: stepping on wobble boards one after the other with straight back, neck and head and then using ball by passing it hand to hand. (two times). Training on posturemed by stepping on and off forward and the sideways.

Results:

Objective:

After the therapy, the patient felt okay. She did not feel any pain at all.

Subjective:

There was slight increase in passive range of motion in both extension and flexion by approximately 5 degrees on the right side on the knee. There was a little improvement in the fascia and skin mobility after the soft tissue techniques were performed in cranial, caudal, and lateral directions on the anterior part of the thigh.

3.8.2 Second therapeutic unit

Friday 25.01.2013

Goals of today's therapy unit

- Release tension of skin and fascia around the thigh and calf
- Relaxation and stretching of tense and shortened muscles (gastrocnemius, soleus, hamstrings and piriformis)
- Maintenance of muscle strength lower extremity
- Increase range of motion in both extension and flexion
- Mobilization of restricted joints
- Sensomotoric training

Therapy suggestion:

- Soft tissue techniques
- PIR according to Lewit
- Active exercises for both strengthening and increasing range of motion
- Joint play techniques by Lewit
- Sensomotoric training

Execution:

- Soft tissue techniques according to Lewit: applied on the right side of the thigh and calf on the anterior part in all directions (caudocranial, mediolateral)

- PIR techniques according to Lewit: applied on the right side for relaxation of tense muscles by stretching of hamstrings, gastrocnemius and pririformis
- Exercises to increase range of motion in flexion and extension
    - wall slides: patient is supine lying on floor mat with both legs extended up on the wall. She slightly lowers the right leg by sliding the foot down the wall and after reaching maximum flexion as far as she can go, she holds this position for approximately 10 seconds and returns to starting position. (5 repetitions)
    - towel pulls: patient is in sitting position with the non affected leg flexed and a the affected side extended. Patient places a band round the soles of the foot and tries to help the knee go into full extension by pulling the band towards the trunk
- Active strengthening exercises:
    - patient is in supine lying on a mat on the floor with both legs fully extended and a small exercise ball is placed under the affected knee. Patient is asked to press the ball down repeatedly. (15 times, 2 repetitions)
    - patient is in supine lying and moves right leg laterally and back while in extension and foot in dorsal flexion 15 times
- Joint play techniques by Lewit: applied for the lisfranc joint on the right side, dorsal and plantar fan on the right side, patella in lateral and caudal directions on the right side and fibula in dorsal direction on the right side
- Sensomotoric training: stepping on wobble boards one after the other with straight back, neck and head and then using ball by passing it hand to hand. (two times). Training on posturemed by stepping on and off forward and the sideways.

Subjective: patient had no trouble doing the exercises according to the instructions given

Objective: The soft tissue of the right thigh and calf had better mobility in all directions. There was better mobility in the lisfranc joint and the fibular joint in both ventral and dorsal directions and in patella in all directions (caudal, cranial and lateral lateral directions).

3.8.3 Third therapeutic unit

Monday 28.01.2013

Goals of today's therapy unit

- Stretching of hamstrings
- Strengthen quadriceps
- Increase range of motion
- Sensomotoric training

Therapy suggestion

- PIR techniques according to Lewit
- Active exercises to increase range of motion and for strengthening
- Sensomotoric training

Execution:

- Exercises to increase range of motion in flexion and extension
  - wall slides: patient is supine lying on floor mat with both legs extended up on the wall. She slightly lowers the right leg by sliding the foot down the wall and after reaching maximum flexion as far as she can go, she holds this position for approximately 10 seconds and returns to starting position. (5 repetitions)
  - towel pulls: patient is in sitting position with the non affected leg flexed and a the affected side extended. Patient places a band round the soles of the foot and tries to help the knee go into full extension by pulling the band towards the trunk

- Active exercises:

  - patient is in supine lying on a mat on the floor with both legs fully extended and a small exercise ball is placed under the affected knee. Patient is asked to press the ball down repeatedly. (15 times, 2 repetitions)
  - Patient is supine lying on the mat with her left leg straight. Her right leg is flexed in hip and knee joints and her foot is stepping on an over-ball, which is on the bed. From this position, patient straightens her right lower extremity by rolling the over-ball (the leg should not fall from the over-ball). Then she is rolling back the ball as far as she can flex her knee and repeats 15 times.
  - leg raises-patient is in spine lying and raises her right leg while in extension and foot in dorsal flexion 15 times
  - patient is in supine lying and moves right leg laterally and back while in extension and foot in dorsal flexion 15 times
- Sensomotoric training: stepping on wobble boards one after the other with straight back, neck and head and then using ball by passing it hand to hand. (two times). Training on posturemed by stepping on and off forward and the sideways. Patient walked on a rope forward and backward two times in each direction

Subjective: patient felt fine and didnt not experience any form of pain and was able to coordinate with the exercises given to her

Objective: there was a slight increase in the range of motion in flexion and extension after performing PIR for the hamstrings and quadriceps in the right leg there was not as much tension in the hamstrings than was felt before

3.8.4 Fourth therapeutic unit

Wednesday 30.01.2013

Goals of today's therapy unit

- Increase range of motion in knee
- Maintenance of muscle strength lower extremity
- Sensomotoric training

Therapy suggestion:

- PIR according to Lewit
- Active exercises for both strengthening and increasing range of motion
- Sensomotoric training

Execution:

- PIR techniques according to Lewit: applied on the right side for relaxation of tense muscles by stretching of hamstrings, gastrocnemius
- Exercise to increase range of motion: bicycle riding for 15 minutes without resistance
- Active exercises for strengthening:
    - patient is in supine lying on a mat on the floor with both legs fully extended and a small exercise ball is placed under the affected knee. Patient is asked to press the ball down repeatedly. (15 times, 2 repetitions)
    - Patient is supine lying on the mat with her left leg straight. Her right leg is flexed in hip and knee joints and her foot is stepping on an over-ball, which is on the bed. From this position, patient straightens her right lower extremity by rolling the over-ball (the leg should not fall from the over-ball). Then she is rolling back the ball as far as she can flex her knee and repeats 15 times.
    - leg raises-patient is in spine lying and raises her right leg while in extension and foot in dorsal flexion 15 times
    - patient is in supine lying and moves right leg laterally and back while in extension and foot in dorsal flexion 20 times

- exercises on the leg curl machine for both quadriceps and hamstrings 15 times each using weight of 15 kilograms

- Sensomotoric training: stepping on wobble boards one after the other with straight back, neck and head and then using ball by passing it hand to hand. (two times). Training on posturemed by stepping on and off forward and the sideways. Patient walked on a rope forward and backward two times in each direction

Subjective: patient felt a little pain in the knee during the exercises on the leg curl machine in flexion and she felt she could extend her leg better than before

Objective: there was an increase in the range of motion in the right knee after perofiming PIR for hamtsrings in extension.

3.8.5 Fifth therapeutic unit

Friday 01.02.2013

Goals of today's therapy unit

- Increase range of motion (flexion and extension)
- Maintenance of muscle strength lower extremity
- Sensomotoric training

Therapy suggestion:

- PIR according to Lewit
- Active exercises for both strengthening and increasing range of motion
- Sensomotoric training

Execution:

- PIR techniques according to Lewit: applied on the right side to stretch hamstrings to improve range of motion

- Exercise to increase range of motion: bicycle riding for 15 minutes without resistance
- Exercises to increase range of motion:
    - wall slides: patient is supine lying on floor mat with both legs extended up on the wall. She slightly lowers the right leg by sliding the foot down the wall and after reaching maximum flexion as far as she can go, she holds this position for approximately 10 seconds and returns to starting position. (5 repetitions)
    - towel pulls: patient is in sitting position with the non affected leg flexed and a the affected side extended. Patient places a band round the soles of the foot and tries to help the knee go into full extension by pulling the band towards the trunk

- Active exercises:
    - patient is in supine lying on a mat on the floor with both legs fully extended and a small exercise ball is placed under the affected knee. Patient is asked to press the ball down repeatedly. (15 times, 2 repetitions)
    - Patient is supine lying on the mat with her left leg straight. Her right leg is flexed in hip and knee joints and her foot is stepping on an over-ball, which is on the bed. From this position, patient straightens her right lower extremity by rolling the over-ball (the leg should not fall from the over-ball). Then she is rolling back the ball as far as she can flex her knee and repeats 15 times.
    - patient is in supine lying and moves right leg laterally and back while in extension and foot in dorsal flexion 15 times
    - exercises on the leg curl machine for both quadriceps and hamstrings 15 times each using weight of 15 kilograms
- Sensomotoric training: stepping on wobble boards one after the other with straight back, neck and head and then using ball by passing it hand to hand. (two times). Training on posturemed by stepping on and off forward and the

sideways. Patient walked on a rope forward and backward two times in each direction

Subjective: patient says she felt a lot better and more stable after the two weeks of therapy

Objective: there was increase in the range of motion in the right knee in both flexion and extension.

3.8.6 SELF THERAPY RECOMMENDATIONS

- stretching of hamstrings for right lower extremity: leg raises in supine position with one leg flexed. Patient raises leg and holds it for approximately eight seconds and returns to starting position. (3 repetitions 3 times a day)
- gravity induced PIR according to Lewit for hamstrings and rectus femoris (3 repetitions 3 times a day)
- strengthening of quadriceps:
    1. leg raises with dorsal flexion of ankle and straight knee (15 repetitions)
    2. leg raises with external and internal rotation of leg (15 repetitions each)
    3. with a soft gym ball placed under the knee, patient presses down repetitively 15 times

3.9 FINAL KINESIOLOGIC EXAMINATION

3.9.1 POSTURE EXAMINATION

Stance: normal base (one foot length apart)

Posterior view

- Left leg more forward
- Left side malleolus slightly more protruded
- Loading of both feet medially
- Achilles tendon slightly bigger on the right side

- Right calf slightly smaller
- **Semi-flexion of right knee but not as much as before**
- Left scapular slightly more protruded
- Left shoulder is slightly higher
- Head is in midline

lateral view

- Left foot more forward
- **Right knee is in flexion but not as much as before**
- Slight anterior tilt of pelvis
- Slight lumbar lordorsis
- Slight kyphosis in thoracic spine
- Prominence of abdominal wall
- Elbows semi flexed
- Left scapular is slightly more protruded
- Slight cervical lordorsis
- Head is in midline

Anterior view

- Left foot more forward
- More loading on medial side of right foot
- **Right knee is in semi-flexion but not as much as before**
- Umbilicus more to left
- **Left shoulder is higher but less than before**
- Left shoulder slightly more forward
- Right clavicle more protruded
- Head in midline

3.9.2 TRENDELENBURG TEST

- **left leg:** negative
- **right leg:** negative

3.9.3 RHOMBERG TEST

- **Rhomberg I:** negative
- **Rhomberg II:** negative
- **Rhomberg III:** negative

3.9.4 GAIT FINAL EXAMINATION

- more loading on the medial side of both feet
- **improved foot contact with ground: first contact with heels followed by soles and then toes**
- left step shorter than the right
- **right knee not in full extension but better than initial**
- slight external rotation in both knee joint but considered at physiological
- trunk rotation more to the left
- same swinging motion of arms on both sides

Tip toe walking: able to provide with very little instability

Walking on heels: able to provide with stability

Squat walking: able to provide but with pain in the right knee

3.9.5 PELVIS PALPATION

- iliac crest: **slightly higher on the left side with very little difference**
- anterior iliac spine: slightly higher on left side with minimal difference
- posterior iliac spine: slightly higher on left side with minimal difference

3.9.6 SPECIAL SCALE TEST

Right 31kg Left 35kg difference: 4kg

3.9.7 ANTHROPOMETRIC MEASUREMENTS

Lengths of lower extremity

Measuremnt	**Right(cm)**	**Left(cm)**
Anatomical length	80	80
Functional length		
• Ant.iliac crest	85	85

Table 14-Final examination: Lengths of L.E

Circumferences of lower extremities

Circumference of thigh	53	54
Circumference above the knee	40	40
Circumference on the knee	38	37
Circumference below the knee	33	34
Circumference of calf	37	37

Circumference of ankle	22	22

Table 15-Final examination: Circumferences of L.E

3.9.8 SOFT TISSUE

Skin and fascia around the thigh and calf was free in all directions (cranial, caudal, lateral directions)

3.9.9 MUSCLE TONE EXAMINATION (PALPATION) BY LEWIT

Muscle	Left	Right
Rectus femoris	Eutone	Eutone
Vastus medialis, vastus intermedialis, vastus lateralis	Eutone	Eutone
Adductors	Eutone	Eutone
Iliopsoas	Eutone	Eutone
Piriformis	Eutone	Eutone
Tensor fasciae latae	Eutone	Eutone
Gluteii	Eutone	Eutone
Hamstrings	Eutone	Slight hypertone
Gastrocnemius	Eutone	Eutone
Tibialis anterior	Eutone	Eutone

Table 16-Final examination: Muscle tone examination

3.9.10 ROM EXAMINATION BY KENDALL

HIP JOINT

Plane	**Left**		**Right**	
	Active Movement	Passive Movement	Active Movement	Passive Movement
S*	10-0- 120	15 -0- 125	10 -0- 110	10 -0- 115
F	40-0-15	45-0-15	40-0-15	45-0-15
R	40-0-40	45-0-45	40-0-40	45-0-45

Table 17-Final examination: ROM of hip joint

*With flexed knee

KNEE JOINT

Plane	**Left**		**Right**	
	Active Movement	Passive Movement	Active Movement	Passive Movement
S	0 – 0 – 125	0 – 0 - 130	5 – 0 - 85	5 – 0 –95(with pain)

Table 18-Final examination: ROM of knee join

ANKLE JOINT

	Left		Right	
	Active Movement	Passive Movement	Active Movement	Passive Movement
S	10-0-40	15-0-45	10-0-35	15-0-40

Table 19-Final examination: ROM of ankle joint

3.9.11 MUSCLE LENGTH TEST BY JANDA

Examined muscle	**left**	**right**
Hamstrings	0	1
Tensor fasciae latae	0	0
Iliopsoas	0	0
Gastrocnemius	0	0
Soleus	0	0
Rectus femoris	0	0

Table 20-Final examination: Muscle length test

3.9.12 MUSCLE STRENGTH TEST BY KENDALL

Muscle strength grading according to Kendall

No contraction-0

Contraction felt with no visible movement-1

Movement through complete ROM for the tested muscle-2

Gradual release from test position-3-

Holds test position (no added pressure)-3

Holds test position against slight pressure-3+

Holds test position against slight to moderate pressure-4-

Holds test position against moderate pressure-4

Holds test position against moderate to strong pressure-4+

Holds test position against strong pressure-5

Tested muscle	**Left**	**Right**
Quadriceps femoris	5	4+
Gluteii	5	4+
Tibialis anterior	5	4+
gastrocnemious	5	4+
Hamstrings	5	4-
Adductors	5	5
Abuductors	5	5

Table 21-Final examination: Muscle strength test

3.9.13 JOINT PLAY EXAMINATION BY LEWIT

- Interphalangeal joints of toes, in all the directions (dorsal, plantar and lateral side): no restriction
- Metatarsophalangeal joints, in all the directions (dorsal, plantar and lateral side): no restriction
- Calcaneus: no restriction
- Lisfranc joint is restricted in dorsal direction

- Chopart joint: no restriction in all directions
- Ankle joint: no restriction
- Patella: no restriction
- Fibular: slightly restricted in dorsal direction on the right side

3.9.14 LACHMAN TEST

- Tested positive on the right side (Grade I)

3.9.15 NEUROLOGICAL EXAMINATION BY LEWIT

Superficial sensation in lower extremities:

- Dermatomes of L2 segment in both extremities- patient felt the same
- Dermatomes of L3 segment in both extremities- patient felt the same
- Dermatomes of L4 segment in both extremities- patient felt the same
- Dermatomes of L5 segment in both extremities- patient felt the same
- Dermatomes of S1 segment in both extremities- patient felt the same
- Dermatomes of S2 segment in both extremities- patient felt the same

Deep sensation in lower extremities:

- Tested negative

Deep tendon reflexes:

Evaluation grades for deep tendon reflexes:

0-absecnt

1-hypoactive or present only with reinforcement

2-normal response

3-brisk with or without evidence of spread of the neighbouring roots

4-unsustained clonus

5-sustained clonus

Reflexes	Right	Left
Knee jerk reflex	2	2
Achilles tendon reflex	2	2
Plantar reflex	2	2

Table 22-Final examination: Deep tendon reflexes of lower extremity

3.10 CONCLUSION

According to the results above, during the initial posture examination, we notice that there was a change in the position of the shoulder and a shift in the pelvis only because of the flexion of the knee. But all this improved according to the final posture examination.

During the initial examination, rectus femoris was in slight hypotone on the right side compared to the left but this improved significantly. The gastrocnemius was found to be in hypertone in the initial examination but improved according to the final examination. The piriformis and the hamstrings remained the same as in the initial examination on the right side. There was a significant increase in the range of motion of the knee on the right side in both flexion and extension. The examination of the joint play in the patella was non restricted compared to the initial examination on the right side. The lisfranc joint was free in the plantar direction unlike in the initial examination where there was restriction in both plantar and dorsal directions. There was a positive Lachman test with grade I. Overall, we could say that the therapy provided to the patient was effective

4. EVALUATION AND RESULTS OF THE THERAPY/ PROGNOSIS

In conclusion, I would like to mention that the patient was satisfied with the therapy treatment that was given to her during the ten days. The patient was generally in good condition from the first time I met her. She was not in pain during rest and there

was no swelling around the affected area. The major concern was the restriction in range of motion in the knee joint and the after effects of the surgery.

During the initial kinesiological examination which I carried out on the 23rd of January 2013, the patient came to the rehabilitation centre without any crutches and besides the fact that her knee was in slight flexion; there was no major visible gait disturbance. During the examination, there was slight muscle weakness of grade -4 of the quadriceps and the hamstrings on the right side which was the affected side as compared to the left side although the I expected a much worse result. There was shortness of the hamstrings, rectus femoris, gastrocnemius and soleus on the right side too which was expected due to the flexion position of the knee. Lachman test proved to be positive when compared on both sides of the lower extremities but I would say that the instability was not so significant and therefore graded I.

The therapy I applied was mainly concentrated on restoring the full range of motion of the right knee and improving and maintaining the muscle strength. We completed five therapy sessions in total and these took place from the 23rd of January 2013 to the 1st of February 2013. Although the therapy was done is a short period of time, the results clearly showed that there was an improvement from the first day I saw the patient. My main goal which was to increase the range of motion of the knee was successfully achieved and there was also an improvement in the muscle strength on the right lower extremity. The patient stated that she felt much better and also noticed the improvement in the range of motion on the affected side. She was generally satisfied with the course of treatment.

Among the therapies I provided which included PIR techniques, joint play techniques and other strengthening and stretching exercises, I believe the most effective therapy was the PIR and the stretching exercises. PIR with stretching for the hamstrings was effective because according to Lewit, PIR is used for tense and short muscles. In my case, the patient had both shortened and tense hamstrings hence the technique that was applied. Also, these techniques are the common techniques used at the rehabilitation centre for ACL injuries. PNF was going to be another effective technique to use for my patient to restore full range of motion because as stated earlier in the theoretical part of the thesis, PNF when used with the correct movements can be very

effective. My reason for not using this technique was because at the time of my research, it had not yet been taught to us. (6,15)

The stretching exercises that are recommended to do as soon as possible as mentioned earlier where very effective as well and easy for the patient. Another reason I believe that the therapy was a success was because my patient was willing to cooperate and did some of the exercises recommended to her alone at home as a self therapy. She was also determined to get back to her activities hence the motivation.

Below I have summarized all the differences in the findings between the Initial kinesiologic examination and the final kinesiologic examination. This is to give an overview of the results of the therapy used in the rehabilitation plan.

SUMMARY OF EVALIUATION OF RESULTS

Examination	Initial Kinesiologic examination	Final Kinesiologic examination
Posture: posterior and lateral view Anterior view	Semi-flexion of right knee joint Right shoulder higher than left	Reduced flexion of right knee joint Right shoulder almost at the same level as left one
Gait	Altered patter of gait through all phases	Gait almost normal
Pelvis palpation	Iliac crest higher on the left side	Right iliac crest almost in level with left one
Muscle tone Rectus femoris Priforis Hamstrings Gastrocnemius	 Hypotone on right side Hypertone on right side Hypertone on right side Hypertone on right side	 Eutone Eutone Still slight hypertone Eutone

ROM of right knee ROM of right knee	Active flexion: 75 degrees Active extension: -15 degrees Passive flexion: 80 degrees Passive extension: -15 degrees	Active flexion: 95 degrees Active extension: -5 degree Passive flexion: 95 degrees Passive extension: -5 degrees
Muscle length on right side Hamstrings Gastrocnemius Soleus	 1 1 1	 1 0 0
Muscle strength Quadriceps	 4-	 4+
Joint play Lisfranc joint	 Restricted in dorsal and plantar directions	 Free in dorsal and plantar directions
Patella	Restricted in lateral and caudal directions	Free in all direction

Table 23: Comparison of initial examination vs final examination

5.CONCLUSION OF RESEARCH

I considered my therapy execution successful. The patient was very cooperative right from the start and did not have any problems with the whole rehabilitation process. Considering the fact that the patient was going into surgery, it is important that she continues with the course of treatment so that it is much easier for her to progress even

after the surgery. I would recommend the same therapy, exercises and self therapy exercises too even after surgery. I think the patient will be back in good condition in a short period of time because she is a very determined and cooperative sports woman although she may have to avoid high risk sports such as basketball itself, and skiing as these sports are prone to leading to ACL injuries only until she is stable and fully healed.

In my opinion, the patient could have avoided surgery but as mentioned earlier, she leads an active kind of lifestyle as a sportswoman and returning to these activities for her was the main aim hence the surgery. The patient could have been treated conservatively. Although this is the case, she is advised to avoid other activities that may cause a similar injury in the near future.

6. LIST OF LITERATURE

1. Adler, S.S., Beckers, D., and Buck, M. (2008). *PNF in Practice.* 3Rd edition. Published by Springer Medlzin Verlag. ISBN: 978 3 540 73901 2

2. Bickley, S.L. (2007). *Bate's Guide to Physical Examination and History Taking.* 9th edition. Published by Lippincott Williams & Wilkins. ISBN: 0-7817-6718-0

3. Brotzman, B.S., and Wilk, E.K. (2003). *Clinical Orthopaedic Rehabilitation.* 2nd edition Published by Mosby. ISBN-13: 9780323011860

4. Buckup, K. (2004). *Clinical tests for the musculoskeletal system.* Thieme Publishing. ISBN: 313136791

5. Cooper, G. (2006). *Pocket Guide to Musculoskeletal Diagnosis.* Published by Humana Press Inc., New Jersey. ISBN: 1588296741

6. Ferber, R., Osternig L.R. and Gravelle, D.C. (2002). *Effects of PNF stretch techniques on knee flexor muscle EMG activity in older adults.* Journal or Electromyography and Kinesiology. 12: 391-397

7. Fitzgerald, G.K., Axe, J.M., and Snyder-Mackler L. (2000). *Proposed Practice Guidelines for Nonoperative Anterior Cruciate Ligament Rehabilitation of Physically Active Individuals.* Journal of Orthopaedic and Sports Physical Education. 30(4): 194-203

8. Fong, D. (2009). *Knee stability assessment on anterior cruciate ligament injury: Clinical and Biomechanical approaches.* Sports science, Medicine and Rehabilitation.

9. Hamill, J., and Knutzen, M.K. (2009). *Biomechanical Basis of Human Movement*, 3rd edition. Published by Lippincott Williams & Wilkins a Wolters Kluwer business. ISBN-13: 978-0-7817-9128-1

10. Hoppenfeld, S. (1976). *Physical Examination of the Spine Extremties.* Published by Prentice-Hall International. Inc., London. ISBN: 0836578535

11. Jalovcova M. (2008). Basic Therapeutic Methods I: Anthropometric Measurements, Lecture notes, Charles University in Prague

12. Jalovcova, M. (2008). Basic Therapeutic Methods I: Evaluation of Motion of Joint, Lecture notes, Charles University in Prague

13. Kendall, P.F. et al. (2005). *Muscles Testing and Function with Posture and Pain.* 5th edition. Published by Lippincott Williams & Wilkins. ISBN: 0-7817-4780-5

14. Leibnson, C. (2007). *Rehabilitation of the spine: A practitioner's Manual.* 2nd edition. Publishd by Lippincott Williams & Wilkins, Baltimore. ISBN: 0781729971

15. Lewit, K. (1999). *Manipulative Therapy in Rehabilitation of the Locomotor System.* 3rd ed. Published Butterworth Heinemann Ltd., Oxford. ISBN: 0750629649

16. Moore, L.K., Dalley, F.A., and Agur, M.R.A. (2010). *Clinically Oriented Anatomy.* 6th edition. Published by Lippincott Williams & Wilkins a Wolters Kluwer business. ISBN: 978-1-60547-652-0

17. Neumann, A.D. (2010). *Kinesiology of the Musculoskeletal System: Foundations for Rehabilitation.* 2Nd edition. 0323039898

18. Standring, S. (2005). *Grey's Anatomy,* 39th edition. Published by Elsivier Ltd, Philadelphia. ISBN: 0 443 06676 0

19. Stewart, T.D. and Hall, R.M. (2006). *Basic biomechanics of human joints: Hips, knees and the spine.* Current Orthopaedics. 20: 23-31

20. Telger, T., and Worth, F. (2006). *Atlas of Anatomy: General Anatomy and Musculloskeletal System,* 1st edition. Publishd by Georg Thieme Verlag. ISBN: 3-13-142071-5

21. Thompson, A., Skinner, A., and Piercy, J. (1991). *Tidy's Physiotherapy.* 12th ed. Published by Butterworth Heinemann Ltd., Oxford. ISBN: 0750613467

22. Williams, S.J., and Bach, B.R. (1996). *Operative and Nonoperative Rehabilitation of ACL-injured Knee.* Sports medicine and arthroscopy review. 4: 69-82.

Websites:

23. http://www.jointinjury.com/knee/page1.htm
24. http://www.drstevenhorwitz.com/ACL.html

7. Supplements

7.1 LIST OF TABLES

7.2 LIST OF FIGURES

7.3 LIST OF ABBREVIATIONS

ACL – Anterior Cruciate Ligame

AM – Antero Medial

LCL – Lateral Collateral Ligament

LE – Lower Extremity

MCL – Medial Collateral Ligament

PCL – Posterior Cruciate Ligament

PIR – Post Isometric Relaxation

PL- Posterolateral Bundle

PNF – Proprioreceptive Neuromascular Facilitation

ROM – Range of Motion