

CHARLES UNIVERSITY IN PRAGUE
FACULTY OF MEDICINE IN PILSEN
DENTISTRY DEPARTMENT

**Contemporary methods of treatment of injuries
and their complications in immature permanent teeth
in children**

DISSERTATION THESIS

Pilsen 2010

MUDr. Tzigkounakis Vasileios

CONTENTS

CONTENTS.....	2
KEY WORDS	4
ABBREVIATIONS	5
1. INTRODUCTION	6
2. THEORETICAL PART OF THE DISSERTATION THESIS – Contemporary state of the problem: a survey	7
2.1 Dental injuries – categories, description	7
2.2 Epidemiology of dental traumas in children	8
2.3 Etiology of dental injuries in different age groups in children	9
2.4 Factors which can affect the outcome of dental injuries‘ treatment	10
2.5 Occurrence of post-traumatic complications in teeth with closed and in teeth with open root apices	11
2.6 Treatment of periodontal tissue injuries in teeth with open root apices and in teeth with closed root apices	12
2.7 The role and importance of calcium hydroxide in endodontic treatment of teeth with open root apices in periodontal tissue injuries	14
3. AIM OF THIS THESIS	15
4. PRE-CLINICAL PART OF THE DISSERTATION THESIS	17
4.1 Prevention of tooth injuries (questionnaires, posters in primary schools)	17
4.1.1 <i>Materials and methods</i>	17
4.1.2 <i>Results</i>	20
4.1.3 <i>Discussion</i>	22
4.1.4 <i>Conclusion</i>	23
5. CLINICAL PART OF THE DISSERTATION THESIS	24
5.1 Retrospective clinical study of 90 avulsed permanent teeth in 57 children	24
5.1.1 <i>Materials and methods</i>	24
5.1.2 <i>Results</i>	25
5.2 Endodontic intervention in treatment of various types of dental injuries and their complications in immature permanent teeth	30
5.2.1 <i>Materials and methods</i>	31
5.2.2 <i>Results</i>	31
5.3 Discussion	35
5.4 Conclusions	39
6. EXPERIMENTAL PART OF THE STUDY	40
6.1 Experiment 1. „Comparison of pH of various calcium hydroxide materials in vitro“	40
6.1.1 <i>Materials and Methods</i>	40
6.1.2 <i>Results</i>	41
6.2. Experiment 2: “Diffusion of calcium ions from various materials with calcium hydroxide in vitro”	42
6.2.1 <i>Materials and Methods</i>	42
6.2.2 <i>Results</i>	44
6.3 Experiment 3: “Vehicle influence on calcium hydroxide materials` diffusion through dentin, in human teeth”	47
6.3.1 <i>Materials and Methods</i>	47
6.3.2 <i>Results</i>	50
6.4. Experiment 4: “Measurement of dentin hardness in teeth with long-term root canal filling with calcium hydroxide”	53

6.4.1 <i>Materials and methods</i>	53
6.4.2 <i>Results</i>	57
6.5. Experiment 5: “Histological evaluation of dentin hypercalcification after long-term filling of root canal with Calcium Hydroxide”	59
6.5.1 <i>Materials and Methods</i>	59
6.5.2 <i>Results</i>	61
6.6 Discussion	72
6.7 Conclusions	75
7. SUMMARY	76
8. SOUHRN	81
9. LITERATURE	86
10. Author’s publications, presentations, posters relevant with this thesis	99
11. Aknowledgements	103
12. Poděkování	104

KEY WORDS

- ❖ Avulsion
- ❖ Calcium hydroxide
- ❖ Dentin hardness
- ❖ Endodontic treatment
- ❖ Hard dental tissue injuries
- ❖ Immature teeth
- ❖ Mature teeth
- ❖ Periodontal tissue injuries
- ❖ pH / alkalic environment
- ❖ Post-traumatic complications
- ❖ Traumatic dental injuries / Dental trauma

ABBREVIATIONS

➤ Calcium hydroxide	Ca(OH) ₂
➤ Complicated crown fracture	CCf
➤ Dentin hardness	Dh
➤ Extra-oral time interval	EOTi
➤ Immature teeth	IT
➤ Lateral luxation	Ll
➤ Mature teeth	MT
➤ Post-traumatic complications	PTCs
➤ Pulp necrosis	PN
➤ Scanning Electron Microscope	SEM
➤ Storage medium	SM
➤ Traumatic dental injuries	TDIs
➤ Uncomplicated crown fracture	UCCf

1. INTRODUCTION

Dental injuries are the most common results of traumas in the orofacial region of children. They occur mostly in mixed dentitions, in immature permanent teeth and during development of jaws. Due to information in literature (14, 45, 57, 62, 129, 161), 35% of children in the age of 9 years have experienced, at least once, tooth injuries and children suffer accidents most frequently between 8 and 11 years of their age. These accidents often result in dental injuries which can be either injuries of the hard tissues of the teeth (clinical crown or root fractures etc.), or injuries of the periodontal tissues (lateral luxation, intrusive luxation, complete avulsion etc.), or combination of the above injuries. These injuries could be accompanied by injuries to gingiva, oral mucosa, or generally soft tissues and injuries to the supporting bone. The most serious type of injury is the complete avulsion which very often might lead to the loss of the affected tooth.

Accidents occur during usual activities of children, like running, skateboarding, cycling etc. The most frequent causes of dental injuries in children are various sport activities, especially contact sports, and the most frequent places that the accidents occur are homes, sport fields and primary schools.

This dissertation thesis was mainly concentrated on treatment of immature permanent teeth after trauma and especially periodontal tissue injuries and clinical crown fractures. We were concerned mainly on the factors which could influence the outcome of treatment of injured teeth (eg. time interval between injury and treatment, providence of first aid at the place of the injury etc.) and on the treatment outcome itself. In immature permanent teeth that had suffered posttraumatic complications, such as pulp necrosis and chronic periodontitis, contemporary methods of treatment were investigated using calcium hydroxide, a material which is widely used in endodontics and in dental traumatology.

The experimental part of this thesis describes the influence of calcium hydroxide in periradicular environment and on root dentin when it is used as intra-canal dressing, for longer period. The antibacterial effect of calcium hydroxide was examined by measuring the differences in pH values which are caused in periradicular environment by long-term use of this material (e.g. in cases of treatment of immature permanent teeth with necrotic pulp). On the other hand, hypercalcification and changes in root dentin hardness were verified by the use of Scanning Electron Microscope (SEM).

2. THEORETICAL PART OF THE DISSERTATION THESIS – Contemporary state of the problem: a survey

2.1 Dental injuries – categories, description

There are quite a few studies in literature describing and categorizing traumatic dental injuries (17, 64, 88, 92, 103, 183). According to the latest categorization attempts, tooth injuries could be divided into:

A. injuries to hard dental tissues and pulp

The injuries to the hard dental tissues and the pulp could be divided into:

A1. Uncomplicated fractures of the clinical crown of the tooth:

A1a. Enamel infraction: It is not a fracture but a crack on the enamel surface of the tooth, without any loss of tooth substance.

A1b. Enamel fracture: The fracture line is confined only to the enamel. There is loss of enamel tooth substance, without dentin exposure.

A1c. Enamel-dentin fracture: The fracture line is confined only to enamel and dentin, without involving the pulp. There is loss of enamel-dentin tooth substance.

A2. Complicated fractures of the clinical crown of the tooth: The fracture line is confined to enamel and dentin, but there is pulp exposure.

A3. Root fractures: The fracture line is confined to cementum, dentin and pulp. The root fractures are further classified according to the location of the fracture line (cervical, middle or apical third) and according to the displacement direction of the coronal fragment.

A4. Uncomplicated crown-root fracture: This type of fracture involves cementum, enamel and dentin, without pulp exposure.

A5. Complicated crown fracture: This type of fracture involves cementum, enamel and dentin but there is pulp exposure.

B. Injuries to the periodontal tissues

The injuries to the periodontal tissues could be divided into:

B1. Concussion: It is an injury to the tooth supporting tissues (mostly periodontal ligaments), which is not characterised by displacement or loosening of the injured tooth. Percussion pain and mild periodontal space widening are present.

B2. Subluxation: It is an injury to the tooth supporting tissues (mainly periodontal ligaments), characterised by loosening of the injured tooth, pain to percussion, widening of the periodontal space, but no displacement is present.

B3. Extrusive luxation: It is an injury to the tooth supporting tissues (mainly alveolar bone and periodontal ligaments), characterised by loosening of the injured tooth and its partial displacement (extrusion) out of its alveolar socket.

B4. Lateral luxation: It is an injury of the tooth supporting tissues (mainly alveolar bone and periodontal ligaments), characterised by loosening of the injured tooth and its displacement in any direction, other than axially. It could be accompanied by fracture of the alveolar process.

B5. Intrusive luxation: It is an injury of the tooth supporting tissues (mainly alveolar bone and periodontal ligaments), characterised by displacement of the tooth axially, into the alveolar bone.

B6. Avulsion: It is the complete displacement (total exarticulation) of the injured tooth, out of the alveolar socket.

The above injuries could be accompanied by gingival or other soft tissues' injuries, alveolar bone injuries or there could be even combination of the above injuries (eg. uncomplicated crown fracture with concussion). The most serious among the above injuries is the tooth avulsion, since it often leads to loss of the affected tooth (14, 15, 33, 105, 170).

This study will be concentrated mostly on occurrence and treatment of post-traumatic complications in immature permanent teeth and the role of calcium hydroxide use in prevention and treatment of these complications.

2.2 Epidemiology of dental traumas in children

Traumatic dental injuries (TDIs) are the most common results of traumas in the orofacial region of children. They occur mostly in mixed dentitions, and in immature permanent teeth (14, 17).

Findings in the literature (14, 29) show that, in some populations 35 % of boys and 23 % of girls, might be assumed to have sustained damage to their teeth by the age of 14 years. Furthermore, it is stated in a study in Danish population that 30 % of children have sustained dental trauma to their primary dentition and 22 % of children to their permanent dentition, so approximately until the age of 14 years, 50 % of children have experienced, at least once, a

dental injury (14). Generally, children suffer accidents most frequently between 8 and 11 years of age (14, 62, 129, 161).

In many studies in literature (13, 133, 134) is stated that boys experience dental injuries to their permanent dentitions more frequently than girls. The reason for the above is that boys in school age are more active than girls in participation in team sports and contact games.

Accidents that result in dental injuries often occur during typical childhood activities, such as running, skateboarding or cycling. In our own previous studies as well as in other studies found in the literature (98, 120, 181, 184), it has been shown that the most common causes of dental injuries in children are sport activities, especially contact sports, and the most common places that the accidents occur are home, primary schools, sport fields and other public places (47, 62, 165).

2.3 Etiology of dental injuries in different age groups in children

There are various activities that children have which may lead to dental injuries. Studies in literature have proved that children suffer in higher frequency from dental injuries than the adults (14, 29, 62). The main reason is that children, especially in preschool ages, have not yet developed the coordination of body movements and have not perfected their balance, so they are more susceptible to falls which are the most frequent cause for TDIs (40, 43, 62, 165). Another reason is that they are not aware of danger (lack of experience), so they risk with activities that the adults would not risk. Falls could occur on stairs, floor or even on furnitures at home.

In school-aged children and adolescents, very frequent cause of dental injuries is sport activities, especially the contact sports, such as football, hockey, basketball etc. (86, 99). These sports are very popular in developed countries, as well as in the Czech Republic, resulting in increased frequency of traumas, especially in orofacial region. In some countries, as Czech Republic, the use of mouth-guards is not yet quite common and this fact increases the risk of a dental injury to occur.

Other sports that have been recorded to cause dental traumas are cycling, running, horse riding etc.

Frequent causes of dental traumas are various types of playing at playgrounds.

Traffic accidents include bicycling, car and pedestrian accidents and they occur mostly in adolescents or late teenagers. The main reasons are the non-use of helmets for bikers and safety belts for car passengers (78, 126).

Finally, increasing incidence of violence and child abuse seems to be rather frequent and tragic cause of TDIs in children. In developed countries, such as USA, this problem seems to have reached dramatic levels, since in the mid-nineties, almost 3.000.000 children were reported to child protection agencies as victims of physical abuse from their parents (125).

2.4 Factors which can affect the outcome of dental injuries' treatment

The most important factor affecting the treatment outcome is time. All trauma cases should be treated on emergency basis (19, 21); only in that way occurrence of healing complications, such as pulpal and periodontal complications, could be reduced. According to time interval between dental injury incident and treatment and to various treatment stages, dental treatment of TDIs can be categorised into (19, 21, 54, 154):

i) Primary care of dental trauma: this provides the urgent treatment which is required immediately after trauma and could be divided into:

- acute or emergent treatment (within few hours after trauma)
- subacute or urgent treatment (within 24 hours after trauma)
- delayed treatment (after the first 24 hours after trauma)

ii) Secondary phase of treatment: It starts usually two weeks after the primary phase and includes the monitoring of pulpal and periodontal status, healing of soft and hard dental tissues, endodontic treatment, orthodontic therapy etc. And

iii) Tertiary phase of treatment: Commences a few months to few years after the injury and includes the final restoration of a missing tooth, orthodontic treatment etc.

For all dental injuries, the following approaches are recommended (19, 154):

- a) Crown and crown-root fractures: Subacute or delayed treatment
- b) Root fractures: Acute or subacute treatment
- c) Concussion and subluxation: Subacute treatment
- d) Extrusive and lateral luxations: Acute treatment
- e) Intrusive luxation: Subacute approach
- f) Avulsion: Acute approach

In cases of avulsion, critical factor for future prognosis of the replanted tooth is the extra-oral time (EOTi). The shorter the EOTi, the better the prognosis (6, 11, 14, 28, 71, 107, 169, 170). Ideally, the avulsed tooth should be replanted immediately at the place of injury (6, 11, 28).

Another factor which plays important role on the treatment outcome is the storage medium (SM) in cases of tooth avulsion and crown fractures. In cases of avulsion, if the tooth is not replanted immediately at the place of injury, it is recommended to be stored in milk or saliva which has almost the same effect as storage in saline solution (16). In cases of clinical crown fractures, the fragment should be stored in moist environment, until its reattachment; if it is stored in dry conditions, it could get dehydrated and reattachment to the tooth is not indicated (1, 143, 144).

There are SMs which are recommended by some authors, which seem to effect positively the outcome of the treatment. Such solutions could be Hank's Balanced Salt Solution, Gatorade, fluoride solutions and Tooth Rescue Box (containing various salts, amino-acids, vitamins and glucosis) (44, 59, 115, 138, 169, 172).

Finally, factors such as, stage of root development, type and period of splinting after periodontal tissue injuries and root fractures, timing of endodontic intervention whenever is required, use of antibiotics whenever is recommended, patients' behaviour, post-traumatic care and frequent clinical and radiographic controls play important role in treatment outcome.

2.5 Occurrence of post-traumatic complications in teeth with closed and in teeth with open root apices

TDIs require long-term clinical and radiographic controls, since occurrence of post-traumatic complications (PTCs) is frequent and often not predictable. The most frequent, among PTCs, is pulp necrosis (PN) (15, 30, 97). PN occurs after periodontal tissue injuries (lateral, extrusive, intrusive luxations, avulsion injuries) and in cases of untreated uncomplicated crown fractures (UCCf) or complicated crown fractures (CCf) and root fractures. Untreated PN could lead to apical chronic periodontitis, a complication which will require long-term endodontic treatment using calcium hydroxide. PN could also be associated with occurrence of root resorption which is very serious PTC and could lead even to loss of the affected tooth. Obliteration of root canal is also, relatively, frequent PTC; it seems to be related with pulp revascularization after luxation injuries and occurs more frequently in permanent teeth with incomplete root development (15, 30, 97).

All the above complications should be treated on time, soon after they are diagnosed. Endodontics and use of calcium hydroxide as intracanal medicament play important role in treatment of these complications.

In cases of periodontal tissue injuries (especially when there is presence of tooth displacement), there is disruption of the nerve-vessel bundle in the apical area, a fact which leads to high probability of PN occurrence; if tooth is repositioned after luxation injuries or replanted in cases of avulsion soon after the injury, especially in immature teeth with wide open root apices, there is good chance for occurrence of pulp revascularisation (28, 107). In mature teeth, the chance for pulp revascularisation occurrence is significantly weaker (130). So, in mature teeth (MT) there is higher probability for occurrence of PN, but in immature teeth (IT) there is higher chance for pulp revascularisation and eventual root canal obliteration (8).

2.6 Treatment of periodontal tissue injuries in teeth with open root apices and in teeth with closed root apices

Concussion and subluxation are minor periodontal tissue injuries. In concussion injury, no mobility and no displacement of the injured tooth is present, only tenderness to occlusal forces and to percussion tests. In subluxation injuries, the injured tooth is mobile in horizontal direction but no displacement is present and is sensitive to occlusal forces and percussion tests. For the above injuries, in IT and MT, no active treatment is required. Patients are advised to maintain good oral hygiene and consume soft diet, at least for one week period. Occurrence of PTCs as pulp necrosis, especially in IT is rare. Arrested surface root resorption is noticed, though, some time after the injury (8, 34, 144).

Extrusive and lateral luxations are more serious periodontal tissue injuries. In cases of extrusion, the tooth is mobile in all directions and seems elongated and displaced (partially exarticulated) outwards from its alveolar socket (in axial direction). In lateral luxation cases, the tooth is dislocated and mobile. In x-ray pictures there is significant widening of the periodontal space. In both cases, careful repositioning and splinting is required for 2-3 weeks (8, 20, 109, 128).

In IT, in both extrusive and lateral luxation injuries, PN occurs significantly less frequently than in MT; this is because IT have better healing capability than MT (8, 109, 128). In cases of revascularization of the pulp, root canal obliteration occurs very frequently in IT, when in MT revascularization of the pulp is rather uncommon (8, 109, 128). In IT, in lateral luxation injuries, surface root resorption is a frequent finding, but replacement root resorption and infection related root resorption are rather rare (8, 20), when in MT root resorption, in general is significantly more frequent finding.

In general, it is recommended to postpone any endodontic intervention in IT that have suffered extrusive and lateral luxation injuries, since if they are treated properly and on time, there is high chance that pulp vitality of the injured teeth could be saved (8, 10). Even in cases of pulpal damage, there is good chance of pulp revascularization, especially in IT with wide open root apex. Endodontic intervention is recommended only in situations that there is irreversible damage to the pulp, as in PN. In these cases, trepanation and removal of the necrotic tissue from the root canal, effective irrigation and repeatedly filling of the root canal with calcium hydroxide materials are indicated, until apexification is achieved (50, 69, 124, 149).

Intrusive luxation is relatively infrequent dental injury of permanent teeth (22, 156). The intruded tooth is displaced into the alveolar bone along its axis. It is very serious injury of periodontal tissues, accompanied by damage to gingiva, periodontal ligaments and alveolar bone. The intruded teeth are firm (no mobility present), but very sensitive to percussion, which produces metallic sound. If the tooth is fully intruded, it is possible that there is bleeding from the nasal cavity, since the root apex of the intruded tooth could be pushed into the nasal cavity.

For IT, spontaneous re-eruption has always been the choice of primary treatment (2, 8, 22-24). It is a process which could last even up to 6 months. Alternative to this approach is orthodontic extrusion, which is decided if 1-2 months after the injury, there is no sign of tooth re-eruption. For MT, orthodontic extrusion, or surgical reposition is usually the treatment choice.

Frequency of occurrence of PN and inflammatory root resorption is significantly high even in IT; therefore, frequent clinical and radiographic controls are necessary. In cases of PN and inflammatory root resorption, immediate endodontic treatment is indicated comprising the removal of necrotic pulp tissue and repeatedly filling of root canal with calcium hydroxide pastes, until the root resorption is arrested and apexification is achieved.

Finally, avulsion injuries are considered as the most serious dental injuries. In these injuries, tooth is fully exarticulated out of the alveolar socket. Usually, avulsions are accompanied with injuries to the soft tissues (gingiva, lips etc.), alveolar bone fractures and periodontal tissue damages. Replantation of the luxated tooth is the ideal choice of treatment. Critical factor affecting the future prognosis of the replanted tooth is the extra-oral time interval (EOTi) which should be up to 20 min. The avulsed tooth, ideally should be replanted immediately, at the place of the traumatic incidence, after it is rinsed with cold water (6, 11,

28, 45, 52, 71). If the tooth is not replanted immediately, factors such as storage medium and stage of root development will influence the treatment outcome.

In IT which are replanted even until 2-3 hours after the injury, pulp revascularization could be expected (25-27, 71, 100, 107).

2.7 The role and importance of calcium hydroxide in endodontic treatment of teeth with open root apices in periodontal tissue injuries

Calcium Hydroxide ($\text{Ca}(\text{OH})_2$) was firstly induced in dentistry in 1920 by Hermann, who used it as disinfection of the root canal, presenting with good results.

$\text{Ca}(\text{OH})_2$ is widely used in endodontics as root canal medicament because of its beneficial properties, such as: 1. antibacterial effect, 2. induction of hard tissue formation, 3. bleeding and exudation control, 4. antiresorptive effect, 5. biocompatibility and 6. easy application into the root canal (5, 49, 53, 80, 174).

In endodontics $\text{Ca}(\text{OH})_2$ is used as direct and indirect pulp capping [In 1929, Hess introduced $\text{Ca}(\text{OH})_2$ as material indicated for covering the pulp after pulpotomy treatment (91)] and as root canal sealer. It is also used as root canal dressing for short term (eg. in cases of bleeding or exudation from the root canal, as dressing between appointments) or for long term (for apexogenesis and apexification, in cases of acute and chronic periodontitis and of large periapical lesions, for prevention and treatment of root resorption, in root fractures etc).

In treatment of PTCs in permanent teeth of children, $\text{Ca}(\text{OH})_2$ is the root canal dressing of our choice, especially in root fractures, in complicated clinical crown fractures and in periodontal tissue injuries, like avulsion, lateral and extrusive luxation. In the root canal, $\text{Ca}(\text{OH})_2$ dissociates into calcium and hydroxyl ions, the environment becomes highly alkaline, thus antibacterial, since the hydroxyl ions enhance the formation of an alkaline medium, which is responsible for the destruction of bacterial cell-membrane lipoproteins (67, 72, 80, 153).

Endodontic treatment in IT with wide open apices is difficult, especially in drying and obturating adequately the root canal and in removing the infected root dentin from the root walls. For many years, $\text{Ca}(\text{OH})_2$ is suggested as the material for treating non-vital IT. Nowadays $\text{Ca}(\text{OH})_2$ is the most commonly used material, indicated as root canal dressing in treatment of IT, having favorable results (89, 113, 149). $\text{Ca}(\text{OH})_2$ is indicated for treatment of infected root canals and periradicular tissues, for arresting of infection related root resorption and for formation of an apical hard tissue barrier (apexification), which will enhance future root canal obturation (46, 112, 157).

3. AIM OF THIS THESIS

This dissertation thesis consists of three major parts: 1) pre-clinical, 2) clinical and 3) experimental part.

1) The aim of the pre-clinical study of the thesis was to evaluate the efficiency of primary school teachers' knowledge on how to provide adequately first aid in case of tooth avulsion injury, the most serious among all dental injuries. Determining factors for prevention of PTCs occurrence are the immediate providence of effective first aid and fast transfer of child to dental office for treatment. If dental injuries are not treated on time, the the PTCs that might occur, could lead even to loss of the injured tooth.

2) The aims of the clinical part of the dissertation thesis were:

- a) to find out the most frequent causes and mechanisms leading to avulsion of permanent teeth,
- b) to determine the frequency of tooth replantation in cases of avulsion,
- c) to specify the most frequently used storage mediums and the extraoral time,
- d) to analyse any healing events which will require endodontic treatment with the use of calcium hydroxide, focusing mostly on the type of root resorption of the replanted teeth,
- e) to analyze possible post-traumatic complications' occurrence in immature permanent teeth,
- f) to compare post-traumatic complications occurring in immature teeth and mature teeth and
- g) to state the differences in endodontic treatment approach in immature teeth and mature teeth

3) The aims of the experimental part of the thesis were:

- a) **Experiment 1:** To measure and compare in vitro the pH of various $\text{Ca}(\text{OH})_2$ materials which are used as intracanal medicaments in Dentistry department of Faculty of Medicine and Faculty hospital in Pilsen, so to estimate the alkaline properties of each material.
- b) **Experiment 2:** To analyze the ability of various $\text{Ca}(\text{OH})_2$ materials to release calcium and hydroxyl ions and to find out if the vehicles used in $\text{Ca}(\text{OH})_2$ preparations play a role in the diffusion of the above ions, in vitro. The results were statistically analysed.
- c) **Experiment 3:** i) To compare in vitro the calcium ion diffusion (through the exposed dentin tubules) of various $\text{Ca}(\text{OH})_2$ materials, ii) to measure the extra-radicular pH changes, caused by the use of these $\text{Ca}(\text{OH})_2$ materials as intracanal dressings in human teeth. The results were statistically analysed.

d) Experiment 4: To measure the root dentin micro-hardness in vitro, after long-term use of Ca(OH)_2 as intra-canal medicament and evaluate the differences of dentin hardness (Dh) after the use of various Ca(OH)_2 preparations. The measurements of Dh were statistically analysed and compared.

e) Experiment 5: Based on limited findings in literature (32, 75, 158), we performed a microscopic study of root dentin. The aim of this study was to observe (in vitro) in Scanning Electron Microscope (SEM) the root dentin after long-term use of Ca(OH)_2 , as intracanal dressing and subsequently to compare teeth, filled with Ca(OH)_2 and teeth without any root canal filling.

Furthermore, with the help of SEM, to compare the calcium weight percentage of root dentin, in teeth that had been previously filled with Ca(OH)_2 and teeth without any root filling.

4. PRE-CLINICAL PART OF THE DISSERTATION THESIS

4.1 Prevention of tooth injuries (questionnaires, posters in primary schools)

Dental injuries in children are rather common during sport activities and at schools, where they spend most of their time every day (3, 17, 108). It has been stated in many studies in literature that tooth injuries occur mostly in young ages, especially in school children, when children develop various physical activities (12, 14, 29, 42, 62, 129, 140, 161). It has been also noted that 1/3 of children population between 8 and 11 years old has already experienced a dental injury (33, 81, 121, 178). These injuries occur mostly in schools, sport and playing fields and at home.

4.1.1 Materials and methods

A simple questionnaire was prepared, containing 9 questions about tooth avulsion. The definition of avulsion was included at the top of the questionnaire (Fig. 1).

For each question, there were two to seven possible responses, from which the teachers could choose one or more. 350 questionnaires were distributed in 9 randomly-chosen primary schools, in Pilsen, Czech Republic, to 300 teachers who were asked to complete and return them within one week. A short letter on the reverse side of the questionnaires contained instructions and provided our contact information, in case that respondents would have any questions.

Subsequently, we prepared posters which were distributed in most of the primary schools in the Czech Republic; the posters contained information about how teachers should react and behave in cases of permanent tooth avulsion (Fig. 2).

„Avulsion is defined as the traumatic knock-out of the tooth from the alveolar socket, as a result of an injury“

Questionnaire

1.	Have you ever received any information about providing first aid in cases of dental injuries?	<input type="checkbox"/> Yes	<input type="checkbox"/> No	1.
2.	If yes, mention the source of the information			2.
	a. Courses of first aid			
	b. Education in pedagogic faculty			
	c. Dentist			
	d. Other sources			
3.	Have you ever heard the term „avulsion of tooth“?	<input type="checkbox"/> Yes	<input type="checkbox"/> No	3.
4.	Have you ever met with avulsion in your school? If „yes“, please mention how many times	<input type="checkbox"/> Yes <input type="checkbox"/>	<input type="checkbox"/> No	4.
5.	Describe the situation that resulted in avulsion			5.
	a. During sport activities (running, football, etc.)			
	b. Falls during walking or playing			
	c. As a result of an impact of an object in the oral area			
	d. Due to a conflict between students			
	e. Other			
6.	What was your immediate reaction after the incident?			6.
	a. I immediately informed the child's family			
	b. I arranged at once the transfer of the child to a dentist			
	c. I left the child at school, since it was not a serious injury			
	d. I arranged at once the transfer of the child to his/her home			
7.	If you have never experienced such a situation, what would you do in a case of an injury which would result in avulsion of a tooth?			7.
	a. I would inform the family and immediately arrange the transfer of the child to a dentist			
	b. I would inform the family and immediately arrange the transfer of the child to his/her home			
	c. If the only injury would be avulsion of a tooth and no other more serious trauma would be present, I would leave the child at school			
	d. I would inform the director of the school and let him/her decide about any possible steps which should be taken or not			
	e. I would contact by phone a dentist, inform him about the incidence and listen to his/her advice			
8.	What would you do with the avulsed tooth, if it would be found?			8.
	a. I would throw it out since it would be dirty and infected			
	b. I would rub it, so that to clean the dirt out of it			
	c. I would wash it with tap water			
	d. I would place it in a clean handkerchief or gauze			
	e. I would place it into milk			
	f. I would place it in physiologic solution			
	g. I would place it in desinfectant solution			
9.	If you would find the tooth, how would you hold it?			9.
	a. From the clinical crown			
	b. From the root			
	c. Anyhow – it does not make any difference			

✓for positive answers, please use tick or circle the letter before each answer

Thank you very much for filling this questionnaire.

FIG. 1 QUESTIONNAIRE FORM



Podle doporučení AAЕ (American Association of Endodontists) zpracovali:
 Doc. MUDr. Vlasta Merglová, CSc., MUDr. Vladimír Trzlgounák / Stomatologická klinika LF a FN Píseň

PREVENT THE TOOTH INJURIES IN CHILDREN

With the use of sport mouth-guards

During contact sports (basketball, handball, football etc.) and other sports (cycling, skateboarding etc.), it is possible to prevent dental injuries or -at least- decrease the traumatic incidences, by the use of sport mouth-guards.

By providing first aid

By correct providence of first aid, it is possible even to save the tooth which was knocked out from its socket.

In the case that a permanent tooth of a child is knocked out, please remain calm and pursue the following, simple procedure:

◆ **Find the knocked out tooth** Do not touch the root of the tooth. Hold the tooth from its crown. Do not rub the dirt out of the tooth and do not place it into disinfection solution.

◆ **First the tooth** should be rinsed with milk or cold water and then carefully should be placed to its socket.

◆ **The tooth should be immobilized** in a way that the child is biting gently to a handkerchief.

◆ **Immediately after, transfer the child to the closest dental clinician.**

If for some reason it is not possible to replace the expelled tooth to its socket: ◆ Use physiologic solution or even milk for placement of the expelled tooth ◆ Do not let the tooth to dry ◆ Do not use as a storage medium disinfection solution ◆ Immediately transfer the child and the knocked tooth to a dentist

On time visit to dentist

The visit to the dentist on the right time (as soon as possible after the injury) is extremely important in all cases of dental injuries. With the immediate transfer of the child we can prevent future unpleasant complications which require long-term treatment and which could lead even to the loss of the affected tooth



WWW.ZDRAVEZUBY.CZ



Foto a sazba: Jitka Zahrádka, www.foto-zahradka.cz

FIG. 2 POSTER DISTRIBUTED TO PRIMARY SCHOOLS

4.1.2 Results

74 % of teachers filled out the questionnaire.

69 % of respondents who replied had never received any information about providing first aid in cases of dental injuries.

34 % had not heard the term “avulsion” of tooth, 20 % had had experience with dental avulsion in the school and some of them more than once.

The most common cause of dental avulsion, according to respondents, was some kind of sport activity, such as running, football or hockey (63 % of the cases). The second most common cause was an impact to the oral cavity with an object (18 %), and the third cause was injury during playing or walking (9 %).

83 % of respondents answered that they would immediately arrange for the transfer of the child to the dentist and inform the parents.

81 % of respondents would keep the avulsed tooth in a dry handkerchief or in any available clean, dry medium, until the child was transferred to the dental office. 2 % would choose to put the tooth in saline solution and 4 % would place the tooth into milk.

The results are presented in (Table 1).

Number of question	Questions and possible answers	No. of answers	Percentage (%)
1	Have you ever received any information about providing first aid in cases of dental injuries?	220	100
	Yes	68	30,9
	No	152	69,1
2	If yes, mention the source of information	64	100
	Courses of first aid	19	29,7
	Education in pedagogic faculty	21	32,8
	Dentist	17	26,6
	Other sources	22	34,4
3	Have you ever heard the term “avulsion of tooth”?	220	100
	Yes	146	66,4
	No	74	33,6
4	Have you ever met with avulsion in your school?	219	100
	Yes	44	20,1
	No	175	79,9
5	Describe the situation that resulted in avulsion	56	100
	During sport activities (running, football, etc.)	35	62,5
	Falls during walking or playing	5	8,9
	As a result of an impact of an object in the oral area	10	17,9
	Due to a conflict between students	4	7,1
	Other	2	3,6
6	What was your immediate reaction after the incident?	58	100
	I immediately informed the child’s family	25	43,1
	I arranged at once the transfer of the child to the dentist	27	46,6
	I left the child at school since it was not a serious injury	0	0
	I arranged at once the transfer of the child to his/her home	6	10,3
7	If you have never experienced such a situation, what would you do in a case of an injury which would result in avulsion of the tooth?	217	100
	I would inform the family and immediately arrange the transfer of the child to a dentist	179	82,5
	I would inform the family and immediately arrange the transfer of the child to his/her home	19	8,7
	If the only injury was avulsion of a tooth and no other more serious trauma would be present, I would leave the child at school	0	0
	I would inform the director and let him/her decide about any possible steps which should be taken or not	3	1,4
	I would contact by phone a dentist, inform him/her about the incidence and listen to his/her advice	16	7,4
8	What would you do with the avulsed tooth, if it would be found?	233	100
	I would throw it out since it would be dirty and infected	5	2,1
	I would rub it, so that to clean the dirt out of it	4	1,7
	I would wash it with tap water	15	6,4
	I would place it in a clean handkerchief or gauze	188	80,7
	I would place it into milk	10	4,3
	I would place it into physiologic solution	5	2,1
I would place it into disinfectant solution	6	2,6	
9	If you would find the tooth, how would you hold it?	217	100
	From the clinical crown	202	93,1
	From the root	4	1,8
	Anyhow - it does not make any difference	11	5,1

TABLE 1 QUESTIONNAIRE RESULTS

4.1.3 Discussion

Especially in avulsion injuries of permanent teeth, immediate replantation or fast transfer of child and avulsed tooth (which should be stored in proper medium) to a dentist, are determining factors for the future prognosis of the affected tooth, since prolonged extra-oral storage of tooth will worsen the treatment outcome (16, 44, 56, 58, 59, 87, 170). Due to our experience (170), immediate replantation of the avulsed tooth is extremely rare, and this is the reason that this answer was not used among options in this questionnaire. In similar studies in other countries, at least 75 % of the people who were asked would not even think that such a choice could be possible (33).

The results of this study concerning knowledge of primary school teachers on how to behave in dental trauma situations, confirm the data in the literature (33, 37). More specifically it was confirmed that most of primary school teachers would put the avulsed tooth in a dry handkerchief until the transfer to the dentist. 1/3 of teachers had never heard the medical term “avulsion” before we gave them the questionnaires. It was concluded that teachers of primary schools are inadequately informed on how to provide first aid in cases of dental avulsion and apparently other dental injuries, a conclusion which was common in most of similar studies that took place in other countries (37, 101, 136).

Especially for avulsion injuries, the knocked-out tooth should be ideally replanted immediately at the injury place; if replantation though, is realized within 20 minutes from the time of injury and if the luxated tooth is not stored in dry environment (but instead in saline solution or in milk) until it is replanted, then prognosis could be quite promising (104, 170, 171) and the risk of occurrence of future PTCs, such as PN, obliteration of root canal, infection related root resorption, ankylosis, or even premature loss of the affected tooth with consequent inclination of the neighbouring teeth, could be significantly decreased. Therefore, persistent effort of dental practitioners to communicate and inform primary school teachers and sport trainers is important and necessary (137).

4.1.4 Conclusion

In the Czech Republic, primary school teachers have inadequate knowledge concerning dental injuries and their consequences. This fact demands a better communication between dental practitioners, primary school teachers and in general all professionals who are in regular contact with children. Correct behaviour, not only might support the prevention of dental traumas, but in advance may minimize the risk of occurrence of future post-traumatic complications. It is in dental practitioners' hands to persuade the elementary school teachers and other professionals for the importance to try to minimize the incidences of tooth injuries which may lead to irreversible situations, such as a loss of a permanent tooth. In addition, it is required an effort from all professionals to improve their knowledge, in order to be more effective when they will have to deal with childrens' dental traumas.

➤ *The results of the above study was published in Journal Dental Traumatology (175).*

5. CLINICAL PART OF THE DISSERTATION THESIS

5.1 Retrospective clinical study of 90 avulsed permanent teeth in 57 children

During tooth avulsion, apart from the cement of the root, the neighbouring tissues are affected also, and more specifically the periodontal ligaments, the nerves and vessels in the apical area of the root, the gingiva and the alveolar bone (13, 14, 16). IT are the most affected teeth. Avulsion is the most serious dental trauma which often results in loss of the injured tooth. The treatment outcome, as well as the occurrence of PTCs depend mostly on the time interval between the traumatic incident and the type of dental treatment. The tooth should be replanted immediately or maximum up to 20-30 minutes after the injury (11, 19, 21, 28, 38, 170). Treatment outcome also depends on the transport medium that the avulsed tooth was stored until the visit to the dentist (16, 44, 59, 115, 138, 169, 172).

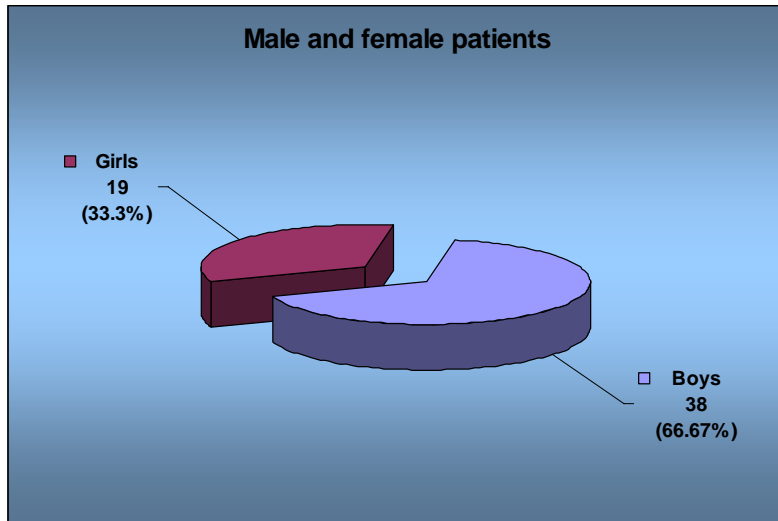
5.1.1 Materials and methods

We analysed 57 young patients' records in their documentations. These patients were treated in Dentistry department of Medical faculty in Pilsen, for avulsion of their permanent teeth, in the years between 1995 and 2005. From these records, the age of children at injury time, the type and number of the avulsed teeth and the type of treatment were established. Moreover occurrence of PTCs, especially various types of resorption of the root were analysed.

5.1.2 Results

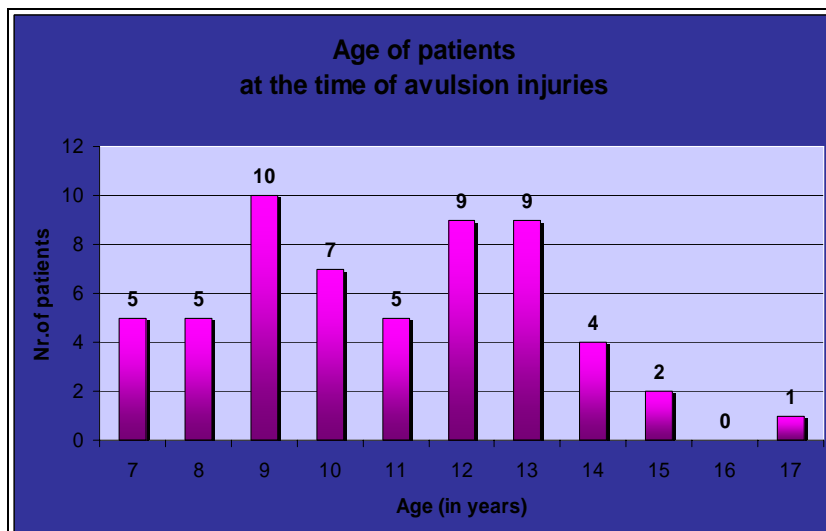
- Age and sex of patients at the time of injury

57 patients had 90 avulsed teeth. Out of 57 patients, 38 (67 %) were boys and 19 (33 %) were girls (Graph 1).



GRAPH 1 SEX PREVALENCE IN CHILDREN WITH AVULSION INJURIES

The group of patients of this study included children between 7 and 17 years old. The most frequent ages were between 7 and 12 years (41 children or 72 %). A total of 27 (47.4 %) children belonged to the age category between 8 and 11 (Graph 2).



GRAPH 2 AGE OF PATIENTS AT THE TIME OF THE AVULSION INJURY

- Type and number of avulsed teeth

57 children had a total of 90 avulsed teeth. 42 (74 %) had only one tooth avulsed, 10 (17 %) had two teeth avulsed and the remaining 5 (9 %) patients had more than two teeth avulsed. In one of these cases a young boy 9 years old avulsed all his upper and lower incisors and a lower right canine after fall against a metal object (Fig. 3). 51 out of 90 (57 %) avulsed teeth were upper central incisors. Totally 74 (82 %) out of 90 were upper teeth and only 16 (18 %) were lower.

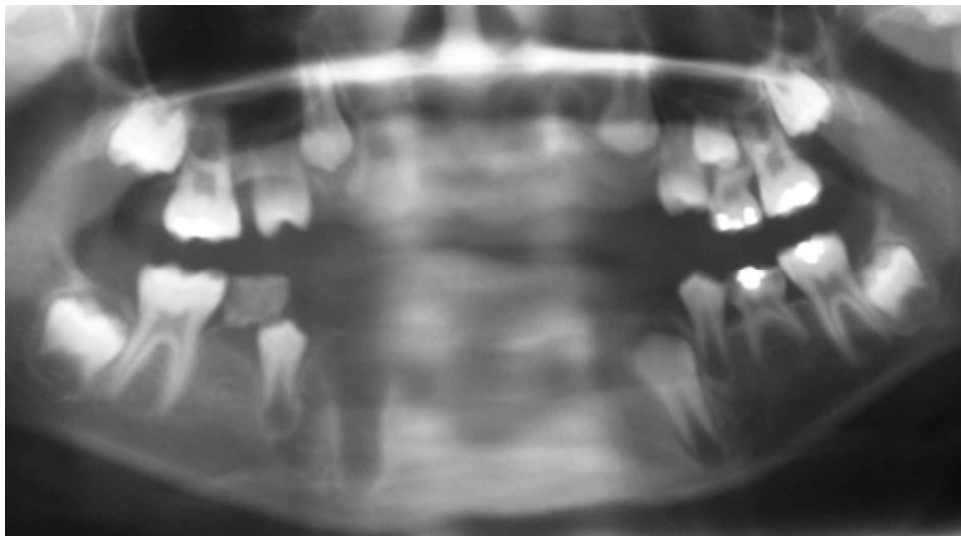
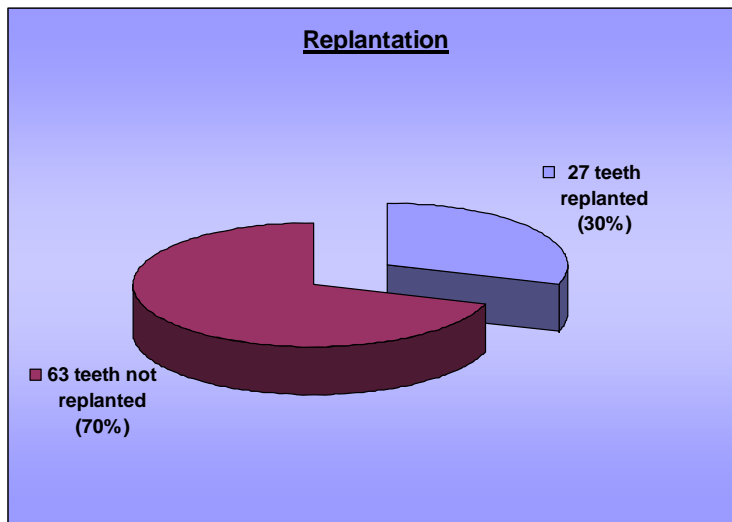


FIG. 3 PANORAMIC X-RAY OF A 9 YEAR OLD BOY, WITH AVULSION OF 9 PERMANENT TEETH AFTER FALLING ON HIS FACE TO A METAL PIPE

- Type of treatment

26 (46 %) of these patients were treated with replantation of the avulsed teeth. In one of these cases, a young boy immediately replanted the avulsed tooth at the place of the accident. Only in one case we replanted 2 teeth. One tooth was treated with definite endodontic filling extraorally before its replantation, 12 hours after the injury.

31 (54 %) of our patients were treated without replantation, either because the avulsed teeth were not found, or because they visited the Dentistry department long after the traumatic incident, or finally because they were hospitalized for more serious injuries. So, out of 90 avulsed teeth of this study, only 27 (30 %) were replanted (Graph 3).



GRAPH 3 TYPE OF TREATMENT

- Transport medium for the avulsed teeth

In 11 out of 27 (41 %) replanted teeth, we could not determine from the records the transport medium that the avulsed tooth was stored until the patient visited the Dentistry department for treatment. 9 (33 %) were stored in dry media, like dry handkerchief, 2 (7 %) in saline, 2 (7 %) in a wet towel and 1 (4 %) in solution with local antibiotics. One patient kept the avulsed tooth in his oral cavity until the visit to the Dentistry department and another one replanted the tooth himself immediately after the accident. Finally one tooth (4 %) was stored in milk (Table 2).

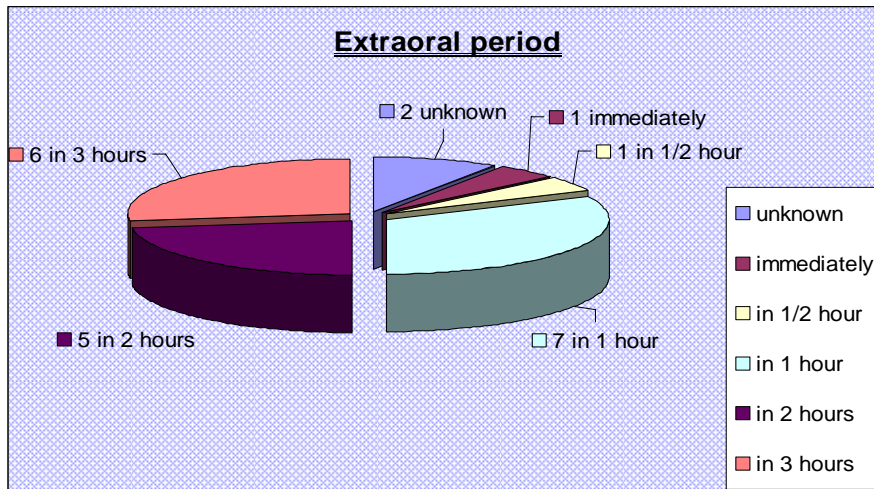
27 teeth replanted		
Transport medium type	Number of teeth	In %
Unknown	11	40,7
Saline solution	2	7,4
Dry media	9	33,3
Wet towel or handkerchief	2	7,4
Solution of Framykoin	1	3,7
In oral cavity	1	3,7
Replanted immediately	1	3,7
Total	27	100

TABLE 2 TRANSPORT MEDIA OF THE AVULSED TEETH

- Extraoral period

One patient replanted the avulsed tooth at the place of the accident and in one case the tooth was replanted in Dentistry department 1/2 hour after the injury. 7 of the children were transferred to the dental office in one hour, 11 of them between one and three hours, and 4 of

them in more than three hours after the traumatic incident. In two cases, the extraoral period of the avulsed teeth could not be traced (Graph 4).



GRAPH 4 EXTRAORAL PERIOD OF THE AVULSED TOOTH

- Splinting and endodontic treatment

After replantation a splint (for immobilization of the injured teeth) was always used. The avulsed teeth were splinted for a period up to two weeks. Endodontic treatment of replanted teeth comprised extirpation of the necrotic pulp and the filling of the root canal with Ca(OH)_2 in 23 cases. One tooth was filled endodontically before replantation and for one of the replanted teeth we have no further information, since the patient did not continue his treatment in our department. We noticed pulp revascularization after replantation of IT in two cases. These two teeth were then presented with partial root canal obliteration and were treated endodontically.

- Treatment and healing of immature teeth

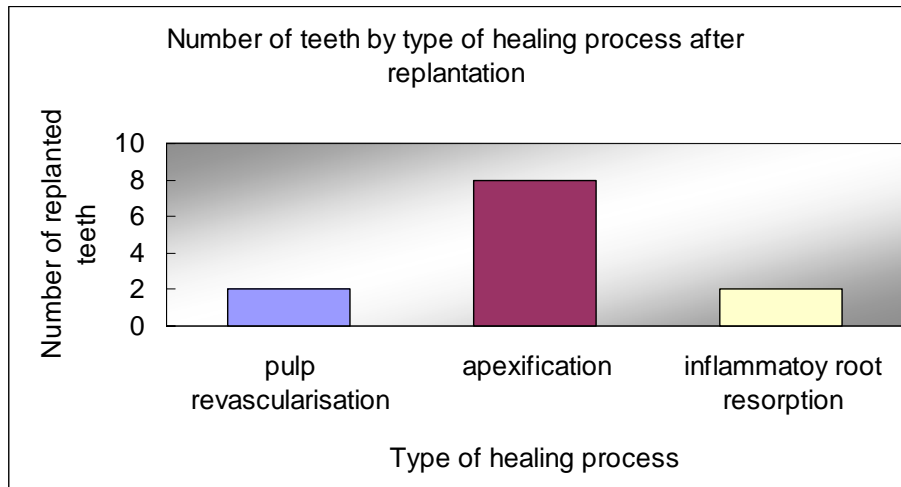
10 out of 12 IT were endodontically treated repeatedly and for long-term with Ca(OH)_2 (apexification) (Graph 5).

-In 8 of them apical barrier was formed.

-In two cases, pulp revascularisation occurred and subsequent partial pulp canal obliteration was diagnosed some time after the injury.

-Two replanted immature teeth had to be extracted because of late diagnosis of infection related root resorption.

Prolonged extra-oral period and storage of the avulsed tooth in improper storage medium until tooth replantation influence the outcome of treatment and increase the risk for occurrence of PTCs.



GRAPH 5 TYPE OF HEALING IN REPLANTED IMMATURE TEETH

5.2 Endodontic intervention in treatment of various types of dental injuries and their complications in immature permanent teeth

This clinical study describes the occurrence of post-traumatic complications in immature teeth and mature teeth after lateral luxation injuries, complicated and uncomplicated clinical crown fractures. The choice of treatment of dental injuries depends on factors such as level of root development, degree of destruction of dental tissues and possible bacterial contamination of the pulp from the oral cavity. The above factors influence the occurrence of complications which may appear weeks, months or even years after the injury. This is the reason that dental injuries require long-term clinical and radiographic controls. The most frequent PTC is pulp necrosis which might lead to further complications, such as gangrene and later chronic periodontitis (15, 30, 97). Other possible complications are external and internal root resorptions and root canal obliteration. Endodontics play important role in prevention and treatment of the above PTCs. Especially in IT, treatment of pulp necrosis and infection related root resorption includes endodontic intervention with Ca(OH)_2 (as intracanal dressing), since definite obturation of the root canal with sealer and guttapercha could be impossible, without formation of mineralized apical barrier (apexification). Ca(OH)_2 has been used for many years for apexification in IT, since it has been presenting with very good results (16, 50, 74, 89, 102, 122, 139, 166, 169).

5.2.1 Materials and methods

A retrospective clinical study was conducted, containing 178 patients with 383 injured permanent teeth. This study was focused on 300 out of 383 teeth which had suffered lateral luxation (LI) injuries and complicated and uncomplicated crown fractures.

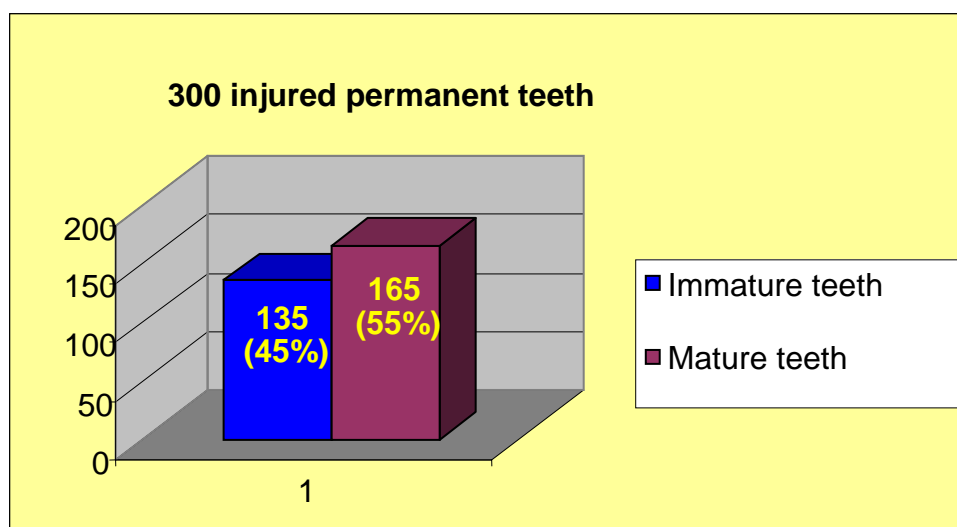
These patients were treated in period 1995-2005 in Dentistry department of Faculty hospital and Faculty of Medicine in Pilsen. The records in the documentations of patients were analyzed mostly from the point of identification of post-traumatic complications' occurrence. The type of PTCs occurring after each tooth injury was issued and compared in immature and mature teeth, always for a specific type of injury. Subsequently, from the records in patients' documentations the use of endodontic treatment after post-traumatic complications occurrence in each injury was analysed.

5.2.2 Results

- Post-traumatic complications occurrence in teeth with unfinished root development

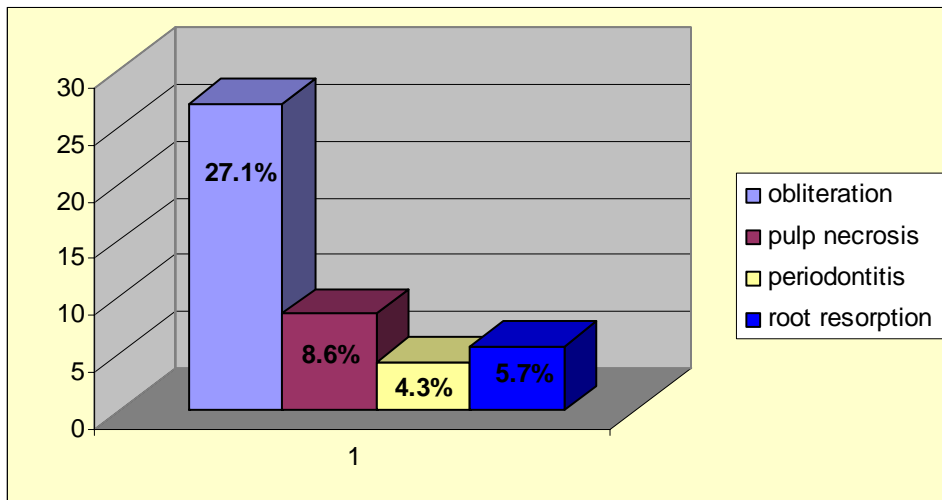
- Out of 383 injured permanent teeth, 300 had LI injury and CCf and UCCf.

Out of 300 injured permanent teeth, 135 were IT and 165 were MT (Graph 6).



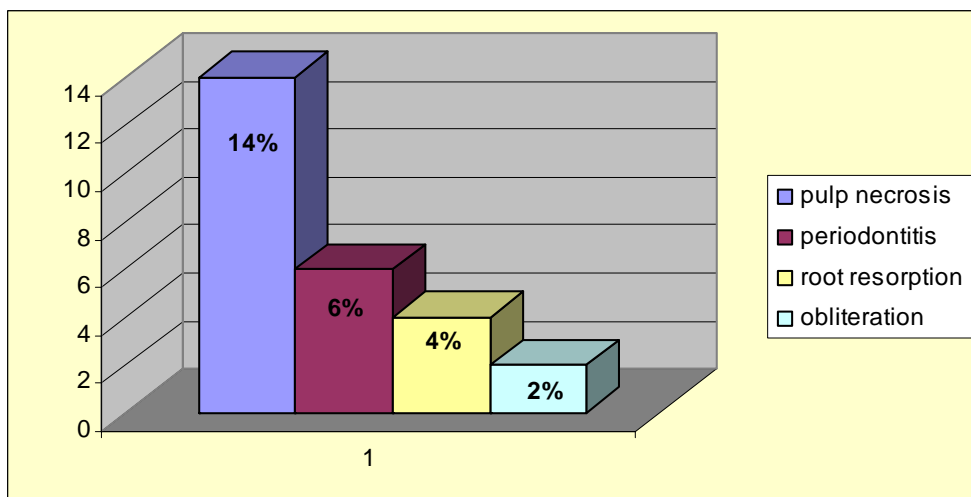
GRAPH 6 RELATION BETWEEN IMMATURE AND MATURE TEETH IN A TOTAL OF 300 INJURED TEETH

- In 70 IT teeth with LI diagnosis, the most frequent PTC was root canal obliteration (in 19 cases, 27,1 %) and PN (in 6 cases, 8,6 %). PN occurred relatively infrequently, since, most probably, subluxations were included in LI injuries (Graph 7).



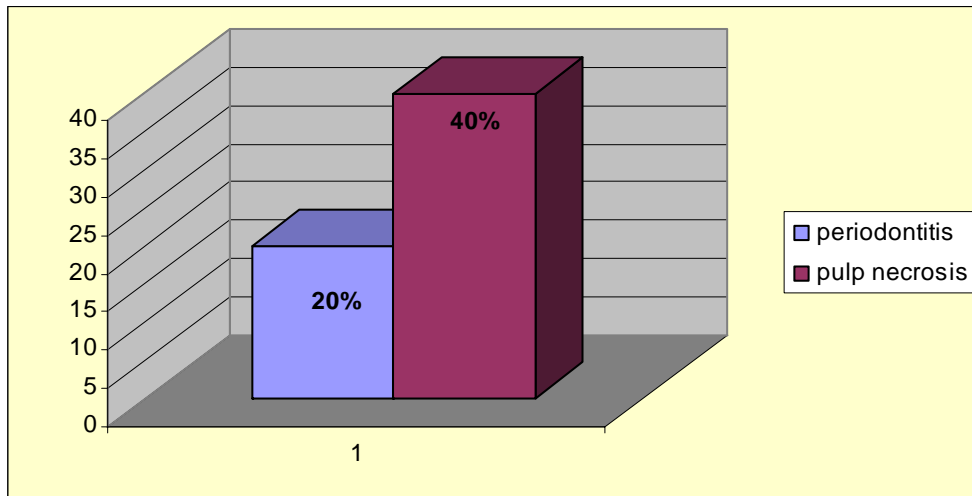
GRAPH 7 POST-TRAUMATIC COMPLICATIONS' OCCURRENCE IN IMMATURE TEETH, AFTER LATERAL LUXATION INJURIES

- In 50 UCCf in IT, the most frequent post-traumatic complication was PN (7 cases, 14 %) which was always treated endodontically (Graph 8).



GRAPH 8 POST-TRAUMATIC COMPLICATIONS' OCCURRENCE IN IMMATURE TEETH, AFTER UNCOMPLICATED CROWN FRACTURE INJURIES

- Out of 15 cases of CCf in IT, 6 were treated with pulpotomy (in 3 of them periodontitis occurred) (Graph 9).



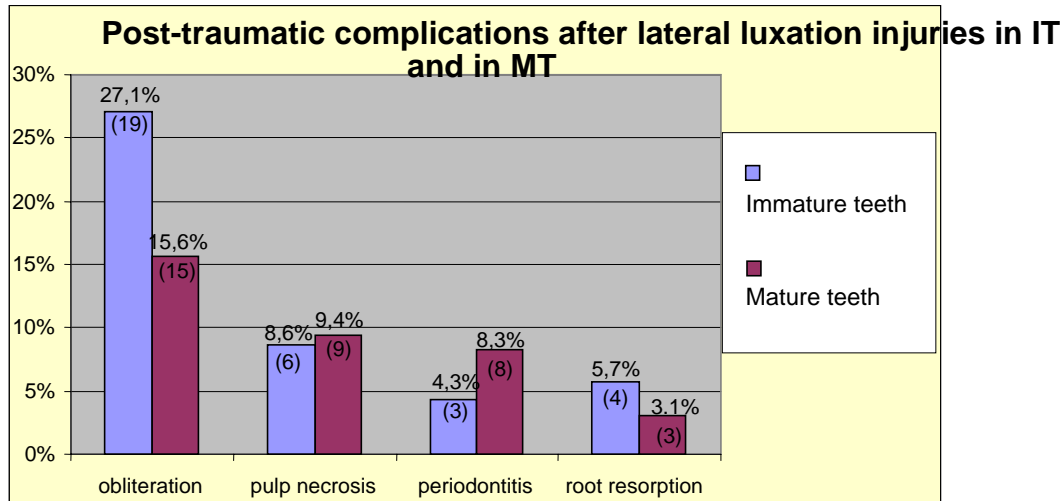
GRAPH 9 POST-TRAUMATIC COMPLICATIONS' OCCURRENCE IN IMMATURE TEETH, AFTER COMPLICATED CROWN FRACTURE INJURIES

- No complications occurred in 15 out of 18 similar cases in MT which were treated with standard endodontic therapy.

- Comparison of post-traumatic complications occurrence between MT and IT after the same injuries

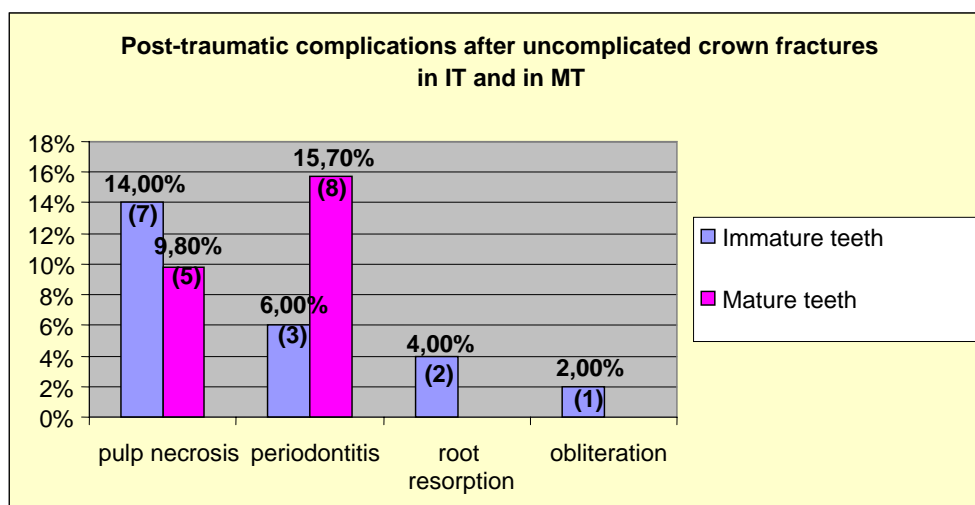
The comparison of post-traumatic complications occurrence between MT and IT revealed differences in each type of dental injury:

- In LI injuries, in IT, root canal obliteration occurred in 27.10 % of cases; in MT, occurred in 15.60 % of cases (Graph 10).



GRAPH 10 COMPARISON OF POST-TRAUMATIC COMPLICATIONS AFTER LATERAL LUXATION INJURIES, BETWEEN IMMATURE AND MATURE TEETH

- In UCCf injuries, in IT pulp necrosis and chronic periodontitis occurred in a total of 20 % of cases but in MT, pulp necrosis and chronic periodontitis occurred in a total of 25.5 % of cases (Graph 11).



GRAPH 11 COMPARISON OF POST-TRAUMATIC COMPLICATIONS, AFTER UNCOMPLICATED CROWN FRACTURES, IN IMMATURE AND MATURE TEETH

5.3 Discussion

We chose to perform retrospective study on avulsion injury, since it is considered as the most serious periodontal tissue injury, leading often to loss of the injured tooth. Treatment of avulsion injury in immature teeth could be quite complicated. According to „Guidelines for the management of traumatic dental injuries. II. Avulsion of permanent teeth“ and „Recommended guidelines of the American Association of Endodontists“ (4, 71), treatment of IT is primarily dependant on the time interval between the traumatic incident and tooth replantation (11, 16, 28, 38, 170). If the tooth is replanted until one hour after the injury and is stored into a proper medium, it should be immobilised and being followed-up regularly and for long-term. No endodontic intervention is indicated, until signs of infection of root canal are obvious (e.g. periapical radiolucency seen radiographically) and in these cases, root canal treatment with $\text{Ca}(\text{OH})_2$ will be required. In cases that the avulsed IT are replanted more than one hour after the injury and are stored in innappropriate medium, endodontic treatment is indicated prior to replantation through the open root apex, then replantation and immobilization for 4 weeks (16, 71). In cases of replantation of MT, endodontic treatment is initiated, even before the splinting removal.

Avulsion of teeth occurs more frequently in ages between 7 and 11 years old (14, 45, 57, 62, 129, 161, 184). In our study 56% of the patients belonged to that age category. Our results confirm the data in the literature, since 67% of our patients were boys and only 33% were girls, so the ratio boys / girls was equal to 2 : 1 (13, 56, 133, 134, 169, 184).

In our study, like in all studies in the literature (38, 56, 152, 156, 181) the most frequent affected teeth are the upper central incisors and in most of the cases dental avulsion is accompanied with other injuries, like injuries of the neighbouring soft tissues, alveolar bone etc.

Important factors for a successful replantation is the transport medium (90) in which the avulsed tooth is stored until the transport of the child to the dentist and the extraoral time interval (11, 15, 16, 19, 21, 28, 38, 44, 59, 69, 71, 115, 118, 138, 169, 170, 172). EOTi is the time duration between the traumatic avulsion of the tooth until its replantation and it should be up to 20 – 30 minutes (11, 19, 21, 28, 38, 170). In our study, only one tooth was replanted 30 minutes after the injury and in one case the child replanted the tooth itself at the place of the accident. Various SMs have been suggested in literature, such as Hanks Balanced Solution, Tooth Rescue Boxes, Fluoride solutions, etc. (44, 59, 115, 138, 169, 172). Saline solution or milk can be used as SMs with relatively good results (16). In the Czech Republic,

there are no SMs available in the market, so we suggest that the avulsed tooth, if not replanted immediately, should be stored into milk, saline solution or into the patients' saliva until transfer to dentist.

After replantation, semi-rigid splinting of the tooth is suggested for up to 2 weeks (7, 14, 16, 71). In Dentistry department in Pilsen we splinted the teeth for two weeks in most of the cases. Prolongation of splinting may lead to ankylosis (104). It is always on the benefit of the patient to provide tetanus prophylaxis, prescribe antibiotics and analgetics, mouth rinses with 0.12% chlorhexidine digluconate solution and finally advise the patient to have good oral hygiene and use soft diet (16, 51, 84).

For MT, we performed endodontic therapy, two weeks after the injury, in order to decrease the risk of future appearance of infection related root resorption (4, 71, 116, 146, 169). In cases of avulsed IT, we should wait before proceeding to endodontic treatment, because if the tooth is replanted until one hour after the injury, we could expect pulp revascularization, which in the future x-ray controls will be verified by continuation of root development of the replanted tooth. Endodontic treatment should be performed only when clinical and x-ray controls of the IT indicate a necrotic pulp (16, 25-27, 71, 100, 107, 170). In this case, the long-term use of $\text{Ca}(\text{OH})_2$ is indicated. The root canal should be repeatedly filled with $\text{Ca}(\text{OH})_2$ pastes, until a mineralization barrier close to the apex of the root canal appears (apexification), a fact which will enhance the future definite filling of the root canal (16, 50, 74, 89, 102, 122, 139, 166, 167).

The type of healing of the replanted tooth depends on the reaction of the periodontium and the pulp to replantation (25, 104, 114). Superficial resorption is considered to be the most favourable type of healing and is due to mechanical injury of the periodontal ligaments and the superficial layer of the cement of the root during avulsion injury. Replacement resorption or ankylosis appears in teeth that their periodontal ligaments have dried, have been destructed or removed from the surface of the root (16, 30, 69). Usually this type of resorption can be seen during radiographic controls, two months, or even later, after replantation. Apart from that, sometimes it may lead to infraocclusion which can be diagnosed clinically. This unpleasant situation can be treated by decoronation, a technique that comprises the separation of the clinical crown from the root with a diamond bur, after the elevation of a mucoperiosteal flap and the removal of the root filling (68, 117-119). This technique has the advantage that the root is gradually resorbed and replaced by alveolar bone and in this case the bone is preserved and can be used in the future for implant. In advance, the separated clinical crown could be bonded to the adjacent teeth, providing the patient a satisfactory

aesthetic result. This technique was used in three patients (12 %). Infection related root resorption is the most serious type of root resorption, having the worst prognosis. It is characterised by resorption of the cement and dentin of the root together with inflammatory changes of the periodontium. This type of resorption is associated with necrosis and infection of the pulp from where bacteria enter the periodontal space through the dentinal tubules. Infection related root resorption can appear 3 weeks after replantation, and can progress so fast, that might lead to loss of the affected tooth within 8 to 12 weeks (16). We met with such a situation in three patients (12 %). If infection related root resorption is diagnosed on time, root canal treatment with $\text{Ca}(\text{OH})_2$ is indicated, since its intracanal use could lead to resorption arrest (28, 52).

Data in literature confirm the results in the second retrospective clinical study (5.2); the most frequent post-traumatic complication in lateral luxation injuries (LI) in IT is root canal obliteration (10, 20, 63, 70, 95, 131, 145). This is a complication which is diagnosed during radiographic controls (10, 103, 131). Second most frequent complication was pulp necrosis which occurred in this study in 8.6 % of IT lateral luxation injuries, similarly as in other studies (10, 15, 16, 30, 97, 103, 131).

In 96 cases of lateral luxation in MT, pulp necrosis and chronic periodontitis were the most frequent PTCs occurring in 17.70 % of cases. Studies in literature confirmed that in LI injuries of MT, the most frequent complication is pulp necrosis (8, 9, 14, 95, 164).

In uncomplicated clinical crown fractures (UCCf), both in MT and IT, pulp necrosis was the most frequent PTC, a fact which agrees with other studies in literature (14, 16, 95, 141, 143, 144). The main reason for the above, is the delay of dental treatment after the injury, which increases the risk of pulp bacterial contamination through the open dentinal tubules.

Concerning complicated crown fractures (CCf), factors such as time interval between dental injury and treatment, size of pulp exposure and level of root development play important role on type of treatment and treatment outcome (1, 96, 144). MT were treated endodontically, soon after the traumatic incident; the endodontic treatment comprised pulp extirpation, temporary root canal filling with $\text{Ca}(\text{OH})_2$ and later obturation with sealer and guttapercha. In IT, pulp extirpation is the last possible treatment choice, since the main goal of our treatment should be to save the pulp vitality. If pulp exposure is not large, there is not excessive bleeding from pulp and the time interval between injury and the treatment is short,

the treatment of our choice could be direct pulp capping, eventhough all three cases, in this study, that were treated in this direction resulted in PN.

In many cases of CCf in IT, pulpotomy is indicated (48, 160). With this method, the infected coronal part of the pulp or part of the coronal part (2 mm) is removed, and the remaining pulp is covered with Ca(OH)_2 , trying to save the pulp vitality in the root canal, so that to preserve undisturbed the continuation of root development (48, 96).

In any case, up to nowadays, Ca(OH)_2 plays a quite important role in treatment of PTCs. In cases of IT, when the choice of treatment is either direct pulp capping or indirect pulp capping or pulp amputation, the pulp should be covered with Ca(OH)_2 paste.

Even in cases that pulp vitality of these teeth can not be saved, it is recommended to fill repeatedly and for long-term the root canal with Ca(OH)_2 , trying to achieve the formation of mineralised apical barrier, which will allow future definite endodontic treatment (46, 72, 89, 112, 113, 149, 157).

5.4 Conclusions

From 90 avulsed teeth found in our patients' documentations, only 27 were replanted. Most of the replanted teeth either were transported to Dentistry department of Faculty of Medicine in Pilsen, quite long time after the injury or they were stored in inappropriate transport medium. These facts prove that there is significant insufficiency on the knowledge of adult people who are in daily contact with children at providing first aid in cases of dental injuries; this endangers the treatment outcome and future prognosis of such injuries and increases the risk for occurrence of post-traumatic complications, as pulp necrosis, chronic periodontitis and infection related root resorption which will require long-term and high cost treatment. Dental trauma requires frequent and long-term clinical and radiographic controls, since post-traumatic complications could occur even long time after the injury. These complications could be serious and could lead even to loss of the affected tooth. Most of them, if are diagnosed on time, could be treated succesfully. Endodontic treatment, especially in teeth with unfinished root development, can be complicated and requires the use of calcium hydroxide, which for many years has been presenting with quite satisfactory results.

➤ *The results of the study 5.1 were published in Journal Dental Traumatology (137).*

6. EXPERIMENTAL PART OF THE STUDY

6.1 Experiment 1. „Comparison of pH of various calcium hydroxide materials in vitro“

6.1.1 Materials and Methods

We measured and compared in vitro the pH of different $\text{Ca}(\text{OH})_2$ materials which we use in Dentistry department of Faculty of Medicine in Pilsen, Czech Republic, as intracanal medicaments. The procedure took place in the laboratory of Clinical Biochemistry department using WTW Microprocessor pH Meter pH 537 and in room temperature. After diluting equal quantities (same weight - 10mg) of these materials in equal volume of distilled water (5 ml), we measured with the pH meter 3 times the alkalinity of each material. We considered the mean value as the material's pH. The same procedure was repeated, 10 minutes and 1 week after the placement of the materials into the saline solution. The alkalinity of the $\text{Ca}(\text{OH})_2$ points was estimated in the same way after placing one point (ISO 40) in 5ml of distilled water.

The $\text{Ca}(\text{OH})_2$ materials that we use in our department as root canal dressings and we chose to compare are the following ones:

- “Calxyd” {Spofa Dental, Czech Republic}. Paste - composed of calcium hydroxide, glycerine and water.
- “Calxyl” red and blue {OCO Präparate, Germany}. Both red and blue are in paste form. The red variant is composed of calcium hydroxide and water. The blue variant is composed of calcium hydroxide, water and Barium Sulphate, which is the element providing the property of x-ray contrast.
- “Dentbalzam” {Spofa Dental, Czech Republic}. Paste - composed of calcium hydroxide suspension in distilled water.
- “Calcium Hydroxide PLUS points” {Roeko, Germany}. They are in the form of points which should be inserted in the root canal. Composed of 52 % calcium hydroxide, 42 % gutta-percha, sodium chloride, surfactant and colouring agents.

6.1.2 Results

Our measurements revealed that the pH of the first 4 materials which were in paste form was ranging between 11.65 and 11.80, while Dentbalzam proved to be slightly less alkaline than the rest. The „PLUS“ points proved to have significantly less pH, which was ranging at the levels of 6.30 to 7.

More specifically, one week after the initiation of the experiment, Calxyd, Calxyl red and blue were proved to be the most alkaline materials, since their pH was measured to be approximately 11.80.

Dentbalzam's measurements were also quite satisfactory, because its pH was measured at levels of 11.65.

The $\text{Ca}(\text{OH})_2$ points though, were measured to have almost neutral pH, since 30 minutes after their dilution in distilled water their pH was measured to be 6.40, and one week after it was measured at levels of 6.75 (Table 3).

Material	Mean value of pH after 10 minutes	Mean value of pH after 30 minutes	Mean value of pH after 1 week
<i>Calxyd</i>	11.75	11.80	11.80
<i>Calxyl red</i>	11.80	11.82	11.82
<i>Calxyl blue</i>	11.80	11.81	11.82
<i>Dentbalzam</i>	11.65	11.64	11.65
<i>Plus Calcium Hydroxide points</i>	6.30	6.40	6.75

TABLE 3 PH VALUES OF EACH TESTED MATERIAL

6.2. Experiment 2: “Diffusion of calcium ions from various materials with calcium hydroxide in vitro”

6.2.1 Materials and Methods

For this experimental study we used the same $\text{Ca}(\text{OH})_2$ materials that were used in experiment 6.1.

The tested materials were applied into shortened, yellow, conical pipettes with 200 μl volume capacity, with the help of lentulo spiral instrument in micromotor. The lower part of these pipettes which were simulating root canals of teeth, obtained an opening of 0.5mm, resembling the apex of the tooth root (Fig. 4).



FIG. 4 EXPERIMENTAL PIPETTES

Each pipette was filled with standard way and every $\text{Ca}(\text{OH})_2$ material was applied into 5 pipettes. The lower part of the pipettes was dipped into 0.5 ml of saline solution, in small closed laboratory tubes with a total volume capacity of 1.5 ml. The top part was above the level of the solution (Fig. 5).



FIG. 5 LABORATORY TUBE CONTAINING PHYSIOLOGIC SOLUTION

Ca(OH)_2 diffuses through the lower opening of the pipettes into the saline solution with various rates (this depends on the various vehicles that each Ca(OH)_2 material contains and on the consistency of each material). Ca(OH)_2 dissociates in the saline solution into calcium and hydroxyl ions. The pH was calculated by measuring the concentration of calcium ions into the saline solution.

All samples were incubated and stored in laboratory temperature and in the same conditions. In specific time intervals the pipettes were removed from the closed tubes and placed in other tubes containing physiologic solution, until the concentration of calcium ions was measured into the original tubes. After the measurements, the pipettes were placed back to their original tubes. This procedure was repeated, first in short and then in longer time intervals.

The measurement of calcium ions was realised with the help of analyser “AU 400 Olympus” from the company Olympus System reagent Calcium OSR 6276 (Fig. 6).




FIG. 6 AU 400 OLYMPUS

The results of measurements of calcium ion concentration were statistically analysed using the method: “ANOVA repeated design” (Graf 12, Table 5, 6).

6.2.2 Results

The highest alkalinity was resulted from Dentbalzam and Calxyd. The pH of these two materials reached values of approximately 11.9 and 12.1 respectively, 3 weeks after the first measurements.

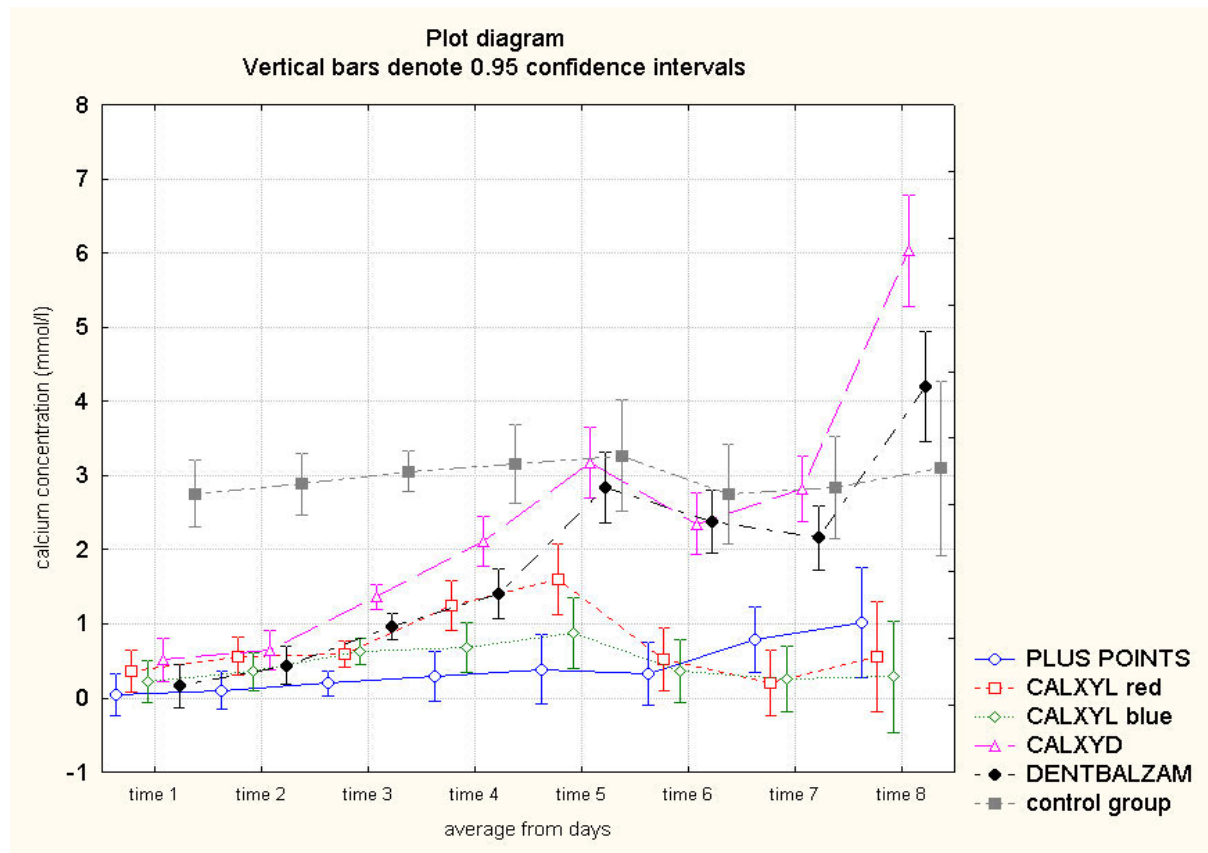
Calxyl red and blue seemed to have reached their maximum pH values (11.860 and 11.649 respectively) 1 week after first measurements and then some slight, gradual reduction was noticed.

Finally, Roeko Plus points, showed some gradual release of calcium and hydroxyl ions, and although at the first measurements the pH was low – in comparison with the rest materials – , 3 weeks after first measurements the pH was measured to be at values of 11.394 (Table 4).

MATERIALS	15 min. pH	24 hours pH	1 week pH	3 weeks pH
Dentbalzam	10.401	11.390	11.639	11.909
Calxyd	10.960	11.584	11.631	12.088
Calxyl Red	10.769	10.867	11.860	11.731
Calxyl Blue	10.542	10.775	11.659	11.532
Roeko Plus points	9.903	10.742	10.817	11.394

TABLE 4 PH VALUES OF EACH MATERIAL

Statistic analysis of the results of all measurements of calcium ions`concentration was performed (Graph 12).



GRAPH 12 STATISTIC ANALYSIS OF CALCIUM CONCENTRATION VALUES IN SALINE SOLUTION OF EACH MATERIAL GROUP TO TIME

Repeated ANOVA: all groups against each other

	p-value
GROUP	0,000000
Factor (time - development to time)	0,000000
GROUP * Factor	0,000000

TABLE 5 P-VALUES OF REPEATED ANOVA TESTS

Statistic analysis confirmed that:

- the mean values differ from one group to another
- it was confirmed that the parameters change by time
- the development of curves between groups differs / varries

Repeated ANOVA: only the groups of samples filled with Ca(OH)_2 (without the control group)

	p-value
GROUP	0,000000
Factor (time - development to time)	0,000000
GROUP * Factor	0,000000

TABLE 6 P-VALUES OF REPEATED ANOVA TESTS

Statistic analysis confirmed that:

- a) the mean values differ from one group to another
- b) it was confirmed that the parameters change by time
- c) the development of curves between groups differs / varies

6.3 Experiment 3: “Vehicle influence on calcium hydroxide materials` diffusion through dentin, in human teeth”

6.3.1 Materials and Methods

27 permanent teeth which were extracted for orthodontic reasons were used in this study. These teeth were intact premolars (single or double root). All teeth were rinsed with chlorhexidine solution immediately after their extraction and then stored into saline solution until their use.

These teeth were trepanated and access was gained into their root canals. Mechanical hand instrumentation was performed for all the root canals with K-files and Flexo-files. The apical foramen of all roots was enlarged up to a No ISO 30 Flexo-file, and the work length was determined to 1 mm from the apex. Subsequently the roots were mechanically prepared with step-back technique (work length – ISO 30) up to No ISO 40 Flexo-files. During the preparation of the root canals, chlorhexidin 0.12 % was used as rinsing and disinfection solution.

A small standard cavity, 1.5 to 2 mm deep, was prepared on the surface of the middle third of each root with tungsten-carbide inverted cone bur in micromotor hand piece, so the cement of the roots of each tooth was disrupted and the dentin was exposed in that specific area, resembling an external root resorption (Fig. 7).



FIG. 7 CAVITY SIMULATING ROOT RESORPTION AT MIDDLE ROOT THIRD

After the accomplishment of the root canal and the cavity preparations, each root canal was filled with Ca(OH)_2 materials from different companies which are used in Dentistry department of Faculty hospital in Pilsen. These Ca(OH)_2 preparations were placed into the root canals with Lentulo spiral instruments (ISO 25) in micromotor hand-piece in low rounds. The teeth were then divided in 5 groups (each group contained 5 teeth), according to the material that they were filled with (same materials were used as in 6.1, 6.2).

Group 1: “Plus points” (Roeko, Germany), which are composed from Ca(OH)_2 , gutta-percha, sodium chloride and colouring agents.

Group 2: “Calxyd” (Spofa Dental, Czech Republic), which is composed from Ca(OH)_2 powder, glycerine and distilled water.

Group 3: “Calxyl” red (OCO Präparate, Germany), which is composed from Ca(OH)_2 powder and distilled water.

Group 4: “Calxyl” blue (OCO Präparate, Germany), which is composed from Ca(OH)_2 powder, Barium sulphate and distilled water.

Group 5: “Dentbalzam” (Spofa Dental, Czech Republic), which is composed from Ca(OH)_2 powder and distilled water.

The 2 remaining teeth were used as control teeth and their root canals were filled with dry, sterile paper points.

After filling each root, the clinical crown was restored with glass ionomer cement filling (Kavitan, Spofa Dental, CZ) which was covered with varnish (Fig. 8).




FIG. 8 GLASS IONOMER CEMENT RESTORATION OF CLINICAL CROWNS

Glass ionomer cement (Kavitan) was placed in the apex of the roots, so that there was no communication between the root canal and the extra-radicular environment. The cement in the apex was again covered with varnish. Each tooth then was stored into 0.5 ml saline solution into closed tubes with total capacity 5ml, so that the exposed dentin of the roots was dipped into the saline solution, but not the restored clinical crowns of the teeth (Fig. 9).

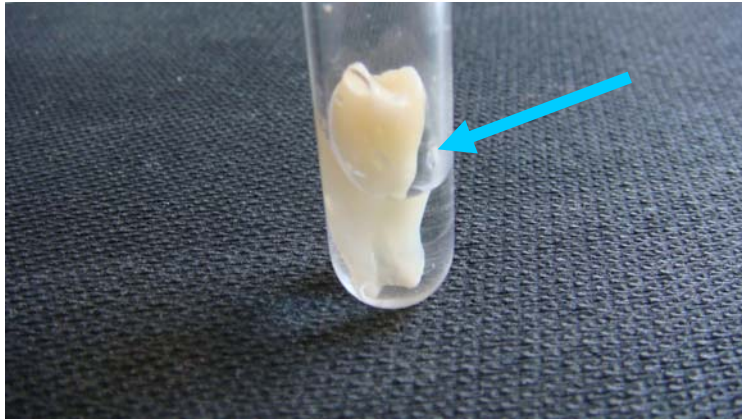


FIG. 9 SAMPLES DIPPED IN SALINE SOLUTION IN CLOSED GLASS TUBES

The pH of each solution was calculated with the help of “WTW Microprocessor pH meter pH 537”. In specific time intervals, the teeth were removed from the tubes with a pinset and placed into other tubes containing 0.5 ml of saline. In the original tubes, the concentration of calcium ions was measured (2 μ l were sufficient for the measurement of calcium ions). After the measurement, the teeth were placed back into their original storage tubes. This procedure was repeated in short time intervals at the beginning, and then in longer time intervals. The measurements of calcium ions were realised with the help of analyser “AU 400 Olympus” from the company Olympus System reagent Calcium OSR 6276.

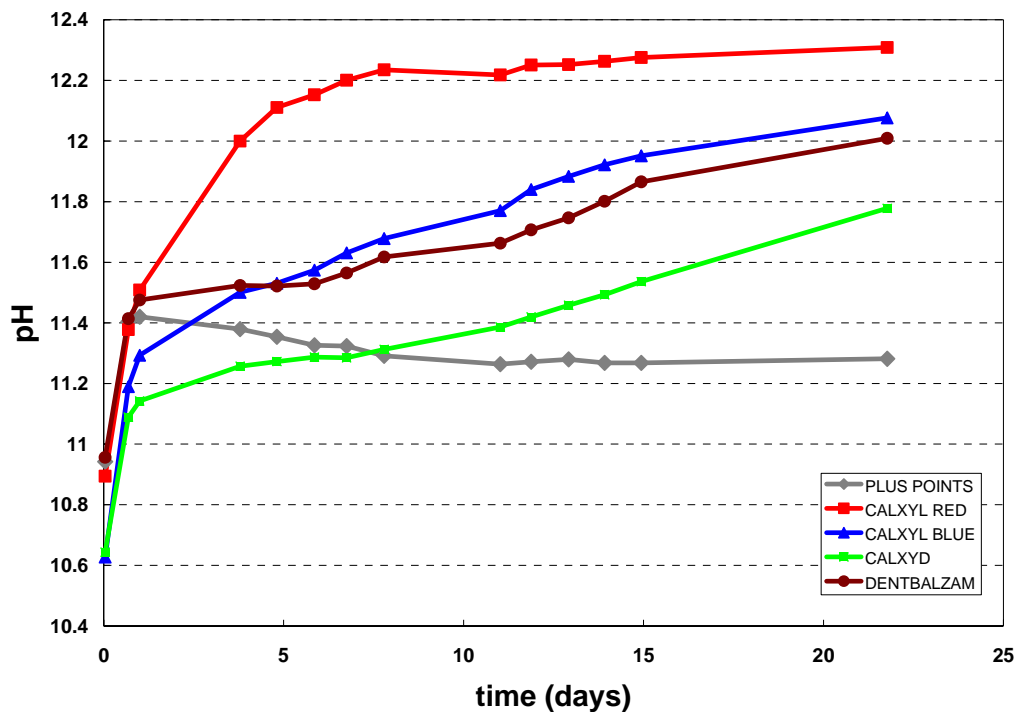
The results were recorded for each tooth separately and then for each group and were statistically analysed using the method: “ANOVA repeated design” (Graf 14, Table 7, 8).

6.3.2 Results

The pH reached almost its maximum values 2-3 weeks after the filling of the root canals with $\text{Ca}(\text{OH})_2$ materials, since calcium and hydroxyl ions need at least 14 days to penetrate the dentin, through dentinal tubules and reach the external surface of the root.

As results we considered the mean values of every 5 teeth of each group.

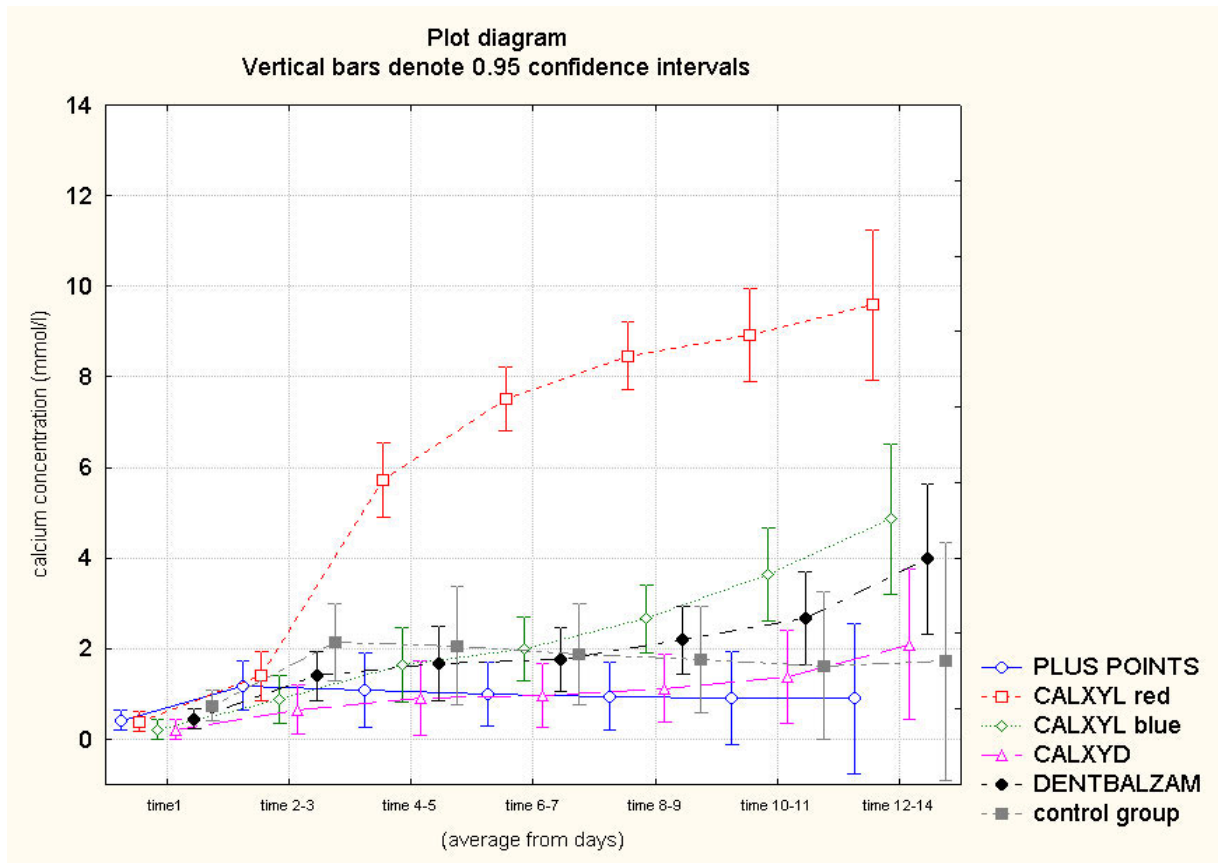
The highest pH values were presented in cases of “Red Calxyl”, since 2 to 3 weeks after filling the root canals, pH reached values of 12.2. In the second place were “Calxyl blue” and “Calxyd” which were measured to cause an alkaline environment with pH around 12. “Dentbalzam” caused a pH around 11.8 and in the last place were “Roeko Plus points” that caused pH around 11.2 (Graph 13).



GRAPH 13 RELATION OF PH TO TIME

The control teeth which were filled with standard paper points caused a concentration of calcium ions higher than that of “Plus points (Fig. 22).

Concerning the concentration of calcium ions, again 2 to 3 weeks after filling of the root canals, “Red Calxyl” was the first (highest diffusion of calcium ions through dentinal tubules), then “Blue Calxyl” and “Calxyd”, “Dentbalzam” and finally “Roeko Plus points” . The control teeth which were filled with standard paper points, caused a concentration of calcium ions similar to that of “Plus points” (Graph 14).



GRAPH 14 STATISTIC ANALYSIS: RELATION OF CALCIUM ION CONCENTRATION TO TIME

Repeated ANOVA: all groups against each other

	p-value
GROUP	0,000000
Factor (time – development to time)	0,000000
GROUP * Factor	0,000000

TABLE 7 P-VALUES OF REPEATED ANOVA TESTS

Statistic analysis confirmed that:

- a) the mean values differ from one group to another
- b) it was confirmed that the parameters change by time
- c) the development of curves between groups differs / varries

Repeated ANOVA: only the groups of teeth filled with Ca(OH)₂ (without the control group)

	p-value
GROUP	0,000000
Factor (time - development to time)	0,000000
GROUP * Factor	0,000000

TABLE 8 P-VALUES OF REPEATED ANOVA TESTS

Statistic analysis confirmed that:

- a) the mean values differ from one group to another
- b) it was confirmed that the parameters develop by time
- c) the development of curves between groups differs / varries

Red Calxyl, blue Calxyl, Calxyd and Dentbalzam are materials that proved to cause better penetration of calcium and hydroxyl ions through dentin tubules to the external root surface, thus they cause highly alkaline environment locally, around the external surface of the root. Roeko Plus points did not present with the same satisfactory results in diffusion of hydroxyl ions through the exposed dentinal tubules, as the Ca(OH)₂ materials in paste form.

6.4. Experiment 4: “Measurement of dentin hardness in teeth with long-term root canal filling with calcium hydroxide”

6.4.1 Materials and methods

The sample teeth (two from each group and the control teeth) of the previous experimental study (6.3) were used. These teeth were stored in saline solution, in closed glass tubes, in room temperature for 1 year. The following steps were performed, so that to finally get access to root dentin and measure the hardness:

- Fixation and embedding of samples

For fixation and embedding of the teeth, standard technique was used (76, 162, 177):

1. The teeth were dried in phases, using increasing concentration solutions of ethanol. All samples were placed in each solution for 10 minutes (40 %, 50 %, 70 % and 100 % solutions of ethanol) in low temperature (4°C). By that method, dehydration of root surface was achieved at the same time as fixation, and the teeth did not have to be repeatedly washed in water overnight, in case that formalin solution would be used.
2. For embedding of teeth we used EPON set 812 in standard procedure. The above drying phase was followed by infiltration phase which was completed at 18°C. Infiltration phase consisted of placement of teeth into propylene-oxide for 15 minutes, then in a mixture solution of propylene-oxide and Epon (1:1 solution) for 60 minutes and finally into mixture solution of propylene-oxide and Epon (1:3 solution) for 6 hours.
3. The teeth were then removed from the above mixture solution and were placed into special, standard, cylindrical, plastic tubes, the mounding cups, with 30 mm diameter (Fig. 10) which were containing the final solution of Epon 812 at 37°C.



FIG. 10 VARIOUS TYPES OF MOUNDING CUPS
(yellow cups were used for the needs of this study)

Subsequently, the moulding cups were placed into a thermostat in conditions of 37°C for 5 hours, and then in conditions of 45°C for another 10 hours. Finally, the temperature of the thermostat was increased once more to 60°C for 12 hours and then the moulding cups were stored into room temperature conditions. The embedding medium reached the hard phase and the samples were prepared for grinding.

- Grinding and polishing of samples

1. The hard embedding medium was removed from the moulding cups (Fig. 11a, b).



FIG. 11 a) HARDENED EMBEDDING MED b) REMOVED SAMPLES FROM CUPS

For grinding of samples the machine HK 350 disc grinder (“H & K laboratory equipment” company) was used (Fig. 12). The method used for grinding of our specimens is a standard method introduced by Geels (79) using SiC grinding discs. At the beginning, rough abrasive grinding, using P 120 grain size SiC grinding discs (120 µm thickness), was performed. For cooling and lubrication of the sample during grinding, distilled water was used. The samples were held against the grinding disc, until half of the tooth (longitudinally) was removed, so that the whole pulp cavity was exposed. This method is so called “grinding until interested area is visible”.



FIG. 12 HK 350 DISC GRINDER

After rough grinding, plane grinding was performed, using thicker SiC paper discs (P 320 grain size – 320 μm thickness) and then fine grinding, with SiC paper discs P 500 grain size – 500 μm in thickness. The cooling and lubricant agent which was used in all phases of grinding was distilled water.

2. Final polishing was achieved by Labopol 5 polishing machine (Struers comp.), using thin Silica discs with 200 dia and in 200 rounds per minute (rpm), without the use of any lubricant or cooling agent (Fig. 13). Polishing was performed, in order to produce smooth tooth surfaces, important for nanoindentation technique (dentin hardness measurement).



FIG. 13 LABOPOL POLISHING MACHINE

Each phase lasted 2 minutes and the applied force to each specimen during grinding was 30 Newton. For polishing, the applied force was 10 Newton, and the polishing period of each specimen was 5 to 7 minutes.

- Measurements of root dentin hardness

The root-dentin micro-hardness of 2 specimens of each material and 5 control teeth was measured, using nanoindentation tests with Nano Indenter XP, from MTS Systems Company.

These measurements were realized towards the whole length of dentin of the root, at the side where the cavity had been prepared (experiment 6.3, page 47).

These nanoindentation tests were conducted with a maximum load of 1 Newton, with hold period of 30 seconds. A total of 50 indents were made, in distance of 200 μm from each other (Fig. 14, 15).




FIG. 14 50 INDENTS, IN DISTANCE 200 μm FROM EACH OTHER, ON DENTIN SURFACE

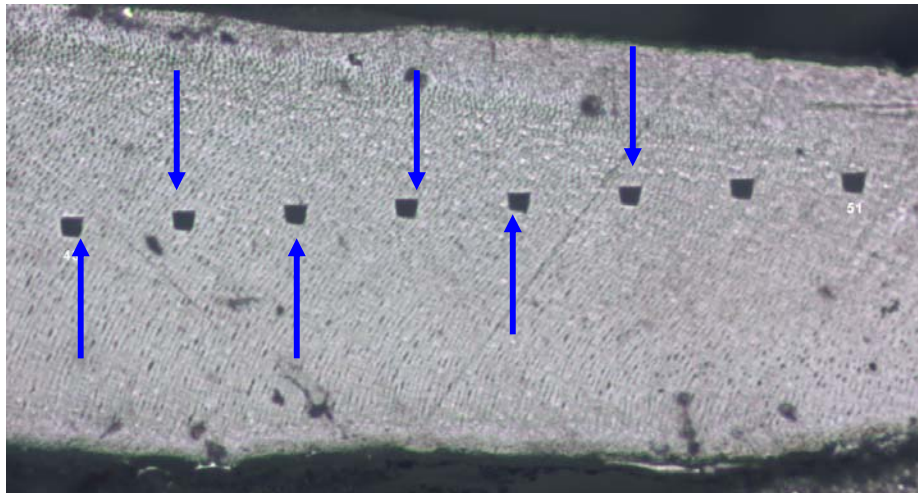


FIG. 15 INDENTS ON DENTIN SURFACE

The hardness and elastic modulus for each indentation were determined using the method described by Oliver and Pharr and in other studies (132, 142), which will not be described in details in our study.

50 measurements of dentin hardness in each sample, were statistically analyzed and evaluated and the mean values of dentin hardness of each specimen and control teeth were produced and compared with each other.

6.4.2 Results

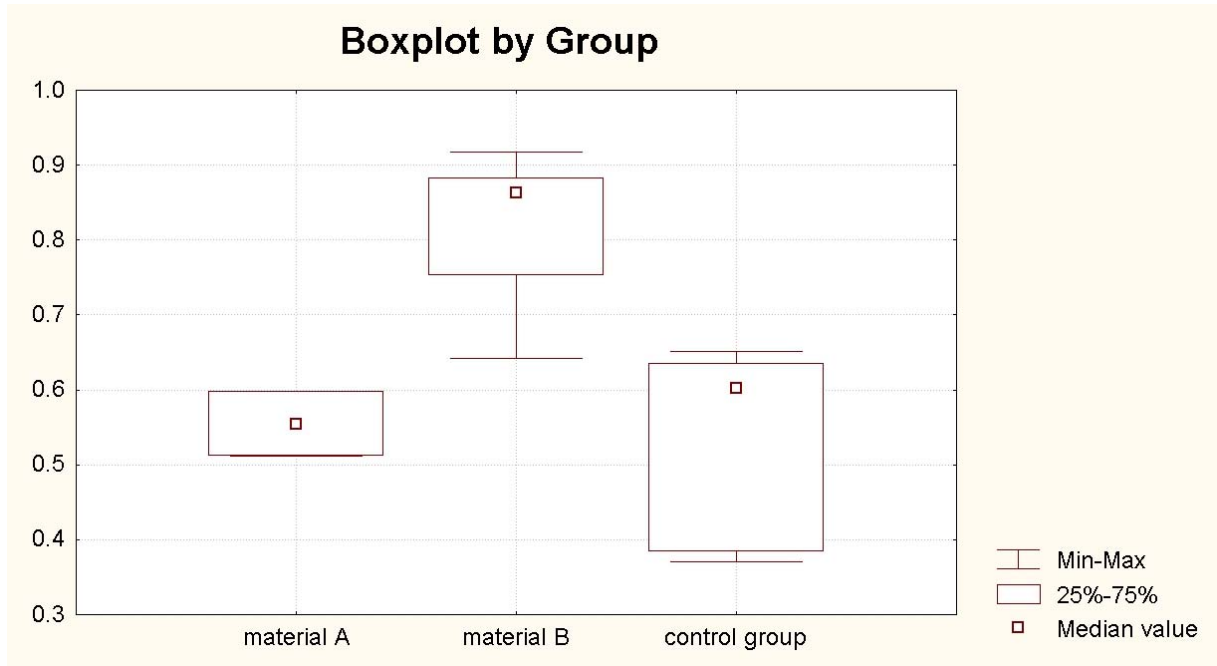
The measurements revealed that all teeth which had been filled with Ca(OH)₂ materials, presented with higher values of dentin hardness than control teeth.

- More specifically, the mean values of dentin hardness of the two control teeth, with their root canals containing paper points, were measured to be 0.370 and 0.384 GPa.
- Three intact, freshly extracted for orthodontic reasons teeth, were measured to have mean values of root dentin hardness 0.602, 0.635 and 0.651 GPa.
- Two teeth that had their root canals filled with Plus points had mean values of dentin hardness 0.511 and 0.598 GPa.
- The root dentin hardness of two teeth, filled with Calxyd was measured to be 0.868 and 0.892 GPa.
- Calxyl red had 0.749 and 0.756 GPa and Calxyl blue was measured at levels of 0.642 and 0.898 GPa.
- Finally, two teeth filled with Dentbalzam presented with dentin hardness at levels of 0.875 and 0.917 GPa.

The results are presented in Table 9. Statistic analysis of the results was performed using the Wilcoxon method. The median values of dentin hardness of teeth filled with Ca(OH)₂, teeth filled with “Plus points” and control teeth were compared (Graph 15, Table 10).

DENTIN HARDNESS MEASUREMENTS GPascals / Standard deviation(St)	Tooth 1	Tooth 2	Tooth 3
Control teeth (root canals filled with paper points)	0.384 / 0.072	0.370 / 0.151	-
Control teeth (freshly extracted teeth)	0.602 / 0.118	0.635 / 0.081	0.651 / 0.149
Roeko “Plus points”	0.511 / 0.215	0.598 / 0.188	-
Calxyd	0.868 / 0.098	0.892 / 0.112	-
Calxyl red	0.756 / 0.186	0.749 / 0.078	-
Calxyl blue	0.898 / 0.136	0.642 / 0.139	-
Dentbalzam	0.875 / 0.179	0.917 / 0.105	-

TABLE 9 RESULTS OF MEASURING DENTIN HARDNESS



GRAPH 15 STATISTIC ANALYSIS OF DENTIN HARDNESS MEASUREMENTS

Material A = Roeko Plus points

Material B = 8 teeth filled with Calxyl red and blue, Calxyd and Dentbalzam

Material C = 5 control teeth

Statistic analysis confirmed that the median values of dentin hardness between control teeth and teeth filled with Roeko plus points did not differ significantly. Values of dentin hardness, though, in teeth filled with $\text{Ca}(\text{OH})_2$ pastes were significantly higher.

P value - Wilcoxon test

material A vs. material B: **0.0367**

material A vs. control: **0.0054**

material B vs. Control: **0.6985**

TABLE 10 P-VALUES OF WILCOXON TEST

6.5. Experiment 5: “Histological evaluation of dentin hypercalcification after long-term filling of root canal with Calcium Hydroxide”

6.5.1 Materials and Methods

i) The teeth samples were observed in SEM “*JSM.6300 Scanning microscope*” from JEOL company. The samples were broken vertically (Fig. 16), cleaned with ultrasounds and fixed with ethanol solution, as was described in experiment 6.4, in order to achieve root surface dehydration. Subsequently, the teeth were dried and mounted to a metal base. For better observation in SEM, the teeth were covered from a narrow layer of pure gold metal of 15 to 20 nanomilimeters. With the help of computer, several photographs of root dentin were produced, in various root places and in various magnifications (magnifications of up to 12000x). We concentrated mostly on establishing occurrence of calcifications in root dentin of teeth that were filled with $\text{Ca}(\text{OH})_2$ and compare the findings with control teeth (teeth without root filing). This experimental study took place in Laboratory of electronic microscopes AVČR in České Budějovice, CZ.




FIG. 16 BROKEN TOOTH VERTICALLY (in optic microscope: magnification x 20)

ii) Other teeth samples, that had been used in experiment 6.4, were mapped with the help of SEM Quanta 200 from FEI company (Fig. 17). A root dentin surface of 0.5 x 1 mm was analysed with the help of the above SEM, concentrating on the percentage weight of calcium on that specific dentin surface, which was located always below the cavity preparation at the middle root third (see experiment 6.3). We compared the results between control teeth and teeth that had been filled with $\text{Ca}(\text{OH})_2$. This study was realized in West Bohemian University, in Pilsen, CZ.



FIG. 17 SEM QUANTA 200 - FEI

6.5.2 Results

i) Dentin observation in SEM of teeth filled with Ca(OH)_2 preparations and comparison with control samples.

We compared the dentin between control teeth and teeth that had been filled with Ca(OH)_2 , after extensive observation in SEM.

In control teeth, the internal walls of dentin tubules were smooth, without any finding (Fig. 18). The internal walls of dentin tubules in teeth with Ca(OH)_2 , seemed to be "granulated", rough and hypercalcified (Fig. 19). In some cases, large Ca(OH)_2 particles / crystals were visible in the tubules (Fig. 20).

In control teeth, the dentin tubules seemed to be empty (Fig. 21). Dentin tubules of teeth with Ca(OH)_2 were filled with particles of this material, and in microscope they seemed quite obliterated (Fig. 22).

In higher magnification, in teeth with Ca(OH)_2 , hypercalcification of the internal surfaces of the dentin tubules is visible, as well as local calcification areas in intertubular dentin (Fig. 24, 25), when in control teeth tubules and intertubular dentin did not present with hypercalcified areas (23).

Finally, in high magnification (x 10000), in teeth with Ca(OH)_2 , large calcium crystals and hypercalcified areas were detected in intratubular walls, as well as in intertubular dentin (Fig. 27, 28), when in control teeth, no hypercalcified areas were detected in intertubular dentin and physiologic intratubular branching structure was visible, but no Ca(OH)_2 particles or calcium crystals were detected (Fig. 26).




FIG. 18 CONTROL TOOTH: SEM OF LONGITUDINALLY SECTIONED DENTIN TUBULES CLOSE TO PULP. TUBULES APPEAR TO BE EMPTY (A), THERE IS EVIDENCE OF PERITUBULAR DENTIN (B) AND CLEAN INTERTUBULAR DENTIN (C).
(x 4000)




FIG. 19 TOOTH FILLED WITH CALCIUM HYDROXIDE PREPARATION: SEM OF DENTIN TUBULES WHICH CONTAIN SMALL CALCIUM PARTICLES; THE INTERNAL WALLS OF DENTIN TUBULES ARE CRYSTALLIZED (A) AND THERE IS HYPERCALCIFICATION OF INTERTUBULAR DENTIN LOCALLY (B). (x 4000)




FIG. 20 TOOTH FILLED WITH CALCIUM HYDROXIDE MATERIAL. SEM: VISIBLE CALCIUM HYDROXIDE PARTICLES IN DENTIN TUBULES (A) AND CALCIUM CRYSTALS IN TUBULES (B) AND IN INTERTUBULAR DENTIN (C).
(x 4000)




FIG. 21 CONTROL TOOTH:
SEM OF DENTIN TUBULES IN CROSS
SECTION. DENTIN TUBULES SEEM TO
BE "EMPTY". (x 4000)




FIG. 22 TOOTH FILLED WITH CALCIUM
HYDROXIDE: SEM OF DENTIN TUBULES
WHICH ARE OBLITERATED WITH
CALCIUM HYDROXIDE PARTICLES (A);
INTERTUBULAR DENTIN IS
HYPERCALCIFIED LOCALLY (B).(x 4000)




FIG. 23 CONTROL TOOTH: SEM OF DENTIN TUBULES IN HIGHER MAGNIFICATION. NO SIGNS OF CALCIFICATION OF DENTIN TUBULES, PERITUBULAR AND INTERTUBULAR DENTIN. (x 8000)




FIG. 24 TOOTH FILLED WITH CALCIUM HYDROXIDE PREPARATION: SEM OF DENTIN TUBULES IN HIGHER MAGNIFICATION: VISIBLE ROUGH, CRYSTALLIZED INTERNAL WALL OF DENTIN TUBULES (A); HYPERCALCIFIED AREAS IN INTERTUBULAR DENTIN (B). (x 8000)




FIG. 25 TOOTH FILLED WITH CALCIUM HYDROXIDE PREPARATION: SEM OF DENTIN IN HIGHER MAGNIFICATION: CRYSTALLIZED INTERNAL WALL OF DENTIN TUBULES (A); HYPERCALCIFIED AREAS IN INTERTUBULAR DENTIN (B). (x 8000)




FIG. 26 CONTROL TOOTH: SEM OF RADICULAR DENTIN IN HIGH MAGNIFICATION. TYPICAL PICTURE OF INTRATUBULAR BRANCHING STRUCTURE, CONTAINING ODONTOBLASTS PROCESSES AND NERVE ENDINGS. NO SIGNS OF HYPERCALCFICATION OF DENTIN TUBULES AND INTERTUBULAR DENTIN. (x 10000)




FIG. 27 TOOTH FILLED WITH CALCIUM HYDROXIDE PREPARATION: SEM OF DENTIN IN HIGH MAGNIFICATION: CRYSTALLITES [CALCIUM HYDROXYAPATITE - $\text{Ca}_{10}(\text{PO}_4)_6(\text{OH})_2$] IN INTERTUBULAR DENTIN (A) AND CALCIUM CRYSTALS IN INTERTUBULAR DENTIN (B). (x 10000)


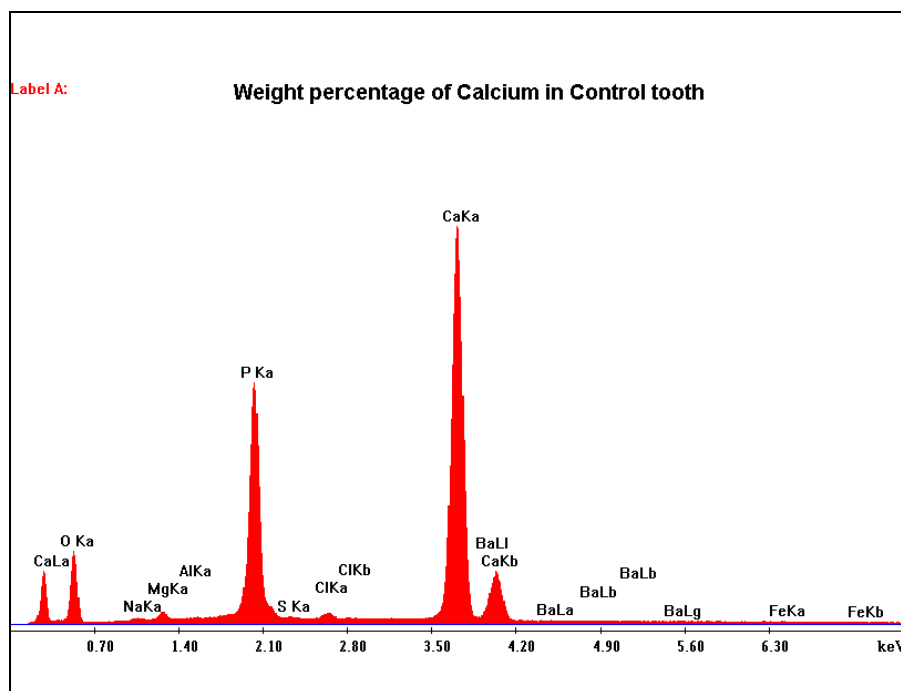


FIG. 28 TOOTH FILLED WITH CALCIUM HYDROXIDE PREPARATION: SEM OF DENTIN IN HIGH MAGNIFICATION: FORMATION OF CALCIFIED CRYSTALS IN BOTH INTERTUBULAR DENTIN (A) AND INTERNAL WALLS OF DENTIN TUBULES (B). (x 10000)

ii) Mapping of root dentin in SEM – Percentage weight of Calcium

We compared the weight percentage of control teeth and teeth that had been previously filled with Ca(OH)₂ materials (we used samples that had been used in experiment 6.3). After statistic analysis the highest values of calcium weight percentage, on each tooth, were detected. For control teeth, calcium weight percentage reached highest values of 36.14 % (Graf 16, Table 11).

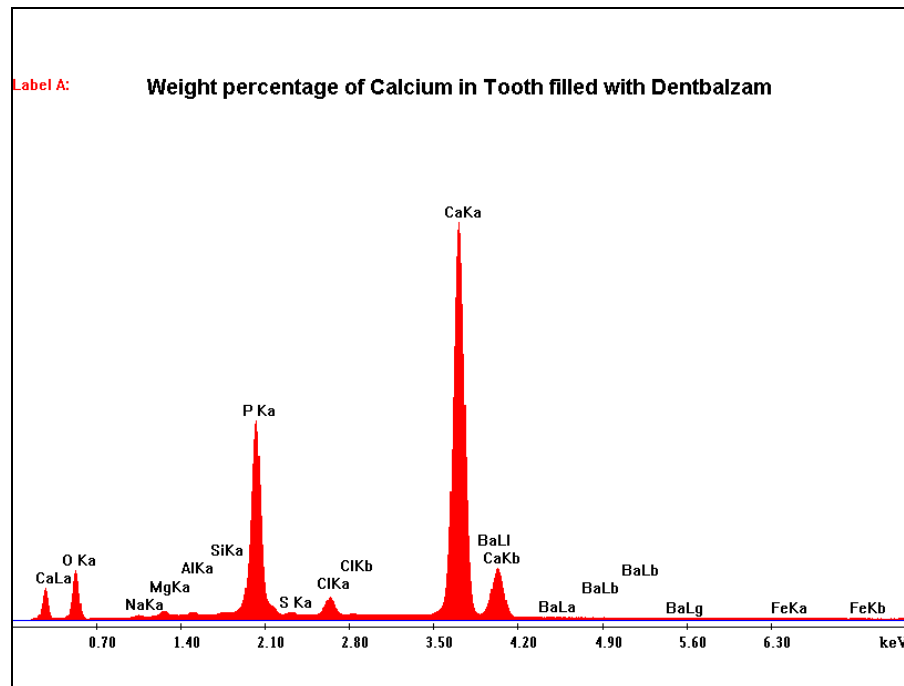


GRAF 16 WEIGHT PERCENTAGE ANALYSIS OF ROOT DENTIN IN CONTROL TOOTH

Element	Wt %	At %
O K	43.6	63.47
NaK	0.59	0.59
MgK	0.96	0.92
AlK	0.05	0.04
P K	18.04	13.56
S K	0.14	0.1
ClK	0.44	0.29
CaK	36.14	21
BaL	0	0
FeK	0.04	0.02
Total	100	100

TABLE 11 WEIGHT PERCENTAGE OF INORGANIC COMPONENTS OF ROOT DENTIN IN CONTROL TOOTH

Statistic analysis revealed that in teeth that had been filled with Dentbalzam, the highest values of calcium weight percentage were at levels of 41.7 % (Graf 17, Table 12).

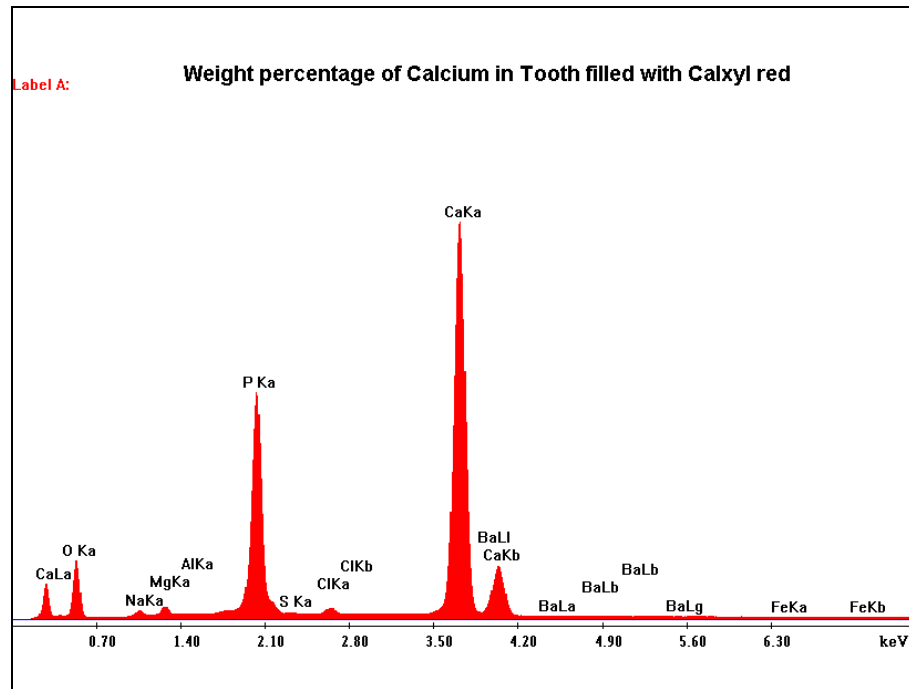


GRAF 17 WEIGHT PERCENTAGE ANALYSIS OF ROOT DENTIN IN TOOTH FILLED WITH „DENTBALZAM“

Element	Wt %	At %
O K	37.48	57.68
NaK	0.41	0.44
MgK	0.88	0.89
AlK	0.36	0.33
SiK	0.22	0.2
P K	16.94	13.46
S K	0.27	0.2
ClK	1.67	1.16
CaK	41.7	25.62
BaL	0	0
FeK	0.07	0.03
Total	100	100

TABLE 12 WEIGHT PERCENTAGE OF INORGANIC COMPONENTS OF ROOT DENTIN IN TOOTH WITH „DENTBALZAM“

Teeth that had been filled with „Calxyl red“ had highest values of calcium weight percentage, at levels of 39.35 % (Graf 18, Table 13).

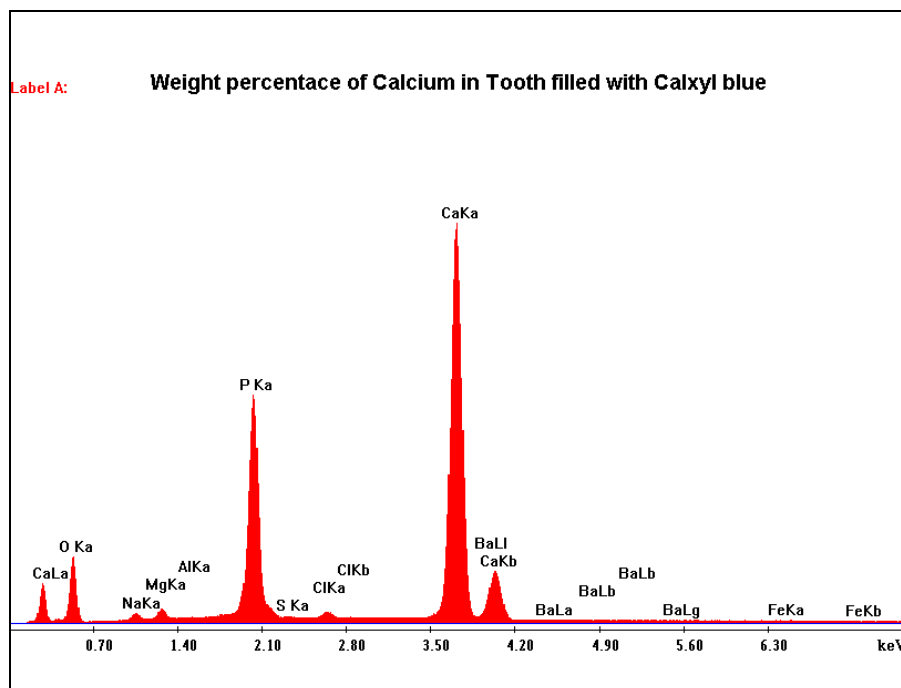


GRAF 18 WEIGHT PERCENTAGE ANALYSIS OF ROOT DENTIN IN TOOTH FILLED WITH „CALXYL red“

Element	Wt %	At %
O K	39.05	58.91
NaK	1.33	1.39
MgK	1.3	1.29
AlK	0.05	0.05
P K	18.2	14.18
S K	0.16	0.12
ClK	0.51	0.35
CaK	39.35	23.69
BaL	0	0
FeK	0.05	0.02
Total	100	100

TABLE 13 WEIGHT PERCENTAGE OF INORGANIC COMPONENTS OF ROOT DENTIN IN TOOTH WITH „CALXYL red“

Teeth that had been filled with „Calxyl blue“ showed highest values of calcium weight percentage, at levels of 37.98 % (Graf 19, Table 14).

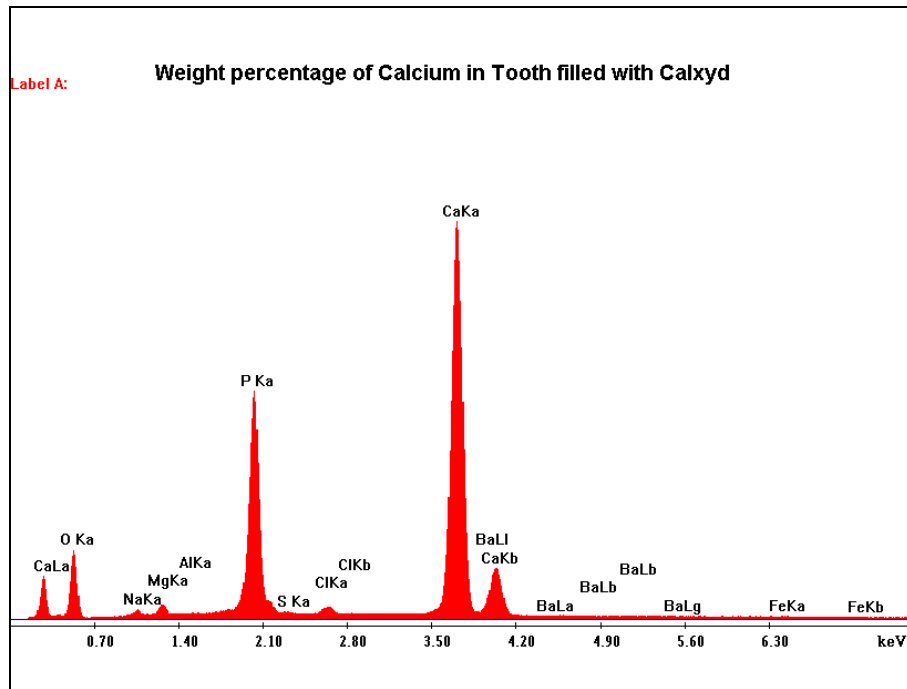


GRAF 19 WEIGHT PERCENTAGE ANALYSIS OF ROOT DENTIN IN TOOTH FILLED WITH „CALXYL blue“

Element	Wt %	At %
O K	39.72	59.5
NaK	1.27	1.32
MgK	1.42	1.4
AlK	0.05	0.05
P K	18.48	14.3
S K	0.14	0.1
ClK	0.84	0.57
CaK	37.98	22.71
BaL	0	0
FeK	0.11	0.05
Total	100	100

TABLE 14 WEIGHT PERCENTAGE OF INORGANIC COMPONENTS OF ROOT DENTIN IN TOOTH WITH „CALXYL blue“

Teeth that had been filled with „Calxyd“ had highest values of calcium weight percentage, at levels of 38.48 % (Graf 20, Table 15).

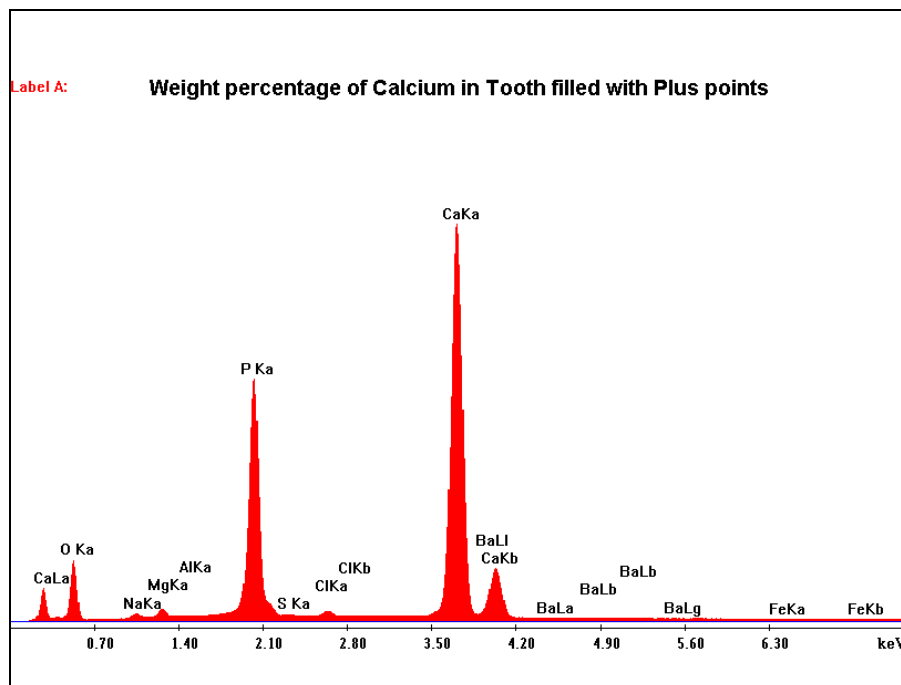


GRAF 20 WEIGHT PERCENTAGE ANALYSIS OF ROOT DENTIN IN TOOTH FILLED WITH „CALXYD“

Element	Wt %	At %
O K	39.82	59.71
NaK	0.96	1.01
MgK	1.11	1.1
AlK	0.02	0.02
P K	19.05	14.76
S K	0.13	0.1
ClK	0.38	0.26
CaK	38.48	23.04
BaL	0	0
FeK	0.04	0.02
Total	100	100

TABLE 15 WEIGHT PERCENTAGE OF INORGANIC COMPONENTS OF ROOT DENTIN IN TOOTH WITH „CALXYD“

Statistic analysis of measurements of calcium weight percentage in tooth that had been filled with „Plus points“ revealed that the highest values reached levels of 38.55 % (Graf 21, Table 16).



GRAF 21 WEIGHT PERCENTAGE ANALYSIS OF ROOT DENTIN IN TOOTH FILLED WITH „PLUS points“

Element	Wt %	At %
O K	39.65	59.54
NaK	0.99	1.03
MgK	1.11	1.1
AlK	0.02	0.02
P K	19.1	14.81
S K	0.13	0.1
ClK	0.39	0.27
CaK	38.55	23.11
BaL	0	0
FeK	0.06	0.02

TABLE 16 WEIGHT PERCENTAGE OF INORGANIC COMPONENTS OF ROOT DENTIN IN TOOTH WITH „PLUS points“

6.6 Discussion

Ca(OH)₂, for many years, is widely used in endodontics as root canal medicament because of its significantly beneficial properties. Among them, its high antibacterial and antiresorptive effects, together with its easy application into the root canal and its low cost (5, 49, 50, 52, 53, 69, 80, 124, 149, 174) are the reasons that we prefer its use, among other materials, as intracanal medicament in cases of PTCs treatment of immature, permanent teeth.

In treatment of PTCs, especially in IT, Ca(OH)₂ even nowadays seems to be the material of choice, although other materials, such as MTA (mineral trioxide aggregate) have been introduced, presenting with quite promising results (31, 150, 151, 163, 180). The wide spectrum of Ca(OH)₂ use, though, as well as its quite advantageous properties, low cost and its easy application (61, 106), seem to maintain this material in the first place of our choice.

Elimination of bacterias, which are lodged in the root canal system, is of great importance for apical and periapical healing, during and after endodontic treatment (36, 95, 164, 168). There are several studies in literature, reporting the antibacterial properties of Ca(OH)₂ (35, 49, 53, 66, 67, 83, 110, 135, 148, 155). Cvek reports that quite a few bacterias can resist in alkalic environments with pH 11-11.5, but not in pH more than 12 (18).

Our study confirmed other studies in the literature, concerning the antibacterial properties of Ca(OH)₂, by performing a series of experiments in vitro (6.1, 6.2, 6.3). In experiment 6.1, pH values of various preparations in paste form, after repeated measurements, varried between 11.65 and 11.80, agreeing in general with many authors' statements that Ca(OH)₂ causes alkalic environment with pH ranging between 11 and 12.5 (18, 41, 167). The in vitro measurements of „Plus points“, though, revealed that even after 1 week, pH did not exceed 6.75, although studies in literature have resulted in values of 12, for „Plus points“ pH (111).

The experiment 6.2 described the ability of Ca(OH)₂ particles to diffuse through the apical foramen into the surrounding tissues, affecting on the alkalinity of surrounding tooth environment. The results of the study revealed that in some cases of Ca(OH)₂ materials in paste form (Calxyl red and blue) the pH reached its maximum values, 1 week after the initiation of the experiment measurements and in other cases (Calxyd, Dentbalzam, Plus points), the pH reached its maximum values, 3 weeks after the initial measurement. It is reported in literature, that pH values, within one to three weeks of Ca(OH)₂ use, should reach quite high values (67, 72, 80, 159). In our study was also noted, that concerning the speed of diffusion of Ca(OH)₂ particles into the surrounding tissues, Calxyl red and blue presented

with better results than the rest of used materials, since they caused a maximum pH value, just 1 week after the initiation of the experiment; concerning the alkalinity values, Calxyd and Dentabazam presented with the best results, since their pH reached at values of 12, 3 weeks after the initiation of the experiment. In general, materials in paste form had better results than calcium points. Especially in cases of infection related root resorption and chronic periodontitis, speed of calcium and hydroxyl ions diffusion to the surrounding tissues and alkalinity should be in high levels, since infection should be treated fast and adequately (55, 73).

Experiment 6.3 confirmed that calcium and hydroxyl ions diffuse, through exposed dentin tubules, to the periradicular environment in various rates and with various intensities. This is important in cases of PTCs, as infection related root resorption, when cement on the root surface of the tooth is damaged locally and dentin of the root is exposed (39, 73, 82, 123). External root resorption is initiated when the osteoclasts attack the cement of the root surface. Alkaline environment (thus antibacterial) will inhibit the action of osteoclasts and arrest the root resorption. Composition and consistency of each $\text{Ca}(\text{OH})_2$ material play important role for the above (39, 123). The diffusion speed and the pH values were higher in cases that preparations with $\text{Ca}(\text{OH})_2$ in paste form were used, and more specifically in cases of „Calxyl red“, „Calxyl blue“ and „Dentbalzam“, since after three weeks of use, pH exceeded values of 12. „Plus points“, though, 3 weeks after the initiation of the experiment, caused pH values, lower than 11.4. This experiment was based on some studies found in literature where it is also stated that $\text{Ca}(\text{OH})_2$ pastes promote high pH intracanal and periradicularly and that various vehicles in $\text{Ca}(\text{OH})_2$ materials play major role on the diffusion of calcium and hydroxyl ions through dentin (39, 93, 123).

In cases of occurrence of PTCs in IT, such as PN, chronic periodontitis and infection related root resorption, initiation of endodontic therapy is inevitable. Definite obturation of root canals in IT, though, is quite impossible, since the root apex is wide open. Long-term use of $\text{Ca}(\text{OH})_2$, as intracanal medicament is indicated, since for many years $\text{Ca}(\text{OH})_2$ has been presenting with quite satisfactory results in treatment of infected root canals and in apexification of IT (50, 69, 74, 77, 102, 122, 124, 139, 149, 166). On the other hand, studies in the literature indicate that long-term intracanal use of $\text{Ca}(\text{OH})_2$ influences on the root dentin microhardness and on root dentin fracture resistance (60, 85, 94, 147, 173, 179, 183). In our study (experiment 6.4), it was measured that all teeth which had been filled previously with some preparation with $\text{Ca}(\text{OH})_2$, had higher values of root dentin hardness, than the control teeth (even than the dentin hardness of freshly extracted control teeth). The findings

in the literature report that control teeth had higher values of dentin hardness than teeth that had been previously filled with Ca(OH)_2 and that dentin hardness is significantly decreased in teeth filled with Ca(OH)_2 materials (85, 173, 179, 183). The fact that, in our study, the teeth had been resting in room temperature conditions and in glass tubes for more than one year, may be the reason for having different results. On the other hand, we seaked to check the effect of Ca(OH)_2 on dentin after long-term use – as in cases of apexification, in IT that had suffered a TDI - , and not after 3 weeks use.

Finally, in the last experimental studies (experiment 6.5 i and ii), we examined in SEM the dentin appearance of the same teeth that had been filled with Ca(OH)_2 materials (experiment 6.3); subsequently we compared the microscopic pictures with pictures of teeth that had not been filled with Ca(OH)_2 (control teeth). We also compared our microscopical findings with other studies in literature (65, 127). Although not so many studies exist concerning microscopic evaluation of root dentin, after long-term use of Ca(OH)_2 our findings seemes to be similar with those of the above studies We confirmed the occurrence of hypercalcified areas in intertubular dentin and the existence of calcium crystals in dentin tubules. Measurements of weight percentage of calcium in SEM revealed that calcium weight percentage of dentin in teeth that had been previously filled with Ca(OH)_2 materials was significantly higher than in control teeth. Measurements also revealed that there were significant differences in values of calcium weight percentage in each tooth (this is the reason that after statistical analysis we chose the highest values of calcium weight percentage); in teeth that had not been filled with Ca(OH)_2 , various measurements in root dentin revealed that values of calcium weight percentage were identical but significantly lower than in teeth, filled with Ca(OH)_2 .

6.7 Conclusions

Immediate and proper first aid in dental trauma cases is important factor for the future prognosis of the injured teeth. Inadequate knowledge on providing first aid from adults and professionals that are in daily contact with children could result in delayed treatment. This fact will increase the risk for occurrence of post-traumatic complications, such as pulp necrosis, chronic periodontitis, root resorption which might endanger the life of the injured teeth. In cases of traumatic dental injuries of immature, permanent teeth, the treatment of the above complications is difficult and long-lasting. For the treatment of these complications in immature teeth, endodontics with the use of Ca(OH)_2 is indicated, since over the last decades this material has been proved to have good results in creating an alkalic, antibacterial environment into the root canal and neighbouring tissues.

In our study, the strong antibacterial effect of Ca(OH)_2 is proved, since most of the materials that were used, created an environment with high pH. The materials that should be preferred are the ones that cause high alkaline environment, with pH values around 12. These materials are the materials that are suspensions of Ca(OH)_2 in distilled water and in paste form, such as Dentbalzam, preferably without any other additives. These materials could diffuse through dentin tubules to surrounding tissues and arrest procedures such as infection related root resorption which will lead to loss of the tooth. On the other hand, prolonged intracanal use of Ca(OH)_2 , mainly in traumatised immature teeth, causes structural changes and hypercalcification of root dentin and increase of dentin hardness. This fact might lead to future root fractures, since these teeth are more fragile to masticatory forces. The above indicate that continuous effort on discovering new materials which will have better properties than Ca(OH)_2 is necessary. Until now, though, for treatment of post-traumatic complications in immature teeth, Ca(OH)_2 is, without question, the material of our choice.

7. SUMMARY

This study deals with the evaluation of endodontic treatment using calcium hydroxide materials in immature permanent teeth that have sustained traumas, especially after severe periodontal tissue injuries.

- The aim of this work was:

- a. to analyze the factors that contribute to occurrence of post-traumatic complications, especially after avulsion injuries in immature permanent teeth ,
- b. to investigate the effectiveness of endodontic therapy of these complications with the use of calcium hydroxide materials in immature permanent teeth,
- c. to evaluate various calcium hydroxide materials,
- d. to compare our results with other studies in literature concerning calcium hydroxide properties in cases that it is used as an intra-canal medicament.

- The pre-clinical and clinical parts of this thesis are divided in 3 parts:

1. Evaluation of primary schools teachers` knowledge on providing first aid in cases of tooth avulsion injuries: immediate and proper first aid and fast transfer of children to dental practitioner are determining factors for prognosis of the injured tooth and for future occurrence of post-traumatic complications. 300 teachers were asked to fill questionnaires about avulsion of permanent teeth. 69 % of the respondents had never been informed about providing first aid in dental trauma situations, 34 % had never heard the term “avulsion” and 81 % would keep the avulsed tooth in a dry handkerchief until the transfer to dental practitioner. These results proved inadequate knowledge of teachers in providing first aid in dental trauma situations, although schools are frequent places that these injuries occur. This fact worsens the outcome of dental treatment and the prognosis of injured teeth.

2. Retrospective analysis of 90 avulsed teeth in 57 children: this study was concentrated mostly in type of treatment (replantation or not), time interval between injury and dental treatment, storage medium, occurrence of post-traumatic complications and endodontic treatment in teeth with open root apices. Only 27 teeth (30 %) were replanted; 12 were with unfinished root development. 10 out of 12 teeth with open root apices were endodontically treated with calcium hydroxide (apexification), since revascularisation of the pulp was not noticed and in 8 of them apical barrier was formed. In two cases, pulp revascularisation occurred and subsequent pulp canal obliteration was investigated some time after the injury. Two replanted teeth with unfinished root development had to be extracted because of advanced infection related root resorption. Prolonged extra-oral period or storage of the

avulsed tooth in improper storage medium until tooth replantation influence the outcome of treatment and increase the risk for occurrence of post-traumatic complications.

3. Endodontic intervention in treatment of post-traumatic complications in immature teeth: the records in documentations of a group of 178 patients with 383 teeth, who were treated for dental traumas in Dentistry department of Faculty of Medicine and Faculty hospital in Pilsen, were analyzed, concentrating mostly in occurrence of post-traumatic complications in lateral luxation injuries and in complicated and uncomplicated crown fractures in immature, permanent teeth. 156 out of 383 injured teeth were immature teeth.

In 70 lateral luxations and subluxations in immature teeth, root canal obliteration occurred in 19 cases, pulp necrosis in 9 cases and inflammatory root resorption in 4 cases. In 50 uncomplicated crown fractures in immature teeth, the most frequent post-traumatic complication occurring was pulp necrosis (7 cases, 14 %) which was always treated endodontically. All teeth with pulp necrosis and infection related root resorption, were treated with calcium hydroxide. In 11 out of 12 teeth that had necrotic pulp in the above injuries, calcium hydroxide showed to have good results since resulted in apexification. One tooth had to be extracted because even after filling of root canal with calcium hydroxide paste, infection related root resorption progressed.

- The experimental part of the thesis aimed to bring up new information concerning the effect of calcium hydroxide, when it is used as an intra-canal medicament for short-term and when it is used for long-term, especially in cases of apexification of immature teeth. Various calcium hydroxide materials that are used in Dentistry department of Faculty hospital in Pilsen were used:

- "Calxyd" (Spofa Dental, CZ), composition: Ca(OH)_2 , glycerine, distilled water
- "Calxyl" (OCO Präparate, Germany)
 - a) red, composition: Ca(OH)_2 , distilled water
 - b) blue, composition: Ca(OH)_2 , distilled water, Barium Sulphate
- "Dentbalzam" (Spofa dental, CZ), composition: Ca(OH)_2 , distilled water
- "Calcium hydroxide PLUS points" (Roeko, Germany), composition: 52 % Ca(OH)_2 , 42 % gutapercha, sodium chloride, dyes.

The experimental part of this study was divided in 5 parts:

1. Calcium hydroxide in endodontics – measuring of pH of various materials in vitro:

The aim of this experiment was to measure the pH and to discover if added substances influence the pH values of the above materials.

For that reason, equal weight quantities of each material were applied in equal volume of distilled water in closed plastic tubes and in 10 min., in 30 min. and in 7 days the pH of distilled water was measured using WTW Microprocessor pH meter pH 537.

It was measured that all materials in paste form had high pH values, ranging between 11.65 and 11.82. The pH of calcium points was almost neutral (6.73), even after 1 week.

2. Diffusion of calcium ions into saline solution of various materials in vitro:

For this experiment, the same materials were used. The aim of this experimental study was to investigate the ability of penetration of calcium ions of the used materials with calcium hydroxide through apical foramen in vitro; subsequently to measure the concentration of calcium ions and calculate and compare the pH of these materials.

For that reason each from the above materials was applied in a small plastic pipette with an opening of 0,5 mm, simulating a single root tooth. These pipettes were then placed in small, plastic, closed tubes which were containing saline solution. With the help of WTW Microprocessor pH meter pH 537 the concentration of calcium ions of saline solution was measured repeatedly. These measurements revealed that concentration of calcium ions in saline solution where pipettes containing materials in paste form was higher than in pipettes with calcium points.

3. Calcium and hydroxyl ion diffusion through dentin - comparison study of various materials:

For this experiment, the same materials were used. The aim of this study was to find out the diffusion ability of calcium and hydroxyl ions from root canal to periradicular environment through dentin tubules in cases of exposed root dentin, after endodontic use of calcium hydroxide and subsequently to compare the concentration of calcium ions and changes of pH in the extraradicular environment after the use of various materials with calcium hydroxide.

25 intact premolars extracted for orthodontic reasons were used and in each tooth at middle root third, a cavity was prepared simulating root resorption. The teeth were treated endodontically, instrumented in the same conditions and the same way and in every 5 teeth the same, from the above, material was applied. The trepanation cavity was filled with glass ionomer cement and the apical foramen was covered with the same material.

Two control teeth with their root canals filled with paper points were prepared the same way. The teeth were then placed into plastic tubes containing saline solution. Only the roots

of the teeth were inserted into the solution. At specific time intervals the teeth were placed into reserve plastic tubes and in the original tubes the concentration of calcium ions in the saline solution was measured. After measurement, the teeth were placed back into the original tubes. The measurements were repeated every hour for the first 12 hours and later and later, once every 24 hours for 21 days.

The results revealed that hydroxyl and calcium ions diffuse through dentin tubules into saline solution. The speed of diffusion depends on the contents and on the consistency of each calcium hydroxide preparation. Higher calcium concentration and higher pH in saline solution were measured in cases of materials in paste form.

4. Measurement of dentin hardness in teeth with long-term root canal filling with calcium hydroxide:

The sample teeth of the previous experimental study were used. These teeth had been stored in saline solution, in closed glass tubes, in room temperature for 1 year. The teeth were fixated with ethanol and embedded in EPON using standard procedures. Subsequently, the teeth were placed into a thermostat and then were stored into room temperature conditions. For grinding of samples the machine “HK 350 disc grinder” was used. At the beginning, rough abrasive grinding was performed. The samples were held against the grinding disc, until half of the tooth (longitudinally) was removed, so that the whole pulp cavity was exposed. After rough grinding, plane grinding was performed and then fine grinding. The cooling and lubricant agent which was used in all phases of grinding was distilled water. Final polishing was achieved by Labopol 5 polishing machine. Polishing was performed, in order to produce smooth tooth surfaces, important for nanoindentation technique (dentin hardness measurement).

The root-dentin micro-hardness of 2 specimens of each material and 5 control teeth was measured, using nanoindentation tests with Nano Indenter XP. These measurements were realized towards the whole length of dentin of the root, at the side where the cavity had been prepared. A total of 50 indents were produced, in distance of 200 μm from each other.

These 50 measurements of dentin hardness of each sample were statistically analyzed and evaluated and the mean values of dentin hardness of each specimen and control teeth were produced and compared with each other.

Results revealed that teeth that had been filled with calcium hydroxide presented with higher values of dentin hardness than control teeth, proving that long-term use of calcium hydroxide (eg. in cases of apexification, or treatment of chronic periodontitis) influences root dentin hardness of the teeth.

5. Histological evaluation of dentin hypercalcification after long-term root canal filling with calcium hydroxide:

We performed a microscopic study of root dentin. The aim of this study was to observe in Scanning Electron Microscope (SEM) the root dentin after long-term use of calcium hydroxide. We compared teeth, filled with calcium hydroxide and teeth without any root canal filling. Furthermore, with the help of SEM, we compared the percentage weight of calcium in areas of root dentin between teeth that had been filled with calcium hydroxide and teeth without any endodontic filling. It was observed that teeth that had been previously treated with long-term use of calcium hydroxide had hypercalcified areas at their root dentin, dentin tubules contained particles of calcium hydroxide paste and in intertubular dentin calcium crystals were identified. In addition, the percentage weight of calcium in root dentin was measured higher in teeth that had been filled with calcium hydroxide than the control teeth that had been used in this experiment. The above lead us to the conclusion that long-term use of calcium hydroxide may lead to structural changes and hypercalcification of root dentin.

8. SOUHRN

Tato studie se zabývá vyhodnocením endodontického ošetření s použitím materiálů s hydroxidem vápenatým u stálých zubů s nedokončeným vývojem kořene následkem traumatu, především po úrazech závěsného aparátu.

- Cílem práce je zejména:

- a. analyzovat faktory, které přispívají ke vzniku post-traumatických komplikací, především po avulzi stálých zubů s nedokončeným vývojem kořene,
- b. zkoumat účinnost endodontické léčby těchto komplikací s použitím materiálů s hydroxidem vápenatým u stálých zubů s nedokončeným vývojem kořene,
- c. vyhodnotit různé materiály s hydroxidem vápenatým,
- d. porovnat vlastní výsledky s ostatními studii v literatuře, týkajícími se vlastností hydroxidu vápenatého v případech, kdy je používán jako dočasná kořenová výplň.

- Preklinická a klinická část této studie jsou rozdělené na 3 části:

1. Vyhodnocení znalostí učitelů základních škol při poskytování první pomoci v případech avulze stálých zubů: bezprostřední a správná první pomoc a rychlý transfer dětí k zubnímu lékaři jsou určujícími faktory prognózy poraněných zubů a budoucího výskytu posttraumatických komplikací. 300 učitelů bylo požádáno o vyplnění dotazníků týkajících se avulze stálých zubů. 69 % respondentů nebylo nikdy informováno o poskytnutí první pomoci v situacích dentálního traumatu, 34 % nikdy neslyšelo pojem „avulze“ a 81% by uchovalo vyražený zub během transferu k zubnímu lékaři v suchém kapesníku. Tyto výsledky ukázaly nedostatečné znalosti učitelů v poskytování první pomoci při úrazu zubů, ačkoliv právě školy jsou častým místem výskytu těchto úrazů. Tento fakt zhoršuje výsledek zubního ošetření a prognózu.

2. Retrospektivní analýza 90 vyražených zubů u 58 dětí: tato studie byla zaměřena především na způsob ošetření (replantace či nikoliv), časový interval mezi úrazem a ošetřením zubu, způsob uchování zubu, výskyt posttraumatických komplikací a endodontické ošetření u zubů s nedokončeným vývojem kořene. Pouze 27 zubů (30 %) bylo replantováno; 12 z nich nemělo dokončený vývoj kořene. 10 z 12 zubů s nedokončeným vývojem kořene bylo endodonticky ošetřeno hydroxidem vápenatým (apexifikace), neboť nedošlo k revaskularizaci pulpy a u 8 z nich se vytvořila apikální bariéra. Ve dvou případech se objevila revaskularizace pulpy a následně došlo k postupné obliteraci kořenového kanálku. Dva ze dvou replantované zuby s nedokončeným vývojem kořene bylo nutno extrahovat,

neboť se vyskytla zánětlivá resorpce kořene. Prodloužená extra-orální perioda nebo uložení vyraženého zubu v nevhodném prostředí do doby replantace ovlivňuje výsledek ošetření a zvyšuje riziko výskytu posttraumatických komplikací.

3. Endodontický zásah při ošetření post-traumatických komplikací u zubů s nedokončeným vývojem kořene: byly analyzovány záznamy 178 pacientů s 383 poraněnými zuby, kteří byly ošetřeni na Stomatologické klinice Fakultní nemocnice v Plzni, se zaměřením především na výskyt posttraumatických komplikací u laterálních luxacích, komplikovaných a nekomplikovaných frakturách klinických korunek, u zubů s nedokončeným vývojem kořene. 156 z 383 zraněných zubů nemělo dokončený vývoj kořene.

Ze 70 zubů s nedokončeným vývojem s laterální luxací nebo subluxací se objevila obliterace kořenového kanálku v 19 případech, nekróza pulpy v 9 případech a zánětlivá resorpce kořene ve 4 případech. U 50 nekomplikovaných fraktur klinických korunek u zubů s nedokončeným vývojem kořene byla nejčastější post-traumatickou komplikací nekróza pulpy (7 případů, 14 %) a byla vždy ošetřena endodonticky. Všechny zuby s nekrozou pulpy a zánětlivou resorpcí kořene byly ošetřeny hydroxidem vápenatým. Jeden zub musel být extrahován, vzhledem k tomu, že i po zaplnění kořenového kanálku hydroxidem vápenatým se objevila zánětlivá resorpce kořene.

- Experimentální část této práce je zaměřena na poskytnutí nových informací zabývajících se výsledky ošetření zubů, preparáty s hydroxidem vápenatým jako kořenové výplně. Posuzovali jsme jeho krátkodobé i dlouhodobé použití, především v případech apexifikace zubů s nedokončeným vývojem kořene. Na Stomatologické klinice Fakultní nemocnice v Plzni jsou používány různé materiály s hydroxidem vápenatým:

- "Calxyd" (Spofa Dental, CZ), složení: Ca(OH)_2 , glycerin, destilovaná voda
- "Calxyl" (OCO Präparate, Germany)
 - a) červený, složení: Ca(OH)_2 , destilovaná voda
 - b) modrý, složení: Ca(OH)_2 , destilovaná voda, síran barnatý
- "Dentbalzam" (Spofa Dental, CZ), složení: Ca(OH)_2 , destilovaná voda
- "Calcium hydroxide PLUS points" (Roeko, Germany), složení: 52 % Ca(OH)_2 , 42 % gutaperča, chlorid sodný, barviva.

Experimentální část studie je rozdělena na 5 částí:

1. Hydroxid vápenatý v endodncii – měření pH různých materiálů in vitro:

Cílem experimentu bylo změřit pH a zjistit, zda přidané substance ovlivňují hodnoty pH výše uvedených materiálů. Z tohoto důvodu bylo dané váhové množství každého materiálu rozpouštěním v určitém objemu destilované vody v uzavřených plastových zkumavkách a po 10 min., 30 min. a po sedmi dnech bylo za použití WTW Microprocessor pH meter pH 537 měřeno pH destilované vody. Měřením bylo zjištěno, že všechny materiály ve formě pasty mají vysoké hodnoty pH, pohybující mezi 11,65 a 11,82. Průměrné pH čepů s hydroxidem vápenatým bylo 6,73, dokonce i po 1 týdnu.

2. Difúze kalciových iontů z různých materiálů ve fyziologickém roztoku s in vitro:

Pro tento experiment byly použity výše uvedené materiály. Cílem studie bylo zjistit in vitro schopnost penetrace iontů kalcia použitých materiálů přes foramen apicale. Následně jsme měřili koncentraci iontů kalcia a vypočítali a porovnávali pH těchto materiálů.

Z těchto důvodů byl každý z uvedených materiálů aplikován do malé plastové pipety s otvorem velikosti 0,5 mm, která měla simulovat kořenový kanálek a foramen apicale zubu. Tyto pipety byly následně umístěny do plastových, uzavřených zkumavek s fyziologickým roztokem. S pomocí mikroprocesoru WTW pH meter pH 537 byla opakovaně měřena koncentrace iontů kalcia ve fyziologickém roztoku. Tato měření odhalila, že koncentrace iontů kalcia ve fyziologickém roztoku byla vyšší v pipetách s materiálem ve formě pasty, než s čepý s hydroxidem vápenatým.

3. Průnik kalciových a hydroxylových iontů dentinem – srovnávací studie různých materiálů:

Pro tento experiment byly použity rovněž výše uvedené materiály. Cílem této studie bylo popsat schopnost difúze iontů kalcia a hydroxyly z kořenového kanálku do periradikularního prostředí přes dentinové tubuly. Z tohoto důvodu jsme po endodontickém ošetření (s použitím výše uvedených materiálů s hydroxidem vápenatým) obnažili kořenový dentin. Následně jsme porovnali koncentraci iontů kalcia a změny pH v extraradikulárním prostředí. Bylo použito 25 intaktních premolárů, extrahovaných z ortodontických důvodů. Do každého zubu byla ve střední třetině kořene vypreparována standardní kavita simulující resorpci kořene. Zuby byly ošetřovány endodonticky za stejných podmínek a stejným způsobem. U skupiny 5 zubů byl aplikován vždy stejný materiál. Trepanační otvor byl vyplněn skloionomerním cementem a foramen apicale překryto stejným materiálem. Dva kontrolní zuby, které měly kořenové kanálky vyplněné papírovými čepý, byly ošetřeny stejným

způsobem. Zuby byly následně uloženy do plastových zkumavek s fyziologickým roztokem. Pouze kořeny zubů byly ponořeny v roztoku. V určitých časových intervalech byly zuby umístěny do rezervních plastových zkumavek a v originálních tubusech byla měřena koncentrace iontů kalcia ve fyziologickém roztoku. Po měření byly zuby uloženy zpět do originálních plastových zkumavek. Měření byla opakována v prvních 12–ti hodinách po hodině, následně jednou za 24 hodin a to po dobu 21 dní. Výsledky odhalily, že ionty kalcia a hydroxyly pronikly přes dentinové tubuly do fyziologického roztoku. Rychlost difúze závisela na složení a konzistenci preparátů s hydroxidem vápenatým. Vyšší koncentrace kalcia a vyšší pH fyziologického roztoku bylo naměřeno u materiálů ve formě pasty.

4. Měření tvrdosti dentinu u zubů s dlouhodobou výplní kořenového kanálku s hydroxidem vápenatým:

Byly použity zuby z předchozí experimentální studie. Tyto zuby byly uchovány po dobu 1 roku ve fyziologickém roztoku, v uzavřených skleněných tubusech, při pokojové teplotě. Zuby byly fixovány ethanolem a uloženy v EPON za použití standardních postupů. Postupně byly zuby umístovány do termostatu se specifickými podmínkami a následně byly uskladněny v místnosti s pokojovou teplotou. Pro broušení vzorků byla použita ruční rozbrušovačka „HK 350“. Na počátku se provádělo hrubé abrasivní obroušování. Vzorky byly přidržovány u brusného kotouče, dokud nebyla odstraněna polovina zubu (podélně) a byla odkryta celá dřeňová dutina. Po hrubém broušení se provádělo rovinné broušení a následně jemné broušení. Jako chladicí a lubrikační prostředek byla ve všech fázích použita destilovaná voda. Výsledného vyleštění bylo dosaženo prostřednictvím Labopol 5 leštícího stroje. Leštění bylo provedeno za účelem získání hladkého povrchu zubu, který je důležitý pro techniku nanoindentace (měření tvrdosti dentinu).

Byla měřena mikrotvrdość kořenového dentinu u 2 vzorků každého materiálu a 5 kontrolovaných zubů, za použití nanoindentace testů s Nano Indenter XP. Měření byla realizována po celé délce dentinu kořene, na straně, kde byla preparována kavita ve střední třetině kořene. Bylo realizováno 50 měření tvrdosti vtiskem ve vzdálenosti 200 μm od sebe.

50 výstupů měření tvrdosti dentinu u každého vzorku bylo statisticky analyzováno a vyhodnoceno a průměrné (střední) hodnoty tvrdosti dentinu každého vzorku a kontrolních zubů byly navzájem porovnávány. Výsledky odhalily, že zuby, které byly zaplněny hydroxidem vápenatým, representovaly vyšší hodnoty tvrdosti dentinu než kontrolní zuby. To potvrzuje, že dlouhodobé použití kalcium hydroxidu (např. v případech apexifikace nebo při ošetření chronické periodontitis) ovlivňuje tvrdost kořenového dentinu zubů.

5. Histologické vyhodnocení hypercalcifikace dentinu po dlouhodobém zaplnění kanálku hydroxidem vápenatým:

Provedli jsme mikroskopickou studii kořenového dentinu. Cílem této studie bylo zkoumat ve Scanning Electron Microscope (SEM) kořenový dentin po dlouhodobém použití kalcium hydroxidu. Porovnali jsme zuby zaplněné hydroxidem vápenatým a zuby bez jakékoliv výplně. Kromě toho jsme za pomoci SEM porovnávali procentuální hmotnost kalcia v oblastech kořenového dentinu jak u zubů, které byly zaplněny hydroxidem vápenatým, tak u zubů bez kořenové výplně. Bylo zjištěno, že zuby, které byly dříve ošetřeny dlouhodobou aplikací kalcium hydroxidu měly hypercalcifikované oblasti na svém kořenového dentinu, dentinové tubuly obsahovaly částice kalcium hydroxidové pasty a v intertubulárním dentinu byly identifikovány krystaly kalcia. Kromě toho byla naměřena vyšší váhová procenta materiálů kalcia v kořenovém dentinu u zubů, které byly vyplněny kalcium hydroxidem než u kontrolních zubů, které byly použity pro tento experiment. Výše uvedené vede k závěru, že dlouhodobé použití kalcium hydroxidu může vést ke strukturálním změnám a hypercalcifikaci kořenového dentinu.

9. LITERATURE

1. Aggarwal V, Logani A, Shan N.: Complicated crown fractures-management and treatment options. *Int Endod J* 2009; 42: 740-753.
2. Al-Badri S, Kinirons M, Cole BOI, Welbury RR.: Factors afflicting resorption in traumatically intruded permanent incisors in children. *Dent Traumatol* 2002; 18: 34-39.
3. Al Jundi SH.: Type of treatment, prognosis, and estimation of time spent to manage dental trauma in late presentation cases at a dental teaching hospital: a longitudinal and retrospective study. *Dent Traumatol* 2004; 20: 1-5.
4. American Association of Endodontists: Treatment of the avulsed permanent tooth. Recommended guidelines of the American Association of Endodontists. *Dent Clin North Am* 1995; 39: 221-25.
5. Andersen M, Lund J, Andreasen JO, Andreasen FM.: In vitro solubility of human pulp tissue in calcium hydroxide and sodium hypochlorite. *Endod Dent Traumatol* 1992; 8: 104-108.
6. Andersson L, Bodin I.: Avulsed human teeth replanted within 15 minutes – A long-term clinical follow-up study. *Endod Dent Traumatol* 1990; 6: 37-42.
7. Andersson L, Lindskog S, Blomlof L, Hedstrom KG, et al.: Effect of masticatory stimulation on dentoalveolar ankylosis after experimental tooth replantation. *Endod Dent Traumatol* 1985; 1: 13-16.
8. Andreasen FM, Vestergaard Pedersen B.: Prognosis of luxated permanent teeth – the development of pulp necrosis. *Endod Dent Traumatol* 1985; 1: 207-220.
9. Andreasen FM, Yu Z, Thomsen BL.: The relationship between pulpal dimensions and the development of pulp necrosis after luxation injuries in the permanent dentition. *Endod Dent Traumatol* 1986; 2: 90-98.
10. Andreasen FM, Yu Z, Thomsen BL, Andersen PK.: Occurrence of pulp canal obliteration after luxation injuries in the permanent dentition. *Endod Dent Traumatol* 1987; 3: 103-115.
11. Andreasen JO.: A time-related study of periodontal healing and root resorption activity after replantation of mature permanent incisors in monkeys. *Swed Dent J* 1980; 4: 101-110.
12. Andreasen JO.: Challenges in clinical dental traumatology. *Endod Dent Traumatol* 1985; 1: 45-55.
13. Andreasen JO.: Etiology and pathogenesis of traumatic dental injuries. A clinical study of 1298 cases. *Scand. J Dent Res* 1970; 78: 339-342.

14. Andreasen JO, Andreasen FM.: Avulsions. Textbook and color atlas of traumatic injuries to the teeth. 3rd ed. St Louis: Mosby, 1994; 383-425.
15. Andreasen JO, Andreasen FM.: Essentials of Traumatic Injuries to the Teeth. 2nd edn. Copenhagen, Munksgaard Mosby; 2000; 115-131.
16. Andreasen JO, Andreasen FM, Andersson L.: Avulsions. Textbook and color atlas of Traumatic injuries to the teeth. 4th ed. Oxford: Blackwell Munksgaard, 2007; 444-488.
17. Andreasen JO, Andreasen FM, Andersson L.: Classification, Epidemiology and Etiology. Textbook and color atlas of Traumatic injuries to the teeth. 4th ed. Oxford: Blackwell Munksgaard, 2007; 217-254.
18. Andreasen JO, Andreasen FM, Andersson L.: Endodontic Management and the Use of Calcium Hydroxide in Traumatized Permanent Teeth (Cvek M.). Textbook and color atlas of Traumatic injuries to the teeth. 4th ed. Oxford: Blackwell Munksgaard 2007: 598-657.
19. Andreasen JO, Andreasen FM, Andersson L.: Examination and Diagnosis of Dental injuries. Textbook and color atlas of Traumatic injuries to the teeth. 4th ed. Oxford: Blackwell Munksgaard 2007; 271-272.
20. Andreasen JO, Andreasen FM, Andersson L.: Extrusive Luxation and Lateral Luxation. Textbook and color atlas of Traumatic injuries to the teeth. 4th ed. Oxford: Blackwell Munksgaard 2007; 411-427.
21. Andreasen JO, Andreasen FM, Skeie A, Hjorting-Hansen E, et al.: Effect of treatment delay upon pulp and periodontal healing of traumatic dental injuries – a review article. Dent Traumatol 2002; 18(3): 116-128.
22. Andreasen JO, Bakland L, Matras R, Andreasen FM.: Traumatic intrusion of permanent teeth. Part 1. An epidemiologic study of 216 teeth. Dent Traumatol 2006; 22: 83-89.
23. Andreasen JO, Bakland L, Matras R, Andreasen FM.: Traumatic intrusion of permanent teeth. Part 2. A clinical study of the effect of preinjury and injury factors, such as sex, age, stage of root development, tooth location, and extent of injury including number of intruded teeth on 140 intruded permanent teeth. Dent Traumatol 2006; 22: 90-98.
24. Andreasen JO, Bakland L, Matras R, Andreasen FM.: Traumatic intrusion of permanent teeth. Part 3. A clinical study of the effect of treatment variables such as treatment delay, method of repositioning, type of splint, length of splinting and antibiotics on 140 intruded permanent teeth. Dent Traumatol 2006; 22: 99-111.
25. Andreasen JO, Borum MK, Jakobsen HL, Andreasen FM.: Replantation of 400 avulsed permanent incisors. I. Diagnosis of healing complications. Endod Dent Traumatol 1995; 11: 51-58.

26. Andreasen JO, Borum MK, Jakobsen HL, Andreasen FM.: Replantation of 400 avulsed permanent incisors. II. Factors related to pulp healing. *Endod Dent Traumatol* 1995; 11: 59-68.
27. Andreasen JO, Borum MK, Andreasen FM.: Replantation of 400 avulsed permanent incisors. III. Factors related to root growth after replantation. *Endod Dent Traumatol* 1995; 11: 69-75.
28. Andreasen JO, Borum MK, Jakobsen HL, Andreasen FM.: Replantation of 400 avulsed permanent incisors. IV. Factors related to periodontal ligament healing. *Endod Dent Traumatol* 1995; 11: 76-89.
29. Andreasen JO, Ravn J.: Epidemiology of traumatic dental injuries to primary and permanent teeth in a Danish population sample. *Int J Oral Surg* 1972; 1: 235-239.
30. Barnett F.: The role of endodontics in the treatment of luxated permanent teeth. *Dent Traumatol* 2002; 18: 47-56.
31. Behnia A, Strassler HE, Cambell R.: Repairing iatrogenic root perforations. *J Am Dent Assoc* 2000; 131(2): 196-201.
32. Berkovitz BKB, Holland GR, Moxham BJ.: 9. Dentine. *Oral Anatomy, Histology and Embryology*. 3rd edition. Mosby 2005, 127-135.
33. Blakytyn C, Surbutis C, Thomas A, Hunter ML.: Avulsed permanent incisors: knowledge and attitudes of primary school teachers with regard to emergency management. *Int J Paed Dent* 2001; 11: 327-332.
34. Borum MK, Andreasen JO.: Therapeutic and economic implications of traumatic dental injuries in Denmark: an estimate based on 7549 patients treated at a major trauma centre. *Int J Paediat Dent* 2001; 11: 249-258.
35. Bystrom A, Claesson R, Sundqvist G.: The antibacterial effect of camphorated paramonochlorophenol, camphorated phenol and calcium hydroxide in the treatment of infected root canals. *Endod Dent Traumatol* 1985; 1: 170-175.
36. Bystrom A, Sundqvist G.: Bacteriologic evaluation of the efficacy of mechanical root instrumentation in endodontic therapy. *Scand J Dent Res* 1981; 89: 321-328.
37. Caglar E, Ferreira LP, Kargul B.: Dental trauma management knowledge among a group of teachers in two south European cities. *Dent Traumatol* 2005; 21: 258-262.
38. Caldas AD, Burgos MEA.: A retrospective study of traumatic dental injuries in a Brazilian dental trauma clinic. *Dent Traumatol* 2001; 17: 250-253.
39. Camargo CHR, Bernardineli N, Valera MC.: Vehicle influence on calcium hydroxide pastes diffusion in human and bovine teeth. *Dent Traumatol* 2006; 22: 302-306.

40. Cardoso M, De Carvalho Rocha MJ.: Traumatized primary teeth in children assisted at the Federal University of Santa Catarina, Brazil. *Dent Traumatol* 2002; 18: 129-133.
41. Carrotte P.: Endodontics: Part 9. Calcium hydroxide, root resorption, endo-perio lesions. *British Dental Journal* 2004; 197: 735-743.
42. Carter AP, Zoller G, Harlin VK, Johnson CJ.: Dental injuries in Seattle's public school children – school year 1969-1970. *J Public Health Dent* 1972; 32: 251-254.
43. Celenk S, Sezgin B, Ayna B, Atakul F.: Causes of dental fractures in the early permanent dentition: A retrospective study. *J Endo* 2002; 28: 208-210.
44. Chamorro M, Regan J, Opperman L, Kramer P.: Effect of storage media on human periodontal ligament cell apoptosis. *Dent Traumatol* 2008; 24: 11-16.
45. Chappuis V, von Arx T.: Replantation of 45 avulsed permanent teeth: a 1-year follow-up study. *Dent Traumatol* 2005; 21: 289-296.
46. Chawla HS.: Apexification. Follow-up after 6-12 years. *J Ind Pedodont Prev Dent* 1991; 8: 38-40.
47. Chen YL, Tsai TP, See LC.: Survey of incisor trauma in second grade students of Central Taiwan. *Chan Gung Med J* 1999; 22: 212-219.
48. Cvek M.: Partial pulpotomy in crown fracture incisors: results 3 to 15 years after treatment. *Acta Stomatol Croat* 1993; 27: 167-173.
49. Cvek M.: Prognosis of luxated non-vital maxillary incisors treated with calcium hydroxide and filled with guttapercha. *Endod Dent Traumatol* 1992; 8: 45-55.
50. Cvek M.: Treatment of non-vital permanent incisors with Calcium Hydroxide. Follow-up of periapical repair and apical closure of immature roots. *Odontol Revy* 1972; 23: 27-44.
51. Cvek M, Cleaton-Jones P, Austin J, Kling M.: Effect of topical application of doxycycline on pulp revascularization and periodontal healing in reimplanted monkey incisors. *Endod Dent Traumatol* 1990; 6: 170-176.
52. Cvek M, Granath LE, Hollender L.: Treatment of non-vital permanent incisors with calcium hydroxide. Part 3. Variation of occurrence of ankylosis of reimplanted teeth with duration of extra-alveolar period and storage environment. *Odontol Revy* 1974; 25: 43-56.
53. Cvek M, Hollender I, Nord C-E.: Treatment of non-vital permanent incisors with calcium hydroxide. VI. A clinical, microbiological and radiological evaluation of treatment on one sitting of teeth with mature and immature roots. *Odont Revy* 1976; 27: 93-108.

54. David J. Kenny, Michael J. Casas and The Toronto Dental trauma Research Group.: Dental injuries: A field-side guide for parents, athletic trainers and dentists. Toronto Dental Trauma Research Group 2008; 1: 1-5.
55. Deardorf KA, Swartz ML, Newton CW, et al.: Effect of root canal treatment on dentin permeability. *J Endodon* 1994; 20: 1-5.
56. Dewhurst SN, Mason C, Roberts GJ.: Emergency treatment of orodental injuries: a review. *J Oral Maxillofac Surg* 1998; 36: 165-175.
57. Diangelis AJ.: Traumatic dental injuries: current treatment concepts. *J A Dent Ass* 1998; 129: 1401-13.
58. Donaldson M, Kinirons MJ.: Factors affecting the time of onset of resorption in avulsed and replanted incisor teeth in children. *Dent Traumatol* 2001; 17: 205-209.
59. Doyle DL, Dumsha TC, Sydiskis RJ.: Effect of soaking in Hank's balanced salt solution or milk on PDL cell viability of dry stored human teeth. *Endod Dent Traumatol* 1998; 14: 221-224.
60. Doyon GE, Dumsha T, Fraunhofer A.: Fracture Resistance of Human Root Dentin Exposed to Intracanal Calcium Hydroxide. *J Endodon* 2005; 31(12): 895-897.
61. Dunsha TC, Gutman JL.: Clinical techniques for the placement of calcium hydroxide. *Comp Educat Art* 1985; 6: 482-489.
62. Eilert-Peterson E, Andersson L, Sorensen S.: Traumatic oral vs non-oral injuries. An epidemiological study during one year in a Swedish county. *Swed Dent J* 1997; 21: 55-68.
63. Elena C, Pozzi F, von Arx T.: Pulp and periodontal healing of laterally luxated permanent teeth: results after 4 years. *Dent Traumatol* 2008; 24: 658-662.
64. Ellis RG.: The classification and treatment of injuries to the teeth of children. Year Book Medical Publishers. 5th ed. Chicago, 1970; 56-199.
65. El-Sayed JM, Ezzat KM.: Qualitative and quantitative assay of calcium content of root canal dentin walls irrigated with calcium hydroxide solution. *Cairo Dental J* 2001; 17: 179-184.
66. Estrela C, Bamman LL, Pecora JD.: Control of microorganisms in vitro by calcium hydroxide pastes. *Int Endod J* 2001; 34: 341-345.
67. Estrela C, Sydney GB, Bammann LL, Felipe Junior O.: Mechanism of Action of Calcium and Hydroxyl Ions of Calcium Hydroxide on Tissue and Bacteria. *Braz Dent J* 1995; 6(2): 85-90.
68. Filippi A, Pohl Y, von Arx T.: Decoronation of an ankylosed tooth for preservation of alveolar bone prior to implant placement. *Dent Traumatol* 2001; 17: 93-5.

69. Finucane D, Kinirons MJ.: Non-vital immature permanent incisors: factors that may influence treatment outcome. *Endod Dent Traumatol* 1999; 15: 273-277.
70. Fischer CH.: Hard tissue formation of the pulp in relation to treatment of traumatic injuries. *Int Dent J* 1974; 24: 387-396.
71. Flores MT, Andersson L, Andreasen JO, et al.: Guidelines for the management of traumatic dental injuries. II. Avulsion of permanent teeth. *Dent Traumatol.* 2007; 23 (3) :130-136.
72. Foreman PC, Barnes I.: A review of calcium hydroxide. *Int Endod J* 1999; 25: 481-482.
73. Foster KH, Kulild JC, Weller RN.: Effect of smear layer removal on the diffusion of calcium hydroxide through radicular dentin. *J Endodon* 1993; 19: 136-140.
74. Frank AL.: Therapy for the divergent pulpless tooth by continued apical formation. *J Am Dent Assoc* 1966; 72: 87-93.
75. Frank RM, Nalbandian J.: Structure and Ultrastructure of dentine. Teeth. *Handbook of Microscopic Anatomy.* Springer Verlag, Berlin 1989; 173-247.
76. Frost HM.: Preparation of thin undercalcified bone sections by rapid method. *Stain Technol* 1958; 33: 272-273.
77. Gaikwad B, Banga KS, Thakore AJ.: Effect of Calcium Hydroxide as an intracanal dressing on apical seal – An in-vitro study. *J Endodon* 2000; 12: 7-12.
78. Gassner RJ, Hackl W, Tuli T, Fink C, et al.: Differential profile of facial injuries among mountainbikers compared with bicyclists. *J trauma* 1999; 47: 50-54.
79. Geels K, Fowler DB, Kopp WU, Ruckert M.: Metallographic and Materialographic Specimen Preparation, Light Microscopy, Image Analysis and Hardness Testing. *ASTM International, USA* 2007; 15-21.
80. Georgopoulou M, Kontakiotis E, Nakou M.: In vitro evaluation of the effectiveness of calcium hydroxide and paramonochlorophenol on anaerobic bacteria from the root canal. *Endod Dent Traumatol* 1993; 9: 249-253.
81. Glendor U, Halling A, Andersson L, Eilert Petersson E.: Incidence of traumatic injuries in children and adolescents in the county of Vastmanland. *Swed Dent J* 1996; 20(1-2): 15-28.
82. Gomes I, Chevitarese O, De Almeida N.: Diffusion of calcium through dentin. *J Endodon* 1996; 22(11): 590-595.
83. Haapasalo M, Orstavik D.: In vitro infection and disinfection of dentinal tubules. *J Dent Res* 1987; 66: 1375-1379.

84. Hammarstrom L, Blomlof L, Feiglin B, Andersson L, et al.: Replantation of teeth and antibiotic treatment. *Endod Dent Traumatol* 1986; 2: 51-57.
85. Hasheminia Mohsen S, Norozynasab S, Feizianfard M.: The effect of Three Different Calcium Hydroxide Combinations on Root Dentine Microhardness. *Res. J Biol Sc* 2009; 4(1): 121-125.
86. Hayrinen-Immonen R, Sane J, Perkki K, Malmstrom M.: A six-year follow-up study of sports-related dental injuries in children and adolescents. *Endod Dent Traumatol* 1990; 6: 208-212.
87. Hecová H, Merglová V., Houba R.: Injuries of permanent teeth periodontal tissues. *LKS* 2005; 15: 12-17.
88. Hecová H., Tzigkounakis V., Merglová V., Stehliková J.: Retrospektivní studie 447 stálých zubů s poraněním závěsného aparátu. *Čes Stomat.* 2008; 108: 135-141.
89. Heithersay GS.: Calcium hydroxide in the treatment of pulpless teeth with associated pathology. *J Br Endod Soc* 1962; 8: 74-93.
90. Hermann B.: Calcium hydroxyd als Mittel zum Behandel und Füllen von Zahnwurzelkanälen (dissertation). 1920, Würzburg, Germany: Faculty of Medicine, University of Würzburg.
91. Hess W.: Pulp amputation as a method of treating root canals. *Dent Items Int* 1929; 51: 596-597.
92. Hiewy Tarik A, Kubad Taher D.: Luxation Dental Injuries: Review of Treatment Guidelines And Endodontic Considerations. *JEMTAC (Journal of Emergency Medicine, Trauma and Acute Care)*, 2006; 6(2): 78-84.
93. Hydroxide-Based Materials: Ultracal XS, Vitapex, Roeko Calcium-Hydroxide Plus points and Pure Calcium Hydroxide through Radicular Dentin. *Int J Oral Med Sc* 2004; 3(2): 75-82.
94. Imbeni V, Nalla RK, Bosi C, et al.: In vitro fracture toughness of human dentin. *Wiley Periodicals, Int. J Biomed Mater Res* 2003; 66A: 1-9.
95. Ingle JJ, Bakland LK, Baumgartner J: 36. Endodontic considerations in Dental Trauma (Trope M). *Ingle's Endodontics* 6. 6th edition. 2008; 1330-1357.
96. Jackson NG, Waterhouse PJ, Maquire A.: Factors affecting treatment outcomes following complicated crown fractures managed in primary and secondary care. *Dent Traumatol* 2006; 22: 179 – 185.
97. Jacobsen I.: Criteria for diagnosis of pulp necrosis in traumatized permanent incisors. *European Journal of Oral Sciences* 2007; 88: 306-312.
98. Janíčková M, Statelová D, Stiffel W.: Injuries of maxillofacial region in children. *Čes Stomat* 2003; 103: 224-8.

99. Johnson JE.: Causes of accidental injuries to the teeth and jaws. *J Public Health Dent* 1975; 35: 123-131.
100. Johnson WT, Goodrich JL, James GA.: Replantation of avulsed teeth with immature root development. *Oral Surg Med Oral Pathol* 1985; 60: 420-427.
101. Jundi SH, Al-Waeili H, Khairaiyah K.: Knowledge and attitude of Jordanian school health teachers with regards to emergency management of dental trauma. *Dent Traumatol* 2005; 21: 183-187.
102. Kerekes K, Heide S, Jakobsen I.: Follow-up examination of endodontic treatment in traumatized juvenile incisors. *J Endod* 1980; 6: 744-748.
103. Kilian J.: Rozdělení úrazů, názvosloví. Úrazy zubů u dětí. Avicenum/Zdravotnické nakladatelství, Praha, 1985; 25-34.
104. Kinirons MJ, Boyd DH, Gregg TA.: Inflammatory and replacement resorption in reimplanted permanent incisors teeth: a study of characteristics of 84 teeth. *Endod Dent Traumatol* 1999; 15: 269-272.
105. Kinoshita S, Kojima R, Taguchi Y, Noda T.: Tooth replantation after traumatic avulsion: report of 10 cases. *Dent Traumatol* 2002; 18: 153-56.
106. Kleier DJ, Averbach RE, Kawulok TC.: Efficient calcium hydroxide placement within the root canal. *J Prosth Dent* 1985; 53: 509-510.
107. Kling M, Cvek M, Mejare I.: Rate and predictability of pulp revascularization in therapeutically reimplanted permanent incisors. *Endod Dent Traumatol* 1986; 2: 83-89.
108. Koch G, Poulsen S.: Traumatic injuries-examination, diagnosis and immediate care. *Pediatric Dentistry*. Munksgaard, Copenhagen, 2001; 366-367.
109. Lee R, Barrett EJ, Kenny DJ.: Clinical outcomes for permanent incisor luxations in a pediatric population. II. Extrusions. *Dent Traumatol* 2003; 19: 274-279.
110. Leonardo MR, Silva LAB, Tanomaru Filho M, et al.: In vitro evaluation of antimicrobial activity of sealers and pastes used in endodontics. *J Endodon* 2000; 26: 391-394.
111. Lohbauer U, Gambarini G, Ebert J, et al.: Calcium released and pH characteristics of calcium plus points. *Int Endod J* 2005; 38(10): 683-689.
112. Mackie IC, Bentley EM, Worthington HV.: The closure of open apices in non-vital immature incisor teeth. *Br Dent J* 1988; 165: 169-173.
113. Mackie IC, Hill FJ, Worthington HV.: Comparison of two calcium hydroxide pastes used for endodontic treatment of non-vital immature incisor teeth. *Endod Dent Traumatol* 1994; 10: 90-99.

114. Mackie IC, Worthington HV.: An investigation of replantation of traumatically avulsed permanent incisor teeth. *Br Dent J* 1992; 172: 17-20.
115. Mahajan SK, Sidhu SS.: Effect of fluoride on root resorption of autogenous dental replants. Clinical study. *Aust Dent J* 1981; 26: 42-45.
116. Majorana A, Bardellini E, Conti G, Keller E, et al.: Root resorption in dental trauma: 45 cases followed for 5 years. *Dent Traumatol* 2003; 19: 262-65.
117. Malmgren B.: Decoronation: How, Why and When? *Californian Dental Assoc. J* 2000; 131: 65-75.
118. Malmgren B, Malmgren O.: Rate of infraposition of reimplanted ankylosed incisors related to age and growth in children and adolescents. *Dent Traumatol* 2002; 18: 28-36.
119. Malmgren B, Cvek M.: Surgical treatment of ankylosed and infrapositioned reimplanted incisors in adolescents. *Scand J Dent Res* 1984; 92(5): 391-399.
120. Merglová V, Tzigkounakis V.: Retrospective clinical study 64 avulsed permanent teeth in children. *Čes Stomat* 2004; 104: 89-98.
121. Mestrinho HD, Bezerra AC, Carvalho JC.: Traumatic dental injuries in Brazilian preschool children. *Braz Dent J* 1998; 9: 101-104.
122. Morfis AS, Siskos G.: Apexification with the use of calcium hydroxide: a clinical study. *J Clin Pediatr Dent* 1991; 16(1): 13-19.
123. Mori Garrido G, Ferreira FC, Batista de Souza FR.: Evaluation of the diffusion capacity of calcium hydroxide pastes through the dentinal tubules. *Braz Oral Res* 2009; 23(2): 133-137.
124. Morse DR, O'Larnic J, Yesilsoy C.: Apexification: review of the literature. *Quintessence Int* 1990; 21: 589-598.
125. Mouden LD, Bross JD.: Legal issues affecting dentistry's role in preventing child abuse and neglect. *J Am Dent Assoc* 1995; 126: 1173-1180.
126. Mouzakes J, Koltai PJ, Kuhar S, Bernstein DS, et al.: The impact of airbags and seat belts on the incidence and severity of maxillofacial injuries in automobile accidents in New York State. *Arch Otolaryngol Head Neck Surg* 2001; 127: 1189-1193.
127. Naaman A, Kaloustian H, Ounsi HF.: A scanning electron microscopic evaluation of root canal wall cleanliness after calcium hydroxide removal using three irrigation regimens. *Contemporary Dental Practice J* 2007; 8(1): 1-12.
128. Nikoui M, Kenny DJ, Barret EJ.: Clinical outcomes for permanent incisor luxations in a pediatric population. III. Lateral luxations. *Dent Traumatol* 2003; 19: 280-285.

129. O'Brien M.: Children's dental health in the United Kingdom 1993. Her Majesty's Stationery Office, 1994.
130. Ohman A.: Healing and sensitivity to pain in young replanted human teeth. An experimental, clinical and histological study. *Odontologisk Tidsskrift* 1965; 73:165-228.
131. Oikarinen K, Gundlach KKH, Pfeifer G.: Late complications of luxation injuries to teeth. *Endod Dent Traumatol* 1987; 3: 296-303.
132. Oliver WC, Pharr GM.: An improved technique for determining hardness and elastic modulus using load and displacement sensing indentation experiments. *J. Mater. Res.* 1992; 7: 1564–1583.
133. Oluwole TO, Leverett DH.: Clinical and epidemiological survey of adolescents with crown fractures of permanent anterior teeth. *Pediatr Dent* 1986; 8: 221-223.
134. O'Mullane DM.: Injured permanent incisor teeth; An epidemiological study. *J Irish Dent Assoc* 1972; 18: 160-173.
135. Orstavik D, Kerekes K, Molven O.: Effects of extensive apical reaming and calcium hydroxide dressing on bacterial infection during treatment of apical periodontitis. *Int Endod J* 1991; 24: 1-7.
136. Pacheco LF, Garcia Filho PF, Letra A, Menezes R, et al.: Evaluation of the knowledge of the treatment of avulsions in elementary school teachers in Rio de Janeiro, Brazil. *Dent Traumatol* 2003; 19: 76-78.
137. Perunski S, Lang B, Pohl Y, Filippi A.: Level of information concerning dental injuries and their prevention in swiss basketball – a survey among players and coaches. *Dent Traumatol* 2005; 21: 195-200.
138. Pohl Y, Filippi A, Kirschner H.: Results after replantation of avulsed permanent teeth. II. Periodontal healing and the role of physiologic storage and antiresorptive-regenerative therapy. *Dent Traumatol* 2005; 21: 93-101.
139. Rafter M.: Apexification: a review. *Dent Traumatol* 2005; 21(1): 1-8.
140. Ravn J.: Dental injuries in Copenhagen schoolchildren, school years 1967-1972. *Community Dent Oral Epidemiol* 1974; 2: 231-245.
141. Ravn J.: Follow-up study of permanent incisors with enamel – dentin fractures after acute trauma. *Scand J Dent Res* 1981; 89: 355-65.
142. Rho JY, Zioupos P, Currey JD, Pharr GM.: Variations in the Individual Thick Lamellar Properties within Osteons by Nanoindentation. *Elsevier. Bone J* 1999; 25(3): 295-300.
143. Robertson A.: A retrospective evaluation of patients with uncomplicated crown fractures and luxation injuries. *Endod Dent Traumatol* 1998; 14: 245- 56.

144. Robertson A, Andreasen FM, Andreasen JO, Noren JG.: Long-term prognosis of crown-fractured permanent incisors. The effect of stage of root development and associated luxation injury. *Int J Paediat Dent* 2000; 10: 157-159.
145. Robertson A, Andreasen FM, Bergenholtz G, Andreasen JO, et al.: Incidence of pulp necrosis subsequent to pulp canal obliteration from trauma of permanent incisors. *J Endod* 1996; 22(10): 557-560.
146. Robertson A, Robertson S, Norén JG.: A retrospective evaluation of traumatised permanent teeth. *Int J Paediatr Dent* 1997; 7: 217-26.
147. Rosenberg B, Murray PE, Namerow K.: The effect of calcium hydroxide root filling on dentin fracture strength. *Dent Traumatol* 2006; 23(1): 26-29.
148. Safavi KE, Spangberg LSW, Langeland K.: Root canal dentinal tubule disinfection. *J Endod* 1990; 16: 207-210.
149. Sceehey EC, Roberts GJ.: Use of Calcium Hydroxide for apical barrier formation and healing in non-vital immature permanent teeth: a review. *Br Dent J* 1997; 183: 241-246.
150. Schmitt D, Lee J, Bogen G.: Multifaceted use of ProRoot MTA root canal repair material. *Pediatr Dent* 2001; 23(4): 326-330.
151. Schwartz RS.: Mineral trioxide aggregate: a new material for endodontics. *J Am Dent Assoc* 1999; 130(7): 967-975.
152. Shulman JD, Peterson J.: The association between incisor trauma and occlusal characteristics in individuals 8-50 years of age. *Dent Traumatol* 2004; 20: 67-74.
153. Siqueira Junior JF, Lopes HP.: Mechanisms of antibacterial activity of calcium hydroxide: a critical review. *Int Endod J* 1999; 32: 361-369.
154. Siu-fai Leung.: Traumatic Dental Injuries to the Permanent Dentition. *Dental Bulletin – The Hong Kong Medical Diary* 2006; 11: 15-17.
155. Sjogren U, Figdor D, Spangberg L, et al.: The antibacterial effect of calcium hydroxide as a short term intracanal dressing. *Int Endod J* 1991; 24: 119-125.
156. Skaare AB, Jacobsen L.: Dental injuries in Norwegians aged 7-18 years. *Dent Traumatol* 2003; 19: 67-71.
157. Soares J, Santos S, Cesar C, Silva P, et al.: Calcium hydroxide induced apexification with apical root development: a clinical case report. *Int Endod J* 2008; 41:710-719.
158. Sogaard-Pedersen B, Boye H, Matthiessen ME.: Scanning electron microscope observations on collagen fibers in human dentin and pulp. *Scand J of Dent Research* 1990; 98: 89-95.

- 159.Solak H., Oztan MD.: The pH changes of four different calcium hydroxide mixtures used for intracanal medication. *J Oral Rehab* 2003; 30(4): 436-439.
- 160.Sonmez IS, Sonmez H.: Long-term follow-up of a complicated crown fracture treated by partial pulpotomy. *Int Endod J* 2007; 40(5): 398-403.
- 161.Stockwell AJ.: Incidence of dental trauma in the Western Australian School Dental Service. *Community Dent Oral Epidemiol* 1988; 16: 294-298.
- 162.Te Velde J, Burkhardt R, Kleiverda K, Leenbeers-Binnendijk L, et al.: Methylmetacrylate as an embedding medium in histopathology. *Histopathology* 1977; 319-320.
- 163.Torabinejad M, Chivian N.: Clinical applications of mineral trioxide aggregate. *J Endod* 1999; 25(3): 197-205.
- 164.Torabinejad M, Walton RE.: 10. Management of traumatic dental injuries. *Endodontics: principles and practice*; 4th edition. 2008; 175-176.
- 165.Traebert J, Peres MA, Blank V, Boell RD, et al.: Prevalence of traumatic dental injury and associated factors among 12-year-old school children in Florianopolis, Brazil. *Dent Traumatol* 2003; 19: 15-18.
- 166.Tronstad L.: Treatment of immature non-vital teeth – Apexification. *Clinical Endodontics – A textbook*. 2nd Revised edition. Thieme 2003; 120-122.
- 167.Tronstad L, Andreasen JO, Hasselgren G, Kristerson L, et al.: PH changes in dental tissues after root canal filling with calcium hydroxide. *J Endod* 1981; 7: 17-21.
- 168.Tronstad L, Barnett F, Riso K, Slots J.: Extraradicular endodontic infections. *Endod Dent Traumatol* 1987; 3: 86-90.
- 169.Trope M.: Clinical management of the avulsed tooth: Present strategies and Future directions. *Dent Traumatol* 2002; 18: 1-11.
- 170.Trope M.: Current concepts in the replantation of avulsed teeth. *Alpha Omegan*, 1997; 90: 56-63.
- 171.Trope M.: Root resorption due to dental trauma. *Endod Topics* 2002; 2: 79-100.
- 172.Trope M, Friedman S.: Periodontal healing of replanted dog teeth stored in Viaspan, milk and Hank`s Balanced Salt Solution. *Endod Dent Traumatol* 1992; 8: 183-188.
- 173.Tsuzuki T, Ogawa H, Kitamura K, et al.: A study of Hardness Change of Root Canal Dentin Applied with Calcium Hydroxide. *Japan J of Conserv Dent* 2000; 43(1): 158-162.
- 174.Turkun M, Gengiz T.: The effects of sodium hypochlorite and calcium hydroxide on tissue dissolution and root canal cleanliness. *Int Endod J* 1997; 30: 135-142.

175. Tzigkounakis V, Meglová V.: Attitude of Pilsen primary school teachers in dental traumas. *Dent Traumatol* 2008; 24: 528-531.
176. Tzigkounakis V, Merglová V, Hecová H, Netolický J.: Retrospective clinical study of 90 avulsed permanent teeth in 58 children. *Dent Traumatol* 2008; 24: 598-602.
177. Villanueva AR.: Methods for preparing and interpreting mineralized sections of bone. *Bone Morphometry*, Ottawa Press 1976; 33-34.
178. Walker A, Brenchley J.: It's a knockout. Survey of the management of avulsed teeth. *Accid Emerg Nurs* 2000; 8(2): 66-70.
179. White DJ, Lacefield WR, Chavers LS, et al.: The effect of Three Commonly Used Endodontic Materials in the Strength and Hardness of Root Dentin. *J Endodon* 2002; 28(12): 828-830.
180. Witherspoon DE, Ham K.: One-visit apexification: technique for inducing root-end barrier formation in apical closures. *Pract Prosed Aesthet Dent* 2001; 13(6): 455-460.
181. Wood EB, Freer TJ.: A survey of dental and oral trauma in south – east Queensland during 1998. *Aust Dent J* 2002; 47: 142-46.
182. World Health Organization: Application of the International Classification of Diseases to Dentistry and Stomatology (ICD-DA). Geneva, 1978; 88-89.
183. Yoldas O, Doan C, Seydaoglu G.: The effect of two different calcium hydroxide combinations on root dentine microhardness. *Int Endod J* 2004; 37(12): 828-831.
184. Zuhail K, Semra OEM, Hüseyin K.: Traumatic injuries of the permanent incisors in children in southern Turkey: a retrospective study. *Dent Traumatol* 2005; 21: 20-25.

10. Author's publications, presentations, posters relevant with this thesis

Presentations:

1. Tzigkounakis V., Merglová V.: Retrospektivní klinická studie 64 luxovaných stálých zubů u dětí. IV Jindřichohradecké pedostomatologické dny, 23 – 24.4.2004.
2. Tzigkounakis V., Merglová V.: Prevence úrazů zubů u dětí. Festival pedostomatologických kazuistik, 23.4.2005, Motol, Praha.
3. Tzigkounakis V.¹, Zikmundová K.², Merglová V.¹ (¹Stomatologická klinika LF UK v Plzni, ²Ústav sociálního lékařství LF UK v Plzni): Znalosti učitelů základních škol o problematice 1. pomoci při luxacích zubů. 45. studentská vědecká a odborná konference, 19.5.2005, Plzeň.
4. Merglová V., Tzigkounakis V.: Příčiny a prevence úrazů stálých zubů u dětí. III Plzeňské pracovní dny, 4-5.11.2005.
5. Tzigkounakis V. Merglová V.: Poúrazové resorpce kořenů – etiologie, výskyt, terapie. 46. studentská vědecká a odborná konference, 11.5.2006, Plzeň.
6. Tzigkounakis V., Merglová V.: Hydroxid vápenatý v endodoncii – pH různých materiálů in vitro. PDD 12.10.2006, Praha.
7. Merglová V., Tzigkounakis V.: Prevence úrazů zubů u dětí. Preventivní symposium, 10 – 11.11.2006, Košice, SR.
8. Tzigkounakis V., Merglová V.: Hydroxid vápenatý či MTA? Jindřichohradecké pedostomatologické dny. 30 – 31.3.2007.
9. Tzigkounakis V., Merglová V., Trefil L.: Difuze kalciových iontů z různých materiálů s hydroxidem vápenatým in vitro. 47. studentská vědecká a odborná konference, 23.5.2007, Plzeň.
10. Tzigkounakis V., Merglová V.: Ošetření nekomplikovaných fraktur klinických korunek stálých zubů – historie a současnost. PDD 10 – 12.10.2007, Praha.
11. Merglová V., Tzigkounakis V.: Dlahování traumaticky uvolněných zubů – využití adhesivní techniky. PDD 10 – 12.10.2007, Praha.
12. Tzigkounakis V., Merglová V.: Obliterace kořenového kanálku – častý poúrazový následek. Festival pedostomatologických kazuistik II, 19.4.2008, Motol FN, Praha.
13. Cibulková V., Prokupková J.(školitel Tzigkounakis V., Merglová V., Trefil L.): Vliv složení endodontických materiálů s hydroxidem vápenatým na difuzi kalciových iontů dentinem. 48. studentská vědecká a odborná konference, 14.5.2008, Plzeň.

14. Tzigkounakis V., Merglová V.: Hydroxid vápenatý v endodoncii. Hlavní referát, 7.10.2008, Stomatologická klinika v Plzni.
15. Merglová V., Tzigkounakis V.: Úrazy stálých zubů s nedokončeným vývojem – léčení, komplikace, prognóza. PDD 15 – 17.10.2008, Praha.
16. Tzigkounakis V., Merglová V.: Úrazy stálých zubů u dětí – význam endodontického léčení. PDD, 15 – 17.10.2008, Praha.
17. Tzigkounakis V., Merglová V., Houba R.: Příspěvek k problematice ošetření zlomenin klinických korunek stálých zubů. Jindřichohradecké pedostomatologické dny. 27 – 28.3.2009.
18. Tzigkounakis V., Merglová V., Houba R.: Ošetření komplikovaného úrazu u dítěte. Demontrace, 2.6.2009, Stomatologická klinika v Plzni.
19. Tzigkounakis V., Němečková A., Medlin R., Bláhová O., Merglová V.: Vliv dlouhodobého působení hydroxidu vápenatého na kořenový dentin. Plzeňské pracovní dny, 13 – 14.11.2005.
20. Tzigkounakis V., Merglová V., Houba R.: Ošetření komplikovaného úrazu u dítěte. Plzeňské pracovní dny, 13 – 14.11.2005.

Posters:

1. Tzigkounakis V., Merglová V.: A retrospective clinical study of 64 avulsed permanent teeth. EAPD (7th congress). 11-13.6.2004, Barcelona, Spain.
2. Tzigkounakis V., Merglová V.: Prevence úrazů zubů u dětí. PDD, 12 – 15. 10.2005, Prague, CZ.*
* This poster was awarded as the third best poster in the congress
3. Tzigkounakis V¹., Trefil L. ², Merglová V. ¹ (¹Stomatologická klinika LF UK v Plzni, ²Oddělení klinické biochemie FN v Plzni): The use of calcium hydroxide in endodontics – comparison of pH in different materials in vitro. ESE Dublin, 15 - 17.9.2005, Dublin, Ireland.
4. Tzigkounakis V., Merglová V.: Prevention of tooth injuries in children. EAPD, 8 - 11.6.2006, Amsterdam, Netherlands.
5. Tzigkounakis V., Merglová V.: Prevention of tooth injuries in children. 11th Annual conference of the European Association for Dental Public Health (EADPH), 7-9.9.2006, Prague, CZ.
6. Tzigkounakis V., Hecová H., Merglová V.: Následky úrazů stálých zubů - retrospektivní studie. PDD, 11 – 14.10.2006, Praha, CZ.*
* This poster was awarded as the 5th best poster in the congress
7. Tzigkounakis V., Merglová V.: Endodontic intervention in treatment of various types of dental injuries and their complications in permanent teeth of children. IFEA, 22 – 25.8.2007, Vancouver, Canada.
8. Tzigkounakis V., Merglová V.: The use of calcium hydroxide in endodontics – comparison of pH in different materials in vitro. EAPD, 29.5 – 1.6.2008, Dubrovnic, Croatia.
9. Merglová V., Tzigkounakis V.: Endodontic intervention in treatment of various types of dental injuries and their complications in permanent teeth of children. EAPD, 29.5 – 1.6.2008, Dubrovnic, Croatia.
10. Tzigkounakis V¹., Merglová V. ¹, Trefil L. ² (¹Dentistry Department¹ and Clinical Biochemistry Department² of Faculty of Medicine and Faculty Hospital in Pilsen, Charles University in Prague, Czech Republic): Calcium and hydroxyl ion diffusion through dentin - comparison study of various materials. IAPD, 17 – 20.6.2009, Munich, Germany.
11. Tzigkounakis V.¹, Merglová V.¹, Trefil L.² (Stomatologická klinika¹ a Oddělení klinické biochemie², LF a FN v Plzni): Průnik kalciových a hydroxylových iontů dentinem. PDD, 21 – 24.10.2009, Praha, CZ.*
* This poster was awarded as among the best two posters in the congress.

Publications:

1. Merglová V., Tzigkounakis V.: Retrospektivní klinická studie 64 luxovaných stálých zubů u dětí. Čes Stomat. 2004; 104: 89-98.
2. Tzigkounakis V., Merglová V.: Prevention of tooth injuries and their complication in children. Poster in 11th Annual conference of the EAPDH, Praha, 7. – 9. 9. 2006. Community dental health. ABSTRACT. 2006; 23, 3: 164-194 (ISSN 0265 – 539x) (I.F.: 1.046).
3. Tzigkounakis V., Merglová V. Attitude of Pilsen primary school teachers in dental traumas. Dent Traumatol. 2008; 24:528-531. (I.F.: 1.274).
4. Tzigkounakis V., Merglová V., Hecová H., Netolický J. Retrospective clinical study of 90 avulsed permanent teeth in 58 children. Dent Traumatol. 2008; 24: 598-602. (I.F.: 1.274).
5. Hecová H., Tzigkounakis V., Merglová V., Stehliková J.: Retrospektivní studie 447 stálých zubů s poraněním závěsného aparátu. Čes Stomat. 2008; 108: 135-141.
6. Tzigkounakis V., Merglová V.: Doporučený léčebný postup – avulze stálých zubů. Časopis České Stomatologické Komory LKS, 2009; 19: č. 9: 254-257 (ISSN 1210-3381).
7. Tzigkounakis V., Merglová V., Trefil L.: Calcium and hydroxyl ion diffusion through dentin - comparison study of various materials. Poster in 47 IAPD congress, Munich, 17. – 20. 6. 2009. International Journal for Paediatric Dentistry. ABSTRACT. 2009; 19: 66-170 (ISSN 0960743) (I.F.: 1.072).

Articles sent for publication:

1. Netolický J., Zahlavová E., Tzigkounakis V., Merglová V., Hecová H.: Internal Inflammatory Root Resorption – A retrospective clinical study of 25 teeth. Sent to Dent Traumatol in January 2010.
2. Hecová H., Tzigkounakis V., Merglová V., Netolický J.: A retrospective study of 889 injured permanent teeth. Sent to Dent Traumatol / recommended for publication by reviewers.

11. Acknowledgements

At this point, I feel deeply obliged to express many thanks to all, who have assisted and helped during my postgraduation studies, either by offering me their scientific advises, or sharing with me their clinical experiences and finally for practical and psychological support.

In the very first place, my gratitude belongs to the tutor of my post-graduation studies, Associate Professor Doctor Vlasta Merglová, CSc., for her scientific guiding, advices, experience sharing and patience.

Special thanking belongs to Professor Doctor Jan Kilian, DrSc., for his generous support, help and advises during my studies.

Furthermore, I would like to thank the Head of Dentistry department of Faculty of Medicine in Pilsen, Associate Professor Doctor Antonín Zicha, CSc. for giving me the chance to enter the PhD program and for his support during the whole period of my studies.

I do thank Associate Professor Pavel Fiala, CSc., Vice-Dean for foreign students of Faculty of Medicine in Pilsen for his kind help on realisation of experiments of this thesis and for his mental support during difficulties.

I also wish to express my appreciation to Ing. Ladislav Trefil from the Clinical Biochemistry department of Faculty Hospital in Pilsen for his valuable advises and help during realisation of the experiments and to Associate Professor Olga Blahová, CSc. and Ing. Rostislav Medlín from West Bohemian University for making possible the realisation of two experiments.

For all the assistance and valuable help during the evaluation of the findings in the electronic microscope observation of experimental samples of this thesis, I thank Assistent RNDr. Alena Němečková, CSc. from Histology and Embryology Department of Faculty of Medicine in Pilsen.

For all the clinical help, guidance and support, I do thank the staff of Paediatric Dentistry department and also all the doctors and medical staff who have been supporting me from other departments.

Finally, I wish to express my gratitude to my family and friends for their understanding, moral support and patience during all these years of my pre and post-graduation studies.

MUDr. Vasileios Tzigkounakis

12. Poděkování

Na tomto místě bych rád vyjádřil poděkování všem, kteří mi pomáhali, přispěli odbornými radami, nebo se se mnou podělili o klinické zkušenosti.

V první řadě bych rád vyjádřil svůj vděk školitelce doc. MUDr. V. Merglové, CSc. za její odborné vedení, rady, sdílení zkušeností a trpělivost.

Speciální dík patří prof. MUDr. J. Kilianovi, DrSc. za jeho velkorysou podporu a za všechny cenné rady, které mi udělil během mých studií.

V neposlední řadě bych rád poděkoval přednostovi stomatologické kliniky Lékařské fakulty v Plzni, doc. MUDr. A. Zichovi, CSc. za možnost přihlásit se do programu PhD a za jeho podporu během celého období mého PhD. studia.

Rád bych poděkoval doc. Dr. P. Fialovi, CSc., proděkanovi pro zahraniční studenty Lékařské fakulty v Plzni za laskavou pomoc při realizaci experimentů a jeho duševní podporu při potížích.

Dále děkuji ing. L. Trefilovi z oddělení klinické biochemie Fakultní nemocnice v Plzni za cenné rady a pomoc při realizaci experimentů a doc. O. Bláhové, CSc. a ing. R. Medlínovi ze Západočeské Univerzity, že mi umožnili realizovat dva experimenty mé dizertační práce.

Za cennou pomoc při hodnocení nálezů v elektronovém mikroskopu děkuji paní as. RNDr. A. Němečkové CSc. z Ústavu histologie a embryologie Lékařské fakulty v Plzni.

Za veškerou klinickou pomoc a podporu děkuji pedostomatologickému oddělení a také lékařům ostatních oddělení, kteří mě podporovali.

Konečně mi dovoluji vyjádřit můj dík mé rodině a přátelům za jejich pochopení, morální podporu a trpělivost během všech let mých řádných a postgraduálních studií.

MUDr. Vasileios Tzigkounakis