CHARLES UNIVERSITY

FACULY OF PHYSICAL EDUCATION AND SPORT

BACHELOR THESIS

June 2022

Author: Muhammad Jessa

CHARLES UNIVERSITY

FACULY OF PHYSICAL EDUCATION AND SPORT

DEPARTMENT OF PHYSIOTHERAPY

Case Study of Physiotherapy: Rehabilitation of patient after Ileostomy

BACHELOR THESIS

Supervisor: Mgr. Kristina Chroustová **Author:** Muhammad Jessa

Prague, June 2022

Declaration

I declare that this thesis is written and completed by myself, under the guidance and supervision of Mgr. Kristina Chroustová. All clinical findings, presented in this thesis, have been obtained through my clinical placement in the Institut klinické a experimentální medicíny in Prague. Clinical procedures used are based on knowledge acquired during my academic studies at the Faculty of Physical Education and Sports of Charles University in Prague.

I declare that no invasive procedures were used my myself during the clinical work placement in the Institut klinické a experimentální medicíny in Prague.

Date: _____ **Signature: _____**

Acknowledgements

I offer my deepest gratitude towards my friends and family who have given their unconditional, unequivocal, and undying support towards my studies and my passion for Physiotherapy.

I express my appreciation towards my teachers and supervisors that have aided me in successfully writing this bachelors thesis. Their guidance and advice carried me through all the stages of writing my project.

Abstract (English)

The aim of this thesis is to clearly portray the rehabilitation process of a patient after an ileostomy.

This work is divided into two parts: a theoretical aspect, and a practical aspect.

The former consists of an introduction and theoretical information regarding the ileostomy and to determine a physiotherapeutic approach to the rehabilitation of the patient post-surgery.

The latter presents the case study which includes the initial and final kinesiological examinations of the patient and day to day therapies that were undertaken as well as the results of said therapies.

A conclusion is drawn to compare the initial and final kinesiological examinations, the results, and benefits of applying varied treatments to the patient.

Abstract (Czech)

Cílem této práce je názorně popsat rehabilitační proces pacienta po ileostomii.

Tato práce je rozdělena na dvě části: teoretickou a praktickou část.

První se skládá z úvodu a teoretických informací o ileostomii a stanovení fyzioterapeutického přístupu k rehabilitaci pacienta po operaci.

Ten představuje případovou studii, která zahrnuje vstupní a závěrečné kineziologické vyšetření pacienta a každodenní terapie, které byly provedeny, a výsledky uvedených terapií.

Závěrem je porovnáno vstupní a výstupní kineziologické vyšetření, výsledky a přínosy aplikace různých léčebných postupů pro pacienta.

Table of Contents

1 Introduction

An ileostomy is a surgery that consists of opening the abdomen to reach and bring out the lumen of the ileum (small intestine). In many cases this is done due to the non-functioning colon or rectum. For this reason, waste does not exit through the proper means, via the rectum.

The goal of an ileostomy is to bring the lumen of the ileum to towards the surgical opening in the abdominal wall called a 'stoma', as suggested by the name 'ileo' = 'Ileum' and = 'stomy' = 'stoma'.

The aim of this bachelor's thesis is to present research regarding caecal carcinomas and their subsequent surgical solution, as well as post-operative care and rehabilitation. The case study included in this thesis is of a patient who underwent a hemicolectomy, lymphadenectomy, ileostomy, and a revision surgery which required an ileo-transverse anastomosis, at the Institute of Clinical and Experimental Medicine in Prague.

The case report was prepared during continuous practice between 17th January 2022 and 11th February 2022 and includes anamnesis, initial kinesiological analysis, proposal of short-term and long-term therapeutic plan, daily record of therapeutic interventions, final kinesiological analysis and evaluation of therapy effect.

2 General part

The Small Intestine

The small intestine is roughly 6 to 7 metres long, with a luminal diameter ranging from 3 to 5 cm. The small intestine is responsible for food digestion, enzyme and protein secretion, and nutrient absorption. At the superior aspect of the caecum, the ileum meets the ileocecal junction. This is where the tinea converges in the gut, where the caecum is found. (Rajaretnam & Lieske, 2022)

The small intestine is part of your digestive system, referred to as the small bowel. Food uses it as part of the journey through your body, also known as the gastrointestinal (GI) tract. From the small bowel food makes its way to the large bowel, both are responsible for the breaking down of food, in the process absorbing nutrients and solidifying the waste. The small intestine is the longest part of the gastrointestinal tract, and it is where most of your digestion takes place. (Cleveland Clinic, 2021) (Nursing Times, 2019)

Anatomy and physiology

The duodenum proximally, the jejunum, and the ileum distally are the three portions that connect. A definite separation is not existent, they do have slightly different characteristics and roles to play. (Cleveland Clinic, 2021) (Nursing Times, 2019)

Duodenum

The duodenum is the initial and the shortest part of the small intestine after the stomach, it is a descending chute only about 20cm long. Its distal end is attached to the antrum of the stomach, divided by the pylorus, while its proximal end is connected to the antrum of the stomach. It curves around the pancreas in a “C” shape before blending into the beginning of the jejunum. (Cleveland Clinic, 2021) (Nursing Times, 2019)

Jejunum

The jejunum, which is about 2.5 meters long, is tightly coiled inside the lower abdominal cavity. The villi and muscular flaps in the jejunum soak up the digestive contents. It's also distinguished by its many blood arteries, which give it a rich crimson colour. (Cleveland Clinic, 2021) (Nursing Times, 2019)

Ileum

The ileum is the final and longest portion of the small intestine ending at the cecum. Measuring around 3 meters, the walls of the small intestine begin to thin and narrow, blood supply is reduced. Food spends the greatest time in the ileum, absorbing the most water and nutrients. The most absorbable molecules include vitamin B12 and bile acids. (Rajaretnam & Lieske, 2022)

Histology

Layers of the Small Intestine: (SHACKLEFORD, 1976)

- Serosa: *"The serosa is the outside layer of the small intestine and consists of mesothelium and epithelium, which encircles the jejunum and ileum, and the anterior surface of the duodenum since the posterior side is retroperitoneal. The epithelial cells in the small intestine have a rapid renewal rate, with cells lasting for only 3 to 5 days."*
- Muscularis: *"The muscularis consists of two smooth muscle layers, a thin outer longitudinal layer that shortens and elongates the gut, and a thicker inner circular layer of smooth muscle, which causes constriction. Nerves lie between these two layers and allow these to muscle layers to work together to propagate food in a proximal to distal direction."*
- Submucosa: *"The submucosa consists of a layer of connective tissue that contains the blood vessels, nerves, and lymphatics."*
- Mucosa: *"The mucosa is the innermost layer and is designed for maximal absorption by being covered with villi protruding into the lumen that increases the surface area. The crypt layer of the small bowel that is the area of continual cell renewal and proliferation. Cells move from the crypts to the villi and change into either enterocytes, goblet cells, Paneth cells, or enteroendocrine cells."*

The mesentery, a double fold of the peritoneum, must be mentioned. Its purpose is to hold all of the blood arteries, nerves, and lymphatic vessels that supply the small intestine and anchor the small and large intestines to the abdominal wall. (SHACKLEFORD, 1976)

Embryology

The endodermal lining gives rise to the rudimentary stomach. The inner epithelial lining of the digestive system is formed by this layer, which is surrounded by splanchnic mesoderm, which makes up the muscular connective tissue and all layers of the small intestine. The midgut

contains the jejunum and ileum, whereas the foregut contains the duodenum. (Rajaretnam & Lieske, 2022)

The lining of the small intestine is made up of crypts and villi. However, until the ninth week of pregnancy, the small intestine is lined with cuboidal cells, after which villi begin to develop. Crypt development develops during the tenth and twelfth weeks of pregnancy. (SHACKLEFORD, 1976)

Nerves

The neural system of the small intestine is divided into parasympathetic and sympathetic divisions. The Vagus nerve is the source of parasympathetic fibres. Sympathetic fibres are produced by three types of ganglion cells in the splanchnic nerve. Motor signals from nerve cells drive blood vessel dilation.

Muscles

The small intestine is made up of two smooth muscle layers. The stomach's outermost layer comprises a thin, longitudinal muscle that contracts, relaxes, shortens, and lengthens, allowing food to travel in one direction. A bigger, rounder muscle makes up the deepest layer. The intestines may contract and break up larger food particles because of this layer. Restricting the more proximal end also prevents food from moving in the other way. Food is promoted from the proximal to the distal end by the two muscular layers working together (Rajaretnam & Lieske, 2022).

Clinical Significance

Malabsorption can be classified as either global or partial, with global malabsorption affecting the entire mucosa and partial malabsorption affecting specific nutrients. Although the clinical characteristics of malabsorption vary depending on the kind of nutrient deficiency, weight loss is a usual sign of global malabsorption. Large, light, and oily stools will also develop. Abdominal discomfort, flatulence, anorexia, and distension are common gastrointestinal symptoms in most individuals. Patients who are suffering from malabsorption may be asymptomatic. (Nikaki & Gupte, 2016)

Specific signs such as bone thinning or iron deficiency anaemia may only be presented in situations with isolated malabsorption, such as celiac disease. Carbohydrate malabsorption causes milk intolerance and watery diarrhoea; protein deficiency causes muscle atrophy and monthly abnormalities; folic acid and iron deficiency create anaemia; vitamin A lack causes

night blindness, and vitamin K deficiency causes bleeding problems. It's also worth mentioning that some forms of malabsorption, such as celiac disease or pancreatic insufficiency, can result in nutritional loss, including vitamin D, which is dependent on chylomicrons for absorption. (Dahly et al., 2003) (Rajaretnam & Lieske, 2022)

Results of malabsorption may wreak havoc on patients' life, limiting their capacity to carry out everyday tasks. As more young patients with disorders like short bowel syndrome, cystic fibrosis, and inflammatory bowel disease enter adulthood, this is an essential area to continue exploring.

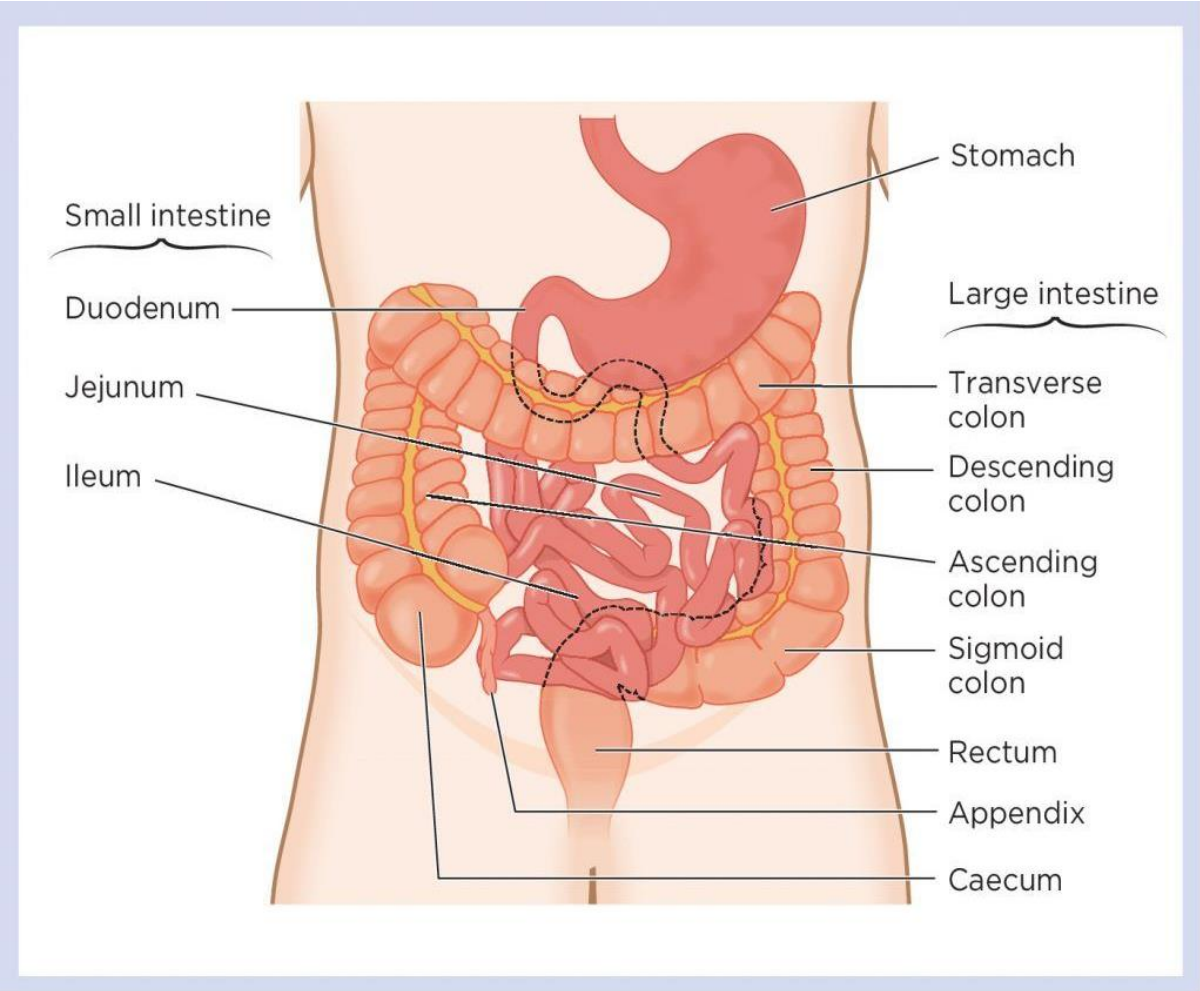

Figure 1: Anatomy of the small and large intestine. (SHACKLEFORD, 1976)

The large intestine

The large intestine, sometimes known as the big bowel, is the last section of the digestive tract. It spans the stomach and pelvic chambers and is roughly 1.5 meters long. (Hub, 2022)

Faeces are generated in the large intestine by the water uptake from the moving intestinal contents. The large intestine harbours a broad microflora that is vital for human existence, in

addition to its involvement in the creation, storage, and subsequent defecation of faeces. To put things in perspective, the gut microbiota weighs 1-2 kg. (Netter, 2019)

The Colon

The colon is made up of various sections:

Undigested food begins its journey through the colon in the **ascending colon**. Undigested food flows upward through this section, where fluid may be reabsorbed more efficiently. (*Colorectal (Colon) Cancer*, 2020)

The transverse colon transports food from one side of the body to the other as it moves across the body (right to left) (*Colorectal (Colon) Cancer*, 2020).

After traveling across the top through the transverse colon, food travels downhill via **the descending colon**, which is normally on the left side. (*Colorectal (Colon) Cancer*, 2020)

The sigmoid colon is the last halt before the rectum. It is formed like a "S" and is the last segment of the colon that runs from the left iliac fossa to the third sacral vertebra (rectosigmoid junction). The colon is intraperitoneal in this area. The sigmoid mesocolon connects it to the pelvic wall. (Hub, 2022)

Cecum

The cecum is the first section of the large intestine, found in the right iliac fossa of the abdomen. The cecum is ringed by folds and pockets and is located inside the peritoneal cavity (retrocecal peritoneal recesses).

The ileocolic junction is where the terminal ileum meets the cecum. The ileal papilla, which is made up of two folds known as ileocecal lips, marks the ileocecal opening (superior, inferior). When the folds around the orifice fuse together, the ileal orifice frenula forms, preventing caecal contents from refluxing into the ileum. The flow of intestinal contents from the small to the large intestine is controlled by an ileocecal valve. The cecum is responsible for temporary chyme storage, as well as fluid and electrolyte reabsorption. (Hub, 2022)

Cecum cancer

To maintain the body healthy and working correctly, all of the body's cells routinely develop, divide, and die. This process can sometimes spiral out of hand. Even though cells are intended to die, they keep growing and dividing. Colorectal cancer can develop when the cells that line the colon and rectum multiply excessively. (*Colorectal (Colon) Cancer*, 2020).

Colorectal cancer is categorized into three types based on anatomical location: colon carcinomas, tumours of the rectosigmoid junction, and cancers of the rectum itself. Anatomically, clinically, and physiologically, colon cancer differs from rectal cancer.

The rectal area has the most tumours, followed by the sigmoid area, the ascending colon has fewer, and the descending and transverse colon has the fewest.

Most colorectal malignancies begin as tiny precancerous polyps (adenomatous or serrated). These polyps usually grow slowly and do not cause symptoms until they have grown to a significant size or become cancerous. This allows for the detection and removal of pre-cancerous polyps before they turn into dangerous tumours.

Colorectal cancer is classified into stages based on when it is discovered. Colorectal cancer stages are determined by the extent of invasion through the gut wall, the presence of lymph nodes (drainage nodules), and the spread to other organs (metastases). In the majority of cases, the damaged intestine must be surgically removed (resection). Certain tumours are treated with chemotherapy or, in the case of rectal cancers, radiation. (*Colorectal (Colon) Cancer*, 2020).

Etiology

Colorectal cancer is caused by abnormalities in the DNA of cells in the colon or rectum, which leave them unable to control their growth and division. These mutant cells are frequently killed or targeted by the immune system. However, certain altered cells may evade the immune system and develop out of control in the colon or rectum, causing a tumour. Although the specific Etiology of colorectal cancer is unknown, some risk factors, such as nutrition, cigarette use, and high alcohol use, are significantly connected to the illness. People with specific genetic cancer syndromes, as well as those with a family history of colorectal cancer, are at an increased risk of acquiring the illness. (Maurie Markman, 2019)

Some aspects of colorectal cancer risk can't be regulated, and this is true for some but not all of them.

These traits may make you more likely to have colorectal cancer:

Age: Cases are on the rise among those under the age of 64, and more so in those under 50. Colorectal cancer affects around 90% of the population of 50 years and older, concurring with the Centres for Disease Control and Prevention. (Maurie Markman, 2019)

Race and ethnicity: Non-Hispanic African Americans have the greatest rate of colon cancer diagnosis and mortality. These percentages are also greater among American Indians, Alaska Natives, and Eastern and Central European Jews (Ashkenazi).

Polyps or cancer history: People who have had colorectal polyps in the past are more likely to develop cancer, especially if they were large, many, or had abnormal-but-noncancerous cells (dysplasia). Patients who have already been diagnosed with colorectal cancer are also at a higher risk.

Inflammatory bowel illness (IBD), such as ulcerative colitis or Crohn's disease, and type 2 diabetes, for example, can increase the risk of colorectal cancer. Irritable bowel syndrome (IBS) does not affect or increase cancer development.

Health history in the family: If colorectal cancer or polyps appear in family members the likelihood of colorectal cancer is increased.

According to the American Cancer Society (ACS) (Maurie Markman, 2019), lifestyle factors are responsible for 55 percent of colorectal cancer cases in the United States. These are some of them:

Diet: Those who consume a high-fat diet, as well as a lot of processed meat or red meat, are at a higher risk. A diet high in fruits, vegetables, and fibre is recommended.

Drinking: Alcohol intake ranging from light to heavy, as well as light to moderate drinking, may increase the risk of developing cancer. Men should restrict themselves to two drinks per day, while women should limit themselves to one drink per day.

Weight: Overweight or obese adults, particularly males, have an increased risk of colorectal cancer.

Physical exercise has been associated with colon cancer but not rectal cancer. Colorectal cancer may be more prevalent in those who spend most of their time sitting or lying down. According to an ACS research paper, the International Agency for Research on Cancer has established that smoking tobacco promotes colorectal cancer. In the United States, around 12% of colorectal cancer cases are caused by current or former smoking. (Maurie Markman, 2019)

Epidemiology

Colorectal cancer incidence and mortality rates vary substantially from nation to country. Colorectal cancer is the third most often diagnosed cancer in males and the second most commonly diagnosed cancer in women, according to the GLOBOCAN database of the World Health Organization. Males have much higher rates of occurrence and mortality than females. (Thanikachalam & Khan, 2019)

"In the Czech Republic, almost 8,500 patients with colorectal cancer are newly diagnosed every year, and approximately 3,900 people succumb to this disease every year. The total prevalence in 2012 will exceed 55,000 people. The social, ethical, and economic consequences of such a high burden are clear." (Dušek et al., 2012)

"Both the incidence and mortality of cancer have been continuously falling in the United States. Approximately 151,030 new instances of large bowel cancer are identified each year, with 106,180 cases being colon cancer and the rest being rectal cancer. CRC kills around 52,580 people in the United States per year, accounting for about 8% of all cancer fatalities." (Islami et al., 2021) (Siegel et al., 2022)

Incidence — The global incidence of Colorectal cancer varies by a factor of ten. Most of Europe and North America have more significant prevalence rates, whereas Africa and Asia are in the category of low rates. The differences in rates are likely due to difference in food and environmental disclosures, poor social and economic level, and low rates of cancer screening, all of which are imposed on a genetically established susceptibility background. (Fitzmaurice, 2018)

The lifetime incidence of Colorectal cancer in persons at average risk in the United States is around 4%. Males have a 25 percent greater incidence than females, and African Americans have a 20 percent higher incidence than White Americans. Patients with particular hereditary disorders have a greater incidence that makes individuals more likely to develop Colorectal cancer. (Siegel et al., 2022) (Jemal et al., 2010)

Both in the United States and worldwide, a steady shift toward right-sided or proximal colon malignancies has been seen, with the highest proportional rise in incidence in caecal primaries. Improvements in diagnosis and treatment, as well as enhanced screening with the removal of adenomatous polyps in the distal colon, may have contributed to this shift in the anatomic distribution of Colorectal cancer. (Troisi et al., 1999)

In the United States, Colorectal cancer incidence rates had been dropping at a pace of about 2% per year, but this rate of decrease dropped to around 1% per year between 2013 and 2017. During this time, most other Western countries' rates of cancer have remained steady or climbed modestly. CRC incidence rates, on the other hand, have rapidly climbed in numerous formerly low-risk locations, such as Spain and a number of countries in Eastern Asia and Eastern Europe. (Islami et al., 2021)

Pathophysiology

Colorectal tumours are caused in large part by genomic and epigenomic instability. These are manifested in multiple ways. (Mckenzie, 2018)

- Chromosomal instability (CIN)
- Microsatellite instability (MSI)
- Non-MSI hypermutability
- Global DNA hypomethylation

Chromosomal instability (CIN)

"This type of instability can be found in up to 85% of colorectal tumours. The presence of aneuploid or polyploid DNA causes chromosomal instability. Flow cytometry and whole exome sequencing are two approaches that may be used to examine these structural alterations in chromosomes. Unfortunately, there are no defined criteria for assessing whether a colorectal cancer diagnosis also includes CIN, making comparisons between studies problematic." (Grady & Markowitz, 2014) (Kuipers & Spaander, 2015)

Microsatellites Instability (MSI)

"Microsatellite-instable colorectal tumours account for around 15% of all colorectal malignancies. The mutations found in this form of colorectal cancer are not the same as those seen in CIN tumours. The presence of at least 30% unstable microsatellite loci is a hallmark of MSI colorectal tumours. MSI has well-understood processes, which mainly entail the inactivation of DNA mismatch repair genes." (Grady & Markowitz, 2014) (Kuipers & Spaander, 2015)

CpG Islands and Global Hypomethylation

"Colorectal cancer is caused by hypermethylation of gene loci including CpG islands, as well as global DNA hypomethylation. When compared to other types of colorectal cancer, a subset of colorectal malignancies has a higher proportion of methylated CpG sites. A CpG island

methylator phenotype describes these individuals (CIMP). The overexpression of DNA methyltransferases (such as DNMT3B or DNMT1) has been linked to CIMP."

Many colorectal tumours have been shown to have a worldwide reduction in methylation. The mechanics behind this remain a mystery. It may have a function in the induction of oncogene expression in some studies, and it may also play a role in the formation of CIN in others. More research on the impact of worldwide DNA hypomethylation on colorectal cancer is needed before any clear conclusions can be drawn. (Mckenzie, 2018)

Adenocarcinoma

Adenocarcinoma is a kind of cancer that starts in the glandular cells that produce mucus in your body. Adenocarcinoma can develop in any of these glands, which can be found in a range of organs. The most frequent types of cancer include breast cancer, colorectal cancer, lung cancer, pancreatic cancer, and prostate cancer. (Chun, 2019)

The most prevalent oncological diagnosis are tumours of the colon and rectum.

If the cancer hasn't grown large enough to create issues, or if it was discovered in its early stages via a screening test, there may be no symptoms.

Colorectal malignancies frequently cause bleeding, which results in blood in the stool, however the amount may be too tiny to observe. It's possible that eventually enough will be apparent. The hue of visible blood can range from vibrant red to maroon. (Chun, 2019)

Other signs and symptoms of colorectal cancer include:

- Abdominal cramps or pain
- Diarrhoea, constipation, or other bowel irregularities
- Gas, bloating, or a constant sense of being full faeces that narrows or thins
- Unexplained slimming down

Clinical examination

Because no clinical indications may show in the early stages, routine screening in the at-risk population is recommended. If symptoms appear, they are classified as local or global. Changes in stool consistency and regularity, the presence of blood or mucus in the stool, constipation, diarrhoea, and alternating constipation and diarrhoea are all local symptoms. Abdominal and rectal discomfort can develop in various instances, and it can be either intermittent or persistent. In a rare case, the patient might feel the development in his lower abdomen. Loss of appetite, nausea, weakness, exhaustion, weight loss, jaundice, and an increase in stomach volume and warmth are all common symptoms. Overall symptoms, on the other hand, are more common in late stages of cancer. (Jiří Vorlíček et al., 2006)

These particular tests based on the late-stage cancer's location. These may include the following: (Bernstein, 2021)

Blood tests. Your blood may include cancer-related markers. Your doctor could examine it to discover whether you have anaemia from a bleeding tumour, for example. Furthermore, high levels of several enzymes or other substances produced by cancer cells may indicate the likelihood of malignancy.

Imaging tests. They can help determine whether any of the tissues in your organs are abnormal. A CT scan, which is a strong X-ray that creates precise images within your body, may be performed on you. An MRI, which employs strong magnets and radio waves to create images of organs and tissues, may be required. Imaging tests can also help determine how well your treatment is working if you do have cancer and begin treatment.

Biopsy. A sample of tissue from the organ is obtained if cancer is suspected. Removal of a polyp or growth from your colon or remove tissue from your breast using a little needle. A pathologist will examine it under a microscope to discover whether cancer cells are present. A biopsy can also reveal if the tumours are limited to that organ or have migrated to other parts of your body, as well as how much they've grown. (Bernstein, 2021)

Prognosis

If colorectal cancer is identified early, it can be effectively treated since it develops locally for a long time and only spreads in advanced stages. Advanced malignancies are difficult to treat, but for many patients, it results in a better quality of life with fewer clinical symptoms and longer survival. (Horvat et al., 2019)

Pharmacology

Medications for prevention: Regular use of aspirin or other nonsteroidal anti-inflammatory medicines (NSAIDs) has been demonstrated to reduce the incidence of colorectal cancer, especially in those under the age of 70 who are in good health. Patients should seek medical advice before using these drugs. (*Colorectal (Colon) Cancer*, 2020)

For many years, 5-fluorouracil, or 5-FU (Adrucil®), has been the first-line chemotherapy medication for advanced colorectal tumours, combined with the vitamin leucovorin. 5-FU is often administered intravenously, although capecitabine (Xeloda®) is also available.

Irinotecan (Camptosar®) and oxaliplatin (Eloxatin®), two other intravenous (straight into the vein) chemotherapy medicines, are also used to treat advanced colorectal tumours. For advanced colorectal tumours, oxaliplatin is administered in conjunction with 5-FU and leucovorin, whereas irinotecan is given alone or in combination with 5-FU/leucovorin for patients with metastatic colorectal cancer (cancer that has spread).

Monoclonal antibodies and immunotherapy are two newer therapies for metastatic colorectal cancer. Monoclonal antibodies are lab made and intended to identify and eliminate cells, for instance colorectal cancer cells. Because of their accuracy, treating a tumour with a monoclonal antibody is supposedly more targeted than chemotherapy medications, with fewer adverse effects. (*Colorectal (Colon) Cancer*, 2020)

Some monoclonal antibody drugs, such as vascular endothelial growth factor (VEGF), a chemical secreted by tumours to encourage the formation of new blood vessels, stop cancers from forming the blood vessels they need to survive. Interfering with a tumour's blood supply may limit its development. Others target the epidermal growth factor receptor (EGFR), a protein located on the surface of 60 to 80 percent of colon cancer cells, to limit cancer progression. For metastatic colorectal cancer that has not responded to prior therapies, they are frequently used in combination with or after other chemotherapeutic drugs. (*Colorectal (Colon) Cancer*, 2020)

Treatment

Specific treatment is based on the type of tumour, its size, characteristics, and whether there are metastases or lymph node involvement. Cancer localized to one body region is often treated with surgery and radiation. When cancer has metastasized, chemotherapy is more likely to be included in the treatment. (Chun, 2019)

There are three leading treatments for adenocarcinomas:

Surgery: Which eradicates the tumour and adjacent tissue.

Chemotherapy: Uses intravenous treatments that obliterate cancer cells across the body.

Radiation therapy: That annihilates cancer cells in a specific location.

The most common treatment option is surgical excision of the tumour-affected portion of the intestine. It is feasible to join both ends of the resected large intestine depending on the degree of the resection; in the worst-case scenario, a colostomy is required. The intestine is forced out through the front abdominal wall, resulting in a colostomy. (Horvat et al., 2019)

Chemotherapy is a word that describes the use of drugs to kill cancer cells. Chemotherapy drugs are taken either intravenously (via a vein), by an injection, or orally (through the mouth) via a tablet. It is used to treat a specific type of cancer and is administered at certain times and in exact doses. Advanced colorectal cancers that have affected the lymph nodes and other parts of the body may be treated with chemotherapy. (*Colorectal (Colon) Cancer*, 2020)

Chemotherapy has a wide range of applications, including:

When colon cancer has progressed to other organs, such as the liver or lungs, primary chemotherapy is used. Because surgery cannot generally eliminate cancer, chemotherapy can reduce tumour nodules, improve symptoms, and extend life in this scenario. (Horvat et al., 2019)

Neo-adjuvant chemotherapy is administered prior to surgery for some rectal cancers in order to shrink the tumour and make it easier for the surgeon to remove it. The patient is commonly given radiation in combination to chemotherapy in this scenario.

Adjuvant chemotherapy is administered after the colorectal cancer has been surgically removed if it is a good candidate. Because some cancer cells were not completely eliminated after surgery, they may survive in lymph nodes or other organs. Any cancer cells that persist after surgery are treated with adjuvant chemotherapy. (*Colorectal (Colon) Cancer*, 2020)

In the treatment of rectal cancer, radiotherapy is extremely significant. The goal of this form of treatment is to shrink the tumour, limit the vitality of tumour cells, and so enhance the surgical resection circumstances before the surgery. Preoperative or postoperative radiotherapy seeks to lower the risk of local recurrence, particularly in the small pelvis. It is highly beneficial in late tumours that are no longer operable. (Horvat et al., 2019)

Ileostomy

The ileum (small bowel) lumen is delivered through the abdominal wall via a surgical hole in an ileostomy (created by an operation). This can be a beginning, a middle, an end, and a loop. An ileostomy is a surgical procedure that allows faeces to be removed from the abdomen via the ileum compared to the anus where is would usually exit from. The faeces produced by an ileostomy are loose, similar to what would pass through the small bowel. An ileostomy's production varies, but it usually runs from 200 to 700 ml per day, and it's usually established on the right side of the abdomen. (Rajaretnam & Lieske, 2022)

Indications

There are several reasons for immersing in an ileostomy, but they all lead to the same result: directing faeces away from the body and colon.

A loop ileostomy is when the distal part of the ileum is pushed out to the skin with two lumens draining into the stoma bag and is typically used as a temporary stool diversion. This would protect certain leaks from the anastomosis from faeces passing through the connection between the ends of the bowel. Both of the loop ileostomy arms can be re-joined once the anastomosis is restored, restoring continuity to the gastrointestinal system, and allowing faeces to flow across the colon. The proximal limb of a loop ileostomy is responsible for passing stool, while the distal limb serves as a mucous fistula, emptying secretions generated inside the lumens mucosal lining to the caecum. If the ileocecal valve functions, there will be no draining of colonic secretions from the distal limb does and hence the colon will not be decompressed. If there is a colonic blockage, this is vital to notice since the patient is at danger of perforation from a major bowel obstruction. This is because obstructing source is not allowing the colon to decompress, therefore, secretions and flatus pile up under strain in an effectively closed bowel loop. This temporary ileostomy can be "reversed" or re-joined at a later period, generally between three and six months, to re-establish bowel continuity. (Rajaretnam & Lieske, 2022)

If there is no distal part to the proximal emptying limb, or when there is no intestine to be attached to this "end", it is called an end ileostomy. The construction of an end ileostomy is

often considered after the everlasting exclusion of the whole colon, which means the patient is responsible for managing their stoma for the rest of their lives. (Chudner et al., 2019)

The following are some of the reasons for establishing an ileostomy:

- To safeguard a distal anastomosis, the rest of the intestine is deactivated.
- If the whole colon has been removed to eliminate faeces from the body, as in colorectal cancer, Crohn's disease, ulcerative colitis, and familial adenomatous polyposis.
- Get rid of bowel obstructions.

Contraindications

Ileostomy formation has no absolute contraindications, although there are some relative ones: (Pisarska et al., 2018)

- The ileum cannot be externalised through the abdominal wall to the skin without stress due to a short mesentery. Unfortunately, fat people are more likely to experience this.
- Carcinomatosis is a condition that inhibits the ileum from fully mobilising.
- The ileostomy should be created as far away as feasible to provide ample gut length for nutrition absorption.
- An ileostomy with a high output might cause electrolyte imbalances (essential for monitoring and treating individuals with renal impairment) and malabsorption and malnutrition.
- To keep the effluent away from the epidermis, it is critical to spout the stump during ileostomy creation.
- To facilitate insertion of the stoma appliance and reduce leakage, an ileostomy should be placed away from scars, skin wrinkles, and bony prominences.

Procedure

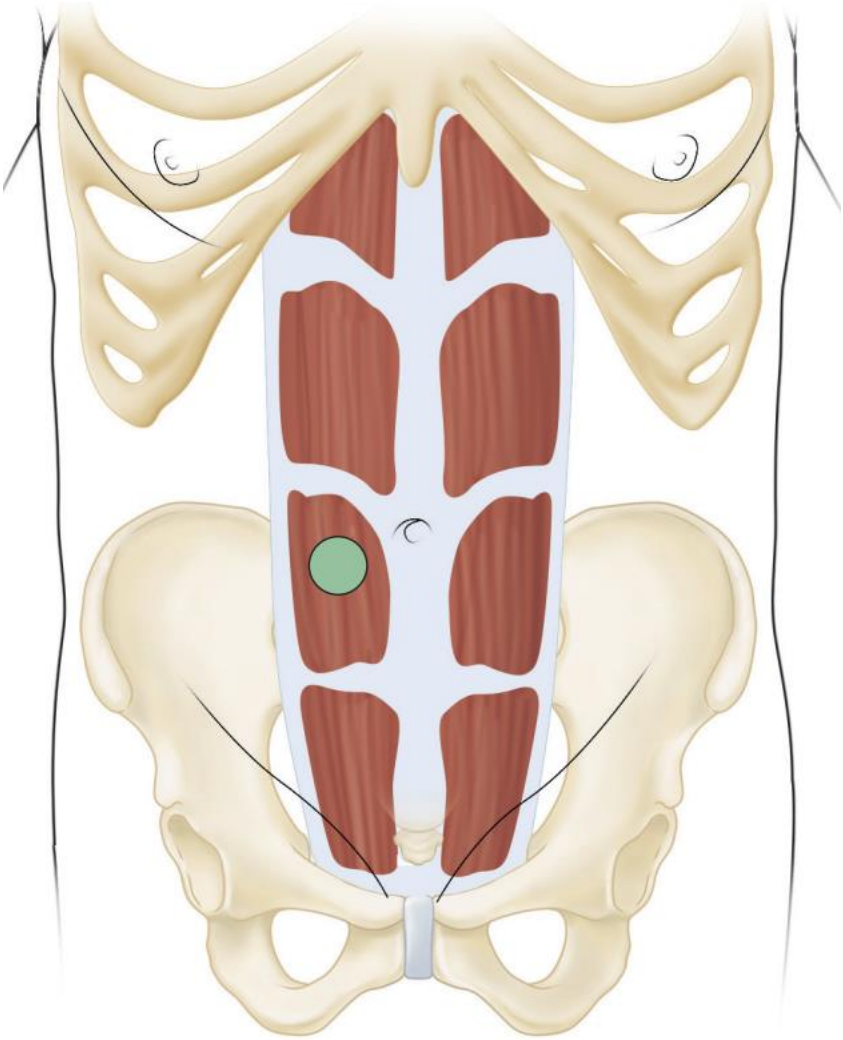

Figure 2: Siting of the ileostomy. (Yeo, 2019) (Reddy & Longo, 2019)

An ileostomy can be a very successful faecal diversion procedure that is also compatible with a high quality of life. The location of the ileostomy, on the other hand, is critical.

The ileostomy should be put in a visible and manageable area for the patient, with minimum mobility restriction and difficulties concealing it with clothes. (Yeo, 2019) (Reddy & Longo, 2019)

The patient's employment, dress preference, waistline, flexibility, body posture, physical impairments, and site of existing scars on the abdomen are all elements to contemplate when identifying the perfect area for the stoma.

The right bottom section is the best site for most ileostomies away from and scars or creases in skin. (Brand & Dujovny, 2002)

Any place that will disrupt the skin-appliance seal should be avoided at all costs. The patient should mark the ostomy site when standing, bending, sitting, and supine.

"A 1.5- to 2-cm circular incision is made in the skin and continued through the subcutaneous tissues, down to the anterior rectus fascia, depending on the size of the intestine to be utilised for the stoma. Kocher clamps are used on the border of the fascia during open surgery to align the layers of the abdominal wall during stoma formation." (Chudner et al., 2019)

The visible rectus muscle is then divided along their lengths to expose the posterior rectus sheath by a vertical incision. It is important to prevent injuring the epigastric vessels, which can be ligated if they are wounded accidentally. A transverse incision is made on the front of the rectus sheath to establish an exposed entrance. While avoiding any harm to the underlying intestine, the subsequent rectus sheath and the core peritoneum are split. Two fingers should be able to pass through the hole that has been formed. This, however, may vary depending on the patient's habits and gut wall oedema. A bigger opening may cause a parastomal hernia with oedematous bowel or hemodynamic instability, but it may be desirable. Ischemia and blockage of the ileostomy might occur if the hole is too small, this could cause obstruction and should be adjusted for size. The mobilised small bowel must be externalised and evaluated for practicality and rigidity at this stage. (Reddy & Longo, 2019)

It is important to prevent twisting the mesentery. If the mesentery can rotate around the luminal axis, if this occurs due to the mesentery being limp, absorbable sutures should be used to secure it to the front abdominal wall. (Yeo, 2019) (Reddy & Longo, 2019)

To determine the viability of the exteriorised intestine *"Visualise the pink serosa, palpate the pulsatile flow in the immediate area, evaluate the viable mucosa of the stoma, or cut the ileostomy border to confirm bleeding."* (Reddy & Longo, 2019)

"After ensuring sufficient length to prevent forming a flat stoma, the abdominal wall can be closed, and the stoma developed, depending on the kind of ileostomy. To prevent ectopic mucosal implants at the suture sites on the dermis, bites should be placed in the subcuticular area rather than the epidermis. Ectopic mucosal implants at the suture sites on the dermis can lead to mucous production and a rupture in the appliance-skin seal." (Reddy & Longo, 2019)

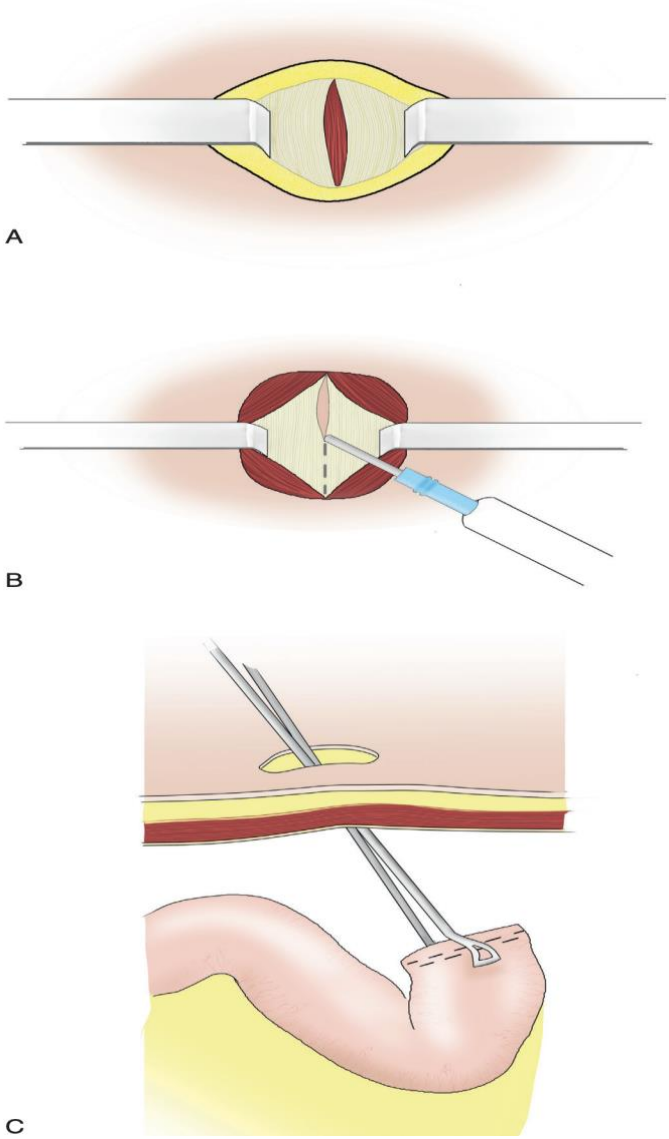

Figure 3: "Construction of ileostomy. (A) Incising the fascia. (B) Splitting the rectus and dividing the posterior sheath and peritoneum. (C) Exteriorising the small bowel." (Yeo, 2019) (Reddy & Longo, 2019)

End ileostomy

The mesentery of the small bowel is quite mobile, this is why it is easy to perform an end ileostomy (Figure 3). The affixed end of the small bowel, which has been mobilized and well-vascularized, taken through and out of the abdominal wall without bending the mesentery. To promote eversion, thick or bulky mesentery may need to be debulked.

Sutures can be put in the end of the stoma, approximately four thick sutures, and into the subcuticular region of the skin opening depending on the peristomal fat (tripartite bites). Sutures can be linked to the ileostomy once they've been inserted. (Yeo, 2019) (Reddy & Longo, 2019)

To complete the mucocutaneous connection, many additional absorbable sutures can be inserted between the full-thickness margin of the ileostomy and the subcuticular layer. Some surgeons prefer not to use sutures in the seromuscular layer because it makes it easier to evert the stoma. To extend the gap of waste away from the skin and reduce, the end ileostomy should obtrude two to three cm above the surface of the skin. (Hendren et al., 2015)

Since the majority of end ileostomies are everlasting, it is important to elude stomas that are at the same level of the skin or slightly above it. As this may result in faeces in leaking or getting stuck, resulting in severe skin abrasion, as well as discomfort and inconveniency pouching the stoma. (Cottam et al., 2007)

Diverting loop ileostomy

Following a low anterior resection with a low colorectal or coloanal anastomosis, a diverting loop ileostomy is commonly utilized for faecal diversion. Though it has an increased risk of dehydration and blockage than a loop colostomy, it has a lower risk of prolapse or wound infection at the moment of takedown. A diverting loop ileostomy is also easier to remove from a technical standpoint.

"The diverting loop stoma is made by mobilizing a loop of ileum, making a slightly larger opening in the abdominal wall than would be expected for an end ileostomy, and then exteriorizing the mobilized loop with knowledge of the direction of luminal flow (this can be marked with sutures or ink on the antimesenteric border)." (Rondelli et al., 2009)

A mesenteric defect is created, after which a stoma rod is inserted. This defect can also be formed before, or umbilical tape can be used to help the loop externalize and mature into a stoma. Before continuing with the ileostomy maturation, the remaining fascial holes and skin are closed. Cautery is a technique for dividing the ileum's antimesenteric wall at the efferent limb at the stoma bridge. From one mesenteric edge to the other, an aperture is formed. (Tang et al., 2003)

To finish the mucocutaneous connection, the same thick sutures as end ileostomy can be put in between the tripartite everting sutures. At the time of ileostomy takedown, covering the ileostomy with a sheet of sodium hyaluronate can help to reduce adhesions.

To insert a stoma rod, a mesenteric defect is formed. This may also be formed before mobility, and a Penrose drain, or umbilical tape can be used to help the loop externalise and mature into a stoma. Before continuing with the ileostomy maturation, all sites of surgery are closed and reattached. Cautery is a technique for dividing the ileum's antimesenteric wall at the efferent

limb at the stoma bridge. From one mesenteric edge to the other, an aperture is formed. (Tang et al., 2003)

The defunct limb is developed first, with sutures running from the ileostomy's border to under 30% of the boundary of the abdominal opening level. The proximal limb matures through creating an everted bud by through the border of the stoma and linking it to the skin. An intricate and carefully performed loop ileostomy may entirely redirect the faecal torrent while permitting reflux of the downriver secretions through the defunctionalized limb. The functional limb must inhabit the bulk (75 per cent) of this circumference. (Salum et al., 2006)

End loop ileostomy

Obese patients are candidates for an end-loop ileostomy that has a thin abdominal wall or a short mesentery, or a loop ileostomy that is converted to an end ileostomy. The bowel is mobilised to the fullest degree possible. While the deployed loop's vascularity is preserved, the bowel section on the deployed loop achieves maximum height over the skin. The bowel and mesentery are both kept in a comparable position. The functional limb occupies most of the abdominal wall perimeter, comparable to the loop ileostomy. The helpful use of a support rod can be put under the colon to relieve the stress at the mucocutaneous junction that an end ileostomy would otherwise cause. (Rondelli et al., 2009)

Laparoscopy

Khoo et al. were the first to describe laparoscopic loop ileostomy in 1993. The procedure is identical to that of open surgery. After achieving pneumoperitoneum and performing any necessary resections, an abdominal wall entrance is established in a predetermined location. Usually, a port can be attached at a predetermined location and then expanded. A wound retractor is implanted, and the designated loop of the bowel is guided towards the hole using a laparoscopic locking atraumatic bowel grasper. A Babcock clamp is used to externalise the targeted bowel while keeping the mesentery in place and preventing twisting. Single-port surgery is also an option, as it eliminates the need for additional incisions. (Prieto et al., 1989) (Atallah et al., 2011) (Shah et al., 2014)

Laparotomy

In some circumstances, combining a laparoscopic method with a traditional laparotomy is useful, particularly when re-sectioning organs or their components or constructing anastomoses. The hemodynamic stability of the operated patient is a need for the laparoscopic method. (Akhan & Baysal, 2002)

Traditional laparotomy procedures normally begin with an incision in the direction of the skin splitting while respecting the course of the skin lines to reduce the amount of stress in the wound region. The scar's ultimate form should have a pleasing aesthetic impact due to the following considerations. The incision position is critical for optimal access to the operated organ or structure. In general, surgeons strive to produce transverse, oblique, or obtuse angles incisions.

Pathology

Anastomotic leak is an uncommon but significant anastomotic problem after an ileostomy or colostomy. An anastomotic leak happens when the freshly formed connection fails to mend and begins to leak, as the term implies. (Cafasso, 2018)

According to a 2009 assessment, it is expected to occur in 3 to 6% of colorectal anastomoses. Whereas, only 1.1 percent of 379 patients who had ileocolic anastomosis suffered leakage as a consequence of the operation, according to a 2014 study. (Liu et al., 2014)

The following are symptoms of an anastomotic leak:

- Fever
- Abdominal soreness
- Low urine production
- Diarrhoea
- Higher than normal white blood cell count
- Peritonitis
- Ileus, or a lower amount of movement in the intestine

Obese or steroid-using adults are at a higher risk of leaking. Anastomotic leaking can also be exacerbated by smoking and binge drinking.

Treating the leak

If the leak is minor, antibiotics or a drain put through the abdominal wall may be used to treat it until the intestines recover. A second surgery will be required if the leak is greater.

In certain situations, a colostomy and abdominal washout will be necessary. During a washout, a saltwater solution is used to cleanse the peritoneal cavity, which includes the intestines, stomach, and liver. (Murrell & Stamos, 2006)

Your body may need to be drained of contaminated fluid and/or oedema caused by inflammation. If feasible, your healthcare professional will do this procedure percutaneously, which means that a hollow needle will be introduced into your skin. (*Anastomotic Leak: Symptoms, Treatment & What It Is*, 2022)

If the leak is in your intestines, you'll need to refrain from eating and drinking throughout treatment. Intravenous fluids and, if necessary, intravenous feeding will be administered. (*Anastomotic Leak: Symptoms, Treatment & What It Is*, 2022)

In a subsequent operation, your surgeon may need to review the anastomosis. A less invasive procedure such as a laparoscopy may be used, which involves inserting a tiny camera into the belly through a small incision. The surgeon can also use small instruments to drain an abscess or clean out your cavity with antiseptic through the incision. If this doesn't work, reopening of the body cavity to access the leak will be necessary. The anastomosis may need to be strengthened or recreated in a healthier part of your body. Your body may require more healing time before the anastomosis can be rebuilt.

To allow your anastomosis more time to heal, rerouting part of your intestines to a temporary ostomy, a new opening that bypasses the anastomosis will be needed. (*Anastomotic Leak: Symptoms, Treatment & What It Is*, 2022)

According to a 2006 study review, it is stated that an anastomotic leak has a mortality risk of up to 39%. The earlier it is detected, the better the prognosis. (Murrell & Stamos, 2006)

Stoma problems

An ileostomy may cause problems related to the stoma, such as: (S, 2017)

- Inflamed skin or irritation around the stoma
- stoma stricture, which is narrowing of the stoma
- The bowel pushing through the stoma (stoma prolapse)
- An organ or internal part of the body pushing through the tissue wall or weakness in the muscle (parastomal hernia)
- Retraction of the stoma, the stoma retracting below the level of the skin after the swelling has receded.
- Prolapse in the way of the bowel pushing itself out of the abdomen.

Physiotherapy for Ileostomy

An ileostomy that has just been placed is generally oedematous at first, but it will diminish within four to six weeks. The stoma output is initially both blood cells and serum, without much particle debris. Royal greenish bilious output is observed when the stoma begins to operate, and particle debris emerges in the effluent as the diet progresses. The exodus of the postoperative ileus's retained bowel contents can result in a large initial output that gradually decreases. Dehydration is a worry in the early period after operation, and studies have found that patients have been submitted again ranging from 17 to 20%, with certain literature collecting data suggesting 8.9% of individuals suffering from kidney failure after undergoing ileostomies. (Yeo, 2019) (Reddy & Longo, 2019)

Readmissions for dehydration have been proven to be reduced by teaching the patient and families, caring through nurses, and prompt post-operative appointments. Education for patients and caregivers on maintaining the stoma and fixing the appliance should begin soon after surgery. On the other hand, most ostomates will take out utilities when being released, necessitating teaching, and troubleshooting with the help of a call on nurse. Learning about how to look after yourself after an ileostomy is essential for caring for the stoma, troubleshooting stoma and appliance issues, and improving stoma value of life. (Yeo, 2019) (Reddy & Longo, 2019)

Patients' quality of life will be improved in the long run by regular consultations with an enterostomal therapist and participation in assemblies with people in the same situation. (Paquette et al., 2013) (Justiniano et al., 2018) (Hendren et al., 2015)

Pre-operative physiotherapeutic care

The majority of stoma problems are caused by improper placement. This can be avoided by including the surgeon, enterostomal therapist, and the patient in preoperative preparation. Proper stoma location and formation improve the capacity to care for the stoma and preserve a protected pouch with minimal likelihood of leaking for 7 days. Stomas that are incorrectly positioned cause stool leaks, peristomal skin irritation, mental strain, and higher costs. These issues can be treated with early closure for transient stomas. On the other hand, permanent stomas may need to be changed or moved. (Brand & Dujovny, 2008)

Stoma implantation must be customised for each patient depending on several factors. Most patients do not possess an scar free, flush, well-developed abdomen. To make the stoma more visible to the patient, it should be positioned near the superior apex of the infra-umbilical crease

in the lesser quarter. The stoma may be better situated in the upper belly in obese people to allow for better sight and care, which would be impossible otherwise (Burch, 2017). Fold in the skin, scar tissue, and waistlines should all be avoided since they can affect the characteristics of the seal between the skin and the appliance's connection. Finally, to prevent a parastomal hernia or stomal prolapse, the stoma opening must travel through the rectus abdominis muscular tissue. (Brand & Dujovny, 2008)

Preoperative physiotherapy includes post-operative education to make sure the patient knows what to expect and not be surprised by the outcome. Training of certain movement stereotypes with light conditioning exercises. Above all, respiratory physiotherapy is necessary to maintain optimal function, static and dynamic breathing, isolated breathing, and cough training with emphasis on holding the surgical wound. Overall, pre-surgery physiotherapy helps prevent the incidence of post-surgery complications. (Abcarian & Pearl, 1988)

Respiratory physiotherapy

If there are signs of pathophysiology in the respiratory tract, preoperative physiotherapy aims to address it. Increased lower airway blockage, diaphragmatic dysfunction, reduced lung capacity, and decreased muscular strength of the muscles involved in breathing and coughing are only a few examples. It is already known that the combination of these factors can lead to bacterial proliferation in the airways, the formation of atelectasis and thus increase the risk of infection and serious complications. (Burch, 2017)

Respiratory physiotherapy before surgery should then consist of educating the patient about the effect of anaesthesia and the lung function itself, deep breathing and coughing exercises, and instruction on the early postoperative stage. (Reeve et al., 2019)

Fitness Training

Conditional exercises and fitness training with low intensity will enhance the patient’s condition and improve likelihood of successful post-surgery results.

It incorporates active limb movements as well as vascular gymnastics aspects, which will continue to be a part of therapeutic physical education in the post-operative period. Verticalization to sitting and standing, as well as practising the correct gait, are all part of training the correct preconceptions. (Pavel Kolář et al., 2013)

Early postoperative physiotherapeutic care

Postoperative care helps prevent the increase of postoperative complications and minimises chances of severe difficulties. This also makes the patient's return to normal life easier and faster. As soon as the patient is woken from anaesthetic, therapeutic physical education and its components should be implemented. Intubated patients who are under the effect of analgesics may benefit from passive movements and some aspects of respiratory therapy. The value of respiratory physiotherapy, conditioning, verticalization, and walking cannot be overstated. Positioning, stretching, and relaxation methods, self-service training, scar care, and the environment are also employed during this time. If necessary Occupational therapy and Ergotherapy are additional options. (*Ileostomy - Recovery*, 2018)

Positioning

Patients who cannot shift positions and patients with restricted mobility and sensitivity to particular body parts are treated with positioning at short intervals lasting 30 minutes to 3 hours. Sensory and motor functions are stimulated, the skin is lightened, blood circulation in body parts is improved, muscular atrophies and contractures are prevented, joint deformation is prevented, and analgesic effects are achieved. In the postoperative phase, positioning substantially impacts the patient's functional recovery. (Pavel Kolář et al., 2013)

Elevation of the limbs, particularly the lower limbs, is also beneficial in thromboembolic disease prevention. (Müller, 1992) It's also crucial to underlie the regions where the bones have been pardoned to avoid pressure ulcers, which can make the patient's rehabilitation more difficult. All postures must be comfortable, pain-free, and free of impediments to mobility. (Pavel Kolář et al., 2013)

Respiratory physiotherapy

Respiratory physiotherapy aims to improve breathing parameters and airway clearance, as well as airway hygiene, atelectasis prevention, and pneumonia prevention. If the patient is sufficiently stable, therapy can begin on the day of the surgery, even if the patient is unable to actively cooperate or his cooperation is restricted. In these situations, we mostly employ touch and reflexive breathing. Through manual touch on the patient's chest, we may particularly control the duration, intensity, fluency, and rate of exhalation via contact breathing. It is acceptable to perform exhalation with ease or employ vibration to help move mucus out of the airways. (VÉLE, 2006)

A patient with higher abilities can then cooperate with us actively and a more static and dynamic approach can be used. An extra implementation is the coughing and vibration that induces airway hygiene. Breathing gymnastics is primarily concerned with the natural style and rhythm of breathing, chest development and respiratory muscle strengthening. It makes use of localised breathing, isolated breathing, limb movement, and other techniques. (Miloš Máček & Libuše Smolíková, 1995)

Changes can be observed and subjectively felt by the patient, this improves the patient's mindset, muscle tone, clarity of breathing and health of internal organs.

Fitness Training

Post operative fitness training (after 5 days) is usually active isometric exercises rather than passive, although if fatigue sets in, passive training is used. Fitness workouts should involve vascular gymnastics, active limb movements, and torso muscular exercises. Active limb motions can help to mobilise, promote, and maybe build muscular strength, but they also allow you to practice self-service in bed. The initial dosage of fitness training should be at least 10 minutes twice a day, with the progressive development of time, difficulty, and intensity, taking the patient's condition into account. We teach the patient and attempt to persuade him to do some exercises on his numerous times during the day. (Lublin, 2018)

Fitness training aims to prevent thromboembolic illness and muscular atrophy by increasing muscle strength, improving coordination and balance, increasing endurance, supporting digestion and elimination processes, and improving the patient's mental state. (Müller & Bohuslava Müllerová, 1992)

Verticalization and walking

Generally, verticalization begins soon after the surgery, this increases the general movement of the patient. It progresses from a raised head position on the bed to a seat, to a standing posture, and finally to the practise of walking. Verticalization has a significant impact on the vestibular and cardiovascular systems, which has a knock-on effect throughout the body.

It serves as a prevention of pressure ulcers, pneumonia, and contractures. Optimal for the function of the diaphragm, increasing ventilation parameters, encouraging coughing and improving hygiene of airways. (Pavel Kolář et al., 2013) This is also useful for patients in ventilator intensive care units as it can reduces the dependency on mechanical ventilation and in turn accelerates their recovery and return to normal life. (Patel & Hall, 2013)

Scar care

Scar treatment and patient education for autotherapy can begin once the sutures have been extracted from the surgical wound. Scar treatment is done by lying on your back with your lower limbs bent and employing soft tissue and pressure massage methods. We strive to improve blood flow to the wound and its environs using a pressure massage. We strive to prevent the joints of specific layers of soft tissues from causing discomfort or response alterations by stretching the connective eyelash and shaping it into the letter "S" (or the letter "C"). This therapy should be done for 10 minutes multiple times a day. (Pavel Kolář et al., 2013)

It's crucial to maintain the scar clean until it's completely healed and free of scabs to avoid infection. It's not a good idea to lubricate it with ointment or lard. However, in the early stages of wound healing, rinsing with a hot shower and gentle drying might be used. At a later stage, however, moisturising the scar with a greasy cream without aroma is required for complete healing. (Pavel Kolář et al., 2013) Once the incision is closed, silicone, gel patches, dressings and compression treatment are indicated if the patient can tolerate it.

Muscle relaxation

Relaxation is an important part of physiotherapy and therapeutic physical education. Therapeutically, it improves the patients mental state, reduces muscle tone and as well as this, it supports the entire healing process. There are many different techniques that can be used in practice, some of which include PIR, Jacobson's method of progressive relaxation, yoga, music, and aromatherapy.

Physical therapy

Physical therapy techniques are used primarily to alter the scar and its localities, and they play a crucial part in recovery. We use methods that have vasomotor, analgesic, bio stimulating, anti-edematous, or anti-inflammatory properties. (Leoš Navrátil, 2019) As aspects of mechanotherapy, soft tissue methods and pressure massage have already been discussed. Thermotherapy, both negative and positive, is also used. We use elements of cryotherapy (cryobags, cold air, liquid nitrogen application) in negative thermotherapy for their vasomotor, analgesic, and anti-edematous effects. (Meaume et al., 2014)

Late postoperative physiotherapeutic care

After the physiotherapy operation, a phase begins 3 months after the patient has been discharged to their household. The aim of the operation is to regain the physical activity that had been lost over the course of the operation. Its aim is to reinstate the patient's physical activity back into their normal life. During the first few weeks, the patient is taught the physical importance that is needed for his abilities and is warned of the contraindicated activities that could harm him. Patients must not lift heavy objects or perform construction work to ensure their body isn't harmed. As well as this, jumping, push ups, reclining and contact sports are prohibited during this process. (*Ileostomy - Recovery*, 2018)

Aerobic activity and consistent exercise are essential in order to prevent muscle and bone loss as well as increasing fitness levels. Ideally, walking, cycling, and swimming are activities that are recommended. Walking can be changed into Nordic walking. Cycling is therapeutic in physical education, and it can be used as a relaxation method for the performer. For swimming, it is only recommended if the scar has healed. Infections can be developed upon the patient if swimming is done in natural or polluted water. A frequency that is recommended for physical activity is around 3-5 times a week for a minimum of 30 minutes. During the first few weeks, the heart rate should not exceed 120 beats per minute. However, if the scar has already healed, the oblique abdominal muscles are strengthened isometrically. The healing of a scar and its stabilization takes approximately 2 months, and it is only recommended to have an increase in physical activity after 3-6 months post-operation. (Lublin, 2018)

Evidence Based Medicine Meta-analysis

Meta-analysis one (Lertsithichai & Rattanapichart, 2004)

Objectives and Method

For individuals with colorectal disorders, this meta-analysis compares the complications of a temporary diverting ileostomy to those of a temporary colostomy. Two researchers conducted a thorough search for randomised controlled trials as part of the technique. This research was carried out using MEDLINE, the Cochrane database, evidence-based medicine reviews, and the journal club of the American College of Physicians. Only RCTs comparing temporary ileostomy against temporary colostomy for faecal diversion in all forms of colonic illness were included in the study (11 studies referenced). The meta-analysis included five hospitals administering "ileostomy AND colostomy", and "loop ileostomy AND loop colostomy" as all

these variations are appropriate methods of abdominal surgery requiring a stoma. Statistically significant *p* values were set at 0.05 or lower. (Sterne et al., 2001)

Results

Stoma prolapse, retraction, parastomal hernia, parastomal fistula, skin irritation due to intestinal contents leaking, and excessive stoma output with/without dietary adjustments were all considered stoma problems. Surgical site infection, intestinal blockage, and an enterocutaneous fistula were post-operative problems. Medical issues were the most common post-closure non-surgical consequences. Among the complications were pneumonia, deep vein thrombosis, pulmonary embolism, respiratory insufficiency, cardiac arrhythmia, myocardial infarction, and urine retention. (Harris et al., 2008)

It was found that in colon cancer patients receiving elective resections, temporary colostomies were considerably more likely to suffer stoma issues, as well as infectious and wound complications. Temporary ileostomy was associated with a higher rate of post-closure surgical complications. (Gavriilidis et al., 2018)

Stoma prolapse was shown to be much more prevalent in the colostomy group, with a risk roughly eight times higher than in the ileostomy group. The ileostomy group had much higher stomal output (6 times higher), which was consistent across all trials. In the colostomy group, there was a slightly greater chance, but the risk of leakage from the colonic anastomosis was not significant. The colostomy group had twice as many wound and infection problems, which was marginally significant. Although not statistically significant, there was a general trend in the ileostomy group to have a greater risk of gut blockage (twice as prevalent).

Meta-analysis two (Geng et al., 2015)

Objectives and Method

This meta-analysis compared studies mentioning the complications associated with defunctioning loop ileostomy compared with loop colostomy after colorectal surgery for rectal carcinoma. Both of these methods are used mostly to shield /handle anastomotic leakage post colorectal surgery. Therefore, it is logical to understand and conclude that after colorectal surgery (low anterior resection) for rectal cancer, which surgical method has the lowest risk of complications.

Literature research was directed on PubMed, MEDLINE, Ovid, Embase and Cochrane databases to classify reports issued between 1966 and 2013 aiming problems linked to and

associated with the surgeries under investigation. *"The following search headings were used: 'rectal neoplasms', 'defunctioning stoma', 'colostomy', and 'ileostomy'; the 'related articles' function was used to broaden the search."* (Geng et al., 2015)

The abstracts, papers, and references were thoroughly revised. All significant studies' reference lists were cross-checked. The citations of the recognised journals were carefully examined. Additional published and unpublished research were requested from authors and equipment manufacturers. The newest date of the review research was 31 March 2013.

The preliminary information search identified 134 studies from the given databases including 5 studies from grey sources. 111 were excluded because their titles described unsuitable matters. The remaining 23 studies were evaluated. In the end, only 5 fit the description to be allowed in the analysis. The meta-analysis was passed through the PRISMA statement and in accord with the suggestions prearranged by the Quality Reporting of Meta-analyses. (Moher et al., 2009) (Idris, 2012)

Results

Anastomotic leaking is one of a low rectal resection's most serious side effects. It's debatable whether proximal faeces diversion can avoid this problem with or without a defuncting stoma. (Tilney et al., 2007)

For 1,025 patients who had the surgery, the approach of pooled data for randomised control tests and observational studies was employed. The occurrence of sepsis, prolapse and parastomal hernia in loop Ileostomy receivers was lower than in loop Colostomy recipients, according to outcome indicators assessed for the formation of a defuncting stoma. Regarding postoperative wound infection and incisional hernia, outcome metrics for stoma closure demonstrated benefits for loop Ileostomy. (Rondelli et al., 2009)

When compared to loop Colostomy, loop Ileostomy was linked to a reduced rate of surgical problems during stoma formation. However, the difference in overall complications between stoma creation and stoma closure is unknown. The current study discovered that the differences in stoma design and closure between loop Ileostomy and loop Colostomy might be attributable to the ileum and colon's architecture and tissue/physiology features. The reduced occurrence of wound infection following conclusion of the ileostomy may be due to lower anaerobic bacterial counts in ileostomy excretion than anaerobic bacterial counts in normal excretion. Still, the release of fluids from the colostomy is reasonably comparable to the human waste. (Stang, 2010)

In the therapy of low rectal anastomoses, the end product of the meta-analysis imply that loop Ileostomy may be chosen over to loop Colostomy in terms of the prevalence of surgical problems related to the formation of a defunctioning stoma. Loop Ileostomy had a lesser incidence of infection, prolapse, and parastomal hernias than loop colostomy. Wound contamination and incisional hernias were less familiar with loop Ileostomy than loop Colostomy when closing stomas. (Murray et al., 2011) (Veljkovic et al., 2010)

Meta-analysis three (Sajid et al., 2014)

Objectives and Method

The reason of this analysis is to methodically examine the randomised, organised examinations associating the efficacy of purse-string closure (PSC) with the conventional linear closure (CLC) of an ileostomy laceration. (Li et al., 2014)

"The trails were analysed using RevMan®, and the combined outcomes were expressed as risk ratio (RR) and standardized mean difference (SMD)." (Sajid et al., 2014)

Results

The PSC approach for ileostomy wounds is linked with a 90 per cent lower incidence of SSI, according to this study, without affecting the time of the surgery or hospital stay.

Because of its nature, the purse-string estimate approach to ileostomy laceration closing deals various benefits. Purse-string closing leaves a one-centimetre-diameter essential drainage cavity, which facilitates constant drainage of secretion and festering fluid in this extensively polluted site, resulting in a smooth restorative process.

Additionally, after the sub-cuticular suture has been immersed or detached and the middle pit occupied with neatly grinding tissue, the wound is concealed by the neighbouring epidermis, resulting in a more cosmetically pleasing site. On the other hand, Linear closure does not allow for the effluvium of secretion, resulting in a greater possibility of SSI, swelling development, and an under-granulating injury site, leading to delayed healing and a more extensive wound scar that is unsightly in that setting. (McCartan et al., 2013) (Camacho-Mauries et al., 2013)

3 Special part (Case study)

3.1 Methodology

The special part of the thesis contains data collected at the Institute of Clinical and Experimental Medicine (IKEM) in Prague, from the dates of 17th January to 11th February 2022. I was supervised by Bc. Robert Charvát during this time.

Much of the placement took place in the intensive care unit, as that is where my patient resided post-surgery, as well as the standard surgical department.

Informed consent was given to the patient, whose reports are part of this thesis, which he signed and granted permission to collect data obtained during therapy. The informed consent was sent together with the application of the Ethics Committee of the Charles University FTVS for approval. The statement of the ethics committee and the document of informed consent are attached to this bachelor's thesis in the 'Annex'

The patient was also made aware of the goals during the therapy provided. He abided by all the recommendations given by the physiotherapist to his best ability.

The following methods were used in the examination of the patient:

- Soft tissue examination according to Lewit.
- Joint examinations according to Lewit.
- Palpation of muscles and muscle tone, scar therapy, pelvis.
- Examination of breathing stereotype in standing and sitting.
- Neurological examination using a neurological hammer.
- Anthropometry using a tape measure.
- Examination of muscle shortness according to Janda.
- Examination of muscle strength with evaluation according to the scale of Janda's muscle test.
- Goniometric examination according to Janda and Pavlu using a goniometer.
- Barthel index for active daily lifestyle (ADL)
- Romberg's stance test

Based on the examination, therapy was then applied, adapted to the patient's current condition. The methods used in the therapy were chosen based on the knowledge acquired in IKEM and gained by the study of physiotherapy at the Charles University FTVS. The therapy consisted of the following methods:

- Respiratory physiotherapy according to Smolíková
- Soft tissue techniques according to Lewit
- Mobilization according to Lewit
- Proprioceptive neuromuscular facilitation (PNF) according to Kabat
- Passive and active movements and individual LTV according to Haladová
- Verticalization and walking training according to Haladová
- Post isometric relaxation (PIR) according to Lewit

Aids were also used in the therapy, specifically a wheelchair, crutches, an overball and a foam ball. The whole therapeutic process was completed by performing a final kinesiological examination.

3.2 Anamnesis

Name: J.S, Male

Year: 1942

Diagnosis: Z43.2 – Ileostomy

Present state

Objective

The patient is conscious and reacting to stimulus, he can communicate and answer questions without problems. The patient is oriented and cooperative.

Postoperative wound in the middle of the abdomen, no external leak, 2 drains are led out on the right side of the torso. Leads on the front of the chest for continuous ECG measurements.

Height (cm): 172

Weight (kg): 73

BMI: 24.7

Blood pressure, Heart rate: 138/80 mmHg, 55bpm

Blood saturation: 98%

Body temperature: 36.2°

Dominant side: Right

Glasses: Reading glasses

Communication ability: Optimal

Subjective

Chief complaint

The patient's main complaint is feeling internal pain on a regular basis. Having trouble with sitting to standing and currently cannot walk, feeling easily fatigued and dealing with scar pain most of the day when in certain positions. Pain level was a moderate 5 out of 10 on the first day I evaluated the patient. General feeling of tiredness and fatigue.

Personal anamnesis

Normal development.

Family anamnesis

Grandfather found positive for tumours in the abdomen, mother died at 90 years of age, sister died at age of 60, daughter healthy, son deaf from birth, immobile, epileptic, was operated on the brain.

Injury anamnesis/ previous rehabilitation

Skiing injury (1977) caused broken tibia in 4 places and broken fibula in 2 places. Resulting in right leg being 2cm shorter than left leg.

9th and 10th ribs fractured and Titanium knee due to skiing accident (1977). 2 weeks post injury rehabilitation, including physiotherapy.

Past medical and surgical history

Status post Transurethral resection of the prostate, 2016.

Status post cholecystectomy.

Bilateral cataract surgery.

Diabetes Mellitus type II. Accidental seizure in preoperative examination about 10 years, previously at diabetology, blood glucose sometimes measures 5-6 mmol/l.

- 1994 sigmoid resection for CA, after chemotherapy surgery, monitored at oncology FNM
- 2010 period of palpitations, chest pain and stress after retirement without major difficulty.
- 1/2020 examined for anaemia - CT scan of the abdomen and diagnosed with carcinoma c. Ascendant- solved surgically:

- 24.1. P hemicolectomy + lymphadenectomy for caecal carcinoma with ileo-transverse anastomosis.
- 26.1. necessary revision for dehiscence in anastomosis with circumscriptive peritonitis - resection of anastomosis and construction of a new ileo- transverse anastomosis performed.
- 28.1. necessary 2nd revision for susp. insufficiency in anastomosis, necessary resection of anastomosis, ileostomy.
- 29.1. Third revision for jejunal perforation in the loop bundle after previous treatment, finding unsuitable for resection or re-suture - therefore perforation of the previous perforation was performed and led through the abdominal wall as a jejunostomy.

- After surgery, fluid substitution -3 times a week (1 litre), in June 2020, to support nutrition sipping.
- Chronic rhinitis
- 6/2021 Revision, hepatic biopsy, complete intestinal deliberation, occlusion of jejunostomy, occlusion of ileostomy, occlusion of hemicolectomy, ileorectoanastomosis, protective axialis ileostomy, drain for fluid.

Current medical anamnesis

Patient after repeated GIT resections, after reconstructive procedures on the 6/2021:

- 12.1.2022: IKEM to immerse the ileostomy.
- 14.1.2022: Signs of enteric leakage, worsening of the condition, sepsis, (need for pharmacological treatment. Surgical revision, anastomosis) small intestine about 5 cm behind the anastomosis, re-suture, definitive suture, flush drainage. Furthermore, flush drainage gradually removed post-operation, leaving only one drain which is stomach waste. Patient is allowed to consume tea with biscuits, gradually restored passage, stool, and winds.
- 19.1.2022 Elevation, control of nutritional drips, with modification. At 21:00 after returning from the toilet enteral leakage of the wound after immersion of the ileostomy, after its dissolution at the base clear enteral leak, indicated for surgical revision. Postoperative admission. Tearing (disruption) of surgical wounds. Infection after surgery. Unspecified severe protein-energy malnutrition.

Pharmacological anamnesis

Fluconazole 2mg / ml i.v. 400 mg i.v. administered every 12 hours, Vancomycin 1000mg i.v. administered every 12 hours Controloc 20 mg iv 1-0-1, Calcichew D3 1 g / 800iu after 0-0-1, Fraxiparine 0.4 ml sc 0-0-0-1, Novalgin 1000mg i.v. 6 hours at VAS> 3, Perfalgan 1000mg i.v. 8 hours at VAS> 4, Ketonal 100mg i.v. at 12 o'clock VAS> 5, Dipidolor 15mg i.m. at 8 o'clock VAS> 7, Humulin 50j. 50ml FR I.v. 1-8 J / h cont. according to glycemia, target 5-9 mmol / l, Reimbursement FR / HR / PL according to balance, target +500 ml / 24h.

Allergy anamnesis

None

Abuses

10 cig / day, alcohol occasionally.

Diet

Average traditional Czech food diet.

Functional anamnesis

The patient can sit but unable to walk or climb stairs as there is a lot of pain. The Barthel scale index is 75/100.

Social anamnesis

Patient lives with his wife in an apartment with an elevator.

Occupational anamnesis

Retired, used to work as a technical engineer. Travelled the world with his job and knows 5 languages.

Sport, Physical activity

None

3.3 Initial Kinesiological examination

Neurological examination

Cranial nerves

Examination of the cranial nerves:

I. Olfactory nerve

- The patient can smell the scent of perfume and other fragrances.

II. Optic Nerve

- The field of view from both eyes is normal.

III. Oculomotor nerve

- Movement of eyes in upwards, downwards, and inward directions are all physiological. Photoreaction symmetrical on both sides.

IV. Trochlear nerve

- The patient does not report any vision problems.

V. Trigeminal nerve

- No painful sensation of nerve.

VI. Abducens nerve

- Symmetrical outward movement of both eyes are physiological.

VII. Facial nerve

- Facial expressions are adequate. No signs of facial paresis.

VIII. Vestibulocochlear nerve

- Hearing is without problems.

IX. Glossopharyngeal nerve

- Patient can say “kah” and “ah” with symmetrical rising of the palate and has a gag reflex.

X. Vagus nerve

- As well as IX nerve test, patient can also cough. This indicates normal function.

XI. Accessory nerve

- Patient shrugged and rotated head both without resistance and against minimal resistance, without any pathologies.

XII. Hypoglossal nerve

- Tongue motility to both sides is physiological and patient can stick his tongue out without pain.

Upper limbs examination

- Deep tendon reflexes testing: No pathologies. Negative.

The deep tendon reflexes that were tested are as follows: Biceps brachii (C5-6), Brachioradialis (C5-6) and Triceps brachii (C7-8)

- Paretic signs: No pathologies. Negative.

The paretic signs that were tested are as follows: Mingazzini, Barré, Hanzal and Du Four.

- Spastic-irritative signs: No pathologies. Negative.

The spastic-irritative signs that were tested are as follows: Hoffman, Juster and Tromner.

Lower limbs examination

- Deep reflexes: No pathologies. Negative.

The deep tendon reflexes that were tested are as follows: Patellar (L3 - L4) and Achilles' tendon (S1- S2).

- Paretic signs: No pathologies. Negative.

The paretic signs that were tested are as follows: Barré, Mingazzini.

- Spastic-irritative signs: No pathologies. Negative.

The spastic-irritative signs that were tested are as follows: Babinski, Chaddock, Oppenheim and Rossolimo.

Taxes UE - Finger-Nose-Finger sign

- Right side: Negative
- Left side: Negative

Taxes LE - Heel-to-Shin test

- Right side: Negative
- Left side: Negative

- Lasègue's sign: Negative

Sensation

Superficial and deep sensations are apparent across the body; upper and lower segment display no signs of pathologies.

Musculoskeletal examination

Examination of breath and respiratory stereotype

Performed in supine and sitting. Breathing is done mostly through upper thoracic region. The breaths are rather shallow, with a slight pause between the inhales and exhales. The wave of breathing travels in a proximodistal direction and is laterally symmetrical, though there is minimal activation of the lower thoracic and abdominal region. The patient has an upper thoracic dominant breathing stereotype.

Soft tissue examination according to Lewit

General soft tissue:

Skin was elastic and freely movable. No sensitive areas apart from the scar. Soft tissue on upper extremities were not restricted. Soft tissue around the chest region had limitations in all directions. Reduction in the mobility of the abdomen due to scar tissue and previous surgical endeavours, skin of the abdomen area was also slightly warmer due to the scar and stoma.

Fascia examination:

Fascia around the neck was restricted in the right longitudinal axis due to frequent turning to the specific side whenever he wanted to drink tea, check his phone, or eat something. Reduced mobility in the areas of the scar and abdominal region. Fascia in general was not restricted.

Examination of the surgical scar:

The wound is around the right side of the abdomen and is covered by a medical gauze. Due to the stoma and abdominal drains, it was painful to palpate the scar and quite sensitive for the patient. Where there was less pain, therefore able to examine, there was reduced mobility of tissue around the scar in all directions.

Muscle palpation

An overall lack of muscle is observed, this may be due to the fact that the patients' medical report mentions a reduced amount of protein is present in his body. Nonetheless, palpation of the left upper limb reveals a hypotonic nature across all muscles. As well as both paravertebral

muscles and hypertonicity of m. quadratus lumborum. Since the patient is right side dominant, he tends to use his right arm for most movements, this may be a reason that when palpated, his right arm tended to be more hypertonic. With this, increased tone was felt around both epicondyles of his humerus.

The lower limbs have signs of hypertonicity, when compared with each other, the right displays a relatively higher tone compared to the left. This is possibly due to the skiing accident and previously broken tibia/ fibula.

Pelvis palpation

Frontal plane:

- Pelvis is equal on both sides

Sagittal plane:

- Pelvis in slight anteversion

Transverse plane:

- No rotation present.

Postural evaluation

Since the patient was unable to stand, a sitting posture was examined. Slight lumbar kyphosis was present as it was painful in the abdominal area (scar region) when he tried to do lumbar lordosis.

Upper thoracic region of the spine from the lateral view showed a high degree of kyphosis. Specifically, in the T4-T7 area.

The cervical spine follows the natural 'S' curve and has no shift or rotation of any kind.

The head of the patient is in a physiological position and does not tilt or shift to any side.

Specific posture testing

Two-scale test: Could not be performed as patient cannot stand.

Romberg test: Could not be performed as patient cannot stand.

Trendelenburg test: Could not be performed as patient cannot stand.

Véle's test: Could not be performed as patient cannot stand.

Modification of standing

Standing on toes: Could not be performed as patient cannot stand.

Standing on heels: Could not be performed as patient cannot stand.

Standing on one leg: Could not be performed as patient cannot stand.

Gait analysis

Patient is unable to walk given his current circumstances. Rest is advised as he requires time to heal and regain energy. At the moment, the patient is transported by wheelchair.

Janda's movement stereotypes

Shoulder abduction

Patient could perform shoulder abduction with no pathological signs. All muscles worked in a synchronised pattern. However, there was slight pain at the end of the range of motion. This was observed with both upper extremities, no compensatory muscles were involved when this pain occurred, but the patient relaxed and lowered his arm. This eccentric motion was faster than the concentric movement stereotype. The logical explanation for this would be, as mentioned in the anamnesis, due to the lower level of protein and lack of overall muscle that the patient cannot maintain the motion for too long and had to quickly lower his arm.

Cervical flexion

During the second attempt of the movement, the patient exhibited signs of SCM dominance. Although, this was not present in the third attempt as the patient approached the movement in a slower, more controlled method. Without my intervention.

Hip abduction

The stereotype was performed with a high degree of accuracy. However, it was noticed that the patient displayed the quadratus mechanism which means there was elevation of the pelvis, due to the hypertonic nature of m. quadratus lumborum.

Joint play examination according to Lewit

Muscle	*Direction*	*L*	*R*
Head of Fibula	Dorsal	No restriction	Restriction
	Ventral	No restriction	Restriction
Tibiofibular joint	External rotation	No restriction	Restriction
	Internal rotation	No restriction	Restriction
Patella	Lateral	Restriction	No restriction
	Medial	No restriction	No restriction
	Cranial	No restriction	No restriction
	Caudal	No restriction	No restriction
Talocrural joint	Springing	No restriction	Restriction
Lisfranc joint	Rotational	No restriction	Restriction
	Dorsal	No restriction	No restriction
	Plantar	No restriction	No restriction
Sacro-iliac joint	Springing	No restriction	Restriction
Wrist	Palmar shift	Restriction	No restriction
	Dorsal shift	No restriction	No restriction
Acromioclavicular	Craniocaudally	No restriction	No restriction
	Ventrodorsally	Restriction	Restriction
Knee	Lateral gapping	Restriction	Restriction

Table 1: Initial joint play examination according to Lewit.

Anthropometric measurements

LEE			***L***	***R***
Length (cm)	Anatomical		85	83
	Functional		91	89
	Upper leg		40	40
	Lower leg		45	43
	Heel		34	33
	MTP		24	24
Circumference (cm)	Knee	Superior patellar apex	45	44
		Patellar	45	46
		Inferior patellar apex	36	35
	Calf		37	35
	Quadriceps		44	43
	Ankle	Malleolar	26	25
		Calcaneal	36	35

Table 2: Initial anthropometric measurements of lower limbs.

UEE		***L***	***R***
Length (cm)	Arm	76	76
	Upper arm	34	34
	Lower arm	43	43
	Wrist	18	19
	MCP	24	25
	Head	58	

Table 3: Initial anthropometric measurements of upper limbs.

Muscle Strength test according to Janda

		L	***R***
Hip	Extensors	3	3
	Flexors	3	3
	Abductors	3	3
	Adductors	4	4
Shoulder	Extensors	4	4
	Flexors	4	4
	Abductors	3	3
	Adductors	4	4
Elbow	Extensors	3	3
	Flexors	4	3
Fingers	Extensors	4	5
	Flexors (longus)	3	4

Table 4: Initial muscle strength test according to Janda.

Passive RoM measurements

PRoM		***L***			***R***		
Shoulder	S:	15	0	175	20	0	180
	F:	120	0	0	115	0	0
	T:	45	0	120	40	0	115
	R:	45	0	75	50	0	75
Elbow	S:	0	0	145	0	0	145
Wrist	S:	70	0	75	65	0	75
	F:	20	0	25	20	0	20
Hip	S:	20	0	120	20	0	125
	F:	30	0	35	35	0	30
	R:	50	0	10	55	0	10
C spine	S:	45		0		40	
	F:	35		0		45	
	R:	50		0		55	

Table 5: Initial passive range of motion measurements.

Active RoM measurements

ARoM		***L***			***R***		
Shoulder	S:	15	0	170	15	0	170
	F:	100	0	0	105	0	0
	T:	30	0	110	25	0	110
	R:	45	0	65	40	0	70
Elbow	S:	0	0	140	0	0	135
Wrist	S:	50	0	75	55	0	70
	F:	15	0	25	15	0	20
Hip	S:	10	0	110	10	0	105
	F:	20	0	30	20	0	20
	R:	40	0	10	40	0	10
C spine	S:	40		0		40	
	F:	35		0		40	
	R:	50		0		55	

Table 6: Initial active range of motion measurements.

Muscle length examination according to Janda and Kendall

Muscles	***L***	***R***
Hip adductors	1	2
Hip abductors	1	0
Hamstrings	0	1
Pectoralis Major	1	1
Pectoralis Minor	1	1
Levator scapulae	0	0
Cranial Trapezius	0	0
SCM	1	0
Piriformis	1	2
Triceps surae	2	2

Table 7: Initial muscle length measurements.

Conclusion of initial examination

The initial examination was performed under the supervision of a physiotherapist. As mentioned in the day-to-day therapies below, the patient underwent a revision surgery twice during this period. Due to this fact, the results of the examination may be affected. The limitation in this case was that the patient was fatigued and told to rest which hindered the physiotherapeutic progress slightly.

According to the Barthel index, the assistance of the nurse is needed when the patient needs the bathroom and therefore cannot perform certain normal daily activities.

Muscle strength was higher in the upper extremities, this is highly likely due to the injuries sustained in the lower extremities after the skiing accident. However, due to post-surgical condition it could be possible that the patient exhibits higher strength in a more favourable scenario.

The examination of soft tissues revealed higher tension around the scar in the abdominal region, as expected. High tension in the skin and soft tissue was palpated across the front of the abdomen. Fascia around the neck was restricted in the right longitudinal axis due to frequent turning to the specific side whenever he wanted to drink tea, check his phone, or eat something. Reduced mobility in the areas of the scar and abdominal region. Fascia in general was not restricted.

Joint play examination revealed that there was restriction in the fibular head of the right leg, where the patient was injured in the skiing accident. This restriction was in the both the dorsal and ventral direction. As well as bilateral acromioclavicular joints, ventrodorsally, probably caused by reflex changes. Lateral gapping of the knees revealed restriction on both lower limbs. Unsurprisingly, the right Sacro-iliac joint was restricted in mobilisation.

The hip joint is where the majority of restriction was found when performing active movements in the frontal and rotational plane. Firstly, it required much effort from the patient and fatigue settled in promptly. The performance was less than adequate in the right hip. This could be due to the fact that, according to anthropometric examination, the right lower limb is shorter. This indicates an imbalance of postural muscles, hypertonicity of the quadratus lumborum is a resulting factor.

3.4 Short-term and long-term physiotherapy plan

Short-term physiotherapy plan

- Respiratory physiotherapy, airway clearance, improvement of tidal volume
- Improving muscle strength
- Bed transfers, ADL
- Increase the range of motion of lower limbs
- Springing joints
- Stretching of shortened muscles
- Hypertonic muscle relaxation
- Verticalization, sitting and slowly introducing standing.
- Soft tissue techniques in the abdomen and chest, scar care
- Improving mental health

Long-term physiotherapy plan

- Increasing and maintaining fitness by appropriate physical activity
- Sensorimotor stimulation
- Activation of the deep stabilization system
- Standing and walking training
- Strengthening the muscular corset in the area of the hip joints
- Scar therapy and fascial release of abdomen and chest
- Correction of the posture

Therapy design

- Passive and active movements
- Respiratory physiotherapy - contact, breathing gymnastics
- Scar therapy
- Fascial stretching
- Post-isometric relaxation acc. Lewit
- PIR with stretching acc. Janda
- Facilitation of hypotonic muscles
- PNF according to Kabat for strengthening and relaxing muscles
- Mobilization acc. Lewit
- Corrected seat according to Brügger
- Corrected standing posture according to Janda
- Training to walk correctly and improving overall gait stereotype
- Training ADL

3.5 Therapy Progress

In the following section, I am reporting the daily examination and therapy from the 24th of January until the 11th of February 2022.

Date: 24.01.2022 (10 days post-surgery)

- **Objective:**
  - The patient is ten days after the operation, he is stable in the ICU ward.
  - Surgical revision was performed on the 19.01.2022 due to enteric leak, re-suture of wound. Care for sepsis.
  - Fully conscious, communicates, oriented in space and time.
  - Extubated, 2 drain outlets on right side of stomach.
  - High level of upper thoracic breathing.
  - Hypotonus of upper limbs.
- **Subjective:**
  - Patient feeling: The patient is fatigued and feels weak. He has a slight headache with pain ranging from the sides to the back of his head.
  - Pain: 8 out of 10
- **Assessment:**
  - During the palpation examination of the breath wave and respiration, heavy use of upper thoracic area for breathing was palpated, the lower part of the chest shows little involvement.
  - The scar from the surgical wound and the outlets of the drains are covered with medical film. The soft tissues in the abdomen are slightly hypertensive in all directions.
  - Patients feeling of weakness is correlated to his lower body muscle strength, cannot push again my hand as resistance.
- **Objectives of Therapy:**
  - Relaxation of the airways, improvement of chest development during respiration
  - Improving muscle strength, joint mobility
  - Stretching of shortened muscles
- **Therapy design:**
  - Localized, contact respiratory physiotherapy
  - Active movements, active assisted movements

- PNF according to Kabat for lower limbs

- **Procedure:**
  - **Respiratory physiotherapy**
    - As a part of contact breathing, I followed the normal breathing of the patient with an effort to slightly deepen his breath.
    - I then asked him to follow my hands with his breathing and actively inhale and exhale deeper.
    - He then tried to inhale into the lower chest, performing a wave like breathing pattern.
    - After performing a vibration therapy attempt to cough, the patient is instructed to hold the scar.
  - **Active movements, active assisted movements**
    - Ankle rotations to induce movement into the lower limbs
    - Hip flexion (assisted)
    - Shoulder flexion and abduction
  - **PNF according to Kabat**
    - Passive execution of I. flexion and I. extension diagonal of lower limb.
    - Active execution of I. flexion and I. extension diagonal with assistance.
- **Results:**
  - Patient felt less fatigued as active movements got blood flowing and respiratory physiotherapy helped with breathing stereotype. Pain rating dropped to 7/10.
  - PNF stretched tight hip flexors and abductors. Breathing stereotype improved.
- **Self-Therapy:**
  - The patient was instructed to repeat the active limb movements that were included in the therapy 6-8 repetitions of each.
  - Intentionally practice improved breathing stereotype and wavelike pattern. Patient can also place his hands on his diaphragm to help conscious deeper inhales and exhales.

Date: 25.01.2022

- **Objective:**
  - The patient is seven days after the operation, he is stable in the ICU ward.
  - Ate breakfast, brushed teeth, and shaved without problems.
  - Hypotonus of upper limbs.
- **Subjective:**
  - Patient feeling: The patient has more energy than previous session. Headache persists, pain in abdominal area near scar.
  - Pain: 7 out of 10
- **Assessment:**
  - Soft tissue around neck feels tight and restricted.
  - The scar from the surgical wound and the outlets of the drains are covered with medical film. The soft tissues in the abdomen are slightly hypertensive in all directions.
  - Joint mobility of hip is sub optimal.
- **Objectives of Therapy:**
  - Improving muscle strength.
  - Increase joint mobility.
  - Stretching shortened muscles.
  - Improve soft tissue displacement in the neck area.
- **Therapy design:**
  - Mobilization of hip joint
  - Active movements, active assisted movements
  - Soft tissue techniques of neck extensors
  - PNF according to Kabat for lower limbs
- **Procedure:**
  - **Mobilization**
    - Mobilization of the hip joint by passive circling
    - Traction of the hip joint in the axis of the femoral neck
  - **Active movements, active assisted movements**
    - Ankle rotations to induce movement into the lower limbs
    - Hip flexion (assisted)
    - Shoulder flexion and abduction

- **Soft tissue techniques**
    - Manual release of skin and fascia in neck area.
    - Movements and displacements of the proximoventral half in different directions, improving the displacement
- **PNF according to Kabat**
    - Passive execution of I. flexion and I. extension diagonal of lower limb.
    - Active execution of I. flexion and I. extension diagonal with assistance.

- **Results:**
    - Especially the neck fascia felt released
    - PNF stretched tight hip flexors and abductors.
    - Breathing stereotype improved.
    - Shoulder movement and ROM improved
- **Self-Therapy:**
    - The patient was instructed to repeat the active limb movements that were included in the therapy 6-8 repetitions of each.
    - Active movements of the hip were given to make full use of hip joint mobilization.
    - Scar therapy

Date: 26.01.2022

- **Objective:**
  - The patient was moved to inpatient surgery ward, he is stable.
  - He is tired as he was just moved to the new ward.
  - Increased pain and sensitivity to palpation in abdomen.
- **Subjective:**
  - Patient feeling: More pain in abdominal area due to increased movement within a short period of time.
  - Pain: 8 out of 10
- **Assessment:**
  - The soft tissues in the abdomen are slightly hypertensive in all directions.
  - Breathing stereotype suboptimal.
  - Muscle strength of upper limbs reduced
- **Objectives of Therapy:**
  - Improving muscle strength.
  - Stretching shortened muscles.
  - Improve breathing stereotype
- **Therapy design:**
  - PNF according to Kabat for upper limbs
  - Localized, contact respiratory physiotherapy
  - Active movements, active assisted movements
- **Procedure:**
  - **PNF according to Kabat**
    - Passive execution of I. flexion and I. extension diagonal of upper limb.
    - Active execution of I. flexion and I. extension diagonal with assistance.
  - **Respiratory physiotherapy**
    - As a part of contact breathing, I followed the normal breathing of the patient with an effort to slightly deepen his breath.
    - I then asked him to follow my hands with his breathing and actively inhale and exhale deeper.
    - He then tried to inhale into the lower chest, performing a wave like breathing pattern.

        - After performing a vibration therapy, the patient is instructed to hold the scar.
    - **Active movements, active assisted movements**
        - Ankle rotations to induce movement into the lower limbs
        - Hip flexion (assisted but with less assistance than previous therapy session)
        - Shoulder flexion and abduction against slight resistance.
- **Results:**
    - Breathing quality improved as well as better stereotype.
    - PNF stretched and strengthened upper body muscles.
    - Shoulder strength and tone increased.
- **Self-Therapy:**
    - Intentionally practice improved breathing stereotype and wavelike pattern. Patient can also place his hands on his diaphragm to help conscious deeper inhales and exhales.
    - The patient was instructed to repeat the active limb movements that were included in the therapy 6-8 repetitions of each, for 2 sets.
    - Using other arm as resistance, patient to perform shoulder flexion for 6 reps.
    - Isometric contraction in shoulder abduction against bedside protection barrier, as resistance for concentric contraction can only be given by therapist.
    - Scar therapy

Date: 28.01.2022

- **Objective:**
  - The patient is in the inpatient surgery ward, he is stable.
  - He communicates well, though very slowly.
  - Increased mobility of ankle joint.
- **Subjective:**
  - Patient feeling: Relaxed, headache decreased however, pain in abdomen still present and strong.
  - Pain: 8 out of 10
- **Assessment:**
  - The soft tissues in the abdomen are hypertensive in all directions.
  - Breathing stereotype is slightly improved.
  - ADL reduced, introduction of verticalization necessary.
- **Objectives of Therapy:**
  - Introduction of verticalization from lying to sitting, to improve ADL.
  - Stretching shortened muscles.
  - Reduction of soft tissue hypertension around the surgical area.
- **Therapy design:**
  - PNF according to Kabat for upper limbs
  - Active movements, active assisted movements
  - Soft tissue techniques.
  - Verticalization
- **Procedure:**
  - **PNF according to Kabat**
    - Passive execution of I. flexion and I. extension diagonal of upper limb.
    - Active execution of I. flexion and I. extension diagonal with assistance.
  - **Active movements, active assisted movements**
    - Alternating dorsal and plantar flexion in the ankle joint.
    - Ankle rotations to induce movement into the lower limbs.
    - Active movements of the cervical spine.
    - Hip flexion (without assistance.)
    - Shoulder flexion and abduction against slight resistance.

- **Soft tissue techniques**
    - Manual release of skin and fascia in surgical area.
    - Movements and displacements of the proximoventral half of the scar in different directions, to improve mobility.
    - Gentle pressure massage around scar area.
    - Stretch of the skin surrounding the surgical wound.
- **Verticalization to sitting position**
    - Instruction to hold the surgical wound and turn sideways
    - Instruction to push on the bed for support in moving to sitting position.
    - Instruction to go to a sitting position.
    - Assistance is given to help patient achieve seated position.
    - Massage of back and neck muscles to reduce hypertension.

- **Results:**
    - Patient felt elated to be verticalized although it did not last for a long time as he mentioned getting a headache, so he lied back down again.
    - Upper body strength increased through regular PNF, and resistance curve is higher than previous session.
    - Pain reduced to 7 out of 10
- **Self-Therapy:**
    - Continual intentional practice of breathing stereotype and wavelike pattern. Patient can also place his hands on his diaphragm to help conscious deeper inhales and exhales.
    - The patient was instructed to repeat the active limb movements that were included in the therapy 6-8 repetitions of each, for 2 sets.
    - Using other arm as resistance, patient to perform shoulder flexion for 6 reps.
    - Isometric contraction in shoulder abduction against bedside protection barrier, as resistance for concentric contraction can only be given by therapist.
    - Scar therapy

Date: 31.01.2022

- **Objective:**
  - The patient is in unwell. Surgical leak observed under wound sponge 2 days ago.
  - Taken in for revision surgery, suture of intestines.
  - He is resting, unable to perform verticalization or active movements.
  - Communication is poor.
- **Subjective:**
  - Patient feeling: Tired, difficult for him to talk for a long time.
  - Feeling weak and unmotivated.
  - Pain: Increased to 8 out of 10.
- **Assessment:**
  - Breathing stereotype is not intentionally monitored, slow breathing.
  - The soft tissues in the abdomen are hypertensive in all directions.
  - Surgical wound covered with medical sponge. Painful during palpation.
- **Objectives of Therapy:**
  - Stretching of pectoral muscles.
  - Reduction of soft tissue hypertension around the surgical area.
  - Increase hip joint mobility.
- **Therapy design:**
  - Passive movements to encourage activity of limbs.
  - Active assisted movements if patient is capable.
  - Soft tissue techniques in chest area.
- **Procedure:**
  - **Passive and active assisted movements.**
    - Passive movements of the cervical spine.
    - Hip flexion, abduction, and adduction.
    - Shoulder flexion and abduction (active assisted).
    - Elbow flexion.
  - **Soft tissue techniques**
    - Manual release of skin and fascia in chest area.
    - Movements and displacements of the proximoventral half of the scar in different directions, to improve mobility.
    - Gentle pressure massage around scar area.

- **Results:**
  - Improved soft tissue displacement in the chest area
  - Increased range of motion in the elbow joint (flexion).
  - Increased range of motion in shoulder flexion and abduction.
  - Hip flexion, abduction, and adduction feel smoother when performing passive motion and reaching barrier.
  - Scar area is tense, massage had little effect.
- **Self-Therapy:**
  - Shoulder flexion and abduction was the only active assisted motion patient could perform; therefore, it was instructed as a self-therapy using opposite upper limb as support. 6 reps, when patient has the strength to perform it.
  - Continual intentional practice of breathing stereotype and wavelike pattern. Patient can also place his hands on his diaphragm to help conscious deeper inhales and exhales.

Date: 03.02.2022

- **Objective:**
  - The patient is in the KARIP ward, he is stable.
  - He communicates well, though very slowly.
  - Reduced muscle strength of hip abductors and adductors.
- **Subjective:**
  - Patient feeling: Persistent headache, pain around still present and strong.
  - Pain: 8 out of 10
- **Assessment:**
  - Breathing stereotype is not consciously improved, palpation reveals slight upper thoracic dominance.
  - Upper body increased in mobility however, strength is suboptimal.
  - Active movements show reduced muscle strength of hip abductors and adductors.
  - Tension in the cervical region.
- **Objectives of Therapy:**
  - Improve breathing stereotype.
  - Stretching shortened muscles.
  - Improve muscle strength
  - Reduce restriction of cervical region
- **Therapy design:**
  - PNF according to Kabat for upper limbs.
  - Active movements, active assisted movements.
  - Respiratory physiotherapy to improve breathing stereotype.
  - Soft tissue technique and traction of cervical area.
- **Procedure:**
  - **PNF according to Kabat**
    - Passive execution of I. flexion and I. extension diagonal of upper limb.
    - Active execution of I. flexion and I. extension diagonal with emphasis on the pectoralis major and minor.
    - Method of repeated contractions for strengthening upper limbs.
    - Emphasis on stretching pectoralis major and minor as well.

- **Active movements, active assisted movements**
    - Alternating dorsal and plantar flexion in the ankle joint.
    - Rotations of the ankle.
    - Flexion and extension in the knee and hip joint by sliding the heel on a pad.
    - Extension of the knee joint by pressure into the overball under the knee
    - Abduction and adduction in the hip joint by sliding the foot over the mat.
    - Active movements of the upper limbs by alternating extension with abduction and flexion with finger adduction
    - Wrist rotation
    - Active movements in the cervical spine
- **Respiratory physiotherapy**
    - As a part of contact breathing, I followed the normal breathing of the patient with an effort to slightly deepen his breath.
    - I then asked him to follow my hands with his breathing and actively inhale and exhale deeper.
    - He then tried to inhale into the lower chest, performing a wave like breathing pattern.
    - After performing a vibration therapy, the patient is instructed to hold the scar.
- **Soft tissue techniques**
    - Traction of the cervical spine with soft tissue massage acc Lewit.
    - Relaxation and release of the Cervical and C/Th junction fascia.

- **Results:**
    - Upper body strength increased through regular PNF.
    - Stretching of pectoral muscles was achieved.
    - Cervical fascia relaxed and pain reduced to 7/10.
- **Self-Therapy:**
    - Continual intentional practice of breathing stereotype and wavelike pattern.
    - The patient was instructed to repeat the active limb movements that were included in the therapy 6-8 repetitions of each, for 2 sets.
    - Scar therapy

Date: 08.02.2022

- **Objective:**
  - The patient is in the inpatient surgery ward, he is stable.
  - He communicates efficiently.
  - Acromioclavicular joint restricted.
- **Subjective:**
  - Patient feeling: Feeling of knee restriction. Headache has subsided.
  - Pain: 7 out of 10
- **Assessment:**
  - Breathing stereotype is improved, though still slightly upper thoracic dominant.
  - Acromioclavicular joint restricted after testing mobilization.
  - Left patella restriction to lateral direction.
  - Hypertension in pectoral muscles and hip abductors.
- **Objectives of Therapy:**
  - Improve breathing stereotype.
  - Stretching shortened muscles.
  - Reduce restriction of Patella and Acromioclavicular joint.
- **Therapy design:**
  - Respiratory physiotherapy to improve breathing stereotype.
  - PIR of pectoralis major and minor and hip abductors.
  - Joint mobilization of patella and Acromioclavicular joint.
  - Verticalization training to sitting.
- **Procedure:**
  - **Respiratory physiotherapy**
    - As a part of contact breathing, I followed the normal breathing of the patient with an effort to slightly deepen his breath.
    - I then asked him to follow my hands with his breathing and actively inhale and exhale deeper.
    - He then tried to inhale into the lower chest, performing a wave like breathing pattern.
    - After performing a vibration therapy, the patient is instructed to hold the scar.

- **PIR acc Lewit**
    - Bilateral PIR of m. Triceps surae – Patient in supine
    - Bilateral mm. Adductors – Patient in supine
    - Bilateral mm. Pectorales – Patient in supine
- **Joint mobilization**
    - Patella mobilization in laterolateral direction until smoothness of motion is felt.
    - Rhythmic springing of knee joint to achieve mobilization.
    - Acromioclavicular dorsoventral springing.
- **Verticalization to sitting position**
    - Instruction to hold the surgical wound and turn sideways
    - Instruction to push on the bed for support in moving to sitting position.
    - Verticalization to sit over the side was performed without assistance.
    - Massage of back and neck muscles to reduce hypertension.

- **Results:**
    - Breathing quality improved as well as better stereotype.
    - Relaxation of Pectoralis muscles was the most effective.
    - Adductors and Triceps surae less tight and relaxed subjectively according to the patient.
    - Verticalization improved mood and ADL.
    - Pain: 6 out of 10.
- **Self-Therapy:**
    - Continual intentional practice of breathing stereotype and wavelike pattern.
    - Patient can perform verticalization on his own as no assistance from therapist is needed.
    - Scar therapy

Date: 10.02.2022

- **Objective:**
  - The patient is in the inpatient surgery ward, he is stable.
  - He communicates efficiently.
- **Subjective:**
  - Patient feeling: Feeling energetic, he was told he would go home this weekend. Motivated for therapy and to try walking.
  - Pain: 6 out of 10
- **Assessment:**
  - Breathing stereotype is optimal.
  - Patients' status allows him to perform sitting to standing verticalization.
  - Trigger point in short extensors of neck is palpated.
  - Activation of deep stabilisation would benefit patients' recovery.
- **Objectives of Therapy:**
  - Improve deep stabilisation activity.
  - Alleviate trigger points in short extensors of neck.
  - Perform optimal verticalization to sitting and to standing.
  - Attempt walking if able by patient.
  - Relaxation of pectoralis major and minor and hip abductors.
- **Therapy design:**
  - Verticalization to sitting and to standing.
  - Walking training.
  - Trigger point therapy and pressure massage on trigger point.
  - Deep stabilization activation.
  - PIR of pectoralis major and minor and hip abductors.
- **Procedure:**
  - **Verticalization to sitting and standing position**
    - Instruction to hold the surgical wound and turn sideways
    - Instruction to push on the bed for support in moving to sitting position.
    - Verticalization to sit over the side was performed without assistance.
    - Verticalization to a standing position with the help of a therapist.
    - Correct posture of the torso with centration of the head and shoulders.

        - Training of corrected standing according to the methodology of sensorimotor stimulation.
        - Training of the step according to the methodology of sensorimotor stimulation.
        - Balance training - uncorrected standing on one leg.
        - Balance training - deflection by a therapist.
    - **PIR acc Lewit**
        - Bilateral PIR of m. Triceps surae – Patient in supine
        - Bilateral mm. Adductors – Patient in supine
        - Bilateral mm. Pectorales – Patient in supine
    - **Trigger point therapy of short extensors in the neck**
        - Soft tissue technique in the short extensor region
        - Gentle pressure massage on palpated trigger points until release is felt.
        - Active chin retraction – 6 repetitions
    - **Activation of deep stabilisation system**
        - Patient is lying on back with lower limbs bent
        - Performing training to place ribs in caudal direction
        - Activation of the deep stabilization system by breathing
        - Intra-abdominal pressure, breathing and pushing against therapists' fingers.
        - Training in the activation of the lower abdomen and pelvic floor.
    - **Walking training**
        - Walking with assistance, halfway down the hall and back to the bed.
- **Results:**
    - Successful verticalization, to sitting and standing with balance training.
    - Relaxation of Pectoralis muscles, Adductors and Triceps surae was effective.
    - Release of short extensor trigger points and improved cervical flexion stereotype
    - Deep stabilisation caused some discomfort in the abdomen, it was therapeutic.
    - Walking induced fatigue but patients' mood was improved after this activity.
- **Self-Therapy:**
    - Intentionally activate deep stabilisation system and practice breathing.
    - Verticalization to sitting but not standing as may experience vertigo.
    - Active movements, stretching and scar therapy.

3.6 Final Kinesiological examination

Neurological examination

Cranial nerves

Examination of the cranial nerves displayed the same results as the initial kinesiological examination. All nerves function optimally.

Upper limbs examination

- Deep tendon reflexes testing: No pathologies. Negative.

The deep tendon reflexes that were tested are as follows: Biceps brachii (C5-6), Brachioradialis (C5-6) and Triceps brachii (C7-8)

- Paretic signs: No pathologies. Negative.

The paretic signs that were tested are as follows: Mingazzini, Barré, Hanzal and Du Four.

- Spastic-irritative signs: No pathologies. Negative.

The spastic-irritative signs that were tested are as follows: Hoffman, Juster and Tromner.

Lower limbs examination

- Deep reflexes: No pathologies. Negative.

The deep tendon reflexes that were tested are as follows: Patellar (L3 - L4) and Achilles' tendon (S1- S2).

- Paretic signs: No pathologies. Negative.

The paretic signs that were tested are as follows: Barré, Mingazzini.

- Spastic-irritative signs: No pathologies. Negative.

The spastic-irritative signs that were tested are as follows: Babinski, Chaddock, Oppenheim and Rossolimo.

Taxes UE - Finger-Nose-Finger sign

- Right side: Negative
- Left side: Negative

Taxes LE - Heel-to-Shin test

- Right side: Negative
- Left side: Negative

- Lasègue's sign: Negative

Sensation

Superficial and deep sensations are apparent across the body; upper and lower segment display no signs of pathologies.

Musculoskeletal examination

Examination of breath and respiratory stereotype

Performed in standing and sitting as patient could now stand. Breathing is seen to be clearer and display a wave like stereotype, including the upper and lower thoracic as well as slight activation of the abdominal breathing. The breaths are deeper than previously examined. The wave of breathing travels in a proximodistal direction and is laterally symmetrical, there is improved activation of the lower thoracic and abdominal region. The patient has a healthy breathing stereotype.

Soft tissue examination according to Lewit

General soft tissue:

Skin was elastic and freely movable. No sensitive areas apart from the scar. Soft tissue on upper extremities were not restricted. Soft tissue around the chest region had no pathological barrier in any direction. Mobility of the abdomen slightly improved though still restricted due to new scar tissue. Skin of the abdomen area was also slightly warmer due to the scar and stoma.

Fascia examination:

Fascia around the neck is much improved through multiple therapies. Both sides have minimal restriction. Mobility in the areas of the scar and abdominal region is still restricted due to revision of surgery. Fascia in general was not restricted.

Examination of the surgical scar:

The wound is around the right side of the abdomen and is covered by a medical gauze. Due to the stoma and abdominal drains, it was painful to palpate the scar and quite sensitive for the patient. Where the was less pain, therefore able to examine, there was reduced mobility of tissue around the scar in all directions.

Palpation

Muscle tonicity is normal and no signs of hypotonicity is felt in the upper limbs during palpation. overall improvement in visible muscle is observed. Slight hypertonicity of m. quadratus lumborum. Since the patient is right side dominant, he tends to use his right arm for most movements, this may be a reason that when palpated, his right arm tended to be more hypertonic. Epicondyles of both humerus' displayed decreased tone.

The lower limbs still exhibit signs of slight hypertonicity, when compared with each other, the right displays a relatively higher tone compared to the left. This is possibly due to the skiing accident and previously broken tibia/ fibula.

Pelvis palpation

Frontal plane:

- Pelvis is equal on both sides

Sagittal plane:

- Pelvis in slight anteversion

Transverse plane:

- No rotation present.

Postural evaluation

The patient was able to stand, posture was examined in sitting and standing. Slight lumbar kyphosis was present as it was painful in the abdominal area (scar region) when he tried to do lumbar lordosis.

Upper thoracic region of the spine from the lateral view showed a high degree of kyphosis. Specifically, in the T4-T7 area.

The cervical spine follows the natural ‘S’ curve and has no shift or rotation of any kind. In standing, cervical spine was kyphotic as patient found it difficult to stand in correct posture.

The head of the patient is in a physiological position and does not tilt or shift to any side.

Specific posture testing

Two-scale test: Negative.

Romberg test: Negative.

Trendelenburg test: Could not be performed as patient cannot lift one leg.

Véle's test: Negative.

Modification of standing

Standing on toes: Positive, patient cannot stand on toes.

Standing on heels: Positive, patient cannot stand on heels.

Standing on one leg: Positive, patient cannot stand on one leg.

Gait analysis

Patient is unable to walk without assistance, a walker is given under his current circumstances. Rest is advised as he requires time to heal and regain energy.

Janda's movement stereotypes

Shoulder abduction

Patient could perform shoulder abduction with no pathological signs. All muscles worked in a synchronised pattern. No pain at any point in the range of motion for either upper extremity. No compensatory muscles were involved. Both the concentric and eccentric part of the movement were done at the same speed and with the same smoothness and quality.

Cervical flexion

Though the movement was done slowly, it was performed correctly. The reason it was performed slowly was because the patient was fatigued after moving into the sitting position from resting in supine after surgical interventions. There was no sign of SCM domination, and all muscle worked synchronously.

Hip abduction

The stereotype was performed with a high degree of accuracy. The quadratus mechanism was not displayed which means there was no elevation of the pelvis. However, on the eccentric movement the patient did have to support himself as he was not able to keep stable.

Joint play examination (Lewit)

Muscle	*Direction*	*L*	*R*
Head of Fibula	Dorsal	No restriction	Restriction
	Ventral	No restriction	No restriction
Tibiofibular joint	External rotation	No restriction	Restriction
	Internal rotation	No restriction	No restriction
Patella	Lateral	No restriction	No restriction
	Medial	No restriction	No restriction
	Cranial	No restriction	No restriction
	Caudal	No restriction	No restriction
Talocrural joint	Springing	No restriction	Restriction
Lisfranc joint	Rotational	No restriction	No restriction
	Dorsal	No restriction	No restriction
	Plantar	No restriction	No restriction
Sacro-iliac joint	Springing	No restriction	No restriction
Wrist	Palmar shift	Restriction	No restriction
	Dorsal shift	No restriction	No restriction
Acromioclavicular	Craniocaudally	No restriction	No restriction
	Ventrodorsally	No restriction	No restriction
Knee	Lateral gapping	No restriction	No restriction

Table 8: Final joint play examination according to Lewit.

Anthropometric measurements

LEE			***L***	***R***
Length (cm)	Anatomical		85	83
	Functional		91	89
	Upper leg		40	40
	Lower leg		45	43
	Heel		34	33
	MTP		24	24
Circumference (cm)	Knee	Superior patellar apex	45	44
		Patellar	45	46
		Inferior patellar apex	36	35
	Calf		37	35
	Quadriceps		46	45
	Ankle	Malleolar	26	25
		Calcaneal	36	35

Table 9: Final anthropometric measurements of lower limbs.

UEE		***L***	***R***
Length (cm)	Arm	76	76
	Upper arm	34	34
	Lower arm	43	43
	Wrist	18	19
	MCP	24	25
	Head	58	

Table 10: Final anthropometric measurements of upper limbs.

Muscle Strength test (According to Janda)

		L	***R***
Hip	Extensors	4	4
	Flexors	4	4
	Abductors	4	4
	Adductors	4	4
Shoulder	Extensors	5	5
	Flexors	4	4
	Abductors	4	4
	Adductors	4	4
Elbow	Extensors	3	3
	Flexors	4	4
Fingers	Extensors	4	5
	Flexors (longus)	3	4

Table 11: Final muscle strength test according to Janda.

Passive RoM measurements

PRoM		***L***			***R***		
Shoulder	S:	15	0	180	20	0	180
	F:	120	0	0	115	0	0
	T:	45	0	120	45	0	125
	R:	45	0	75	50	0	75
Elbow	S:	0	0	145	0	0	145
Wrist	S:	70	0	75	65	0	75
	F:	20	0	25	20	0	20
Hip	S:	20	0	120	20	0	125
	F:	30	0	35	35	0	30
	R:	55	0	10	55	0	10
C spine	S:	45		0		40	
	F:	40		0		45	
	R:	55		0		55	

Table 12: Final passive range of motion measurements.

Active RoM measurements

ARoM		***L***			***R***		
Shoulder	S:	15	0	175	15	0	175
	F:	115	0	0	110	0	0
	T:	35	0	115	40	0	120
	R:	45	0	65	40	0	70
Elbow	S:	0	0	145	0	0	145
Wrist	S:	50	0	75	55	0	70
	F:	15	0	25	15	0	20
Hip	S:	10	0	115	10	0	115
	F:	20	0	30	20	0	30
	R:	50	0	10	50	0	10
C spine	S:	40		0		40	
	F:	40		0		45	
	R:	55		0		60	

Table 13: Final active range of motion measurements.

Muscle length examination (Janda and Kendall methodology)

Muscles	***L***	***R***
Hip adductors	1	1
Hip abductors	1	0
Hamstrings	0	1
Pectoralis Major	0	0
Pectoralis Minor	0	0
Levator scapulae	0	0
Cranial Trapezius	0	0
SCM	1	0
Piriformis	1	1
Triceps surae	1	1

Table 14: Final muscle length measurements.

3.7 Evaluation of the effect of therapy

The effectiveness of the therapy can first be evaluated by the palpation of muscles. Previously, in the initial examination, a high degree of hypotonicity was felt in the upper limbs. Through the therapies, it can now be palpated, and a normal tonicity is felt. The results also display an improvement in overall muscle strength. The epicondyles of both humerus' have also decreased in tone.

The lower limbs still exhibit signs of slight hypertonicity, when compared with each other, the gastrocnemius on the right displays a relatively higher tone compared to the left. This is possibly due to the skiing accident and previously broken tibia/ fibula. Hypertonicity in the left quadratus lumborum was reduced but the patient needed reminding to maintain correction to reduce tonicity.

Furthermore, even with the aid of crutches, the patients standing posture had a significant improvement in stability and balance throughout the stages of 'sitting to standing' therapy. There was slow progress into the walking stages as the patient was gradually increasing confidence in himself.

As a standard practice in IKEM, respiratory physiotherapy has been proven quite useful for the patient. It has managed to improve the breathing stereotype as well as maintain a healthy respiration rate. The wave of breathing travels smoothly through the chest and abdomen and there is improved activation of the lower thoracic region.

Final joint play examination revealed that an overall improvement in mobility was present in both lower extremities. The most improvement was seen in the right lower extremity, mostly due to the fact that there was more restriction on this extremity due to the patient's skiing accident and lack of continual rehabilitation thereafter. Acromioclavicular joint displayed no restriction ventrodorsally as evidently springing therapy improved mobility.

A standout improvement was seen in the range of motion of the shoulder. The range of motion improved bilaterally in the flexion, abduction, and rotational movements. Moreover, the patient also mentioned a subjective feeling of increase in his range of motion, motivating him to continue self-therapy with enthusiasm.

Muscle strength was greatly improved especially in the case of the shoulder extensors and abductors paired interdependently with the increase in range of motion. Another viable strength

gain was noticed in the hip abductors, extensors, and flexors. This demonstrates the success and effectiveness of the therapy.

Anthropometric measurements performed at the final examination revealed an increase in circumference of the quadriceps which pair effectively with the strength increase in the same area. The noted increase was from 44cm for the left limb and 43cm for the right limb, to 46cm and 45cm respectively.

The shortness of muscles such as the pectoralis major and minor, as well as hip adductors, piriformis, and triceps surae was not apparent in the final examination. In other muscles, the palpable hypertonus was reduced, but according to Janda, the degree of shortening remained the same.

Soft tissue around the scar was still generally tough and restricted as expected, this is also owed to the fact that the patient had multiple revision surgeries which would increase the healing time for the hypertensive fascia around the abdomen and scar. Palpation of this area was still painful to the touch. Furthermore, soft tissue techniques have been used to reduce the hypertension in the neck fascia and restore its mobility.

According to Barthel, the patient achieved a score of 80 compared to an initial 75 improving in the mobility section.

4 Personal conclusion

In the lengthy process of writing the bachelors thesis, I have been exposed to invaluable information which has broadened my perspective of physiotherapy. The theoretical segment of the thesis has been eye-opening. Learning about Ileostomy surgery and carcinomas will help me adapt my physiotherapeutic approach to surgical patients in the future.

The experience at IKEM has taught me that it is very important to put yourself in the patients' shoes when providing therapy. Essentially, being empathetic will allow you to modify your therapy to best suit the current condition of the patient and allow for a smooth recovery.

I am grateful to have been given the opportunity to apply my knowledge and skills through this internship. I am satisfied with the outcome of my therapy; the patient was appreciative and despite his unfortunate circumstances kept a delightful smile on his face.

5 Bibliography

Abcarian, H., & Pearl, R. K. (1988). Stomas. *Surgical Clinics of North America*, *68*, 1295–1305. https://doi.org/10.1016/s0039-6109(16)44687-6

Akhan, S. E., & Baysal, B. (2002). Laparotomy or laparoscopic surgery? *Archives of Gynecology and Obstetrics*, *266*(2), 79–82. https://doi.org/10.1007/s004040100198

Anastomotic Leak: Symptoms, Treatment & What It Is. (2022, March 2). Cleveland Clinic. https://my.clevelandclinic.org/health/diseases/22324-anastomotic-leak

Atallah, S., Albert, M., & Larach, S. (2011). Technique for constructing an incisionless laparoscopic stoma. *Techniques in Coloproctology*, *15*(3), 345–347. https://doi.org/10.1007/s10151-011-0698-0

Baraza, W., Wild, J., Barber, W., & Brown, S. (2010). Postoperative management after loop ileostomy closure: are we keeping patients in hospital too long? *The Annals of the Royal College of Surgeons of England*, *92*, 51–55. https://doi.org/10.1308/003588410x12518836439209

Batko, S. (2017). Anti-EGFR therapy in colorectal carcinoma. *Onkologie*, *11*, 66–71. https://doi.org/10.36290/xon.2017.014

Bernstein, S. (2021, August 31). *What is Adenocarcinoma?* WebMD. https://www.webmd.com/cancer/what-is-adenocarcinoma

Brand, M. I., & Dujovny, N. (2002). Preoperative Considerations and Creation of Normal Ostomies. *Clinics in Colon and Rectal Surgery*, *15*(3), 173–182. https://doi.org/10.1055/s-2002-34085

Brand, M., & Dujovny, N. (2008a). Preoperative Considerations and Creation of Normal Ostomies. *Clinics in Colon and Rectal Surgery*, *21*(1), 005-016. https://doi.org/10.1055/s-2008-1055316

Brand, M., & Dujovny, N. (2008b). Preoperative considerations and creation of normal ostomies. *Clinics in Colon and Rectal Surgery*, *21*, 005-016. https://doi.org/10.1055/s-2008-1055316

Burch, J. (2017). Preoperative care of patients undergoing stoma formation: what the nurse needs to know. *Nursing Standard*, *31*, 40–43. https://doi.org/10.7748/ns.2017.e10161

Cafasso, J. (2018, February 12). *Anastomosis: Definition, Techniques, Types, and Risks*. Healthline. https://www.healthline.com/health/anastomosis#anastomotic-leak

Camacho-Mauries, D., Rodriguez-Díaz, José Luis, Salgado-Nesme, N., González, Quintín H, & Vergara-Fernández, O. (2013). Randomized clinical trial of intestinal ostomy

takedown comparing pursestring wound closure vs conventional closure to eliminate the risk of wound infection. *Diseases of the Colon & Rectum*, *56*, 205–211. https://doi.org/10.1097/dcr.0b013e31827888f6

Chudner, A., Gachabayov, M., Dyatlov, A., Lee, H., Essani, R., & Bergamaschi, R. (2019). The influence of diverting loop ileostomy vs. colostomy on postoperative morbidity in restorative anterior resection for rectal cancer: a systematic review and meta-analysis. *Langenbeck's Archives of Surgery*, *404*(2), 129–139. https://doi.org/10.1007/s00423-019-01758-1

Chun, C. (2019, January 25). *Adenocarcinoma Symptoms: Breast, Colorectal, Lung, & Prostate*. Healthline. https://www.healthline.com/health/cancer/adenocarcinoma-symptoms#diagnosis

Cleveland Clinic. (2021, August 12). *Small Intestine: Function, anatomy & Definition*. Cleveland Clinic. https://my.clevelandclinic.org/health/body/22135-small-intestine

Colorectal (Colon) Cancer. (2020, April 22). Cleveland Clinic. https://my.clevelandclinic.org/health/diseases/14501-colorectal-colon-cancer

Cottam, J., Richards, K., Hasted, A., & Blackman, A. (2007). Results of a nationwide prospective audit of stoma complications within 3 weeks of surgery. *Colorectal Disease*, *9*(9), 834–838. https://doi.org/10.1111/j.1463-1318.2007.01213.x

Dahly, E. M., Gillingham, M. B., Guo, Z., Murali, S. G., Nelson, D. W., Holst, J. J., & Ney, D. M. (2003). Role of luminal nutrients and endogenous GLP-2 in intestinal adaptation to mid-small bowel resection. *American Journal of Physiology-Gastrointestinal and Liver Physiology*, *284*(4), G670–G682. https://doi.org/10.1152/ajpgi.00293.2002

Dušek, L., Abrahámová, J., Bortlíček, Z., Brabec, P., Fínek, J., Gregor, J., Hoch, J., Klimeš, D., Koptíková, J., Kožený, P., Májek, O., Malúšková, D., Mužík, J., Pavlík, T., Poc, P., Ryska, M., Seifert, B., Slavíček, L., Suchánek, Š., & Tomášek, J. (2012). Epidemiologie, prevence a léčba kolorektálního karcinomu dle dostupných českých a mezinárodních dat. In *repozitar.cz*. Fakultní nemocnice v Motole. https://repozitar.cz/publication/15544/cs/Epidemiologie-prevence-a-lecba-

Fitzmaurice, C. (2018). Global, regional, and national cancer incidence, mortality, years of life lost, years lived with disability, and disability-adjusted life-years for 29 cancer groups, 2006 to 2016: A systematic analysis for the Global Burden of Disease study. *Journal of Clinical Oncology*, *36*(15_suppl), 1568–1568. https://doi.org/10.1200/jco.2018.36.15_suppl.1568

G, T. S. (1994). Systematic Review: Why sources of heterogeneity in meta-analysis should be investigated. *BMJ*, *309*, 1351–1355. https://doi.org/10.1136/bmj.309.6965.1351

Gavriilidis, P., Azoulay, D., & Taflampas, P. (2018). Loop transverse colostomy versus loop ileostomy for defunctioning of colorectal anastomosis: a systematic review, updated conventional meta-analysis, and cumulative meta-analysis. *Surgery Today*. https://doi.org/10.1007/s00595-018-1708-x

Geng, H. Z., Nasier, D., Liu, B., Gao, H., & Xu, Y. K. (2015). Meta-analysis of elective surgical complications related to defunctioning loop ileostomy compared with loop colostomy after low anterior resection for rectal carcinoma. *The Annals of the Royal College of Surgeons of England*, *97*, 494–501. https://doi.org/10.1308/003588415x14181254789240

Grady, W. M., & Markowitz, S. D. (2014). The Molecular Pathogenesis of Colorectal Cancer and Its Potential Application to Colorectal Cancer Screening. *Digestive Diseases and Sciences*, *60*(3), 762–772. https://doi.org/10.1007/s10620-014-3444-4

Harris, R. J., Deeks, J. J., Altman, D. G., Bradburn, M. J., Harbord, R. M., & Jonathan. (2008). Metan: Fixed- and random-effects meta-analysis. *The Stata Journal: Promoting Communications on Statistics and Stata*, *8*, 3–28. https://doi.org/10.1177/1536867x0800800102

Hendren, S., Hammond, K., Glasgow, S. C., Perry, W. B., Buie, W. D., Steele, S. R., & Rafferty, J. (2015). Clinical Practice Guidelines for Ostomy Surgery. *Diseases of the Colon & Rectum*, *58*(4), 375–387. https://doi.org/10.1097/dcr.0000000000000347

Hill, G. L., & MYERS, R. T. (1976). Ileostomy. *Annals of Surgery*, *184*, 651. https://doi.org/10.1097/00000658-197611000-00023

Horvat, N., Carlos Tavares Rocha, C., Clemente Oliveira, B., Petkovska, I., & Gollub, M. J. (2019). MRI of Rectal Cancer: Tumor Staging, Imaging Techniques, and Management. *RadioGraphics*, *39*(2), 367–387. https://doi.org/10.1148/rg.2019180114

Hub, K. (2022, March 3). *Large intestine*. Kenhub. https://www.kenhub.com/en/library/anatomy/large-intestine

Idris,. (2012). A comparison of methods to detect publication bias for meta-analysis of continuous data. *Journal of Applied Sciences*, *12*, 1413–1417. https://doi.org/10.3923/jas.2012.1413.1417

Ileostomy - recovery. (2018, October). Nhs.uk. https://www.nhs.uk/conditions/ileostomy/recovery/#:~:text=After%20an%20ileostomy%20procedure%2C%20you

Islami, F., Ward, E. M., Sung, H., Cronin, K. A., Tangka, F. K. L., Sherman, R. L., Zhao, J., Anderson, R. N., Henley, S. J., Yabroff, K. R., Jemal, A., & Benard, V. B. (2021). Annual Report to the Nation on the Status of Cancer, Part 1: National Cancer Statistics. *JNCI: Journal of the National Cancer Institute*, *1*(1). https://doi.org/10.1093/jnci/djab131

Jemal, A., Siegel, R., Xu, J., & Ward, E. (2010). Cancer Statistics, 2010. *CA: A Cancer Journal for Clinicians*, *60*(5), 277–300. https://doi.org/10.3322/caac.20073

Jiří Vorlíček, Jitka Abrahámová, & VorlíčkováH. (2006). *Klinická onkologie pro sestry*. Grada.

Justiniano, C. F., Temple, L. K., Swanger, A. A., Xu, Z., Speranza, J. R., Cellini, C., Salloum, R. M., & Fleming, F. J. (2018). Readmissions with dehydration after Ileostomy Creation: Rethinking Risk Factors. *Diseases of the Colon and Rectum*, *61*(11), 1297–1305. https://doi.org/10.1097/DCR.0000000000001137

Kuipers, E. J., & Spaander, M. C. W. (2015). Colorectal Cancer Screening by Colonoscopy, CT-Colonography, or Fecal Immunochemical Test. *Journal of the National Cancer Institute*, *108*(2), djv383. https://doi.org/10.1093/jnci/djv383

Leoš Navrátil. (2019). *Fyzikální léčebné metody pro praxi*. Grada Publishing.

Lertsithichai, P., & Rattanapichart, P. (2004). Temporary ileostomy versus temporary colostomy: A meta-analysis of complications. *Asian Journal of Surgery*, *27*, 202–210. https://doi.org/10.1016/s1015-9584(09)60033-6

Li, Z., & Begg, C. B. (1994). Random effects models for combining results from controlled and uncontrolled studies in a meta-analysis. *Journal of the American Statistical Association*, *89*, 1523–1527. https://doi.org/10.1080/01621459.1994.10476892

Liu, Z., Wang, G., Yang, M., Chen, Y., Miao, D., Muhammad, S., & Wang, X. (2014). Ileocolonic anastomosis after right hemicolectomy for colon cancer: functional end-to-end or end-to-side? *World Journal of Surgical Oncology*, *12*(1), 306. https://doi.org/10.1186/1477-7819-12-306

Lublin, M. (2018). *Colostomy/Ileostomy care post-op instructions*. Www.drmatthewlublin.com. https://www.drmatthewlublin.com/contents/about/post-op-instructions/colostomyileostomy-care-post-op-instructions

Maurie Markman. (2019, May 21). *Colorectal Cancer*. Cancer Treatment Centers of America. https://www.cancercenter.com/cancer-types/colorectal-cancer/risk-factors

Mckenzie, S. (2018, October 8). *Colorectal Cancer Pathogenesis*. News-Medical.net. https://www.news-medical.net/health/Colorectal-Cancer-Pathogenesis.aspx

Meaume, S., Pillouer-Prost, L., Richert, B., Roseeuw, D., & Vadoud, J. (2014). Management of scars: updated practical guidelines and use of silicones. *European Journal of Dermatology : EJD*, *24*, 435–443. https://doi.org/10.1684/ejd.2014.2356

Miloš Máček, & Libuše Smolíková. (1995). *Pohybová léčba u plicních chorob : respirační fyzioterapie*. Victoria Publishing.

Moher, D., Liberati, A., Tetzlaff, J., Altman, D. G., & The PRISMA Group. (2009). Preferred reporting items for systematic reviews and meta-analyses: the PRISMA statement. *PLoS Medicine*, *6*, e1000097. https://doi.org/10.1371/journal.pmed.1000097

MüllerI., & Bohuslava Müllerová. (1992). *Stručný přehled léčebné tělesné výchovy v chirurgii, ortopedii a traumatologii : Učeb. text.* Inst. Pro Další Vzdělávání Prac. Ve Zdrav.

Murray, B. W., Cipher, Daisha J, Pham, T., & Anthony, T. (2011). The impact of surgical site infection on the development of incisional hernia and small bowel obstruction in colorectal surgery. *The American Journal of Surgery*, *202*, 558–560. https://doi.org/10.1016/j.amjsurg.2011.06.014

Murrell, Z., & Stamos, M. (2006). Reoperation for Anastomotic Failure. *Clinics in Colon and Rectal Surgery*, *19*(4), 213–216. https://doi.org/10.1055/s-2006-956442

Netter, F. H. (2019). *Atlas of human anatomy* (7th ed.). Elsevier.

Nikaki, K., & Gupte, G. L. (2016). Assessment of intestinal malabsorption. *Best Practice & Research Clinical Gastroenterology*, *30*(2), 225–235. https://doi.org/10.1016/j.bpg.2016.03.003

Nursing Times. (2019, August 19). *Gastrointestinal tract 4: anatomy and role of the jejunum and ileum | Nursing Times*. Nursing Times. https://www.nursingtimes.net/clinical-archive/gastroenterology/gastrointestinal-tract-4-anatomy-role-jejunum-ileum-19-08-2019/

P, M. D., P, B. J., R, W. S., & C, C. J. (2013). Purse-string approximation is superior to primary skin closure following stoma reversal: a systematic review and meta-analysis. *Techniques in Coloproctology*, *17*, 345–351. https://doi.org/10.1007/s10151-012-0970-y

Paquette, I. M., Solan, P., Rafferty, J. F., Ferguson, M. A., & Davis, B. R. (2013). Readmission for Dehydration or Renal Failure After Ileostomy Creation. *Diseases of the Colon & Rectum*, *56*(8), 974–979. https://doi.org/10.1097/dcr.0b013e31828d02ba

Patel, B. K., & Hall, J. B. (2013). Perioperative physiotherapy. *Current Opinion in Anaesthesiology*, *26*, 152–156. https://doi.org/10.1097/aco.0b013e32835e8b34

Pavel Kolář, Andelova, V., & Al, E. (2013). *Clinical rehabilitation*. Rehabilitation Prague School.

Pisarska, M., Gajewska, N., Małczak, P., Wysocki, M., Witowski, J., Torbicz, G., Major, P., Mizera, M., Dembiński, M., Migaczewski, M., Budzyński, A., & Pędziwiatr, M. (2018). Defunctioning ileostomy reduces leakage rate in rectal cancer surgery - systematic review and meta-analysis. *Oncotarget*, *9*(29), 20816–20825. https://doi.org/10.18632/oncotarget.25015

Prieto, M. L., Casanova, A., Delgado, J., & Zabalza, R. (1989). Cystic teratoma of the mesentery. *Pediatric Radiology*, *19*(6-7), 439–439. https://doi.org/10.1007/bf02387647

Rajaretnam, N., & Lieske, B. (2022). *Ileostomy*. PubMed; StatPearls Publishing. https://pubmed.ncbi.nlm.nih.gov/30085545/

Reddy, V. B., & Longo, W. E. (2019). Ileostomy. *Shackelford's Surgery of the Alimentary Tract, 2 Volume Set*, *2*, 991–1004. https://doi.org/10.1016/b978-0-323-40232-3.00084-4

Reeve, J., Anderson, L., Raslan, Y., Grieve, C., Ford, J., & Wilson, L. (2019). The physiotherapy management of patients undergoing abdominal surgery: A survey of current practice. *New Zealand Journal of Physiotherapy*, *47*(2), 66–75. https://doi.org/10.15619/nzjp/47.2.02

Rondelli, F., Reboldi, P., Rulli, A., Barberini, F., Guerrisi, A., Izzo, L., Bolognese, A., Covarelli, P., Boselli, C., Becattini, C., & Noya, G. (2009b). Loop ileostomy versus loop colostomy for fecal diversion after colorectal or coloanal anastomosis: a meta-analysis. *International Journal of Colorectal Disease*, *24*(5), 479–488. https://doi.org/10.1007/s00384-009-0662-x

Rullier, E., Toux, L., Laurent, C., Garrelon, J.-L., Parneix, M., & Saric, J. (2001). Loop ileostomy versus loop colostomy for defunctioning low anastomoses during rectal cancer surgery. *World Journal of Surgery*, *25*, 274–278. https://doi.org/10.1007/s002680020091

S, N. (2017, October 19). *Ileostomy - Complications*. Nhs.uk. https://www.nhs.uk/conditions/ileostomy/risks/

S, S. M., I, B. M., & F, M. W. (2014). Systematic review and meta-analysis of published randomized controlled trials comparing purse-string vs conventional linear closure of the wound following ileostomy (stoma) closure. *Gastroenterology Report*, *3*, 156–161. https://doi.org/10.1093/gastro/gou038

S, W. N., G, N. D., Jones, D., & H, S. A. (1986). De-functioning stomas: A prospective controlled trial comparing loop ileostomy with loop transverse colostomy. *British Journal of Surgery*, *73*, 566–570. https://doi.org/10.1002/bjs.1800730717

Salum, M., Wexner, S. D., Nogueras, J. J., Weiss, E., Koruda, M., Behrens, K., Cohen, S., Binderow, S., Cohen, J., Thorson, A., Ternent, C., Christenson, M., Blatchford, G., Pricolo, V., Whitehead, M., Doveney, K., Reilly, J., Glennon, E., Larach, S., & Williamson, P. (2006). Does sodium hyaluronate- and carboxymethylcellulose-based bioresorbable membrane (Seprafilm) decrease operative time for loop ileostomy closure? *Techniques in Coloproctology*, *10*(3), 187–191. https://doi.org/10.1007/s10151-006-0278-x

SHACKLEFORD, R. T. (1976). Operative Anatomy of Abdomen and Pelvis. *Archives of Surgery*, *111*(7), 834. https://doi.org/10.1001/archsurg.1976.01360250110034

Shah, A., Moftah, M., Hadi Nahar Al-Furaji, H., & Cahill, R. A. (2014). Standardized technique for single port laparoscopic ileostomy and colostomy. *Colorectal Disease*, *16*(7), O248–O252. https://doi.org/10.1111/codi.12601

Siegel, R. L., Miller, K. D., Fuchs, H. E., & Jemal, A. (2022). Cancer statistics, 2022. *CA: A Cancer Journal for Clinicians*, *72*(1). https://doi.org/10.3322/caac.21708

Stang, A. (2010). Critical evaluation of the Newcastle-Ottawa scale for the assessment of the quality of nonrandomized studies in meta-analyses. *European Journal of Epidemiology*, *25*, 603–605. https://doi.org/10.1007/s10654-010-9491-z

Sterne, Egger, M., & D, S. G. (2001). Systematic reviews in health care: Investigating and dealing with publication and other biases in meta-analysis. *BMJ*, *323*, 101–105. https://doi.org/10.1136/bmj.323.7304.101

T, L. L., C, H. S., A, D. J., S, K. L., L, B. R., A, A. N., & K, L. M. (2014). Circular closure is associated with the lowest rate of surgical site infection following stoma reversal: a systematic review and multiple treatment meta-analysis. *Colorectal Disease*, *16*, 406–416. https://doi.org/10.1111/codi.12556

Tang, C.-L., Seow-Choen, F., Fook-Chong, S., & Eu, K.-W. (2003). Bioresorbable Adhesion Barrier Facilitates Early Closure of the Defunctioning Ileostomy After Rectal Excision. *Diseases of the Colon & Rectum*, *46*(9), 1200–1207. https://doi.org/10.1007/s10350-004-6716-9

Thanikachalam, K., & Khan, G. (2019). Colorectal Cancer and Nutrition. *Nutrients*, *11*(1), 164. https://doi.org/10.3390/nu11010164

Tilney, H. S., Sains, P. S., Lovegrove, R. E., Reese, G. E., Heriot, A. G., & Tekkis, P. P. (2007). Comparison of outcomes following ileostomy versus colostomy for defunctioning colorectal anastomoses. *World Journal of Surgery*, *31*, 1143–1152. https://doi.org/10.1007/s00268-006-0218-y

Troisi, R. J., Freedman, A. N., & Devesa, S. S. (1999). Incidence of colorectal carcinoma in the U.S. *Cancer*, *85*(8), 1670–1676. https://doi.org/10.1002/(sici)1097-0142(19990415)85:8<1670::aid-cncr5>3.0.co;2-m

VÉLE, F. (2006). *Kineziologie: přehled klinické kineziologie a patokineziologie pro diagnostiku a terapii poruch pohybové soustavy. 2.* Praha: Triton, 2006.

Veljkovic, R., Protic, M., Gluhovic, A., Potic, Z., Milosevic, Z., & Stojadinovic, A. (2010). Prospective clinical trial of factors predicting the early development of incisional hernia after midline laparotomy. *Journal of the American College of Surgeons*, *210*, 210–219. https://doi.org/10.1016/j.jamcollsurg.2009.10.013

Yeo, C. J. (2019). *Shackelford's surgery of the alimentary tract*. Elsevier.

6 Annex

Application approval by UK FTVS Ethics committee

CHARLES UNIVERSITY
FACULTY OF PHYSICAL EDUCATION AND SPORT
José Martího 31, 162 52 Prague 6-Veleslavín

Application for Approval by UK FTVS Ethics Committee

of a research project, thesis, dissertation, or seminar work involving human subjects

The title of a project: Case study physiotherapy case study with Ileostomy

Project form: Bachelor Thesis

Period of realization of the project: January 2022 - February 2022

The research will be carried out in accordance with the valid epidemiological measures of the Ministry of Health of the Czech Republic.

Applicant: Muhammad Jessa, UK FTVS Department of Physiotherapy

Main researcher: Muhammad Jessa, UK FTVS Department of Physiotherapy

Workplace: Institut Klinické a Experimentální Medicíny (IKEM)

Co-researcher(s): None

Supervisor: Mgr. Kristina Chroustová

Financial support: No financial support

Project description: Writing the bachelor's thesis based on my patient diagnoses. My patient has undergone the operation of Ileostomy. The methods that will be used throughout the patient's therapy will include soft tissue techniques (myofascial release), respiratory therapy, passive & active motion, and conditioning training.

Characteristics of participants in the research: For my bachelor, there is one patient whose condition (Ileostomy) I will treat. My patient is an 80-year-old male. He has a VAC system due to enteric leakage and anastomosis. Other than that, my patient does not currently suffer from any illnesses other than the one I will treat. He is a patient that has been assigned to me in Institut Klinické a Experimentální Medicíny (IKEM), which is a work placement for my bachelor's practice. Patients with acute (especially infectious) diseases do not participate in therapy.

Ensuring safety within the research: Only non-invasive methods will be used. All techniques that will be used are not dangerous for the safety and health of the patient. Furthermore, I will have my supervisor (Bc. Robert Charvát) present to always oversee me. Risks of therapy and methods will not be higher than the commonly anticipated risks for this type of therapy.

Ethical aspects of the research: Data will be collected in line with the rules given by European Union no. 2016/679 and the Czech Act no. 110/2019 Coll. – on personal data processing.
The collected data will be anonymized within one week after the end of working with the patient. I understand that anonymization means that the text does not use any item of information or combination of Items that could lead to the identification of a person. I will be careful not to enable recognition of a person in the text of the thesis, especially within the anamnesis. After the text has been anonymized, any personal data still kept elsewhere will be deleted.
Photographs of the participant will be anonymized within one week after being taken by blurring the face, parts of the body or any characteristics that could lead to identification of the person. After anonymization any non-anonymized photographs will be deleted.
All collected data will be safely stored on a PC safeguarded by a keyword in a locked room, any data in paper form will be kept safely under lock and key in a locked room. The data will be processed, safely retained and published in an anonymous way in the bachelor thesis.
Photographs: Photographs of the participant will be anonymized within one week after being taken by blurring the face, parts of the body or any characteristics that could lead to identification of the person. After anonymization any non-anonymized photographs will be deleted.
All collected data will be safely stored on a PC safeguarded by a keyword in a locked room, any data in paper form will be kept safely under lock and key in a locked room. The data will be processed, safely retained and published in an anonymous way in the bachelor thesis.
I shall ensure to the maximum extent possible that the research data will not be misused.
Informed Consent: Attached

It is the duty of **all participants of the research team** to protect life, health, dignity, integrity, the right to self-determination, privacy and protection of the personal data of all research subjects, and to undertake all possible precautions.

CHARLES UNIVERSITY
FACULTY OF PHYSICAL EDUCATION AND SPORT
José Martího 31, 162 52 Prague 6-Veleslavín

Responsibility for the protection of all research subjects lies on the researcher(s) and not on the research subjects themselves, even if they gave their consent to participation in the research. All participants of the research team must take into consideration ethical, legal and regulative norms and standards of research involving human subjects applicable not only in the Czech Republic but also internationally.
I confirm that this project description corresponds to the plan of the project and, in case of any change, especially of the methods used in the project, I will inform the UK FTVS Ethics Committee, which may require a re-submission of the application form.

In Prague, 18/01/2022

Applicant's signature:

Approval of UK FTVS Ethics Committee

The Committee: Chair: Doc. PhDr. Irena Parry Martínková, Ph.D.
Members: Prof. PhDr. Pavel Slepička, DrSc. Prof. MUDr. Jan Heller, CSc.
PhDr. Pavel Hráský, Ph.D. Mgr. Eva Prokešová, Ph.D.
Mgr. Tomáš Ruda, Ph.D. MUDr. Simona Majorová

The research project was approved by UK FTVS Ethics Committee under the registration number: 106/2022
Date of approval: 13.1.2022

UK FTVS Ethics Committee reviewed the submitted research project and **found no contradictions** with valid principles, regulations, and international guidelines for carrying out research involving human subjects.

The applicant has met the necessary requirements for receiving approval of UK FTVS Ethics Committee.

UNIVERZITA KARLOVA
Fakulta tělesné výchovy a sportu
José Martího 31, 162 52, Praha 6
– 20 –

Stamp of UK FTVS

Signature of the Chair of
UK FTVS Ethics Committee

Informed Consent Form

UNIVERZITA KARLOVA
FAKULTA TĚLESNÉ VÝCHOVY A SPORTU
José Martího 31, 162 52 Praha 6-Veleslavín

INFORMOVANÝ SOUHLAS

Vážená paní, vážený pane,

v souladu se Všeobecnou deklarací lidských práv, nařízením Evropské Unie č. 2016/679 a zákonem č. 110/2019 Sb. – o zpracování osobních údajů, Helsinskou deklarací, přijatou 18. Světovým zdravotnickým shromážděním v roce 1964 ve znění pozdějších změn (Fortaleza, Brazílie, 2013) a dalšími obecně závaznými právními předpisy Vás žádám o souhlas s prezentováním a uveřejněním výsledků vyšetření a průběhu terapie prováděné v rámci praxe na IKEM, kde Vás příslušně kvalifikovaná osoba seznámila s Vaším vyšetřením a následnou terapií. Výsledky Vašeho vyšetření a průběh Vaší terapie bude publikován v rámci bakalářské práce na UK FTVS, s názvem ……

Cílem této bakalářské práce je ..seznámení se s teoretickými a praktickými poznatky výše zmíněné diagnózy, zdokumentování průběhu terapie a rekonvalescence pacienta.
Získané údaje, fotodokumentace, průběh a výsledky terapie budou uveřejněny v bakalářské práci v anonymizované podobě. Osobní data nebudou uvedena a budou uchována v anonymní podobě. V maximální možné míře zabezpečím, aby získaná data nebyla zneužita.

Jméno a příjmení řešitele Muhammad Jessa ..... Podpis: .....

Prohlašuji a svým níže uvedeným vlastnoručním podpisem potvrzuji, že dobrovolně souhlasím s prezentováním a uveřejněním výsledků vyšetření a průběhu terapie ve výše uvedené bakalářské práci, a že mi osoba, která provedla poučení, osobně vše podrobně vysvětlila, a že jsem měl(a) možnost si řádně a v dostatečném čase zvážit všechny relevantní informace, zeptat se na vše podstatné a že jsem dostal(a) jasné a srozumitelné odpovědi na své dotazy. Byl(a) jsem poučen(a) o právu odmítnout prezentování a uveřejnění výsledků vyšetření a průběhu terapie v bakalářské práci nebo svůj souhlas kdykoli odvolat bez represí, a to písemně zasláním Etické komisi UK FTVS, která bude následně informovat řešitele.

Místo, datum Prague, 24.01.2022

Jméno a příjmení pacienta Jiří Stránský ..... Podpis pacienta: .....