Faculty of Physical Education and Sport UK, Prague
Department of Physiotherapy

Therapeutic approach to the cervicogenic headache

Bachelor Thesis

Author: Marcus Sjöquist
March 2007, Prague

Supervisor: Mgr Miroslava Jalovcova
Advisor: Ass Marie Musilkova

Declaration:

I declare that this Bachelor Thesis is entirely based upon my own work and my own practise that took place in Vojenska nemocnice in Prague from 22/1 -07 til 2/2 -07.

All information of this work has been taken from the list of litterature in the end of this thesis.

Prague 1/4 -07 Marcus Sjöquist

Acknowledgement:

There are a lot of people that supported me during my life. First of all I want to thank my girlfriend who is an amazing person and she was the one who brought me to Prague.
I also want to thank my family who supports me and always stands behind me and my decisions. I also want to thank my anatomy teacher from the massage school, Roland who learned me a lot in a very short time, my supervisor in the clinical practice Mrs Marie Musilkova and my supervisor in this thesis Mgr Miroslava Jalovcova. Finally I want to thank all my teachers, without them I would not have the knowledge I have today.

Marcus Sjöquist

Contents: Page:

1. Preface

Some years ago we had a physiotherapist in my football team and I stayed after some practices to see what he was doing and he learned me some. I wanted a lot but I did not have the knowledge to help the players with their injuries. This was one of the reasons why I chose to study physiotherapy. Here in Prague, after many years, my will met this knowledge and I am ready to become physiotherapist.

My thesis has two main goals. The first goal is to prove that I am able to do correct evaluation, to connect different conclusions, to create therapeutic plans and to provide correctly all the therapeutic methods that I studied. The second goal is to show that the physiotherapists are an important part of rehabilitation and they can handle such diseases effectively and to relief the patients.

1.1 Abstract

Title: Cervicogenic headache

Cervicogenic headache is a syndrome characterized by chronic hemicranial pain that is referred to the head from either bony structures or soft tissues of the neck.

Aim:

The aim with my thesis is to discuss and make a therapeutic approach to the cervicogenic headache.

Method:

This bachelor thesis reviews the casuistisc presentation of cervicogenic headache and the therapeutic approach of it such as: muscle relaxation techniques, joint mobilization, strengthening exercises for improved posture, and stretching of shortened muscles.

After I did the treatments I compared my work with the proposed therapy from books and articles.

Results:

I compared my treatment to therapeutic approaches from articles and books. I found my treatment successful and my treatment helped my patient to release much of the neck stiffness and her headache.

Key words:

Cervicogenic headache

Referred trigger points

Joint blockages

Posture

2. General part

2.1 Anatomy of the spine

2.1.1 Composition of the vertebral column

The vertebral column is composed of 33 vertebrae- 7 cervical, 12 thoracic, 5 lumbar, 5 sacral and 4 coccygeal.

Because the vertebral column is segmented and made up of vertebrae, joints and fibrocartilage called intervertebral discs it is a flexible structure.

The intervertebral discs form about one fourth of the length of the spine.

Viewed laterally the vertebral column presents several curves, (picture 1) which correspond to the different regions of the column, and are called cervical, thoracic, lumbar, and pelvic. The cervical curve, convex forward, begins at the apex of the odontoid (tooth-like) process, and ends at the middle of the second thoracic vertebra; it is the least marked of all the curves.

The thoracic curve, concave forward, begins at the middle of the second and ends at the middle of the twelfth thoracic vertebra. Its most prominent point behind corresponds to the spinous process of the seventh thoracic vertebra. This curve is known as a kyphotic curve.

The lumbar curve is more marked in the female than in the male; it begins at the middle of the last thoracic vertebra, and ends at the sacrovertebral angle. It is convex anteriorly, the convexity of the lower three vertebrae being much greater than that of the upper two. This curve is described as a lordotic curve. (4)

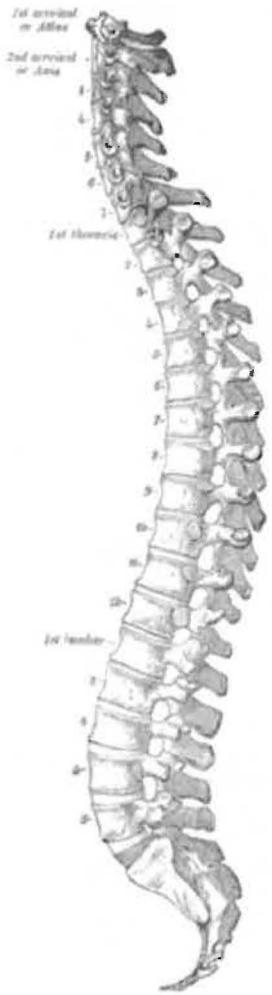

Figure 1: vertebral column (lateral view) (4)

The pelvic curve begins at the sacrovertebral articulation, and ends at the point of the coccyx; its concavity is directed downward and forward. The thoracic and pelvic curves are termed primary curves, because they alone are present during fetal life. In the early embryo, the vertebral column is C-shaped, and the cervical and lumbar curvatures are not yet present in a newborn infant. The cervical and lumbar curves are compensatory or secondary, and are developed after birth, the former when the child is able to hold up its head (at three or four months), and to sit upright (at nine months), the latter at twelve or eighteen months, when the child begins to walk. (4)

2.1.2 Cervical spine

Atlas

In anatomy, the atlas (picture 2) is the topmost cervical vertebra of the spine. It is named for the Atlas of mythology, because it supports the globe of the head. The atlas is the topmost vertebra, and along with the Axis forms the joint connecting the skull and spine. The atlas and axis are specialized to allow a greater range of motion than normal vertebrae. One of the signs of The Atlas is that it has no body, and this is due to the fact that the body of the atlas has fused with that of the next vertebra (the Axis). Its other signs are that it has no spinous process, is ring-like, and consists of an anterior and a posterior arch and two lateral masses. (4)

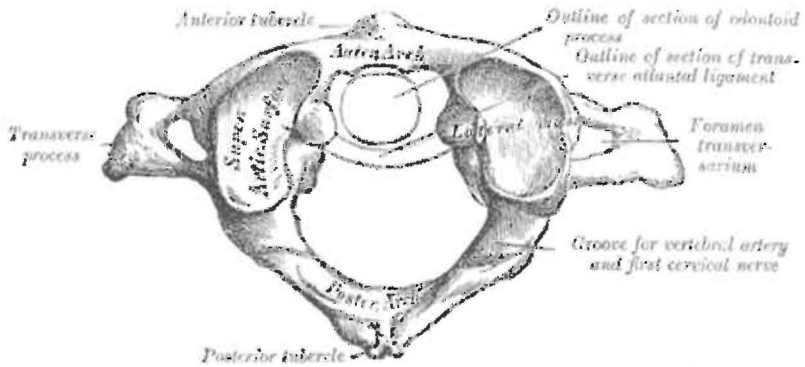

Figure 2: first cervical vertebrae (Atlas) posterior view (4)

Axis

The second cervical vertebra (picture3) of the spine is named the axis (from Latin axis, "axle") or epistropheus. It forms the pivot upon which the first cervical vertebra (the atlas), which carries the head, rotates. The most distinctive characteristic of this bone is the strong odontoid process ("dens") which rises perpendicularly from the upper surface of the body. (4)

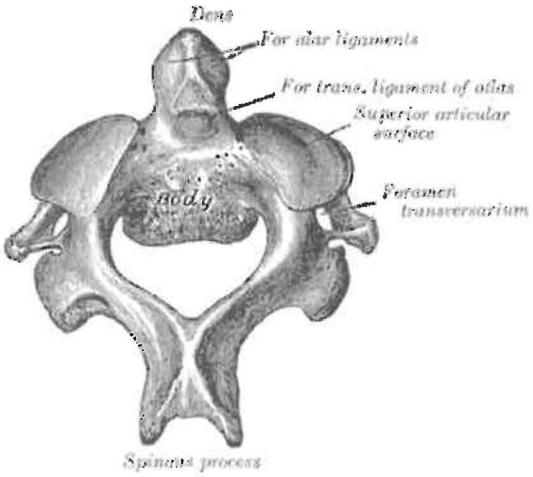

Figure 3: second cervical vertebrae (axis) posterior view (1)

C7 (prominens vertebrae)

The most distinctive characteristic of the seventh cervical vertebra is the existence of a long and prominent spinous process, hence the name vertebra prominens. (picture 4) This process is thick, nearly horizontal in direction. The transverse processes are of considerable size, their posterior roots are large and prominent, while the anterior are small and faintly marked. The foramen transversarium may be as large as that in the other cervical vertebrae, but is generally smaller on one or both sides; occasionally it is double, sometimes it is absent. On the left side it occasionally gives passage to the vertebral artery; more frequently the vertebral vein traverses it on both sides; but the usual arrangement is for both artery and vein to pass in front of the transverse process, and not

through the foramen. Sometimes the anterior root of the transverse process attains a large size and exists as a separate bone, which is known as a cervical rib. (4)

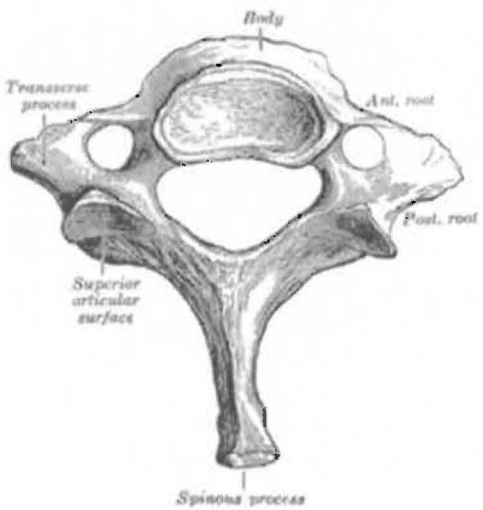

Figure 4: seventh cervival vertebrae (prominens) posterior view (4)

2.1.3 Thoracic spine

The thoracic spine has 12 vertebrae (Th1-Th12) and exhibits a characteristic backward curve or thoracic kyphosis. The thoracic vertebrae are larger than the cervical vertebrae. (picture 5) They have a comparatively heavy body, with a flat wedge shape somewhat lower at the front than at the back when seen from the side. The thick, three-sided spinous processes point downward and backward. The vertebral foramen is round and smaller than in the cervical vertebrae. A characteristic special feature of the thoracic vertebrae is the presence of the connection points to the ribs of the ribcage. Each transverse process features three articular connections (fovea costalis superior and inferior, and the fovea costalis transversalis), at which points each rib is connected to the thoracic spine via the rib tubercle and head. These joints are protected and secured in position by a tight articular capsule and ligaments. The 12 thoracic vertebrae, the 12 rib pairs and the sternum form the ribcage (or thorax), which protects the internal organs. (7)

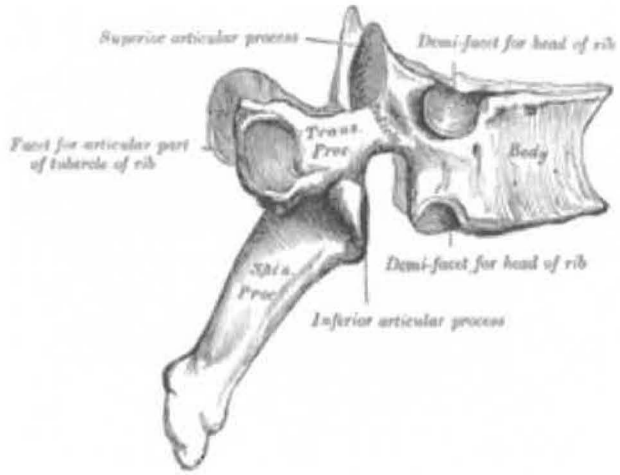

Figure 5: Thoracic vertebrae (lateral view) (1)

2.1.4 Lumbar spine

The lumbar spine has 5 vertebrae (L1-L5). The lumbar vertebral bodies are the largest vertebrae of all (picture 6), since the lumbar spine carries a large proportion of the body's weight. The side view shows their slightly wedge-like shape, similar to the thoracic vertebrae, although in this case the front or ventral side is thicker. The transverse processes are much smaller that those of the thoracic vertebrae. The spinous processes are thick and horizontally oriented. The vertebral foramina are triangular and smaller than in the thoracic vertebrae. The special structure of the lumbar vertebrae facilitates a high degree of mobility for extension and overextension of the trunk in this spinal segment. (7)

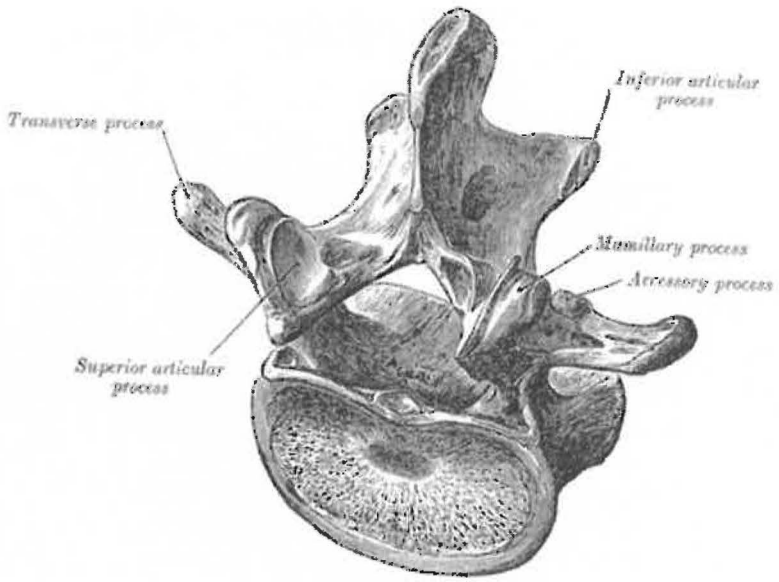

Figure 6: Lumbar vertebrae (posterior view) (1)

2.1.5 zygapophysial joint

A zygapophysial joint (facet joint) is a synovial joint between the superior articular process of one (lower) vertebra and the inferior articular process of the adjacent (higher) vertebra. There are two facet joints in each vertebral motion segment. The biomechanical function of each pair of facet joints is to prevent excessive torsion (twisting) of the spine, while allowing a small amount of left-right bending and bending forward and backward. These functions can be disrupted by degeneration, dislocation, fracture, and/or instability of the facet joints from trauma, osteoarthritis, and/or surgery. (16)

2.2 Biomechanics of the spine

The spinal column performs a variety of mechanical functions, the most important of which are the absorption, dampening, and transmission of pressure and impact loads as well as the absorption and delimitation of movements. The smallest functional element of the spinal column is also known as a mobile segment. A mobile segment consists of two neighboring vertebrae, the intervertebral disc between then, the facet joints and the

ligamentous apparatus. The intervertebral disc is fused to the base and upper plates of the vertebra and the anterior longitudinal ligament, so that it imparts stability to the spinal column. The deformability of the spongy center of the disc gives the mobile segment a measure of elasticity and freedom of movement. The intervertebral disc and ligamentous apparatus are in functional balance, known as discoligamentous stability.The intervertebral, or facet, joints function in this model as the center of rotation between the vertebral bodies as the ventral column and the dorsal column with the transverse and spinous processes, ligamentous apparatus and deep muscles of the back. As the spinal column ages, this sensitive system of spinal column balance may develop serious imbalances, which may in turn result in a variety of degenerative spinal column diseases.

The load bearing capacity, elasticity, flexibility and freedom of movement of the spinal column segments presuppose intact and healthy mobile segments including the vertebral body, intervertebral disc, facet joints, ligamentous apparatus and deep autochthonous back muscles. Within this complex interplay of individual elements, the back muscles play an active role in the so-called "tension band" system that can be understood as a complex system of tensed belts that make it possible for humans to walk upright. Disturbances of this complex harmony in the interplay of the individual components, for example caused by the aging process with attendant wear of the spinal column, can lead to significant changes in a mobile segment, which can then potentially lead to number of degenerative spinal column diseases. (7)

Cervical spine

The cervical spine moves in three planes: flexion-extension, lateral bending and rotation. The atlantooccipital articulation offers a great degree of flexion and extension with limited lateral bending and rotation. The atlantoaxial joint is more complex with rotation as its primary motion with less flexion-extension. Movements between C1 and C2 can occur independently of movements below C2. The cervical segments C3 –C6 are more mobile than C7 and thoracic vertebrae. Most flexion occurs between C5 and C6 followed by C6-C7 and C4.C5. The occipito-atlanto-axial complex allows a great amount of

flexion, mostly at the atlantooccipital articulation. Full rotation is approximately 60 to 75 degrees with half to three quarters occurring in C1-C2. Each disc allows only a few degrees of rotation. Lateral bending occurs in the middle portion of the cervical spine. (3)

- Physiological lateral flexion in the cervical spine is 45 degrees.
- Physiological extension in the cervical spine is 45 degrees.
- Physiological flexion in the cervical spine is 45-60 degrees. (5)

Thoracic spine

The thoracic spine is the part of the spinal column with the lowest degree of mobility in the frontal and sagittal planes, since the ribs of the thorax are solidly connected by joints to the thoracic vertebrae and the sternum.(7)

Lumbar spine

The lumbar spine, taken as a whole, has a maximum mobility of 60°-70° in flexion and up to 30° in extension. Lateral inclination to the right and left is possible up to 30°. The rotation range of the individual mobile segments in the lumbar spine is limited to only 2°. The lower lumbar spine and in particular the transition to the sacrum (lumbosacral transition) can be termed a weak point in spinal column statics, since the 5th lumbar vertebra shows a tendency to shift forward in response to changes in the lumbosacral angle. A healthy lumbar spine is able to absorb the shearing, torsion and compression forces applied to it through the interplay of the intact components of the mobile segments. The fact that the lumbar spine is subject to considerable static loads makes it particularly susceptible to the development of degenerative conditions. (7)

2.3 Cervicogenic headache

Cervicogenic headache was first described by Sjaastad and his colleges in 1983 but has not yet found a normal place in the headache classification.

2.3.1 Symptoms

Cervicogenic headaches are described as predominantely unilateral fronto-temporal headaches with otherwise migraine-like characteristics. Distinguishing features include

consistent unilaterally, precipitation with neck movement or pressure on certain tender spots in the neck, and associated shoulder and arm pain with neck stiffness. Cervicogenic headaches have many features in common with migraine, tension type headache and posttraumatic headache. One unifying feature is the presence of myofascial trigger points in all of these headache types. That patients with cervicogenic headaches have myofascial TrP that reproduce the headache was documented in an evaluation of 11 patients diagnosed by Sjaastad himself as fulfilling the criteria for cervicogenic headache.

Other authors cite the presence of a trigger point as a diagnostic feature in cervicogenic headache. This triggerpoint is described as being a circumscribed hypersensitive skin and muscle spot with a reduced pain threshold, or as being located over specific anatomical sites in the neck or nuchal line without specifically implicating muscle, nerve or bone.

Studies have documented that most cervicogenic headache patients have reduced segmental cervical spine mobility. (15)

2.3.2 Frequency

Tension-type headache and cervicogenic headache are two of the most common non-migraine headaches. Population-based studies suggest that a large proportion of adults experience mild and infrequent (once per month or less) tension-type headaches, and that the one-year prevalence of more frequent headaches (more than once per month) is 20%-30%; a smaller percentage of the population (roughly 3%) has been estimated to have chronic tension-type headache. Estimates of the prevalence of cervicogenic headache have varied considerably, due in large part to disagreements about the precise definition of the condition. A recent population-based study, which used the diagnostic criteria of the International Headache Society , found that 17.8% of subjects with frequent headache fulfilled the criteria for cervicogenic headache; this was equivalent to a prevalence of 2.5% in the larger population. This agrees with an earlier clinic-based study which found that 14% of headache patients treated had cervicogenic headache.

The impact of tension-type headache on individuals and society appears to be significant. According to one population-based study, regular activities were limited during 38% of tension-type headache attacks, and 4% of respondents indicated that their headaches affected their attendance at work. Eighty-nine percent of tension-type headache sufferers

reported that their headaches had negatively affected their relationships with friends, colleagues, and family. Little is known about the personal and societal impact of cervicogenic headache. (11)

2.3.3 Causes

Whether from chronic tension or acute whiplash injury, intervertebral disc disease or progressive facet joint arthritis, the neck can be a hidden and severely debilitating source of headaches. Such headaches are grouped under the term "cervicogenic headache", indicating that the primary contributing structural source of the headache is the cervical spine. There are well mapped out patterns of headache relating to a multiplicity of muscular trigger points in the neck and shoulder-blade (or peri-scapular) region, as well as to disc and joint levels in the upper cervical spine. Even headaches located predominantly in the forehead, or behind, in and around the eyes are very often "referred" pain zones for pathology located in the back of the neck and at the base of the skull. This base of the skull area is called the suboccipital region, because it is below the occipital part of the head. The joints connecting the top two or three levels of the cervical spine to the base of the skull handle almost 50% of the total motion of the entire neck and head region, thus absorbing a continuous amount of repetitive stress and strain, in addition to bearing the primary load of the weight of the head. Fatigue, postural malalignment, injuries, disc problems, joint degeneration, muscular stress and even prior neck surgeries all can compound the wear and tear on this critical region of the human skeletal anatomy. One may also develop a narrowing of the spinal canal itself, through which runs the spinal cord and all of its exiting nerve roots, leading to a condition termed spinal stenosis, also a possible source of headaches, among other symptoms. (17)

2.3.4 Diagnostic testing

Cervical nerve or zygapophyseal joint blockade is required to confidently render a diagnosis of cervicogenic headache. The first three cervical spinal nerves and their rami are the primary peripheral neurogenic sources that can refer pain to the head. (14)

The suboccipital nerve innervates the atlanto-occipital joint; therefore, pathology or injury affecting this joint is a potential source for head pain that is typically experienced

in the occipital region. The C2 spinal nerve and its dorsal root ganglion has a close anatomic proximity to the lateral capsule of the atlantoaxial zygapophyseal joint and innervates the atlantoaxial and C2-3 zygapophyseal joints; therefore, trauma to or pathologic changes surrounding these joints can be a source of referred pain. The pain of C2 neuralgia is typically described as deep and dull located from the occipital to parietal, temporal, frontal, and periorbital regions. There is often an intermittent pain in the occipital region superimposed over the constant pain. Associated signs can include ipsilateral eye lacrimation and conjunctival injection. Arterial or venous compression of the C2 spinal nerve or its dorsal root ganglion has been suggested as a cause for C2 neuralgia in some cases (13)

The third occipital nerve has a close anatomic proximity to and innervates the C2-3 zygapophyseal joint. This joint and thus the third occipital nerve appear most vulnerable to trauma from acceleration-deceleration injuries of the head and neck (commonly known as whiplash) (10).

Pain from the C2-3 zygapophyseal joint can be referred to the occipital, frontotemporal, and periorbital regions. The characteristics of this referred head pain and its associated symptoms may mimic migraine or hemicrania continua but will not significantly respond to medications that are typically effective for these primary headache disorders. The resolution of chronic headache has been reported after discectomy at spinal levels as low as C5-6 (6)

Diagnostic anesthetic blockade for the evaluation of cervicogenic headache can be directed to several anatomic structures such as the greater occipital nerve , lesser occipital nerve, atlanto-occipital joint, atlantoaxial joint, C2 or C3 spinal nerve, third occipital nerve, zygapophyseal joints, or intervertebral discs based on the clinical characteristics of the pain and the physical examination (19)

The occurrence of a regional myofascial pain syndrome involving cervical, pericranial, or masticatory muscles can cause head or face pain referred from the affected muscles. Sensory afferent nerve fibers from the upper cervical segments have been observed to

enter the spinal column by way of the spinal accessory nerve before entering the dorsal spinal cord. (2)

Motor fibers of the spinal accessory nerve can travel with the upper cervical spinal nerves, which carry both motor and sensory nerve fibers. The close proximity of these nerve fibers allows for an interchange of somatosensory, proprioceptive, and nociceptive information that ultimately converges in the trigeminocervical nucleus. This interchange and convergence of sensory information may allow the referral of nociceptive sensory signals from the m. trapezius, m. sternocleidomastoid, and other cervical muscles to regions of the head and face. Trigger points, discreet hyperirritable areas of contracted muscle that have a lowered pain threshold, are found in body regions affected by a myofascial pain syndrome. An active trigger point is able to elicit spontaneous pain or pain after physical stimulation that is referred to distant sites in predictable and reproducible patterns. A latent trigger point can also produce a referred pain pattern when it is manually compressed or when the involved muscle is stretched or stressed in some way. Trigger point injections can assist in the diagnostic evaluation of pain referred to the head or face from muscular sources. (18)

2.3.5 Treatment

The successful treatment of cervicogenic headache usually requires a multifaceted approach using pharmacologic, nonpharmacologic, manipulative, anesthetic, and occasionally surgical interventions. Medications alone are often ineffective or provide only modest benefit for this condition. (1)

Treatment requires a thorough evaluation of the possible contributing factors, several of which often exist together. Physical therapy, provided by an expert spine therapist, is critical to the success of most other treatment modalities, whether those include pain injections or surgery or relaxation and posture techniques. Injections can take the form of muscle (or myofascial) trigger point blocks, nerve blocks or epidural spinal injections. The most effective injections for cervicogenic headaches usually end up being x-ray guided facet joint blocks, especially of the upper facet levels. These should only be performed by a physician trained, skilled and experienced in such procedures, as the area

in the neck where they are given is quite complex. If investigation leads to discovery of significant enough disc or joint disease in the cervical spine, leading to altered load bearing in that area and pain, surgery is sometimes the best answer. Any particular treatment, however, is provided in the context of a comprehensive program addressing all of the issues and possible contributing factors noted above.

Chiropractic adjustments, acupuncture and massage are all excellent therapeutic options to assist in managing chronic pain problems or in arresting acute flare-ups of headache pain emanating from the neck area. A word of caution about such modalities, though, is that they are passive. A critical component of any long-term effective pain-management regimen is a committed, active participation of the patient. Triggering activities need to be recognized. Early pain-building warning signs must be learned and counter-acted. Posture and exercise need to be attended to, while stress must be diffused out of the body. Medications are very effective for cervicogenic headaches, to the degree that they can be tolerated while an individual goes on living a functional life. Certainly in severe pain crises, the paramount goal is to maximally relieve pain as quickly as possible. The balance is to work toward minimizing the number of crises one has to experience, whether through corrective treatment or proactive effective management.

Severe headaches are almost universally described as "oh this was a migraine", but true migraine variant headaches are thought to comprise only 8% of all headache episodes. The much more common, but just as severe, pounding, throbbing, stabbing and nauseating headaches originate from tension, absorbed most frequently in the body in the neck and shoulder region. The majority of these can fall into the category of cervicogenic headache.

Remember, pain is invisible. Very few headaches "show up" on brain MRI scans. There is much to be seen and found in the high stress zone of the neck, however, and this area should be evaluated in detail and treated aggressively in anyone with chronic or recurrent headaches. Even patients with true migraines or cluster headaches will eventually also often end up with compounding cervicogenic headaches, because of the severe stress of

the original headache in the first place. One headache is bad enough. No one needs two types to suffer under. (15)

According to Dr. Zasler we could see these therapeutic approaches for cervicogenic headache:

Trigger point injections may be utilized when there is pain coming from a hypersensitive "trigger point" in a muscle that refers into the head. Trigger points in the upper neck and shoulder may refer pain into the back of the head, behind the eye and into the same side frontal and temporal region. Trigger point therapy may involve dry needling (nothing is injected; the needle is inserted simply to "break up" abnormal bands of fibrous tissue at the trigger point) or injection therapy, the latter typically with local anesthetic and/or a steroid.

Manual therapy is typically utilized to treat myofascial restrictions (abnormalities in muscle and its associated connective tissue) as well as joint dysfunctions. Muscle energy techniques (manipulation without thrust) can be quite beneficial in treating joint dysfunctions of the cervical spine, additionally providing the benefit of being less traumatic to the patient and less risky than thrust manipulation. Thrust manipulation, when performed correctly, generally is a safe technique and is used by chiropractors and appropriately trained physicians.

Post-isometric muscle relaxation (PIMR) is very useful for treatment of shortened muscles and can be used to treat myofascial pain as well. Treatment involves active isometric contraction against the comfortable stretch barrier for a few seconds, followed by stretching of the muscle to its new barrier, and then repeating the process till full or optimal range of motion is achieved. PIMR is an excellent technique that can be taught to patients for self-treatment.

Occipital nerve block may be helpful when there is irritation and dysfunction in specific branches of the occipital nerve on one or both sides of the neck. The occipital nerve provides sensation to the scalp in the back of the head. The nerve root found at the juncture of the head and neck will occasionally be damaged by direct trauma or entrapped

in structures of the upper neck following whiplash type injuries. When irritation is more severe, shooting or stabbing pain can be referred to the same side of the head behind the eye or in the forehead. A nerve block is performed by carefully injecting a local anesthetic, or anesthetic in conjunction with a corticosteroid, for diagnostic and treatment purposes, respectively.

C2-C3 facet joint blockade is a procedure that is typically done by an interventional pain management specialist, either an anesthesiologist or a physiatrist or other appropriately trained clinician. The facet joint at a specific segment of the cervical spine (C2-C3) seems be particular vulnerable to neck trauma. The blockade is done using x-ray fluoroscopy with injection of local anesthetic.

Cervical epidural steroid injections are also performed by interventional pain management specialists. They may be considered when the pain is unresponsive to conservative treatment but is believed to be responsive to steroids. Studies have confirmed the safety of this technique with symptomatic relief of a variety of painful conditions in the cervical spine.

Cervical traction applies a stretch to muscles, ligaments, and tissue components of the cervical spine. It may provide relief by promoting separation of the space between the vertebrae which contains the disc and may thereby reduce a disc "bulge" or nerve impingement. Cervical traction is not indicated for use in conditions of cervical instability. Traction is optimal when the patient's neck is placed at 20-30 degrees of flexion (forward tilt).

More invasive interventions requiring true surgical intervention include surgical fusion of the joints at the juncture of the head and neck in patients with arthritis producing cervicogenic headache.

Treatment of cervicogenic headache, first and foremost, requires taking an adequate history and performing a good physical exam, including assessment of posture, body asymmetries, musculoskeletal evaluation, and neurologic screening evaluation. Treatment should be multimodal and may include various broad interventions, such as medications, injection therapies, physical therapy, TENS, traction, biofeedback, and surgical

procedures. When there is long-standing pain, a referral to a pain behavioral specialist may also be indicated to assist the individual with pain adjustment and to teach pacing and relaxation techniques, among other interventions. (20)

Pharmacological treatment

Pharmacologic treatments for cervicogenic headache include some medications that are used for the preventive management for migraine and neuropathic pain. The medications in this section have neither been approved by the Food and Drug Administration nor rigorously studied in controlled clinical trials for efficacy in the treatment of cervicogenic headache. The medications are suggested as treatments for cervicogenic headache based on the anecdotal experiences of clinicians who treat the condition. The side effects and laboratory monitoring guidelines provided are not intended to be a comprehensive review and the reader is cautioned to consult standard references or the medication package inserts prior to prescribing any medication.

Medication when used as the sole treatment for cervicogenic headache does not tend to provide substantial pain relief in many cases but can often provide enough benefit to allow the patient to be more actively involved in a physical rehabilitation program. Medications are initially prescribed at a low dose and increased over 4 to 8 weeks as necessary and tolerated. The cautious combining of medications from different drug classes may provide more efficacy than using either drug alone (ie, an antiepileptic drug combined with a tricyclic antidepressant). Frequent follow-up visits are necessary for medication dosage adjustments, monitoring of serum drug levels, and evidence of medication toxicity. (8)

Physical therapy and manipulative treatment

When prescribed and expertly provided as an integral part of a multidisciplinary pain rehabilitation program, physical therapy and manipulative treatment are important therapeutic modalities. The pain of cervicogenic headache tends to worsen after having manual or physical treatments that are performed too vigorously. A slow-paced progression of manipulation should begin with gentle muscle stretching and manual

cervical traction thereafter advancing as tolerated. It is important to educate the patient in how to participate in a regularly scheduled home exercise and rehabilitation program. Anesthetic and neurolytic procedures can often provide enough pain relief to allow for a more comfortable and expedient course of manipulative treatment and physical rehabilitation. (12)

Specific exercises to promote strength, endurance and flexibility for better posture.

- Relax and stretch sternocleidomastoideus
- Relax and stretch suboccipitals
- Manual traction of cervical spine
- Facilitate/ strengthen lower and middle trapezius
- Postural exercise for deep neck flexors
- Strength/ endurance exercise for deep neck flexors and lower scapulae stabilizers
- Lumbopelvic stabilization exercises
- Upper thoracic spine extension stretch (9)

3. Special part

3.1 Anamnesis

Patient: C.A

Gender: Female

Age: 19

Height: 165 cm

Weight: 53 kg

BMI: 19,9

Family anamnesis

- Both parents are healthy.

Personal anamnesis

- No allergies
- Normal child diseases
- No operations
- Sprained ankle 2 years ago (left)
- No other injuries or diseases
- No gynecological problems
- She takes analgetic pills for the headache

Social anamnesis

- She is a high school student
- Many hours in sitting position (Approximately 9 hours/day)
- She is swimming twice a week
- She is painting almost every day (for 8 years)
- She is right handed
- She does not smoke and does not drink alcohol

Pain anamnesis

- The present problem started 3 years ago
- She has pain in neck with following headache approximately 3-4 days a week
- The pain is worse after long time sitting and during painting, sometimes she has to stop because of the pain.
- The neck pain is present on both sides but the headache is normally present only on one side (most often on the right side a bit over the eye)
- She sleeps in prone position and she has no pain during the nights
- Sometimes she feels pain in the neck during swimming and sometimes the headache inhibits her to go swimming.

Previous rehabilitation

- No previous rehabilitation

Status present

- She has a small headache and she feels stiff in her neck.

3.2 Initial kinesiologic examination

3.2.1 Postural examination

Standing position

Posterior view:

Standing:	Wide base
Heels:	Symmetrical
Achilles tendons:	Symmetrical
Calves:	Symmetrical
Popliteal lines:	Left slightly higher
Thighs:	Symmetrical contour
Subgluteal lines:	Symmetrical

Illiac crests:	Symmetrical
Posterior superior iliac spine:	Symmetrical
Trunk:	Slightly lateral flexed and rotated to the left
Trunk outlines:	Left is more concave
Scapulae:	Right slightly higher
Shoulders:	Right shoulder is slightly higher
Ear lobes:	Symmetrical

<u>Anterior view</u>

Weight bearing:	Medial standing
Longitudinal arches:	Physiological
Transverse arches	Physiological
Calves:	Symmetrical
Hip joints:	External rotation in both due to the position of patella
Umbilicus:	Symmetrical
Clavicles:	Symmetrical
Head position:	In the midline

<u>Side view:</u>

Knee joint position	Physiological
Lumbar part of spine	Hyperlordosis
Thoracic part of spine	Normal kyphosis
Cervical spine	Straight
Position of shoulders	Physiological
Position of head	Forward posture

<u>Palpation of pelvis</u>

Anterior superior iliac spine	Same level on both sides
Posterior superior iliac spine	Same level on both sides

Illiac crest	Same level on both sides

The anterior superior iliac spines are in lower position than the posterior superior iliac spines, that means that the pelvis is in anterversion.

Conclusion of the postural examination

According to the hyperlordosis and the anterversion of pelvis I will examine length of hip flexors and and paravertebral muscles and because of the forward head position I will examine the length and strength of the muscles around the neck. Due the external rotation in hip joints I will also examine piriformis.

3.2.2 Dynamic and stabilization test evaluation

Trendelenburg test:	Negative
Bending trunk forward:	Restricted movement in thoracic spine

Spine distances:

Stibor`s	7 cm negative
Shober`s	6 cm negative
Cepoj`s	2,5 cm positive

Conclusion of the dynamic test evaluation

Due to the bending trunk forward test I have to examine the length of the paravertebral muscles and due to the Cepoj`s test I will measure the length of the neck extensors and joint play.

3.2.3 Gait evaluation

The gait was normal and symmetric. No clinical findings or any sign of problems.

3.2.4 Range of motion

Goniometry (active) according to SFTR:

Shoulder joint	Left	Right
Flexion	180°	180°
Extension	40°	40°
External rotation	80°	85°
Internal rotation	65°	60°

Elbow joint		
Flexion	145°	145°
Extension	5°	5°

Neck		
Flexion	50°	
Extension	55°	
Lateral flexion	35°	40°
Rotation	65°	65°

Conclusion of the goniometry

There is hyperextension in elbow joints.

There is restriction in lateral flexion of the head, especially to the left side. There is also restriction in rotation of the head.

3.2.5 Neurological examination

Upper extremities

Tendon reflexes

Biceps reflexes	Normal
Triceps reflexes	Normal

Finger flexion reflexes	Normal
Radiocarpal reflexes	Normal

Superficial sensation

Touch	Normal

Deep sensation

Vibration	Normal
Positioning	Normal

Conclusion of the neurological examination

According to the examination there are no signs of radiculopathy.

3.2.6 Palpation

Muscle	Left	Right
m.Gluteus maximus	Hypotonus	Hypotonus
m. Piriformis	Hypertonus and TrP	Hypertonus and TrP
m.Erector spinae		
Lumbar part	Normal tonus	Normal tonus
Thoracic part	Hypertonus	Normal tonus
Cervical part	Hypertonus	Hypertonus
m. Rhomboids	Hypotonus	Hypotonus
m.Upper trapezius	Normal tonus and TrP	Hypertonus and TrP
m. Levator Scapulae	Normal tonus	Normal tonus and TrP
m. Sternocleidomastoideus	Hypertonus and TrP	Hypertonus and TrP
m. Scaleni	Hypertonus	Hypertonus
m. Supraspinatus	Normal tonus and TrP	Normal tonus and TrP
m.Infraspinatus	Normal tonus	Normal tonus
m. Teres minor	Normal tonus	Normal tonus
m. Teres major	Normal tonus	Normal tonus
m. Suboccipitals	TrP	

Conclusion of palpation:

There is hypotonus in m. Gluteus maximus and in m. Rhomboids. There is hypertonus in m. Piriformis, left thoracic part of the erector spinae, cervical part of erector spinae, upper trapezius on the right side, m. Sternocleidomastoideus and the scalene muscles. There are trigger points present in the m. Piriformis, m. upper Trapezius, m. Levator scapulae on the right side, m. Sternocleidomastoideus, m. Supraspinatus and m. Subocccipitals.

3.2.7 Muscle length test (According to Vladimir Janda)

Muscle	Left	Right
m. Illiopsoas	0	0
m. Rectus femoris	0	0
m. Pectoral major	1	2
m. Pectoral minor	1	1
m. Scalenes	0	0
m. Sternocleidomastoideus	0	0
m. Upper trapezius	0	1
m. Levator scapulae	0	1
m. Suboccipitals	1	

Conclusion of muscle length test

There is shortness of m. Pectoralis major and minor in both sides, especially in the left side.

I can also see shortness of m. Levator scapulae and m. upper Trapezius on the right side.

3.2.8 Muscle testing (according to Kendall)

Muscle	Left	Right
Hamstrings	4	5
m. Gluteus maximus	4	5
m. Rectus abdominis	3	
m. Rhomboids	3	3
m. upper Trapezius	5	5
m. middle Trapezius	3	3
m. lower Trapezius	3	3
Deep flexors of the neck	3	

Conclusion of muscle testing

There is weakness of lower and middle part of m. Trapezius and deep flexors of the neck.

There is also weakness in the m. Rhomboids and in the m. Rectus abdominis.

I can also see weakness in the left side of the Hamstrings and in m.Gluteus maximus.

3.2.9 Joint play examination

Joint	Result
Atlantooccipital	Restriction in springing in lateral flexion.
Cervical spine	No restriction
Thoracic spine	No restriction
Lumbar spine	No restriction
Sternoclavicular	No restriction
Acromioclavicular	No restriction
Shoulder	No restriction
Elbow	No restriction
Ribs	No restriction

Conclusion of joint play examination

There is restriction in the lateral flexion of the atlantooccipital joint.

3.3 conclusion of the initial kinesiological examination

According to our classes in Introduction to rehabilitation the anamnesis is a very important part of the examination. During the anamnesis the patient tells you about the main problems he or she has.

My patients main problem is headache and she feels high tension in the neck. She has headaches 3-4 times a week and her neck feels stiff almost all the time. She has been having this problems for three years now. According to the anamnesis I realized that the main problem with my patient is the long time sitting every day in a faulty posture. The posture during painting, which is in standing, is also not good. You can see the forward head posture and the elevated right shoulder. I also think that the swimming makes her problem worse because she is swimming breast stroke and she does not know how to breathe correctly and her incorrect breathing makes her swim with extension in the neck.

I think the high tonus in her neck muscles is a result of a bad swimming pattern and a faulty posture during her sitting and painting. She sprained her left ankle two years ago. No other injuries or operations. Sometimes she takes some analgetic pills for the headache.

She does not smoke and drink alcohol.

According to the anamnesis the main problem with my patient is the headaches and I believe that it is related to the neck. During the examinations I looked for TrP, joint restrictions, muscle imbalances which helped me to decide the reasons of the headache. I found TrP in m. upper Trapezius, m. Sternocleidomastoideus and m. Suboccipitals. I found weakness in deep flexors and shortness in the m. Suboccipitals which is related to the forward head posture. I found weakness of the m. Rhomboids and the m. middle Trapezius and also weakness in the abdominal muscles. According to the joint play examination I found restriction in C0-C1 in lateral flexion.

In the goniometry I found some restricted patterns, the most important was the shortness in lateral flexion of the neck. According to my examination I made a short term and a long term plan for my therapy.

3.4 Short and long term rehabilitation plan

Short term plan

Relaxation of hypertonic muscles

Relieving trigger points

Release the pain

Elongation of shortened muscles

Mobilize the restricted joints

Increase muscle power of weak muscles

Increase the range of motion in restricted joints

Instruction of patient for good posture during sitting and sleeping

Instruction of patient how to provide correct the auto-therapy exercises

Long term plan

Maintain the muscle power

Maintain the range of motion in joints

Keep the right posture during activity of daily living

3.5 Treatment

First session 23/1 -07

- Massage of the cervical and upper thoracic spine for relaxation
- PIR for m. upper Trapezius, m. Levator scapulae, m. Sternocleidomastoideus, m. Scalenes and m. Suboccipitals.
- Stretching for m. Pectoral major and m. Pectoral minor
- Correction of posture according to Brugger
- Mobilisation of Atlantoccipital joint in lateral direction

- Instruction for autotherapy (self PIR for m. upper Trapezius and m. Suboccipitals)

Second session 25/1 -07

- Control autotherapy program
- Massage of the cervical and upper thoracic spine for relaxation
- PIR for m. upper Trapezius, m. Levator scapulae, m. Sternocleidomastoideus, m. Scalenes and m. Suboccipitals.
- Mobilisation of Atlantoccipital joint in lateral direction
- Stretching for m. Pectoral major and m. Pectoral minor
- Correction of posture according to Brugger
- Breathing exercises for strengthening of abdominals
- Strengthening of abdominal muscles on fitball
- Strengthening of m. Rhomboids and middle part of Trapezius in prone lying
- Sensomotoric stimulation (small feet and balance exercises) for posture improvement.
- Instruction for autotherapy (strengthening of abdominals and deep flexors of the neck)

Third session 30/1 –07

- Control autotherapy program
- Correction of posture according to Brugger
- Massage of the cervical and upper thoracic spine for relaxation
- PIR for m. upper Trapezius, m. Levator scapulae, m. Sternocleidomastoideus, m. Scalenes, m. Suboccipitals and m. Piriformis.
- Manual traction of cervical spine
- Klapp exercises for strengthening of m. middle Trapezius and m. Rhomboids.
- Breathing exercises for strengthening of deep flexors of the neck and abdominals
- Strengthening of abdominal muscles on fitball
- Stretching of m. Pectoral major and m. Pectoral minor

- Sensomotoric stimulation (small feet and balance exercises) for posture improvement.
- Instructions for autotherapy (self stretching for m. Pectoral major and breathing exercises for strengthening of deep flexors of the neck and abdominal muscles)

Fourth session 1/2 -07

- Control autotherapy program
- Correction of posture according to Brugger
- Massage of the cervical and upper thoracic spine for relaxation
- PIR for m. upper Trapezius, m. Levator scapulae, m. Sternocleidomastoideus, m. Scalenes, m. Suboccipitals and m. Piriformis.
- Manual traction of cervical spine
- Breathing exercises for strengthening of deep flexors of the neck and abdominals
- Stretching of pectoral major and pectoral minor
- Sensomotoric stimulation (small feet and balance exercises) for posture improvement.
- Repetition of all autotherapy instructions

3.6 Results of the therapy

After the therapy sessions I was really pleased with my results. After the third session the frequency of the headache decreased. She also felt less stiff in the neck already after the first therapy. The patient also told me that she felt it really hard with the posture correction in the beginning of the therapy but after some days it felt better and less unnatural.

3.7 Final kinesiological examination

Postural examination

Standing position

Posterior view:

Standing: Wide base

Heels:	Symmetrical
Achilles tendons:	Symmetrical
Calves:	Symmetrical
Popliteal lines:	Left slightly higher
Thighs:	Symmetrical contour
Subgluteal lines:	Symmetrical
Illiac crests:	Symmetrical
Posterior superior iliac spine:	Symmetrical
Trunk:	Slightly lateral flexed and rotated to the left.
Trunk outlines:	Left is more concave
Scapulae:	Right is slightly higher.
Shoulders:	Right shoulder is slightly higher
Ear lobes:	Symmetrical

<u>Anterior view</u>

Weight bearing:	Medial standing
Longitudinal arches:	Physiological
Transverse arches	Physiological
Calves:	Symmetrical
Hip joints:	External rotation in both due to the position of patella
Umbilicus:	Symmetrical
Clavicles:	Symmetrical
Head position:	In the midline

<u>Side view:</u>

Knee joint position	Physiological
Lumbar part of spine	Normal lordosis (improved)
Thoracic part of spine	Normal kyphosis
Cervical spine	Straight

Position of shoulders	Physiological
Position of head	Still forward posture (less than before, improved)

Goniometry

Shoulder joint	Left	Right
Flexion	180°	180°
Extension	40°	40°
External rotation	80°	85°
Internal rotation	65°	60°

Elbow joint		
Flexion	145°	145°
Extension	5°	5°

Neck		
Flexion	55° (5° more)	
Extension	55°	
Lateral flexion	40° (5° more)	45° (5° more)
Lateral rotation	70° (5° more)	70° (5° more)

Palpation

Muscle	Left	Right
m. Gluteus maximus	Hypotonus	Hypotonus
m. Piriformis	Hypertonus and TrP	Hypertonus and TrP
m. Erector spinae		
Lumbar part	Normal tonus	Normal tonus

Thoracic part	Hypertonus	Normal tonus
Cervical part	Hypertonus	Hypertonus
m. Rhomboids	Normal tonus (improved)	Normal tonus (improved)
m. Upper trapezius	Normal tonus (No Trp) (improved)	Normal tonus (Less Trp) (improved)
m. Levator Scapulae	Normal tonus	Normal tonus (No TrP) (improved)
m. Sternocleidomastoideus	Hypertonus (less TrP, improved)	Hypertonus (less Trp, improved)
m. Scaleni	Hypertension	Hypertension
m. Supraspinatus	Normal tonus and TrP	Normal tonus and TrP
m. Infraspinatus	Normal tonus	Normal tonus
m. Teres minor	Normal tonus	Normal tonus
m. Teres major	Normal tonus	Normal tonus
m. Suboccipitals	(No TrP, improved)	

Muscle length test

Muscle	Left	Right
m. Illiopsoas	0	0
m. Rectus femoris	0	0
m. Pectoral major	1	1 (improved)
m. Pectoral minor	0 (improved)	0 (improved)
m. Scalenes	0	0
m. Sternocleidomastoideus	0	0
m.upper Trapezius	0	0 (improved)
m. Levator scapulae	0	1
m. Suboccipitals	1	

Muscle testing

Muscle	Left	Right

Hamstrings	4	5
m. Gluteus maximus	4	5
m. Rectus abdominis	4 (improved)	
m. Rhomboids	4 (improved)	4 (improved)
m. Upper trapezius	5	5
m. Middle trapezius	3	3
m. Lower trapezius	3	3

Deep flexors of the neck	4 (improved)

Joint play examination

Joint	Result
Atlantooccipital	Less restriction in springing in lateral flexion.
Cervical spine	No restriction
Thoracic spine	No restriction
Lumbar spine	No restriction
Sternoclavicular	No restriction
Acromioclavicular	No restriction
Shoulder	No restriction
Elbow	No restriction
Ribs	No restriction

3.8 Conclusion of the final kinesiological examination

In my final kinesiological examinations I could see a lot of improvements. The most important thing was that the forward head posture was decreased and and I could see increased muscle power in m. Rhomboids, m. middle Trapezius, abdominals and deep flexors of the neck. I could also see increased length in m. Pectoralis major and m. Pectoralis minor.

Lateral flexion in the neck increased with 5 degrees to both sides and so did also the flexion. The restriction in the C0-C1 joint was less after the therapy. A lot of TrP were

relieved after the therapy, especially in the m. suboccipitals, m. sternocleidomastoideus and m. upper Trapezius. The posture on the patient was better after this sessions but there is still a lot of things to work with.

3.9 Prognosis

I believe that the prognosis for my patient is good. We did together a lot of improvements and she was a cooperative patient which helped here to get good result.
If she continues with her autotherapy program she will succeed with her goals to not have any problems anymore.

3.10 Conclusion

I felt that I succeed with my practice in Vojenska nemocnice. It wouldn`t have worked out so good without the supervision of Mrs Musilkova and the good cooperation with my patient who believed in every treatment I did and made the autotherapy programs that I showed her.

4. List of abbreviations

C1: first cervical vertebrae

C2: second cervical vertebrae

C3: third cervical vertebrae

C4: fourth cervical vertebrae

C5: fifth cervical vertebrae

C6: sixth cervical vertebrae

C7: seventh cervical vertebrae

Th1: first thoracic vertebrae

Th12: twelfth thoracic vertebrae

TrP: trigger point

MRI: magnetic resonance imaging

BMI: body mass index

SFTR: sagittal, frontal, transversal, rotational

M: muscle

List of litterature:

1. Blume HG: Cervicogenic headaches: radiofrequency neurotomy and the cervical disc and fusion, Clin Exp Rheumatol 2000, 18(suppl 19):S53-S58.

2. Bremner-Smith AT: Sensory pathways in the spinal accessory nerve, J Bone Joint Surg Br 1999, 81:226-228.

3. Delisa Joel A, Rehabilitation medicine, 3rd edition, Lippincott Williams and Wilkins, Philadelphia, 1998

4. Drake Richard L, Vogl Wayne, Mitchell W. M, Adam Gray`s anatomy for students, 1st edition, Philadelphia, 2:26-33, 2005

5. Elway John, Compensation and pension examination, 2005, Available at: www.va.gov

6. Fredriksen TA: Cervicogenic headache: long-term postoperative follow-up, Cephalalgia 1999, 19:897-900.

7. Harms Jurgen Professor,spinal disease information portal, Available at: www.harms_surgery.com, 2007

8. Hobson DE: Botulinum toxin injection for cervicogenic headache. Headache 1997, 37:253-255.

9. Libenson Craig Rehabilitation of the spine, Lippincott Williams and Wilkins, 1996, 19:365-380

10. Lord SM: Chronic cervical zygapophyseal joint pain after whiplash. A placebo- controlled prevalence study. Spine 1996, 21:1737-1744.

11. Mccrory Douglas, foundation for chiropractic education and research, 2004, Available at: www.fcer.org,

12. Nilsson N, The effect of spinal manipulation in the treatment of cervicogenic headache, J Manipulative Physiol Ther 1997, 20:326-330

13. Pikus HJ: Characteristics of patients successfully treated for cervicogenic headache by surgical decompression of the second cervical root. Headache 1995, 35:621-629.
14. Pikus HJ: Outcome of surgical decompression of the second cervical root for cervicogenic headache. Neurosurgery 1996, 39:63-70.
15. Simmons and Tanner , Myofascial pain and dysfunction, 2nd edition, Lippincot Williams and Wilkins, Philadelphia 1999
16. Snell Richard S, Clinical anatomy, 7th edition, Lippincott Williams and Wilkins, Philadelphia , 2004
17. Surello Len, Chicago institute for neurosurgery and neuroresearch Available at: http://www.cinn.org/pain/headache-cervicogenic.html, 2005
18. Travell JG: Referred pain from skeletal muscle, N Y State J Med 1955, 55:331-340.
19. Van Suijlekom JA: Cervicogenic headache: techniques of diagnostic nerve blocks, Clin Exp Rheumatol 2000, 18(suppl 19):S39-S44.
20. Zasler Nathan D., From Headache, The Newsletter of ACHE, 2002, vol 13, no. 3. Available at: www.achenet.org