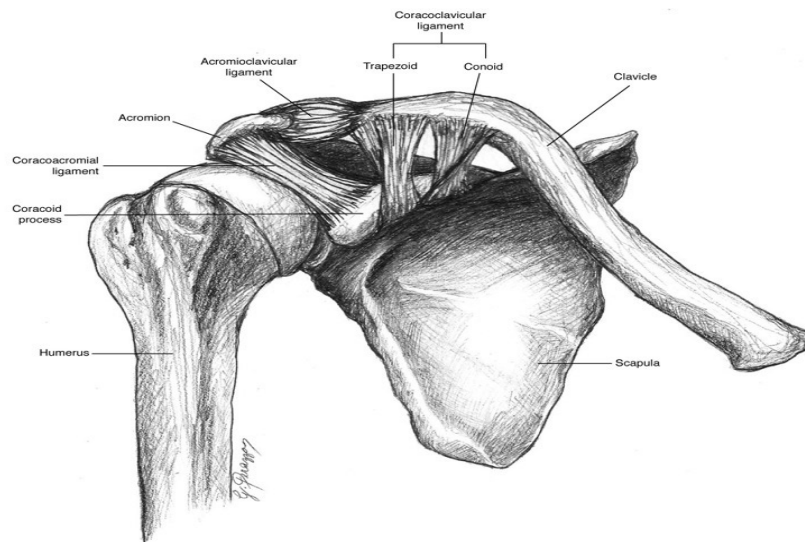


CHARLES UNIVERSITY
FACULTY OF PHYSICAL EDUCATION AND SPORTS
DEPARTMENT OF PHYSIOTHERAPY

Case study of a patient with diagnosis omarthrosis and rupture of rotator cuff muscles



Student name: Savvas Kapiris

Supervisor: Mgr. Ivana Jelínková

Prague 2013

Abstract

Creator: Savvas Kapiris

Title: Case study of a patient with diagnosis omarthrosis and rupture of rotator cuff muscles

Supervisor: Mrg Ivana Jelinkova

Supervisor in hospital: Mgr Zaher el Ali

Target: In this thesis I record the theoretical part of the patient's diagnosis and operation, all the examinations perform in order to create the correct therapeutic plan and lastly the therapeutic approach that was selected to treat patients combined pathological condition.

Methothology: The study includes three parts which analytically narrate all the information about this patient's case. The introduction, Part 2 where I describe the anatomy of the shoulder gridle, specifically skin, fascia, muscle, joint, ligament and bones. Also in the same part, is included the operating technique which was used for the surgery and the theory about the diagnosis and operation. Finally Part 3, where I record the examinations that were performed in the clinical practice, the day to day therapy, the result of the therapy.

Abstrakt

Autor: Savvas Kapiris

Název Případová studie pacienta s diagnózou Omartrosis a ruptura svalů rotátorové manžety

Supervisor: Mgr. Ivana Jelínková

Supervisor v nemocnici: Mgr. Zaher el Ali

Cíl práce: Zaznamenat základní informace o dané diagnóze, operačním přístupu, provést vyšetření a na jeho základě sestavit terapeutický plán, provést terapii dle stavu pacienta.

Metodologie: Práce zahrnuje tři části pojednávající o diagnóze pacienta. Po úvodu navazuje druhá část, kde popisují anatomii pletence ramenního obzvláště kůži, facie, svaly, klouby, ligamenta a kosti. Ve stejné části práce uvádím operační techniku, která byla použita a teorii o dané diagnóze. Třetí část práce zahrnuje vyšetření pacienta, jeho terapii a výsledek terapie.

INDEX

1. Introduction	p.3
2. Theoretical part	p.4
2.1 Anatomy of the shoulder	p.4
2.1.1 Skin.....	p.4
2.1.2 Brachial fascia	p.4
2.1.3 Muscles.....	p.4
2.1.4 Joints	p.8
2.1.5 Ligaments	p.9
2.1.6 Bones.....	p.12
2.2 About the diagnosis.....	p.14
3. Special part.....	p.20
3.1. Methods.....	p.20
3.2 Anamnesis	p.20
3.2.1 Examined person	p.20
3.2.2 Status present.....	p.20
3.2.3 Prior rehabilitation.....	p.21
3.2.4 RHB indications	p.21
3.2.5 Differential balance	p.21
3.3 Examination by physiotherapist	p.21
3.3.1 Observation	p.21
3.3.2 Dynamic tests	p.22
3.3.3 Range of Motion Evaluation	p.22
3.3.4 Gait Examination.....	p.23
3.3.5 Muscle Strength Test.....	p.23
3.3.6 Length test.....	p.24
3.3.7 Hypermobility test.....	p.24
3.3.8 Movement pattern test.....	p.24
3.3.9 Palpation.....	p.25
3.3.10 Joint Play Examination.....	p.25
3.3.11 Neurological Examination.....	p.26
3.3.12 Other tests.....	p.26
3.3.13 Examination's conclusion	p.26
3.4 Therapy.....	p.27
3.4.1 Goal of therapy.....	p.27

3.4.1.1 Proposed therapy	p.27
3.4.1.2 Short- term plan.....	p.27
3.4.1.3 Self-therapy	p.27
3.4.2 Day to day therapy	p.28
3.4.2.1 Day one	p.28
3.4.2.2 Day- two	p.28
3.4.2.3 Day- three.....	p.29
3.4.2.4 Day- four	p.29
3.4.2.5 Day- five.....	p.30
3.4.3 Control examinations	p.31
3.4.3.1 Observation	p.31
3.4.3.2 Dynamic tests	p.31
3.4.3.3 Range of motion evaluation	p.31
3.4.3.4 Gait examination	p.31
3.4.3.5 Muscle strength test.....	p.32
3.4.3.6 Length test	p.32
3.4.3.7 Hypermobility test.....	p.32
3.4.3.8 Movement pattern test.....	p.33
3.4.3.9 Palpation.....	p.33
3.4.3.10 Joint play examination	p.33
3.4.3.11 Neurological examination	p.34
3.4.3.12 Other tests.....	p.34
3.4.3.13 Conclusion of control examination	p.34
3.5 Result of therapy	p.34
3.5.1 Long-term plan.....	p.34
3.5.2 Prognosis	p.34
4. Conclusion.....	p.35
5 Attachments.....	p.36
5.1 Approval of the ethics committee	p.36
5.2 Consent of the patient.....	p.37
5.3 The list of pictures.....	p.38
5.4 The list of table's.....	p.38
6. Literature	p.39

1. Introduction

Attending a two- week clinical therapy course in I encountered several cases in the rehabilitation department. The case which attracted my attention was an elderly man who suffered from rapture in the muscle infraspinatus along omarthrosis in the shoulder joint. In my opinion this was a special case due to the combination of the above. After the surgery, I undertook the postoperative therapy in cooperation with my supervisor.

The following study includes two parts which analytically narrate every information about this patient's case. In Part 2, I describe the anatomy of the shoulder gridle, specifically skin, fascia, muscle, joint, ligament and bones. Also in the same part, is included the operating technique which was used for the surgery and the theory about the diagnosis. The operating technique was the usual one used in patients of this age with the similar problem. In Part 3, I record the examinations that were performed in the clinical practice, the day to day therapy, the result of the therapy.

After fulfilling the clinical practice we agreed with my supervisor that the therapy was effective. To sum up, the patient confirmed the success of the therapy.

2. Theoretical part

2.1 Anatomy of the shoulder

2.1.1 Skin

The blood supply to the skin of the upper extremity can be divided in three parts with separate supply. The deltoid region is supplied by the posterior circumflex humeral artery. The medial side of the upper arm is supplied by five or six fasciocutaneous perforators. The lateral side of the upper arm below deltoid is supplied by perforating vessels from the middle collateral and radial collateral arteries. The skin of the shoulder region is supplied by the supraclavicular nerves from the cervical plexus.

2.1.2 Brachial fascia

Brachial fascia, the deep fascia of the upper arm, is continuous with the fascia covering deltoid and pectoralis major: it forms a thin, loose sheath for muscles of the upper arm. It is thin over biceps, but thicker over triceps and the humeral epicondyles, and is strengthened by fibrous aponeuroses from pectoralis major and latissimus dorsi medially and from deltoid laterally.

2.1.3 Muscles

- **Coracobrachialis**

The coracobrachialis originates from the apex of the coracoid process, together with the tendon of the short head of biceps. One or more branches from the axillary artery pass deep to the lateral root of the median nerve, and the musculocutaneous nerve, to reach the deep surface of the muscle. Coracobrachialis is innervated by the musculocutaneous nerve, C5, C6 and C7.

- **Biceps brachii**

The biceps brachii derives its name from its two proximally attached 'heads'. The short head arises by a thick flattened tendon from the coracoid apex, together with coracobrachialis. The long head starts within the capsule of the shoulder joint as a long narrow tendon, running from the supraglenoid tubercle of the scapula at the apex of the glenoidal cavity, where it is continuous with the glenoidal labrum. The two tendons lead into elongated bellies. At the elbow joint they end in a flattened tendon,

which is attached to the rough posterior area of the radial tuberosity. Biceps brachii is supplied by up to eight vessels originating from the brachial artery in the middle third of the arm. Biceps brachii is innervated by the musculocutaneous nerve, C5 and C6, with separate branches passing to each.

- **Pectoralis major**

The pectoralis major is a thick, fan-shaped muscle. It arises from the anterior surface of the sternal half of the clavicle; half the breadth of the anterior surface of the sternum down to the level of the sixth or seventh costal cartilage and the aponeurosis of external oblique. The clavicular fibres are usually separated from the sternal fibres by a slight gap. The muscle converges to a flat tendon, approximately 5 cm across, which is attached to the lateral lip of the intertubercular sulcus of the humerus. Fibres from the sternum and aponeurosis curve around the lower border, turning successively behind those above them, which means that this part of the muscle is twisted so that the fibres that are lowest at their medial origin are highest at their insertion on the humerus. The rounded lower border of the muscle forms the anterior axillary fold, and becomes conspicuous in abduction against resistance. Pectoralis major is supplied by one dominant vascular pedicle from the pectoral branch of the thoraco-acromial axis. Pectoralis major is supplied through the medial and lateral pectoral nerves. Fibres for the clavicular part are from C5 and C6 those for the sternocostal part are from C6, C7, C8, and T1.

- **Pectoralis minor**

The pectoralis minor is a thin, triangular muscle lying posterior to pectoralis major. It arises from the upper margins and outer surfaces of the third to fifth ribs, near their cartilages, and from the fascia over the adjoining external intercostal muscles. Its fibres ascend laterally under cover of pectoralis major, converging in a flat tendon which is attached to the medial border and upper surface of the coracoid process of the scapula. Pectoralis minor is supplied by pectoral and deltoid branches of the thoraco-acromial and superior and lateral thoracic arteries. Pectoralis minor is innervated by branches of the medial and lateral pectoral nerves, C5, C6, C7, C8 and T1.

- **Trapezius**

The trapezius is a flat, triangular muscle which extends over the back of the neck and upper thorax. The lateral angles occur at the shoulder tips, the superior angle at the occipital protuberance and superior nuchal lines, and the inferior angle at the spine of the twelfth thoracic vertebra. On either side, the muscle is attached to the medial third of the superior nuchal line, external occipital protuberance, ligamentum nuchae, and

apices of the spinous processes and their supraspinous ligaments from C7 to T12. Superior fibres descend, inferior fibres ascend, and the fibres between them proceed horizontally: all come together laterally on the shoulder. The superior fibres are attached to the posterior border of the lateral third of the clavicle; the middle fibres to the medial acromial margin and superior lip of the crest of the scapular spine; and the inferior fibres pass into an aponeurosis which glides over a smooth triangular surface at the medial end of the scapular spine and is attached to a tubercle at its lateral apex. The upper third of trapezius is supplied by a transverse muscular branch which arises from the occipital artery at the level of the mastoid process. The middle portion of trapezius is supplied by the superficial cervical artery. The lower third of trapezius is supplied by a muscular branch from the dorsal scapular artery. Trapezius is innervated by the spinal part of the accessory nerve. Sensory branches are derived from the ventral rami of C3 and C4.

- **Deltoid**

The deltoid is a thick, curved triangle of muscle. It arises from the anterior border and superior surface of the lateral third of the clavicle, the lateral margin and superior surface of the acromion, and the lower edge of the crest of the scapular. The fibres converge inferiorly to a short, substantial tendon which is attached to the deltoid tubercle on the lateral aspect of the midshaft of the humerus. Anterior and posterior fibres converge directly to this tendon. Deltoid is supplied by acromial and deltoid branches of the thoraco-acromial artery; the anterior and posterior circumflex humeral arteries; subscapular artery; and the deltoid branch of profunda brachii. Deltoid is innervated by the axillary nerve, C5 and C6.

- **Levator scapulae**

The levator scapulae is attached by tendinous slips to the transverse processes of the atlas and axis, and to the posterior tubercles of the transverse processes of the third and fourth cervical. It descends diagonally to approach the medial scapular border between its superior angle and the triangular smooth surface at the medial end of the scapular spine. Levator scapulae receives its arterial supply mainly from the transverse cervical and ascending cervical arteries. Levator scapulae is innervated directly by branches of the third and fourth cervical spinal nerves, and from the fifth cervical nerve via the dorsal scapular nerve.

- **Rhomboid major and Rhomboid minor**

Rhomboid major is a quadrilateral sheet of muscle which arises by tendinous fibres from the spines and supraspinous ligaments of the second to fifth thoracic vertebrae,

and descends laterally to the medial border of the scapula between the root of the spine and the inferior angle. The rhomboid minor is a small, cylindrical muscle. It runs from the lower ligamentum nuchae and the spines of the seventh cervical and first thoracic vertebrae to the base of a smooth triangular surface at the medial end of the spine of the scapula. Rhomboid minor is usually separate from rhomboid major, but the muscles overlap and are occasionally united. Rhomboids major and minor are supplied by the dorsal scapular artery or deep branch of the transverse cervical artery and by dorsal perforating branches from the upper five or six posterior intercostal arteries. Rhomboids major and minor are innervated by a branch of the dorsal scapular nerve, C4, C5.

- **Latissimus dorsi**

The latissimus dorsi is a large, flat, triangular muscle that sweeps over the lumbar region and lower thorax and converges to a narrow tendon. It arises by tendinous fibres from the spines of the lower six thoracic vertebrae anterior to trapezius; from the posterior layer of thoracolumbar fascia, by which it is attached to the spines and supraspinous ligaments of the lumbar and sacral vertebrae; and from the posterior part of the iliac crest. It also springs by muscular fibres from the posterior part of the iliac crest lateral to erector spinae, and by fleshy slips from the three or four lower ribs, interdigitating with external oblique. From this attachment, fibres pass laterally to form a sheet approximately 12 or 13 mm thick that overlaps the inferior scapular angle. The muscle curves around the inferolateral border of teres major to gain its anterior surface. Here it ends as a flattened tendon, approximately 7 cm long, in front of the tendon of teres major. It is attached to the floor of the intertubercular sulcus of the humerus, with an expansion to the deep fascia. Latissimus dorsi is supplied by a single dominant vascular pedicle, the thoracodorsal artery, itself a continuation of the subscapular artery. Latissimus dorsi is supplied by the thoracodorsal nerve, from the posterior cord of the brachial plexus, C6, C7 and C8.

- **Serratus anterior**

The serratus anterior is a large muscular sheet which curves around the thorax. It arises from an extensive costal attachment and inserts on the scapula. Its fibres spread anteriorly from the outer surfaces and superior borders of the upper eight, nine or even ten ribs, and from fasciae which cover the intervening intercostals. They lay on a long, slightly curved, line which passes inferolaterally across the thorax. The first digitations spring from the first and second ribs and intercostal fascia, the others from a single rib, and the lower four interdigitate with the upper five slips of external

oblique. The muscle follows the contour of the chest wall closely. It passes ventral to the scapula and reaches the medial border of the scapula in the following way. Serratus anterior is supplied by superior and lateral thoracic arteries, and branches from the thoracodorsal artery. Serratus anterior is innervated by the long thoracic nerve, C5, C6 and C7.

- **Supraspinatus**

The supraspinatus arises from the medial two-thirds of the supraspinous fossa and from the supraspinous fascia. The fibres converge, under the acromion, into a tendon which crosses above the shoulder joint and is attached to the highest facet of the greater tubercle of the humerus. The tendon blends into the articular capsule and may give a slip to the tendon of pectoralis major. Supraspinatus is supplied by the suprascapular and dorsal scapular arteries. Supraspinatus is innervated by the suprascapular nerve, C5 and C6.

- **Infraspinatus**

The infraspinatus is a thick triangular muscle which occupies most of the infraspinous fossa. It arises by muscular fibres from the medial two-thirds of the fossa, by tendinous fibres from ridges on its surface and from the deep surface of the infraspinous fascia, which separates it from teres major and minor. Its fibres converge to a tendon which glides under the lateral border of the spine of the scapula, and then passes across the posterior aspect of the capsule of the shoulder joint to be attached to the middle facet on the greater tubercle of the humerus. Infraspinatus is supplied by the suprascapular and circumflex scapular arteries. Infraspinatus is innervated by the suprascapular nerve, C5 and C6.

- **Subscapularis**

The subscapularis is a bulky, triangular muscle which fills the subscapular fossa. The fibres converge laterally into a broad tendon which is attached to the lesser tubercle of the humerus and the front of the articular capsule. The tendon is separated from the neck of the scapula by the large subscapular bursa, which communicates with the shoulder joint. Subscapularis is supplied by small branches from the suprascapular, axillary and subscapular arteries. Subscapularis is innervated by the upper and lower subscapular nerves, C5 and C6.

- **Teres major**

The teres major is a thick, flat muscle which arises from the oval area on the dorsal surface of the inferior scapular angle, and from the fibrous septa interposed between the muscle and teres minor and infraspinatu. The tendon lies behind that of latissimus

dorsi, from which it is separated by a bursa; the tendons are united along their lower borders for a short distance. Teres major is supplied by the thoracodorsal branch of the subscapular artery on its way to latissimus dorsi and by the posterior circumflex humeral artery. Teres major is innervated by the lower subscapular nerve, C5, C6 and C7.

- **Teres minor**

The teres minor is an elongated muscle which arises from the upper two-thirds of a flattened strip on the dorsal surface of the scapula. It runs upwards and laterally. The upper fibres end in a tendon attached to the lowest facet on the greater tubercle of the humerus. The lower fibres are attached directly into the humerus distal to this facet and above the origin of the lateral head of triceps. The tendon passes across, and blends with, the lower posterior surface of the capsule of the shoulder joint. Teres minor is supplied by the circumflex scapular artery, which pierces the origin of the muscle as it turns upward in the infraspinous fossa, and by the posterior circumflex humeral artery. Teres minor is innervated by the axillary nerve, C5 and C6.

- **Triceps**

The long head arises by a flattened tendon from the infraglenoid tubercle of the scapula, blending above with the glenohumeral capsule. Its muscular fibres descend medial to the lateral head and superficial to the medial head, and join them to form a common tendon. The lateral head arises by a flattened tendon from a narrow, linear, oblique ridge on the posterior surface of the humeral shaft, and from the lateral intermuscular septum. The blood supply to triceps is mainly from the profunda brachii artery and the superior ulnar collateral artery, with an accessory supply from the posterior circumflex humeral artery. Triceps is innervated by the radial nerve, C6, C7 and C8, with separate branches for each head.

2.1.4 Joints

- **Glenohumeral joint**

The glenohumeral joint is a synovial multiaxial spheroidal joint between the roughly hemispherical head of the humerus and the shallow glenoid fossa of the scapula. It is the most mobile joint in the body and the most frequently dislocated. The area of the humeral convexity exceeds that of the glenoid concavity such that only a small portion opposes the glenoid in any position. The remaining capitular articular surface is in contact with the capsule, so that contact on the glenoid fossa is much more uniformly

distributed over its entire articular surface. Both articular surfaces are covered by hyaline cartilage, which is thickest centrally and thinner peripherally over the humerus, and the reverse in the glenoid cavity. The glenoid labrum is a fibrocartilaginous rim around the glenoid fossa. A fibrous capsule envelops the joint. It is attached medially to the glenoid neck outside the glenoid labrum, and encroaches on the coracoid process to include the attachment of the long head of biceps. The fibrous capsule is supported by the tendons of supraspinatus, infraspinatus and teres minor, subscapularis and by the long head of triceps.

- **Acromioclavicular joint**

The acromioclavicular joint is a synovial plane joint. The articulating surfaces are between the acromial end of the clavicle and the medial acromial margin. The joint is approximately plane, but either surface may be slightly convex, the other being reciprocally concave, and both are covered by fibrocartilage. The clavicular surface is a narrow, oval area which faces inferolaterally and overlaps a corresponding facet on the medial acromial border. The long axis is anteroposterior. The capsule completely surrounds the articular margins and is strengthened above by the acromioclavicular ligament. The capsule is lined by synovial membrane.

- **Sternoclavicular joint**

The sternoclavicular articulation is a double arthrodiar joint. The parts entering into its formation are the sternal end of the clavicle, the upper and lateral part of the manubrium sterni, and the cartilage of the first rib. The articular surface of the clavicle is much larger than that of the sternum, and is invested with a layer of cartilage, which is considerably thicker than that on the latter bone

- **Scapulothoracic joint**

The scapulothoracic joint is not a true synovial joint. Rather, the scapulothoracic articulation is formed by the convex surface of the posterior thoracic cage and the concave surface of the anterior scapula. The scapula is a flat bone, with the gliding surfaces formed by the subscapularis and the serratus anterior. The scapula is attached to the axial skeleton through the acromioclavicular joint and the sternoclavicular joint. The scapulothoracic articulation allows for increased shoulder elevation.

2.1.5 Ligaments

- **Glenohumeral ligaments**

Three glenohumeral ligaments, only visible from within the joint, reinforce the capsule anteriorly and inferiorly. The superior glenohumeral ligament passes from the supraglenoid tubercle, just anterior to the origin of the long head of biceps, to the humerus near the proximal tip of the lesser tubercle on the medial ridge of the intertuberculous groove, the fovea capitis. It forms an anterior cover around the long head of biceps, and is part of the rotator interval. Together with the coracohumeral ligament it is an important stabilizer in the inferior direction. The middle glenohumeral ligament arises from a wide attachment below the superior glenohumeral ligament, along the anterior glenoid margin as far as the inferior third of the rim, and passes obliquely inferolaterally to attach to the lesser tubercle deep to the tendon of subscapularis, with which it blends. The thicker and longer inferior glenohumeral ligament arises from the anterior, middle and posterior margins of the glenoid labrum, below the epiphysial line, and passes anteroinferiorly to the inferior and medial aspects of the neck of the humerus.

- **Coracohumeral ligament**

The coracohumeral ligament is attached to the dorsolateral base of the coracoid process and extends as two bands, which blend with the capsule, to the greater and lesser tubercles. Portions of the coracohumeral ligament form a tunnel for the biceps tendon on the anterior side of the joint. The rotator interval is reinforced by the coracohumeral ligament. It also blends inferiorly with the superior glenohumeral ligament.

- **Transverse humeral ligament**

The transverse humeral ligament is a broad band which passes between the humeral tubercles, and is attached superior to the epiphysial line. It converts the intertubercular sulcus into a canal, and acts as a retinaculum for the long tendon of biceps.

- **Synovial membrane**

The synovial membrane lines the capsule and covers parts of the anatomical neck. The long tendon of biceps traverses the joint in a synovial sheath which continues into the intertubercular sulcus as far as the surgical neck of the humerus.

- **Coracoacromial ligament**

The coracoacromial ligament is a strong triangular band between the coracoid process and acromion. It is attached apically to the acromion anterior to its clavicular articular surface and by its base along the whole lateral border of the coracoid.

- **Superior transverse scapular ligament**

The superior transverse scapular ligament converts the scapular notch into a foramen. A flat fasciculus, it narrows towards its attachments to the base of the coracoid process and medial side of the scapular notch. The suprascapular nerve traverses the foramen and the suprascapular vessels cross above the ligament.

- **Inferior transverse scapular ligament**

The inferior transverse scapular ligament is a membranous ligament which may stretch from the lateral border of the spine of the scapula to the glenoid margin. It forms an arch over the suprascapular nerve and vessels entering the infraspinous fossa.

- **Acromioclavicular ligament**

The acromioclavicular ligament is quadrilateral. It extends between the upper aspects of the lateral end of the clavicle and the adjoining acromion. Its parallel fibres interlace with the aponeuroses of trapezius and deltoid.

- **Coracoclavicular ligament**

The coracoclavicular ligament connects the clavicle and the coracoid process of the scapula. Though separate from the acromioclavicular joint, it is a most efficient accessory ligament, and maintains the apposition of the clavicle to the acromion. The trapezoid and conoid parts of the ligament, usually separated, connect the medial horizontal part of the coracoid process and lateral end of the subclavian groove of the clavicle.

- **Articular disc**

The articular disc often occurs in the upper part of the joint, partially separating the articular surfaces: occasionally it completely divides the joint.

2.1.6 Bones

- **Clavicle**

The clavicle lies almost horizontally at the root of the neck and is subcutaneous throughout its whole extent. It braces back the shoulder and enables the limb to swing clear of the trunk and transmits part of the weight of the limb to the skeleton. The lateral or acromial end of the bone is flattened and articulates with the medial side of the acromion, whereas the medial or sternal end is enlarged and articulates with the clavicular notch of the manubrium sterni and first costal cartilage. The shaft is gently curved and in shape resembles the italic letter f, being convex forwards in its medial

two-thirds and concave forwards in its lateral third. The inferior aspect of the intermediate third is grooved in its long axis. Although elongated, the clavicle is unlike typical long bones in that it usually has no medullary cavity. A small oval articular facet, for articulation with the medial aspect of the acromion, faces laterally and slightly downwards at the lateral end of the shaft.

- **Scapula**

The scapula is a large, flat, triangular bone which lies on the posterolateral aspect of the chest wall, covering parts of the second to seventh ribs. It has costal and dorsal surfaces, superior, lateral and medial borders, inferior, superior and lateral angles, and three processes, the spine, its continuation the acromion and the coracoid process. The lateral angle bears the glenoid cavity for articulation with the head of the humerus. The central supraspinous fossa and the greater part of the infraspinous fossa are thin and even translucent and the gaps are filled by fibrous tissue. The inferior angle lies over the seventh rib, or over the seventh intercostal space. The superior angle is placed at the junction of the superior and medial borders, and is obscured by the muscles which cover it. The lateral angle is truncated and broadened. It constitutes the head of the bone. On its free surface it bears the glenoid cavity for articulation with the head of the humerus in the shoulder joint. Very gently hollowed out, the glenoid forms a poor socket for the humeral head. It is narrow above and wider below, and is pear-shaped in outline. Immediately above the glenoid cavity a small, roughened area encroaches on the root of the coracoid process and is termed the supraglenoid tubercle. Ventrally, it can be regarded as extending between the infraglenoid tubercle and the anterior margin of the suprascapular notch. The costal surface, which is directed medially and forwards when the arm is by the side, is slightly hollowed out, especially in its upper part.

- **Acromion**

The acromion projects forwards, almost at right angles, from the lateral end of the spine, with which it is continuous. The lower border of the crest of the spine becomes continuous with the lateral border of the acromion at the acromial angle, which forms a subcutaneous, bony landmark. The medial border of the acromion is short and is marked anteriorly by a small, oval facet, directed upwards and medially, for articulation with the lateral end of the clavicle. The acromion is subcutaneous over its dorsal surface, being covered only by the skin and superficial fascia. The lateral border, which is thick and irregular, and the tip of the process, as far round as the clavicular facet, give origin to the middle fibres of deltoid. The medial aspect of the

tip gives attachment, below the deltoid, to the lateral end of the coraco-acromial ligament. The articular capsule of the acromioclavicular joint is attached around the margins of the clavicular facet. Behind the facet, the medial border of the acromion gives insertion to the horizontal fibres of the trapezius. The inferior aspect of the acromion is relatively smooth, and together with the coraco-acromial ligament and the coracoid process forms a protective arch over the shoulder joint. The tendon of the supraspinatus passes below the overhanging acromion and is separated from it and from the deltoid by the subacromial bursa.

- **Coracoid process**

The coracoid process arises from the upper border of the head of the scapula and is bent sharply so as to project forwards and slightly laterally. The coracoid process lies about 2.5 cm below the clavicle at the junction of the lateral fourth with the rest of the bone and is connected to its under surface by the coracoclavicular ligament. The pectoralis minor is attached to the superior aspect of the coracoid process. The wider, medial end of the coraco-acromial ligament and below that, the coracohumeral ligament, are attached to the lateral border. The coracobrachialis is attached to the medial side of the tip of the process, and the short head of biceps is attached to the lateral side of the tip. The inferior aspect of the process is smooth and helps to complete the coraco-acromial arch.

- **Humerus**

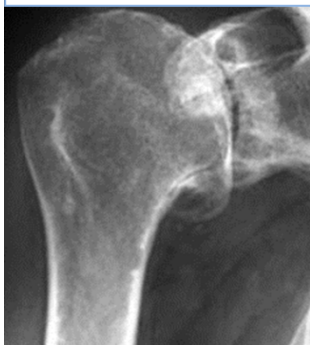The humerus, the longest and largest bone in the upper limb, has expanded ends and a shaft. The rounded head occupies the proximal and medial part of the upper end of the bone and forms an enarthrodial articulation with the glenoid cavity of the scapula. The lesser tubercle projects from the front of the shaft, close to the head, and is limited on its lateral side by a well-marked groove. The proximal end of the humerus consists of the head, anatomical neck and the greater and lesser tubercles. It joins the shaft at the 'surgical neck', which is closely related on its medial side to the axillary nerve and posterior humeral circumflex artery. The head of the humerus forms rather less than half a spheroid. Its smooth articular surface is covered with hyaline cartilage, which is thicker centrally. Medially, the capsular attachment diverges from the anatomical neck and descends 1 cm or more onto the shaft. The lesser tubercle is anterior to and just beyond the anatomical neck. It has a smooth, muscular impression on its upper part palpable through the thickness of deltoid 3 cm below the acromial apex. The lateral edge of the lesser tubercle is sharp and forms the medial border of the intertubercular sulcus. The subscapularis is attached to the lesser tubercle, and the transverse ligament

of the shoulder joint is attached to the lateral margin. The greater tubercle is the most lateral part of the proximal end of the humerus. It projects beyond the lateral border of the acromion. Its posterosuperior aspect, near the anatomical neck, bears three smooth flattened impressions for the attachment of the supraspinatus, infraspinatus and the teres minor. The attachments of the subscapularis and teres minor are not confined to their respective tubercles, but extend for varying distances on to the adjacent metaphysis. The intertubercular sulcus lies between the tubercles. It contains the long tendon of biceps, its synovial sheath, and an ascending branch from the anterior circumflex humeral artery. The rough lateral lip of the groove is marked by the bilaminar tendon of the pectoralis major, its floor by the tendon of latissimus dorsi and its medial lip by the tendon. (Gray, 1918)

2.2 About the diagnosis

In healthy shoulder joints the joint cartilage forms a smooth surface and thus protects the joint surfaces against friction. In the case of omarthrosis however, the joint cartilage firstly loses its elasticity, the surface of the cartilage becomes rough in those areas subject to the greatest loads. The bony surfaces of the joint now rub against each other which can ultimately result in deformation of the humeral head and glenoid cavity. If the joint surfaces rub against each other without the protective layer of cartilage, this will result in pain which is increasingly experienced when the joint is not loaded, particularly at night. Many patients complain about sensitivity to cold and scraping and rubbing inside the shoulder. In addition, the shoulder joint loses its mobility, until it stiffens completely. As a result of this, patients adopt a relieving posture, which in turn causes muscle tension and pain in other regions of the body such as the neck or back. (Wulker, 2000)

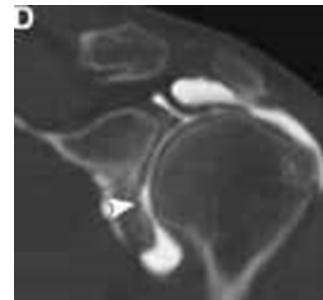
Figure 1: Omarthrosis.
Source: www.schulter.de



Rotator cuff tear arthropathy is a condition that compromises the comfort and function of the shoulder. This condition is characterized by the permanent loss of the rotator cuff tendons and the normal surface of the shoulder joint. These tissues cannot be restored to their normal condition and the lost comfort and function of the shoulder cannot be totally regained. However in the hands of an experienced surgeon and in a well-motivated individual shoulder replacement surgery with a cuff tear arthropathy head prosthesis along with post-surgical rehabilitation can help

restore comfort and function to shoulders damaged by cuff tear arthropathy. (Winston & Frederick, 2013)

Patients with rotator cuff tear, feel pain performing overhead activities and lifting their arm to the side. Pain is more likely in the front of the shoulder and may radiate to the side of the arm. At first, this pain may be mild and occur only with certain movements of the arm. Over time, pain may be present at rest or at night, especially when lying on the affected shoulder. Patients often have weakness and loss of motion when raising the arm above your head. It may become more difficult to place the arm behind their back. The pain with a sudden tear after a fall or injury is usually intense. Symptoms of a chronic rotator cuff tear include a gradual worsening of pain, weakness, and stiffness or loss of motion. The exact point when a rotator cuff tear begins in someone with chronic shoulder tendinitis may or may not be noticed. Most people with rotator cuff tendon tears have pain at night. During the day, the pain is more tolerable and hurts with certain movements. A physical examination may reveal tenderness over the shoulder. X-rays of the shoulder may show a bone spur. An ultrasound test uses sound waves to create an image of the shoulder joint. MRI of the shoulder may show swelling or a tear in the rotator cuff. A special imaging test called arthrography is needed to diagnose a rotator cuff tear. (Burbank & Stevenson, 2008)



The rotator cuff is essential for normal function and strength of the shoulder. Ruptures of the rotator cuff reduce the strength of the joint and lead to arthritis. It is therefore logical to attempt to repair them. The rotator cuff ensures that the head of the humerus is centred in relation to the glenoid. Weakening of the cuff muscles would predispose to subacromial impingement during elevation of the arm and further mechanical irritation to the site of the lesion. Rotator cuff strengthening is, therefore, an important part of the treatment program in any shoulder lesion. However, if recent or repeated steroid injections of the tendon have been performed, a gradually strengthening program should be taken into account. While local steroids do relieve the pain through inhibiting the inflammatory response, they have an antianabolic effect on connective tissue, which may result in structural weakening of the injected tendon. Reconstructive surgery must use techniques which include the reinsertion of healthy tendon without tension with healthy or reinforced muscle. Surgery to repair a torn rotator cuff most often involves re-attaching the tendon to the head of humerus. A partial tear, however, may need only a trimming or smoothing procedure called a debridement. (Lin, 2010)

Figure 2: Rapture of infraspinatus.
Source: www.78steps.com

As it is recorded previously in Part 2.1, the tendons of the rotator cuff pass underneath a bony area on their way to attaching the top part of the arm bone. When these tendons become inflamed and the presence of a bone spur may narrow the space even more. This problem is called rotator cuff tendinitis, or impingement syndrome, and may be due to:

1. Keeping the arm in the same position for long periods of time.
2. Sleeping on the same arm each night.
3. Playing sports requiring the arm to be moved over the head repeatedly.
4. Poor control or coordination of your shoulder and shoulder blade muscles.
5. Poor posture over many years and the usual fraying of the tendons that occurs with age may also lead to rotator cuff tendinitis. (Greiwe & Ahmad, 2008)



Figure 3: Impingement of shoulder.
Source: www.raycrowe.com

Treatment of impingement involves resting the shoulder and avoiding activities that cause pain. It may involve:

1. Ice packs applied 20 minutes at a time, 3 - 4 times a day to the shoulder can relieve pain.
2. Nonsteroidal anti-inflammatory drugs (NSAIDS) to help reduce swelling and pain.
3. Sport and job modifications may be beneficial.
4. Start physical therapy to learn exercises to stretch and strengthen the muscles of your rotator cuff and scapula stabilizers.
5. If the pain persists or if therapy is not possible because of severe pain, a steroid injection may reduce pain and swelling in the injured tendons, to allow effective therapy.
6. A sling is never used, because adhesive capsulitis can result from immobilization. (Allen, 1998)
7. The weighted pendulum stretching exercise performs two functions. Gently stretches the space in which the tendons pass to relieve pressure on the tendons and also prevents the development of a frozen shoulder. This exercise can be started almost immediately after a shoulder injury, or after receiving a steroid injection into the shoulder joint. This exercise should be performed after heating for five minutes once or twice per day. (Anderson, B.)

In a research done by A. Santamato patients with subacromial impingement syndrome into two groups and treated for two weeks. Half the group received high-intensity laser

therapy to the soft tissues of the shoulder for five days each week. The other half had continuous ultrasound for 10 minutes over the shoulder joint. Ultrasound is a way to heat the tissues deep in the shoulder to bring blood circulation to the area for healing. Findings support that ultrasound is not more effective than a placebo in treating subacromial impingement syndrome and that high-intensity laser is more beneficial than a placebo for this condition. (Santamato, 2009)

A different way of treatment is the surgical approach. Arthroscopic surgery can remove inflamed tissue and part of the bone that lies over the rotator cuff. Removing the bone may relieve the pressure on the tendons. Most of the time, arthroscopic surgery can be used. Some large tears require open surgery to repair the torn tendon. A research was performed by Bang MD, Deyle GD to compare the effectiveness of 2 physical therapy treatment approaches for impingement syndrome of the shoulder. Manual physical therapy applied by experienced physical therapists combined with supervised exercise in a brief clinical trial is better than exercise alone for increasing strength, decreasing pain, and improving function in patients with shoulder impingement syndrome. Strength in the manual therapy group improved significantly while strength in the exercise group did not. Subjects in both groups experienced significant decreases in pain and increases in function, but there was significantly more improvement in the manual therapy group compared to the exercise group. (Bang & Deyle, 2000)

Specifically, arthroscopical approach is the first choice for surgery that may be used to treat a rotator cuff injury if the rapture is very severe or if nonsurgical treatment has failed to improve shoulder strength and movement. But for patients who are usually over 60 years old with severe tears and/or have arthritis on the shoulder joint, orthopedic surgeons use a technique called arthroscopic smoothing. Subacromial smoothing

involves shaving bone or removing growths on the acromion. It also removes damaged tendon and bursa from the joint and from the fascia surrounding the muscle. The surgeon may also remove small amounts of bone from the underside of the acromion and the acromioclavicular joint. The goal is to decrease roughness while keeping as much of the normal supporting structures as possible. This surgery creates more room in the subacromial space so that the rotator cuff tendon is not pinched or irritated and can glide smoothly and with more freedom beneath the acromion. Subacromial smoothing, acromioplasty, and rotator

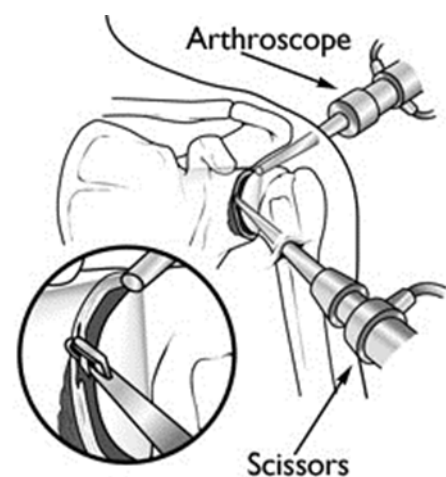


Figure 4: Arthroscopical operation.
Source: www.emedtravel.com

cuff repair may be done using arthroscopic surgery or open surgery. In our case, my patient had undergone the arthroscopic type. Arthroscopy uses a thin viewing scope called an arthroscope that is inserted into a joint through a small incision in the skin. Then the surgeon will remove loose fragments of tendon, bursa, and other debris from the shoulder a technic that is generally called debridement of shoulder. Other instruments are then arthroscopically inserted to shave the bone or remove growths. This type of surgery is usually done on general anesthesia during arthroscopy. As the operating doctor described they shaved anterolaterally, equalizing the surface of the bursae and the surface of the cuff and the anterior side of the acromion. (Devinney, 2005)

In a research done by Rockwood CA, Lyons FR, patients who had shoulder impingement syndrome were managed operatively with acromioplasty. One group who had an intact rotator cuff, had a modified acromioplasty, and the other group, who had a torn cuff, had a modified acromioplasty and repair of the cuff. In the classic anterior acromioplasty (Neer, 1972) emphasis is placed on resection of the inferior prominence of the acromion. This portion of the acromion continues to irritate the subacromial bursa and the rotator cuff and to produce symptoms of impingement. At the most recent follow-up visit, no difference in terms of pain and function was found between the patients who had had the modified acromioplasty only and the patients who had had the modified acromioplasty and repair of the rotator cuff result. (Rockwood & Lyons, 1993)

Based on a statistical analysis, the incidence of anterior acromioplasty increased over time ($p < 0.001$) with the crude rate of 3.3 per 100,000 in 1980 to 1985 to 19.0 per 100,000 in 2000 to 2005. Sex, age, and types of rotator cuff pathology did not significantly change over the twenty-six year period. There was a dramatic shift from use of the open to the arthroscopic approach over this time period ($p < 0.001$) and a decrease in the concomitant performance of distal clavicle resection ($p < 0.001$). The frequency of anterior acromioplasty has dramatically increased over time as mentioned earlier. Increasing knowledge about this syndrome, including better imaging, has facilitated patient treatment for a stable spectrum of rotator cuff pathology as has the application of endoscopic surgery (Yu, 2010).

Lastly, there is evidence of scapular kinematic alterations associated with shoulder impingement, rotator cuff tendinopathy, rotator cuff tears, glenohumeral instability, adhesive capsulitis, and stiff shoulders. There is also evidence for altered muscle activation in these patient populations, particularly, reduced serratus anterior and increased upper trapezius activation. Scapular kinematic alterations similar to those found in patient populations have been identified in subjects with a short rest length of the pectoralis minor, tight soft-tissue structures in the posterior shoulder region, excessive thoracic kyphosis, or with flexed

thoracic postures. This suggests that attention to these factors is warranted in the clinical evaluation and treatment of these patients. The available evidence in clinical trials supports the use of therapeutic exercise in rehabilitating these patients, while further gains in effectiveness should continue to be pursued (Ludewig & Reynolds, 2009).

Therefore the supervisors and I share the same opinion the patient operation needs a special rehabilitation programming because of the combined diagnoses. Our approach to the treatment was a combination of physical therapy, manual therapy and analytic exercises because as it is mentioned earlier these combined approaches have better results in all the rehabilitation parameters of the therapy plan.

3. Special part

3.1. Methods

Workplace: Centrum Léčby Pohybového Aparátu, s.r.o.

Date of the clinical practice: 22/4- 3/5 2013

General information about the clinical practice: In cooperation with the supervisor I chose to perform my clinical practice for my thesis on this particular patient because the diagnosis was interesting. We had five treatment sessions in which I collected enough information to fulfill my thesis.

3.2 Anamnesis

3.2.1 Examined person

Name of patient: N.F (man)

Date of birth: 1947

Diagnosis: Omarthrosis and rapture of rotator cuff muscles (M758)

3.2.2 Status present: The patient is a male three weeks after operation of debridement of right shoulder. He feels pain in some positions, especially ABD 90 and F 90, of his upper extremity and in some motions. He also admits that he feels pain during the night when he rolls over his right shoulder. In general he looks like he is in great condition, in a great mood, and is very anxious to get back to his daily activities soon.

Weight:	80 kg
Height:	1, 82 m
Body Mass Index:	24.4
Blood Pressure:	110/70 mmHg
Heart Rate:	75 bits/min

Table 1: Present status

Medical history: The medical history of the patient shows that the patient was diagnosed with gonarthrosis of his right knee and omarthrosis of the right shoulder on 15.08.2012. After that he has been in the hospital twice last year for control tests of his problems and conservative treatment. In his last session in 2012 he was indicated for operation of his right shoulder.

Family history: He is married and he lives with his wife, he has three children but none of them have similar problems like he does. Prior to his retirement he had worked in an office for a real estate company.

Abuses: The patient is a casual drinker.

Sport: The patient enjoys fencing and cycling.

3.2.3 Prior rehabilitation

He had undergone at least 6 sessions of mobilization and he was on medication for almost a year, mostly Diclofenac.

3.2.4 RHB indications

Pain in the right shoulder in the motions of ABD and F.

3.2.5 Differential balance

Upon further investigation it can be concluded that the patient feels pain in his right shoulder in the region of acromion because of the structural and functional causes. Firstly because from the arthrosis and the rupture and secondly from the immobilization from the pain that the rapture caused.

3.3 Examination by physiotherapist

The examinations performed are as follows:

- Observation
- Dynamic tests
- Range of motion evaluation
- Gait examination
- Muscle strength test
- Length test
- Hypermobility test
- Movement pattern test
- Palpation
- Joint play examination
- Neurological examination
- Other tests

3.3.1 Observation

In the postural examination the patient was observed from all four aspects and the findings were the following:

Anterior view: From this view it was easy to see that his head slightly deviated to the right, his left shoulder was higher, the thorocobrachial spaces looked even and hands were in neutral position and lastly his feet were in neutral position and his stance was too close.

Posterior view: From the posterior view it was easy to see once again that the head was slightly deviated to the right, his left shoulder was slightly higher, there was scoliosis on his thoracic spine to the right, the thorocobrachial spaces looked even once again and hands were in neutral position but from this view one could see a big inflammation on his right elbow and lastly his feet were in neutral position and his stance was too close.

Lateral view: From the lateral view one could see that the head was also slightly foreword, thoracic spine was also kcyphotic but in general his alignment was close to normal.

3.3.2 Dynamic tests

In the dynamic tests the patient's performance was observed in the following motions:

Flexion: Flexion of the trunk was possible, with good quality of movement and with good range of motion, reaching 10 cm above ground level.

Lateral flexion: Lateral flexion was also possible but limited, the motion was only initiated from the thoracic area and the patient reached 45 cm above ground to the right and to the left.

Extension: Extension was better, the range of motion was excessive and the quality of the movement was great.

3.3.3 Range of Motion Evaluation

On this evaluation the range of motion was measured in the patient upper extremity and the results were the following:

Motion	Right extremity	Left extremity	Comments
Shoulder flexion	180 degrees	180 degrees	Slight pain on the right when passing 90 degrees
Shoulder extension	15 degrees	15 degrees	No pain
Shoulder abduction	180 degrees	180 degrees	No pain
Shoulder horizontal abduction	90 degrees	90 degrees	No pain
Shoulder horizontal adduction	40 degrees	40 degrees	Pain on the right in the end of the motion
Shoulder internal rotation	50 degrees	75 degrees	Pain on the right in the end of the motion
Shoulder external rotation	90 degrees	90 degrees	No pain
Elbow flexion	120 degrees	125 degrees	No pain

Table 2: Range of motion evaluation

3.3.4 Gait Examination

During this examination the patient was instructed to walk up and down the room in different ways and try to see first if it was possible and secondly to try and detect any deviations from a normal gait cycle, the results were the following:

The gait was close to normal, only the feet were turned outward more to the left than to the right extremity on the swing phase and lastly the steps were small.

Heel walking, tip toe walking, and backward walking were all possible. (Sutherland, 2005)

3.3.5 Muscle Strength Test

On this test an examination of the strength of several of his muscles was conducted using Kendal muscle strength grading and the results were the following: (Kendall, 2005)

Muscle	Right side	Left side	Comments
Pectoralis major	5	5	Slight pain during test
Pectoralis minor	5	5	
Anterior deltoid	4	5	
Middle deltoid	4	5	Slight pain during test
Posterior deltoid	4	5	Slight pain during test
Supraspinatus	5	5	
Infraspinatus	4	5	Slight pain during test
Subscapularis	5	5	
Teres major	5	5	
Teres minor	4	5	
Latissimus dorsi	5	5	
Upper trapezius	5	5	
Middle trapezius	3	4	Slight pain during test
Lower trapezius	3	4	Slight pain during test
Rhomboid	3	4	Slight pain during test
Serratus anterior	4	4	

Table 3: Muscle strength test

3.3.6 Length test

On this test an attempt was made to detect muscle shortenings in several muscles and the results were the following:

Muscle	Right side	Left side
Pectoralis major	normal	normal
Sternocleidomastoid	normal	normal
Levator scapulae	limited	limited
Scalene	normal	normal
Trapezius	normal	limited

Table 4: Length test

3.3.7 Hypermobility test

On this test several motions were performed to detect if there was hypermobility and the results were as follows:

Scarf test	Hypermobility grade A	Bilaterally but with pain on the right side
Clasped elbows test	Hypermobility grade B	Bilaterally
Wrist flexors test	Hypermobility grade A	Bilaterally
Axillary test	No hypermobility	Bilaterally
Head rotation test	No hypermobility	Bilaterally
Trunk rotation test	No hypermobility	Bilaterally

Table 5: Hypermobility test

3.3.8 Movement pattern test

On this test certain movement patterns were tested as well as the detection of any deviations.

Shoulder abduction: The quality of the motion was good, the activity of the muscles were normal, only the range of motion on the right side was limited.

Push up: The motion was limited because of lack of strength, the quality was bad and there was pain in the anterior side of the shoulder during the test.

Neck flexion: The motion quality was good, the activation of the muscles and the range was also good.

3.3.9 Palpation

During this examination the patients skin, fascia, and scar tissue were examined and several muscles were also palpated to detect change in the muscle tones and the results were the following:

Skin and fascia around the shoulder, neck and back was a little stiff not only from the immobilization, but from the patient’s age as well. Scar tissue was soft and didn’t bother the patient at all.

Muscle	Right side	Left side	Comments
Trapezius	hypertonus	hypertonus	With pain in upper part
Rhomboid	hypertonus	normal	
Pectoralis minor	hypertonus	normal	
Pectoralis major	Normal	normal	
Deltoid	Normal	normal	
Infraspinatus	hypertonus	normal	Pain on the right
Supraspinatus	hypertonus	normal	Pain on the right
Teres major	Normal	normal	
Teres minor	hypertonus	normal	
Erector spinae	hypertonus	hypertonus	The hypertonicity was located in the lower part
Bicep	Normal	normal	
Triceps	Normal	normal	

Table 6: Palpation

3.3.10 Joint Play Examination

This test attempted to detect blockages in the joints of the patient and the results were the following: (Lewit, 2010)

Joint	Result
Glenoventrohumeral	Present
Caudal direction	Present
Dorsal direction	Present
Lateral direction	Present
Acromio clavicular cranio-caudal direction	Present but slight restricted on the right side on the cranial direction
Dorsal ventral direction	Present

Table 7: Joint play examination

3.3.11 Neurological Examination

This test checked deep tendon reflexes and the sensation of upper extremities and the results were the following:

Reflexes	Result
Triceps	present
Bicep	present
Wrist flexors	present

Table 8: Neurological examination

Sensation was present all the way down his upper extremities and the patient felt the touch everywhere in the same quality.

Notes: Almost all the examinations were able to be performed apart from some that irritated the patient due to pain of the operated shoulder.

3.3.12 Other tests

Trendelenburg test: On this test the patient was instructed to stand on one leg and elevate the other leg to 90 degrees and then check for deviations of the pelvis. The results were negative.

Romberg test: This test tested the patient's stability both with eyes open and closed. The results were negative.

Standing on two scales test: On this test the patient stood equally on two scales and checked the weight in each. The result was 40 kg to each leg.

Notes: The patient's performance on those last tests was great; his stability is very good probably caused by his good body condition and his fencing past.

3.3.13 Examination's conclusion

The conclusion of the examinations could be that despite the fact that the patient is in really good condition considering his age, strength, and function are compromised not only from his

age but from the injury and immobilization as well. Specifically, from the hypertonicity and shortness found in truck muscles and rotator cuff muscles, deviations from the ideal alignment were observed. Movement of the shoulder girdle was compromised in the motions of internal rotation, flexion and horizontal adduction. Strength on his shoulder and in intrascapular muscles was reduced mostly from the immobilization and pain. Especially, the push up movement pattern was negative from the lack of strength and pain. Neurological and other special tests did not show any further findings.

3.4 Therapy

3.4.1 Goal of therapy

The goal of the whole therapy of the patient was to treat the blockages, shortness and contractures and provoke relaxation in order to be able to regain full function of his affected extremity after the strengthening program he is going to attend. Specifically, the aim of the therapy is to treat the hypertonicity and shortness of neck, trunk and shoulder muscles. Improve strength on the intrascapular and shoulder muscles that were found weak. Lastly, treat the blockages found in the shoulder.

3.4.1.1 Proposed therapy

In my opinion the suitable therapy for this patient would be to improve skin and fascia mobilization using soft tissue techniques, improve joint play by using joint mobilization and regain normal joint range of motion by using passive stretching. Also the therapy would include relaxing hypertonic muscles by using relaxation techniques and strengthen affected muscles by using analytic exercises and PNF technique.

3.4.1.2 Short- term plan

- Soft tissue techniques will be utilized around the shoulder of the patient and on his upper back and neck and then the same areas will be massaged.
- Mobilize the acromioclavicular joint on the cranial direction and then perform mobilization of scapula.
- Perform passive stretching on levator scapulae
- Relax external rotators, pectoralis minor and upper trapezius using PIR technique
- Use the terra band to provide external rotations and internal rotations from sited position, flexion of shoulder until 90 degrees and diagonal pull downs using resistance

from the terra band later on the therapy then use PNF first extension diagonal and second flexion as well as all the diagonals of scapula.

3.4.1.3 Self-therapy

The patient was instructed on how to perform push-ups against the wall at first because it was the only pattern he couldn't perform and because it is a simple exercise without the need of any apparatus and it assists in scapula stabilization as well as strengthening.

3.4.2 Day to day therapy

3.4.2.1 Day one: 26/4

The treatment began with performing a control examination of active flexion and abduction and the examination of joint play of acromioclavicular joint in cranial direction.

- Soft tissue techniques were performed around the shoulder of the patient and on his upper back and neck and then the same areas were massaged.
- Mobilized the acromioclavicular joint on the cranial direction and performed mobilization of scapula in prone position.
- Passive stretching was performed on the levator scapulae and trapezius muscle.
- Relaxed the external rotators, pectoralis minor and upper trapezius using PIR technique
- The terra band was used to provide external rotations and internal rotations from sited position, flexion of shoulder until 90 degrees and diagonal pull downs using resistance from the terra band to strengthen the weak muscles. In the end the patient did active stretching.

Notes: The patient in the control examinations was not able to perform the flexion and the abduction motion because he felt pain in the anterior side of the shoulder. He responded well to the treatment, he didn't feel any pain apart from when stretching his operated extremity in horizontal adduction and he admitted that he felt very relieved from the scapula mobilization. In the training room, his performance was great and he only felt pain on the flexions with the terra band.

3.4.2.2 Day two: 29/4

Treatment began with performing a control examination of active flexion and abduction, examination of joint play of acromioclavicular joint in cranial direction.

- Soft tissue techniques around the shoulder of the patient and on his upper back and neck and then the same areas were massaged.
- The acromioclavicular joint was mobilized on the cranial direction and mobilization of the scapula was performed.
- Passive stretching was performed on the levator scapulae
- The external rotators were relaxed as well as the pectoralis minor and upper trapezius using PIR technique

- The terra band was used to provide external rotations and internal rotations from sited position, flexion of shoulder until 90 degrees and diagonal pull downs using resistance from the terra band later on the therapy for PNF diagonals of the scapula was used.

Notes: The patient in the control examinations of every day was not able to perform the flexion and the abduction full range of motion because he felt pain in the anterior side of the shoulder. He responded well to the treatment, he didn't feel any pain apart from when stretching his operated extremity in horizontal adduction and he admitted that he felt very relieved from the scapula mobilization. In the training room, his performance was great and he only felt pain on the flexion with the terra band.

3.4.2.3 Day three: 30/4

The treatment began by performing a control examination of active flexion and abduction, examination of joint play of acromioclavicular joint in cranial direction.

- Soft tissue techniques around the shoulder of the patient and on his upper back and neck and then the same areas were massaged.
- The acromioclavicular joint was mobilized on the cranial direction and mobilization of the scapula was performed.
- Passive stretching on levator scapulae was performed
- The external rotators were relaxed as well as the pectoralis minor and upper trapezius using PIR technique
- The terra band was used to provide external rotations and internal rotations from sited position, flexion of shoulder until 90 degrees and diagonal pull downs using resistance from the terra band. Later on during the therapy PNF was used for the first extension diagonal and second flexion as well as all the diagonals of scapula.

Notes: The patient in the control examination was able to perform the flexion and the abduction full range of motion but he felt pain from 90 degrees up to 110 degrees in the anterior side of the shoulder. He responded well to the treatment, he didn't feel any pain apart from when stretching his operated extremity in horizontal adduction and he admitted that he felt very relieved from the scapula mobilization. In the training room, his performance was great and without pain.

3.4.2.4 Day four: 2/5

The treatment began by performing a control examination of active flexion and abduction, examination of joint play of acromioclavicular joint in cranial direction.

- Soft tissue techniques around the shoulder of the patient and on his upper back and neck and then the same areas were massaged.
- The acromioclavicular joint was mobilized on the cranial direction and mobilization of the scapula was performed.
- Passive stretching was performed on the levator scapulae
- The external rotators were relaxed as well as pectoralis minor and upper trapezius using PIR technique
- The terra band was used to provide external rotations and internal rotations from sited position, flexion of shoulder until 90 degrees and diagonal pull downs using resistance from the terra band later on the therapy that was used was PNF first extension diagonal and second flexion and all the diagonals of scapula.

Notes: The patient in the control examination was able to perform the flexion and the abduction full range of motion but he felt pain from 90 degrees up to 110 degrees in the anterior side of the shoulder. He responded well to the treatment, he didn't feel any pain apart from when stretching his operated extremity in horizontal adduction and he admitted that he felt very relieved from the scapula mobilization. In the training room, his performance was great and without pain.

3.4.2.5 Day five: 3/5

Treatment began with performing control examination of active flexion and abduction, examination of joint play of acromioclavicular joint in cranial direction.

- Soft tissue techniques around the shoulder of the patient and on his upper back and neck and then the same areas were massaged.
- The acromioclavicular joint was mobilized on the cranial direction and mobilization of scapula was performed.
- Passive stretching was performed on levator scapulae
- External rotators were relaxed as well as the pectoralis minor and upper trapezius using the PIR technique
- The terra band was used to provide external rotations and internal rotations from sited position, flexion of shoulder until 90 degrees and diagonal pull downs using resistance from the terra band later on the therapy used was PNF first extension diagonal and second flexion as well as all the diagonals of scapula.

Notes: The patient in the control examination was able to perform the flexion and the abduction full range of motion but he felt pain from 90 degrees up to 110 degrees in the anterior side of the shoulder. He responded well to the treatment, he didn't feel any pain apart from when stretching his operated extremity in horizontal adduction and he admitted that he felt very relieved from the scapula mobilization. In the training room, his performance was great and without pain.

3.4.3 Control examinations

3.4.3.1 Observation: From the observation one could see that the position of the head was improved and the shoulders were in the same level, thorachobrahial spaces were even. The scoliosis on his back hasn't improved, his knees were in the same place and his stance was close still.

3.4.3.2 Dynamic tests:

Flexion: Flexion of the trunk was possible, with good quality of movement and with good range of motion, improved reaching 5 cm above ground level.

Lateral flexion: Lateral flexion was again possible but limited, the motion was only initiated from the thoracic area and the patient reached 45 cm above ground to the right and to the left.

Extension: extension was better, the range of motion was again excessive and the quality of the movement was great.

3.4.3.3 Range of motion evaluation:

Motion	Right extremity	Left extremity	Comments
Shoulder flexion	180 degrees	180 degrees	Slight pain on the right when we were passing 90 degrees level
Shoulder extension	15 degrees	15 degrees	No pain
Shoulder abduction	180 degrees	180 degrees	No pain
Shoulder horizontal abduction	90 degrees	90 degrees	No pain
Shoulder horizontal adduction	40 degrees	40 degrees	Pain on the right in the end of the motion
Shoulder internal rotation	60 degrees	75 degrees	Pain on the right in the end of the motion but improved range
Shoulder external rotation	90 degrees	90 degrees	No pain
Elbow flexion	120 degrees	125 degrees	No pain

Table 9: Range of motion evaluation

3.4.3.4 Gait examination: Gait was close to normal, only the feet were turned outward more in the left than the right extremity on the swing phase and lastly the steps were small.

Heel walking, tip toe walking, and backward walking were all possible

3.4.3.5 Muscle strength test:

Muscle	Right side	Left side	Comments
Pectoralis major	5	5	Slight pain during test
Pectoralis minor	5	5	
Anterior deltoid	5	5	Improved
Middle deltoid	4	5	Less pain during test
Posterior deltoid	4	5	Less pain during test
Supraspinatus	5	5	
Infraspinatus	4	5	Slight pain during test
Subscapularis	5	5	
Teres major	5	5	
Teres minor	4	5	
Latissimus dorsi	5	5	
Upper trapezius	5	5	
Middle trapezius	4	4	Improved
Lower trapezius	4	4	improved
Romboid	4	4	improved
Serratus anterior	4	4	

Table 10: Muscle strength test

3.4.3.6 Length test:

Muscle	Right side	Left side
Pectoralis major	normal	normal
Sternocleidomastoid	normal	normal
Levator scapulae	normal	normal
Scalene	normal	normal
Trapezius	normal	normal

Table 11: Length test

3.4.3.7 Hypermobility test:

Scarf test	Hypermobility grade A	Bilaterally
Clasped elbows test	Hypermobility grade B	Bilaterally
Wrist flexors test	Hypermobility grade A	Bilaterally
Axillary test	No hypermobility	Bilaterally
Head rotation test	No hypermobility	Bilaterally
Trunk rotation test	No hypermobility	Bilaterally

Table 12: Hypermobility test

3.4.3.8 Movement pattern test:

Shoulder abduction: The quality of the motion was even better, the activity of the muscles was normal.

Push up: The motion was improved, certainly strength is limited and the quality was limited.

Neck flexion: The motion quality was again good, the activation of the muscles and the range also good.

3.4.3.9 Palpation: Skin and fascia around the shoulder, neck and back were released. Scar tissue was soft and didn't bother the patient at all.

Muscle	Right side	Left side	Comments
Trapezius	normal	normal	No pain
Rhomboid	normal	normal	
Pectoralis minor	normal	normal	
Pectoralis major	normal	normal	
Deltoid	normal	normal	
Infraspinatus	normal	normal	No pain
Supraspinatus	normal	normal	No pain
Teres major	normal	normal	
Teres minor	normal	normal	
Erector spinae	hypertonus	hypertonus	The hypertonicity was located in the lower part
Bicep	normal	normal	
Tricep	normal	normal	

Table 13: Palpation

3.4.3.10 Joint play examination:

Joint	Result
Vlenohumeral ventral	present
Caudal direction	present
Dorsal direction	present
Lateral direction	present
Acromio clavicular cranio-caudal direction	present
Dorsal ventral direction	present

Table 14: Joint play examination

3.4.3.11 Neurological examination:

Reflexes	Result
Triceps	present
Bicep	present
Wrist flexors	present

Table 15: Neurological examination

3.4.3.12 Other tests:

The patient's results of the control examination of Trendelenburg test, Romberg test and standing on two scales test were once again negative.

3.4.3.13 Conclusion of control examination

As we can observe from the control examinations the range of motion was improved with no pain throughout the whole motion apart from 90 degrees to 110 of ABD abduction and flexion. Joint play in the acromioclavicular joint was restored. Strength was improved notably on middle and lower trapezius and rhomboids. Hypertonicity and shortness was successfully treated in upper trapezius, rotator cuff and trunk muscles. To sum up, the patient's posture and the motion was improved significantly, as he admitted. Freedom of the movements of the shoulder was restored.

3.5 Result of therapy

The examination provided us with the information we needed to proceed to the correct treatment. The therapy appeared to be useful and the patient reacted well to the treatment as it is recorded in the control examination. The quality of the movement improved and for sure the patient felt more relieved and his shoulder more free, as he admitted.

3.5.1 Long-term plan

The long term plan would be to complete the examinations of stability and posture and ADL and then to strengthen the muscles around the operated extremity in that level so the motion will not be performed in a way that overloads certain points and avoid the impingement so the patient can use his arm on his ADL activities like he used to in the past before the operation.

3.5.2 Prognosis

The patient is in a very good health condition, he was very active in the past and he was very anxious to get back to living an active lifestyle. He is recuperating perfectly and his problem was treated correctly with the operation. The therapy looks effective and that is the reason one can believe that he will not have any problems in returning to a full active lifestyle without any limitations.

4. Conclusion

To sum up, as is it recorded previously in the conclusion of the examinations, the examination provide us with the evidence needed to create the correct short and long term plan. Secondly as it is record in the results of the therapy, the treatment was successful and the patient was satisfied from the therapy and lastly in the conclusion of the control examination and as the patient himself admitted the sessions were successful. Treating this particular case was not very easy as the patient was not only suffering from rotator cuff rupture but also from omarthrosis which together caused the impingement of the shoulder. As it is mentioned previously the combination of those two conditions is the one that made the procedure very interesting and rewarding. In addition, I had the opportunity to learn about the type of surgery that this case requires and the specific therapy plan that is recommended to follow.

5 Attachments

5.1 Approval of the ethics committee

5.2 Consent of the patient

5.3 The list of pictures

Figure 1: Omarthrosis.....	0
Figure 2: Rapture of infraspinatus.	0
Figure 3: Impigement of shoulder.....	0
Figure 4: Arthroscopical operation.	0

5.4 The list of tables

Table 1: Present status	22
Table 2: Range of motion evaluation.....	25
Table 3: Muscle strength test	26
Table 4: Length test.....	27
Table 5: Hypermobility test.....	27
Table 6: Palpation	28
Table 7: Joint play examination.....	29
Table 8: Neurological examination	29
Table 9: Range of motion evaluation.....	36
Table 10: Muscle strength test	37
Table 11: Length test.....	37
Table 12: Hypermobility test.....	38
Table 13: Palpation	38
Table 14: Joint play examination.....	39
Table 15: Neurological examination	39

6. Literature

1. Allen, E., Fongemie, A., Daniel, D., Buss, D., and Sharon, J., Rolnick, S. (1998). *Management of shoulder impingement syndrome and rotator cuff tears*. Am Fam Physician. Minneapolis, Minnesota. 57(4):667-674.
2. American Academy of Orthopaedic Surgeons. (2011). *Rotator Cuff tears: Surgical treatment options*. Accessed online on 29 July 2013, from <http://orthoinfo.aaos.org/topic.cfm?topic=a00406>
3. Anderson, B. *Shoulder impingement syndrome (Beyond the Basics)*. Oregon Health Sciences University. Accessed online on 30 July 2013, from <http://www.uptodate.com/contents/shoulder-impingement-syndrome-beyond-the-basics>
4. Bang, MD., Deyle, GD. (2000). The Journal of Orthopaedic and Sports Physical Therapy. 30(3), pp.126-137.
5. Burbank, KM., Stevenson, JH., Czarnecki, GR., Dorfman, J. (2008). *Chronic shoulder pain: part I. Evaluation and diagnosis*. Am Fam Physician. 77(4):453-460.
6. Devinney, D.S. (2005). *Surgery of shoulder arthritis*. In W.J. Koopman, L.W. Moreland, eds. Arthritis and Allied Conditions. 15th ed. ISBN: 9780781746717. (vol. 1, pp. 995-1015). Philadelphia: Lippincott Williams and Wilkins.
7. Gray, H. (1918). *Anatomy of the Human Body*. In S. Standring ed., Gray's Anatomy. The Anatomical Basis of Clinical Practice. ISBN: 978-0-443-06684-9. (vol. 40, pp. 791-823). Churchill Livingstone.
8. Greiwe, R.M., Ahmad, C.S. (2010). *Management of the throwing shoulder: cuff, labrum and internal impingement*. Orthopaedic Clinic of North America. 41(3):309-23

9. Heraeus Medical. (2013). *What causes damage to the shoulder joint*. Accessed online on 30 July 2013, from <http://patient.heraeus-medical.com/en/schultergelenk/schdiegungschulter/schaedigungschulter.html>
10. Lewit, K. (2010). *Manipulative Therapy*. Musculoskeletal medicine. ISBN 9-780-7020-3056-7. pp. 180- 299. Churchill Livingstone.
11. Kendall, F. (2005). *Muscles: Testing and Function, with Posture and Pain*. ISBN: 978-0-7817-4780-6. pp. 297- 337. Philadelphia: Lippincott Williams and Wilkins.
12. Khasnis, A., Goluka, R.M. (2003). *Romberg's test*. Journal of Postgraduate Medicine. 49 (2): 169- 72
13. Lin, K.C., et al. (2010). *Rotator cuff*. 1. Impingement lesions in adult and adolescent athletes. In J.C. DeLee eds. DeLee and Drez's Orthopaedic Sports Medicine, Principles and Practice. 3rd ed. (vol. 1, pp. 986-1015)
14. Ludewig, P.M., Reynolds, J.F. (2009). *The association of scapular kinematics and glenohumeral joint pathologies*. Journal of Orthopaedics Sports and Physical Therapy. 39(2):90-104.
15. Magee, D. *Orthopedic Physical Assessment*. 4th ed. pp.491, 592. ISBN: 0721605710
16. Neer, CS. (1972). *Anterior acromioplasty for chronic impingement syndrome in the shoulder—a preliminary report*. 54:41-50.
17. Page, P., Frank, C., Lardner, R. *Assessment and Treatment of Muscle Imbalance: The Janda Approach*. ISBN: 9780-0-7360-7400, pp. 77-116.
18. Russell, S., Triola, M. *The Precise Neurological Exam*. NYU School of Medicine. Accessed online on 29 July 2013, from <http://informatics.med.nyu.edu/modules/pub/neurosurgery/index.html>

19. Santamato, A. (2009). *Short-term Effects of High-Intensity Laser Therapy Versus Ultrasound Therapy in People with Subacromial Impingement Syndrome: A Randomized Clinical Trial in Physical Therapy*. Vol. 89. No. 7. pp. 643-652.
20. Sutherland, D.H. (2005). *The evolution of clinical gait analysis part III--kinetics and energy assessment*. *Gait Posture*. 21(4):447-61.
21. Thorling, J., Bjerneld, H., Hallin, G. (1985). *Acromioplasty for impingement syndrome*. 56:147-3.
22. The Journal of Bone and Joint Surgery. (1993). American Volume, University of Texas Health Science Center Department of Orthopaedics, 75(3), pp. 409-424.
23. Winston, J., Warme, M.D., Frederick, A., Matsen III, M.D. (2013). UW Orthopaedics & Sports Medicine.
24. Wülker, N. (2000). *Omarthrosis*, *Orthopade*, 909-16 [Article in German].
25. Yu, E., Cil, A., Harmsen, W.S., Schleck, C., Sperling W.J., Cofield H. R. (2010). *Arthroscopy and the Dramatic Increase in Frequency of Anterior Acromioplasty from 1980 to 2005: An Epidemiologic Study*. Published in final edited form as: *Arthroscopy*. 2010 September; 26(9 Suppl): S142–S147. Published online 5th August 2010.