

# Charles University

---

Faculty of Physical Education and Sports

## Case study of a patient with Colles' fracture

Bachelor Thesis  
April 2011, Prague

Author: Farah H. Droubi  
Advisor: Mgr. Zaher El Ali  
Supervisor: PhDr. Jitka Čemusová Ph.D

## **Abstract**

**Title:** Case study of a patient with Colles' fracture.

**Thesis aim:** The thesis is divided into two main parts; a general (theoretical) part and a special (practical) part. The theoretical part consist of a combination of anatomy, kinesiology and biomechanics of the distal upper extremity and a specific section on the Colles' fracture and approaches to its treatment and rehabilitation. The practical part consists of a case study of a patient post a Colles' fracture and describes examinations, physiotherapeutic plans and approaches for treatment, and a conclusion on the latter.

**Methods:** The special part is of a 69 year old (male) patient after a Colles' fracture of his wrist. The methods used in rehabilitation focused primarily on regaining enough active ROM and strength in his hand functions to perform ADL's and pre-accident activities. They include functional specific exercises, PIR relaxation techniques, PNF techniques, mobilizations and special exercises over the course of 10 therapy sessions.

**Results:** Improvements were seen throughout the entire program, specifically in reduction of edema and pain and significant increase in ROM. Patient was also able to perform many more self-care activities independently by the end of the therapy.

**Conclusion:** Within the short time of therapy, the patient's improvements were satisfactory as the only remaining problem was the restricted ROM in certain directions which requires more time to improve. As an elderly with low functional demands, the patient has a good prognosis if therapy is to be continued.

**Keywords:** wrist, distal radius fracture, Colles', fracture, physiotherapy, case study, radius, ulna

**I declare:**

That this work is entirely my own individual work based on knowledge gained from books, research, journals and case reports, and from attendance of lectures and seminars at FTVS Charles University.

I also declare that no invasive methods were used during the practical approach and that the patient was fully aware of the procedures at all times.

**Declaration made by** Farah Droubi

April 2011, Prague

## **Acknowledgement**

I owe my deepest gratitude to my mother, who has made all of this a possibility for me. She has made available all her unconditional support and motivation towards my studies and none of those can be appreciated enough. I am also in debt to all my colleagues for all their 'extra pushes', devoted time, advice and support that I needed to get to where I am now.

I would like to show my gratitude to all the professors and remarkable physiotherapists who taught us, with their greatest efforts within the years, everything that we know now and will remember and use throughout our entire future careers. It is an honor for me to be able to learn from you.

It's finally a pleasure to heartily thank those who made this thesis possible; my supervisor, PhDr. Čemusová, for her guidance and time in controlling my thesis, and my advisor, Mgr. Zaher El Ali, for his tireless work in helping me expand my practical skills during the practices.

**Thank you all.**

**Farah Droubi**

Prague, April 2011

## Table of Contents

1	Introduction .....	6
2	General Part.....	7
2.1	Anatomy of the upper extremity .....	7
2.2	Elbow and radioulnar joints .....	7
2.3	Wrist joint .....	12
2.4	Hand joints .....	16
2.5	Prehension.....	21
2.6	Bone – Mechanism of Injury .....	22
2.7	Colles’ Fracture Etiology and Epidemiology.....	23
2.8	Rehabilitation for Colles’ Fractures.....	26
3	Special part.....	30
3.1	Methodology .....	30
3.2	Anamnesis.....	31
3.3	Initial Kinesiologic Examination .....	33
3.4	Short-term and Long-term Physiotherapy Plan .....	40
3.5	Therapy Progress.....	41
3.6	Final Kinesiologic Examination.....	48
3.7	Evaluation of the Effect of the Therapy.....	54
4	Conclusion.....	59
5	Bibliography .....	60
6	Supplement.....	63

# **1 Introduction**

The objective of this thesis is to highlight the physiotherapeutic approach after a Colles' fracture. The base of the thesis is its theoretical part which contains the kinesiology and biomechanics in combination with anatomy of the distal upper extremity in separated parts. The latter also includes a specific part on bone injury mechanisms, fracture healing, Colles' fracture etiopathogenesis, classification and general treatment approaches appropriate to the injury.

As the main part of the thesis, the second special part discusses the examination and therapy progress of a patient after a distal radius fracture. This diagnosis, is the most common distal radius fracture and also the most common occurring fracture in the entire body in the elderly population. It has a high incidence as it is mainly caused by a fall on an outstretched hand which may be a risk for anybody.

The clinical practice for this part took place at Centrum Léčby Pohybového Aparátu Vysočany, Prague. A full examination and therapy execution was performed and evaluations of therapy progress with conclusions of the therapy program are included to highlight the main improvements, results or areas in need of improvement.

The thesis is equipped with a list of literature, figures, tables and explanations of abbreviations that can be found in the supplement.

## 2 General Part

### 2.1 Anatomy of the upper extremity

The upper extremity consists of the shoulder complex (which connects it to the axial organ) and what I will be discussing in more detail, the elbow joints, wrist joints and joints of the hand.

There is a strong and important working relationship between the shoulder complex and the distal upper extremity where both assist in applying force and controlling the placement of the hand in space. (1) This generates different hand positions, grasping, fine hand motions and also a means of communication with people (manual contact, common gestures).

### 2.2 Elbow and radioulnar joints

These joints enable the most important function of the hands, pronation (P) and supination (S), which allows rotation of the hand towards the face involved in daily activities such as feeding, washing and shaving and others such as pushing up from a chair and grasping. (2)

The three bones that constitute the elbow and radioulnar joints are the humerus (long bone which constitutes the upper arm), and the radius and ulna (constitutes the forearm). (3)

**Humeroulnar** joint (ulna and humerus) is the main joint that establishes to **flexion** (F) and **extension** (E) of the elbow. It is the union between the trochlea (of distal humerus) and trochlear notch (of proximal ulna) and the coronoid process (anterior ulna) which contacts the coronoid fossa of the humerus, limiting F in the terminal range of motion (ROM).

On the other hand, limiting the terminal ROM of E, is the olecranon process (posterior ulna) when it is in contact with the olecranon fossa of the humerus. This full E at the elbow is the most stable position for this joint as it is in *close-packed* position therefore the radiohumeral joint here, is least stable.

**Radiohumeral** joint (radius and humerus) is a union between the spheroidal capitulum of the humerus, which is covered with cartilage, and the proximal radial head. The radial

head goes against the capitulum in radial movement and the capitulum acts like a buttress. The close-packed position for the radiohumeral joint is achieved when the forearm is F to 80° and in semi-prone position.

Muscles: There are 24 muscles that cross the elbow joint. Some act only on the elbow but most act on a combination of wrist and phalangeal joints. There are four main muscle groups that act on the elbow, wrist and hand; the anterior flexors, posterior extensors, lateral extensors -supinators, medial flexors – pronators. (1)

The lateral epicondyle of the humerus is the main attachment site for lateral ligaments and forearm supinator and pronator muscles. The medial epicondyle of the humerus attaches the medial ligaments and the forearm flexors and pronators. (3)

Table 1 - ROM at elbow joint and muscles involved (1)

<b>Movement</b>	<b>Muscles (that provide movement)</b>	<b>ROM from 0°</b>
<b>F</b>	Biceps brachii, brachialis, brachioradialis.	Up to 145 ° actively and 160 ° passively.
<b>E</b>	Triceps brachii	0 ° is physiological but can have 5-10 ° of hyperextension present.*

\*Hyperextension at the elbow may mean that the individual has a small olecranon process or a large olecranon fossa.

Movement characteristics: (1) Flexors of the elbow (see Table 1) are more effective as the elbow F increases. This is because their mechanical advantage increases with an increase in the magnitude of the moment arm. It is maximal at 100-120 °F.

The brachialis is active in all positions of flexion but it is limited due to its poor mechanical advantage. It plays the major role when the elbow is in a pronated position.

The biceps brachii muscle is limited mechanically by actions of the shoulder and radioulnar joint, e.g. flexion at the shoulder generates a slack in the long head of bicep and vice versa for extension. Also if the forearm is pronated, the tendon gets tucked under the radius therefore it's not as effective as when the arm is in supination.

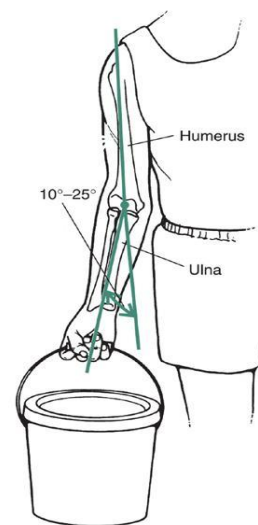
The brachioradialis muscle most effectively flexes the elbow in the midprone position.

Extensors of the elbow (Table 1) are the strongest elbow muscle, the triceps brachii. It consists of three portions (long, medial and lateral heads). As the long head crosses the shoulder joint, it is dependent on the shoulder's position for its effectiveness. The medial head is in advantage as it is active in all positions and speeds. The lateral head of triceps brachii is known to be the strongest, but also relatively inactive unless it is moved against resistance. Unlike the flexors, the output of triceps is not influenced by forearm positions of P and S.

The maximum strength in flexion can be developed when the elbow is in semi-prone position, followed by the supinated position (20-25% more strength than the pronated position). For extension, the greatest strength can be developed from a position of 90° F.

Carrying angle (see Picture 1)

The long axis of the extended forearm lies at an angle to the long axis of the arm. This angle is called the **carrying angle** and is about 10-20° physiologically. This angle, which opens laterally, is important when carrying objects and also in walking as it allows the forearms to clear the hips during swinging movements. The carrying angle may decrease or increase after several fractures.



Copyright © 2009 Wolters Kluwer Health | Lippincott Williams & Wilkins

Picture 1 - Carrying angle (1)

(1)

**The radioulnar** joints establishes the movements pronation and supination of the forearm. It consists of two articulations between the radius and ulna; the proximal radioulnar joint (close to the humerus) and the distal radioulnar joint. Also midway between the proximal and distal joint runs a fibrous connection (interosseous membrane) between the radius and ulna. (3)

The **proximal** radioulnar joint (PRUJ) is an articulation between the radial head and the radial fossa (on the side of the ulna). It is a synovial pivot joint therefore the radial head is able to rotate in a fibrous osseous ring (created like a collar around the radius head by the annular ligament from the ulna), creating movement of the radius in a clockwise or anti-clockwise direction relative to the ulna. The radius and ulna lie next to each other in neutral position but in full pronation the radius crosses the ulna diagonally. This joints

close-packed position is when it is in semi-prone. The **distal** radioulnar joint (DRUJ) is an articulation between the convex rounded head of the ulna and the concave ulnar notch of the distal radius. (1)

The dorsal surface of the distal radius has several grooves and raised areas that help guide or stabilize the tendons that course toward the wrist and hand. The palmar surface of the distal radius is the location of proximal attachments of the wrist capsule and the thick palmar radiocarpal ligaments. The styloid process of the radius projects distally from the lateral side of the radius. The styloid process of the ulna, sharper, extends distally from the posterior-medial corner of the distal ulna. The distal articular surface of the radius is concave in both medial-lateral and antero-posterior directions.(1,3)

The interosseous membrane that runs the length of the ulna and radius and connects them create a larger surface area for muscle attachments. Around 80% of compressive forces are typically applied to the radius, and the interosseous membrane transmits these forces received, distally from the radius, to the ulna. The membrane is taut in a semiprone position. (1)

Supination: With respect to the fixed ulna, at the PRUJ there is a rotation of the radial head within its ring dorsally and distally. S at the DRUJ occurs as the concave ulnar notch of the radius rolls and slides in similar directions of the radial head. The proximal surface of the articular disc remains in contact with the ulnar head and at the end range, the palmar capsule ligament of the wrist is stretched to its maximum length creating a stiffness that stabilizes the joint. (1)

Pronation: Similar mechanism occurs in P but in the opposite direction. The radial head rotates proximally and ventrally during P. Full P elongates and thereby increases tension in the dorsal capsular ligament at the DRUJ. It also slackens the palmar capsular ligament. It also exposes the articular surface of the ulnar head making it readily palpable.(2)

**Table 2 - ROM at the radioulnar joints and muscles involved (1)**

<b>Movement</b>	<b>Muscles (that provide the movement)</b>	<b>ROM from 0°</b>
<b>S</b>	Supinator (primarily) and	Approximately 85° actively

	biceps brachii.	and 90° passively.
<b>P</b>	Pronator teres, pronator quadratus	Approximately 70°, and 90° passively

Movement characteristics: (Refer to Table 2 for ROM norms and muscles' actions) The ROM for P is limited by the ligaments, joint capsule and soft tissue compressing as the radius and ulna cross. ROM for supination is limited by ligaments, capsule and the pronator muscles. Approximately 50° of pronation and 50° of supination are required to perform **most** activities of daily living (ADL).

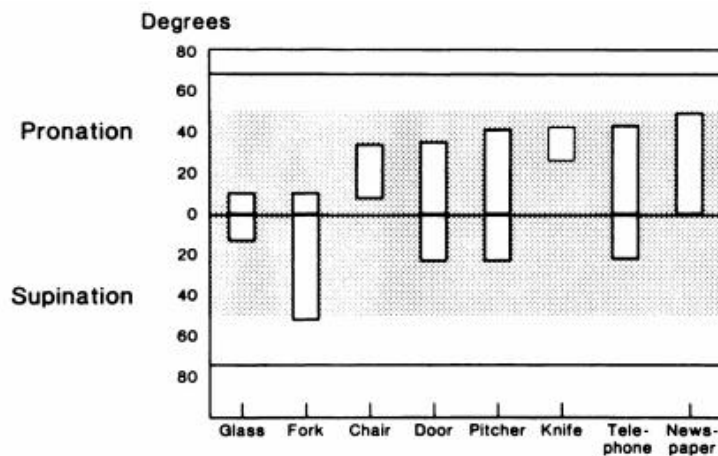
The supinator is the only muscle that contributes to a slow and un-resisted S action in all forearm positions. The biceps brachii can supinate in quick movements or in those where the elbow is flexed.

Pronator quadratus (which is also a primary wrist stabilizer) is more active for P movement regardless of the position or speed of activity. However the pronator teres muscle is more active at 60° F of the elbow and when it is under a load. Most effective P and S strength is when the elbow is in semi-prone position, with the torque dropping off considerably at the fully pronated or supinated position. (1) This is an important notice for conditioning or strengthening exercises of the forearm muscles.

Functional arc:

According to *Figure 2*, there is a 100° functional arc that exists for forearm rotation. This means that people who lack 30° of ROM of elbow rotation are still capable of performing many ADL.

The figure shows arcs of forearm rotation during continuous activity; glass to mouth, fork to mouth, rising from a chair, opening a door, pouring from a pitcher, cutting with a knife, using the telephone and reading the newspaper.



Picture 2 - Activity requiring arc of elbow motion (22)

## Importance of good anatomical alignment of the distal radioulnar joint (2)

Fractures of the distal end of the radius with a dorsal displacement of distal fragment (*Colles fracture*) are very common. A fracture that heals in an abnormally aligned way can significantly alter the fit of both the distal radioulnar joint and the radiocarpal joint of the wrist. Depending on the nature of malalignment, the joints may easily become unstable or may develop degenerative arthritis from altered contact pressures at the articular surfaces of the joint during motion.

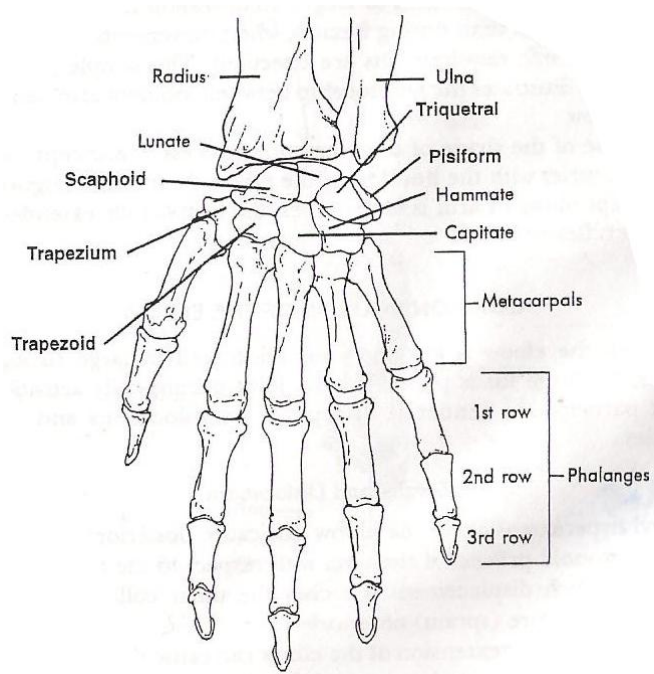
Abnormal alignment of the distal radius can also change the relationship between the axis of rotation of the forearm and the interosseous membrane. If the malalignment is severe, the interosseous membrane may restrict the full extent of P or S.

The distal end of the radius has 2 configurations of biomechanical importance – 1) The distal end of radius angles about  $25^\circ$  toward the ulna medially. This *ulnar tilt* allows the wrist and hand to rotate farther into ulnar deviation than into radial deviation. 2) Distal articular surface of the radius is angled about  $10^\circ$  in the palmar direction. This *palmar tilt* accounts in part for the greater amounts of flexion than extension at the wrist.

### 2.3 Wrist joint

The wrist is composed of the radiocarpal, midcarpal and intercarpal articulations (see Picture 3).

**The radiocarpal joint (RCJ)** is an articulation between the broad end of the radius, and the scaphoid, lunate and also *minimally* the triquetrum carpal bones. Most wrist motion occurs at this joint. The joint allows movement in 2 planes (sagittal and frontal); flexion-extension and radial-ulnar deviation, as well as circumduction. All occur primarily in the RCJ, but a good portion of wrist F occurs at the midcarpal joints too. The joint's close-



Picture 3 - The bones of the wrist and hand. (4)

packed position is in E and radial deviation, therefore when one falls on the hand with hyperextension of the wrist and an outstretched hand the scaphoid bone is the most susceptible to injury. (1,4)

The DRUJ is adjacent to the RCJ but it does not participate in any wrist movements. The ulna doesn't make contact with the carpals as it is separated by a fibrocartilage disc. It can glide on the disc during S and P but does not influence the carpal movements. (1)

The RCJ is reinforced by a joint capsule on its own; ventral radiocarpal, dorsal radiocarpal, radial collateral and ulnar collateral ligaments. The fascia around the wrist is also thickened into fibrous bands (retinacula) which provide a passageway through where long tendons of muscles, nerves and blood vessels pass. (4)

**The midcarpal and intercarpal (MCJ and ICJ) joints** consist of 2 rows of carpals; 1) The proximal row which contains the 3 that participate in wrist joint function – **lunate, scaphoid** and **triquetrum**, and lastly the **pisiform** which is in the medial side of the hand (muscular attachment site). 2) The distal row which contains 4 more carpals – **trapezium** connected with the thumb, **trapezoid, capitate** and **hamate**. (3)

Articulation between the two rows is the MCJ. And the articulation between the bones themselves is an ICJ. They are gliding joints in which translation movements are produced accordingly with wrist movements. The proximal row is more mobile than the distal row. (1)

The most important carpal bone is the scaphoid because it supports the weight of the arm, transmits forces received from the hand to the bones of the forearm and it's also a key participant in wrist joint motions. It transmits forces when the hand is fixed and the forearm weight is applied to the hand. (1)

**Wrist extension** – at the RCJ, occurs as the lunate rolls dorsally on the radius and simultaneously slides palmarly. The rolling motion directs the lunate's distal surface dorsally, toward the direction of E. 60% of the total range of E occurs here.(2) However the movement of E begins at the MCJ as the capitates rolls the same way on the lunate first. (1) In wrist **flexion** – the same kinematics occur but in a reverse fashion. The movement also begins at the MCJ and in this time also 60% of the total ROM occurs at the MCJ. (2)

During **ulnar deviation** – the proximal row of carpals rolls ulnarly and slide a significant distance *radially*. In full ulnar deviation, the triquetrum is in contact with the articular disc and is also compressed by the hamate which pushes the proximal row further to the styloid process of the radius. This stabilizes the wrist and is useful when using large gripping forces. The same kinematics occur in **radial deviation** as the proximal row slides ulnarly and the distal row slides radially. (2)

Muscles: Most of the muscles that act at the wrist and finger joints originate outside the hand in the region of the elbow joint and are termed *extrinsic muscles*. These enter the hand as tendons that can be quite long. The tendons are held in place on the dorsal and palmar wrist area by extensor and flexor retinacula. (1)

The extrinsic muscles provide strength and dexterity to the fingers without adding bulk to the hand. (1) There are also intrinsic muscles originating within the hand that create movements at the metacarpo-phalangeal and inter-phalangeal joints which will be discussed later. In the table below, are the muscles and ROM norms involved in the movements of the wrist joint.

Table 3 - ROM at the wrist joint and the muscles involved (2)

<b>Movement</b>	<b>Muscles</b>	<b>ROM from 0°</b>
<b>E</b>	<i>Primary:</i> Extensor carpi radialis longus, extensor carpi radialis brevis, extensor carpi ulnaris. <i>Secondary:</i> Extensor digitorum, extensor indicis, extensor digiti minimi, extensor pollicis longus.	60-75°
<b>F</b>	<i>Primary:</i> Flexor carpi radialis, flexor carpi ulnaris, palmaris longus. <i>Secondary:</i> Flexor digitorum profundus, flexor digitorum superficialis, flexor pollicis longus.	70-85°
<b>Radial deviation</b>	Flexor carpi radialis, extensor carpi radialis longus, extensor carpi radialis brevis.	15-20°

<b>Ulnar deviation</b>	Flexor carpi ulnaris, extensor carpi ulnaris	35-40°
------------------------	--	--------

Movement characteristics: As shown in Table 3, the muscles that provide F and E of the wrist have been divided into the primary set and the secondary set. The primary muscles are the muscles acting solely on the wrist but the muscles in the secondary set are ones that act on the wrist and fingers as well (therefore their effectiveness is dependant on the position of the fingers). For example, during E, the secondary set assist with the wrist E most effectively when the finger's are flexed. (4) This is because the resistance produced from the finger flexor muscles is diminished. ROM of wrist F is reduced if it's performed with finger F too. (1)

The extensor carpi radialis longus and extensor carpi radialis brevis create also F at the elbow therefore can be more effective as wrist extensors with E at the elbow. The extensor carpi ulnaris creates E at the elbow therefore it is enhanced in elbow F for wrist E. (1) E of the wrist is usually limited by the stiffness in the palmar radiocarpal ligaments and tension of the palmar structures. This stabilizes the wrist in its close-packed position and is useful when weight is borne through the upper extremity during some activities such as transferring from a wheelchair to bed. A greater than average palmar tilt of the distal radius may also limit the E. (2)

The flexor carpi radialis and ulnaris contribute the most to wrist F. The strongest is the flexor carpi ulnaris as it gains some power by encasing the pisiform bone and using it as a sesamoid bone to increase its mechanical advantage and reduce overall tension on the tendon. (1) This makes the flexor carpi ulnaris muscle the strongest of all wrist muscles. (4)

The primary flexors and extensors (Table 3) combine to perform the movements ulnar and radial deviation. There is a large difference between radial and ulnar deviation; primarily because of the ulnar tilt of the distal radius, the ulnar deviation is normally double radial deviation motion. (2)

Functional ROM: A study was made for finding the ROM of the wrist needed to perform 24 different ADLs. (5) It tested a total of 40 subjects (20 women and 20 men). The ADLs included personal care, food preparation, writing, using cooking utensils and tools, etc. The results were that all these important ADL could be performed comfortably

using 40° of flexion and extension each, 10° of radial deviation and 30° of ulnar deviation. These functional ranges were approximately 70% of the subjects' maximal ROM.

## 2.4 Hand joints

The hand functions as the primary effector organ of the upper extremity for support, manipulation and prehension. (2) A large number of joints are required to move this extensive motion capability of the hand. Joints included are; the carpometacarpal (CMC), the intermetacarpal, metacarpophalangeal (MCP), and the interphalangeal (IP) joints.

In literature, the fingers are usually referred to as digits one to five, with first being the thumb. (4)

The **CMC joint** of the thumb, which is a union between the trapezium and the first metacarpal, is a saddle joint therefore most of the movement occurs here. For the other 4 fingers the CMC joints are regarded as gliding joints therefore offer little movement between them. The movements are very restricted at the 2<sup>nd</sup> and 3<sup>rd</sup> CMC joints but increases to allow as much as 10-30° F and E at the CMC joints of the 4<sup>th</sup> and 5<sup>th</sup> digits. There's also a concave transverse arch across the metacarpals of the fingers similar to that of the carpals. This arch facilitates the gripping potential of the hand. All CMC joints are surrounded by joint capsules, which are built up by dorsal, ventral and interosseous CMC ligaments.(1,4)

The thumb sits at an angle of 60-80° to the arch of the hand and has a wide range of functional movements (ROM can be seen in Table 4). One of which are that the thumb can touch each of the fingers in the movement of opposition (OPP) which is very important in all gripping and prehension tasks.

The **MCP joints** are condyloid joints (thumb is an exception) between the rounded distal heads of the metacarpals and the concave proximal ends of the phalanges. They allow movement in 2 planes; flexion-extension and abduction-adduction (ABD-ADD). Each joint is well reinforced on the dorsal side by the dorsal hood of the fingers, on the palmar side by the palmar plates that span the joint and on the sides by collateral ligaments. The MCP joint of the thumb is a hinge joint allowing movement only in 1 plane; flexion-

extension. Close-packed positions of the MCP joints in the fingers are full flexion, and in the thumb is opposition. (1,4)

The **proximal and distal IP joints (PIP and DIP)** of the fingers, and the single IP joint of the thumb are all hinge joints allowing for movement in one plane only (flexion-extension). An articular capsule joined by ventral and collateral ligaments surround each IP joint. Their close-packed position is in full E. (4) There is usually no hyper-E allowed at the IP joints unless an individual has long ligaments that allow E because of joint *laxity*. (1)

Muscles: There is a large number of muscles responsible for the very precise movements of the fingers. As well as the *extrinsic* muscles coming from the elbow region into the hand, there are 7 main *intrinsic* muscles of the hand also. 4 intrinsic muscles act on the thumb and form what is known as the *thenar eminence* and 3 intrinsic muscles act on the little finger and form the *hypothenar eminence*. In Table 4 and 5 are the list of movements produced in the hand and what muscles are involved. (1)

Table 4 - ROM of the thumb joints and the muscles involved (2)

Movement	Muscles involved	ROM from 0°
<b>F</b>	<i>Extrinsic:</i> Flexor pollicis longus. <i>Intrinsic:</i> Flexor pollicis brevis.	MCP: 70° IP: 90°
<b>E</b>	<i>Extrinsic:</i> Extensor pollicis longus (at the MCP + IP), extensor pollicis brevis (at MCP).	MCP: 0-15° IP: 0°
<b>ABD</b>	<i>Extrinsic:</i> Abductor pollicis longus. <i>Intrinsic:</i> Abductor pollicis brevis.	MCP: 50°
<b>ADD</b>	<i>Intrinsic:</i> Adductor pollicis	MCP: 40°
<b>OPP</b>	<i>Intrinsic:</i> Opponens pollicis.	Through a ROM of 90°

Table 5 - ROM of the finger joints and the muscles involved (1)

Movement	Muscles involved	ROM from 0°
<b>F</b>	<i>Extrinsic:</i> Flexor digitorum profundus, flexor digitorum superficialis (digits 2-5). <i>Intrinsic:</i> Lumbricales and interossei (2-5 at MCP joint), flexor digiti minimi (5 <sup>th</sup> )	MCP: 70-90° (least in index finger, most in the little finger) PIP: 110°

	only).	DIP: 90°
<b>E</b>	<i>Extrinsic:</i> Extensor digitorum (2-5), extensor digiti minimi and extensor indicis (5 <sup>th</sup> ). <i>Intrinsic:</i> Lumbricales and interossei (2-5 at the IP joints).	MCP: 25° PIP + DIP: 0°
<b>ABD</b>	<i>Intrinsic:</i> Dorsal interossei (2, 3, 4) and abductor digiti minimi (5 <sup>th</sup> ).	MCP: 20°
<b>ADD</b>	<i>Intrinsic:</i> Palmar interossei (2, 4, 5) and dorsal interossei (3 <sup>rd</sup> ).	MCP: 20°
<b>OPP</b>	<i>Intrinsic:</i> Opponens digiti minimi (5 <sup>th</sup> ).	Terminal ROM is touching the thumb.

There are approximately 39 muscles that work the wrist and hand and none of them work alone. Most of the muscles that act on the digits and wrist are *extrinsic* muscles. The extrinsic muscles provide strength and dexterity without adding bulk to the hand.(1)

There are bands of fibrous tissue running transversely across the distal forearm and wrist, these are called **retinacula**. The flexor and extensor retinacula in the palmar and dorsal wrist area hold the long tendons of the extrinsic muscles in place during movement. (1) The extrinsic muscles of the hand are more than twice as strong as the strongest extrinsic extensor muscles. (4)

Movement characteristics: In reference to Table 4, most muscles acting on the thumb are the intrinsic ones that make up the thenar eminence. The primary function of the thenar is to position the thumb in varying amounts of OPP, usually to facilitate grasping. OPP is a combination of ABD, F and IR at the CMC joint of the thumb. The adductor pollicis is the dominant muscle at this joint and it produces the greatest combination of F and ADD torque, which is applied in many activities in pinching or such like closing a pair of scissors. (2)

Finger F, as seen above, is primarily done by the actions of flexor digitorum profundus and flexor digitorum superficialis (muscles originating from media epicondyle of humerus). The flexor digitorum profundus can't independently flex each finger therefore

F of the middle, ring and little fingers occur together as their tendons all arise from a common tendon and muscle. However, there is a separation of the muscle and tendon for the index finger, allowing it to flex the index finger independently. The flexor digitorum superficialis can flex each finger independently. The fingers can normally flex independently at the PIP joints but not at the DIP joints. F at the MCP joints (for 2-5 digits) are produced by lumbricales and the interossei (intrinsic muscles in the palm). They also produce E at the IP joints as they attach to fibrous extensor hoods running the lengths of the dorsal surfaces of the fingers. Therefore, to achieve full F at the MCP, PIP and DIP joints, the long finger flexors must override the extension component of the lumbricales and interossei (this is made easier if the tension is taken off by wrist E). (1)

Finger E is primarily done by the extensor digitorum (a muscle originating from the lateral epicondyle of humerus). It enters the hand as 4 tendon slips that branch off at the MCP articulations. The tendons create **a main slip** that inserts into the extensor hood and **2 collateral slips** that connect into adjacent fingers. The extensor hood wraps around the dorsal surface of the phalanges and runs the total length of the finger to the distal phalanx. Because the lumbricales and interossei connect into this hood, their actions are facilitated as the extensor digitorum contracts, applying tension to the extensor hood and stretching these muscles. (1)

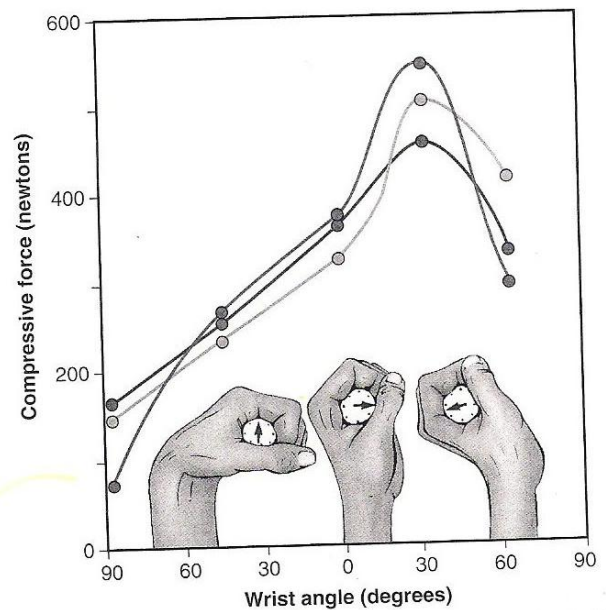
The muscles of dorsal interossei (between the metacarpals) connect to the lateral sides of digits 2 and 4 and to both sides of digit 3. Therefore ABD of fingers is performed by this muscle for digits 2-4. The little finger, digit 5, is abducted by the abductor digiti minimi. The 3 palmar interossei, lie on the medial sides of digits 2,4 and 5 and they perform ADD of the fingers back together. The middle finger is adducted by dorsal interossei. (2)

Besides the extrinsic muscles, there are intrinsic muscles that provide movements of the little finger which make up the hypothenar. The common function of the hypothenar is to raise and “cup” the ulnar border of the hand. This deepens the transverse arch to enhance finger contact with held objects. The abductor digiti minimi can spread the small finger for greater control in grasping. The opponens digiti minimi, another important muscle, rotates the 5<sup>th</sup> MCP joint towards the middle digit. (2)

## Wrist extensor activity while making a fist (2)

2 important roles of wrist extensor muscles are in making a fist or producing a strong grip. The extrinsic finger flexor muscles possess a significant internal moment arm as wrist flexors, therefore as they contract to flex the fingers, they produce a simultaneous wrist F torque. The extensor muscles must counterbalance this torque to block the wrist F tendency so in this manner the wrist extensors maintain the optimal length of the finger flexors to effectively flex the fingers.

When a strong grip is applied to an object, the wrist extensors hold the wrist in a position of 30-35° E and about 5° ulnar deviation. This position optimizes the length-tension relationship of the extrinsic finger flexors (Picture 4). If the wrist is in F, the grip strength is reduced significantly because the finger flexors can't generate enough force as they are functioning at an extremely shortened length respective to their length-tension curve. Also, the overstretched finger extensors in that position creates a passive extensor torque at the fingers which reduce grip strength further.



Picture 4 - Compression forces produced in 3 different wrist positions (2)

A similar mechanism occurs in finger extension when opening the hand. The greatest resistance to complete extension of the fingers is not from gravity, but from the viscoelastic resistance generated by the stretching of the extrinsic finger flexors. Activation of wrist flexor muscles normally accompanies finger extension, especially when it's performed quickly. Therefore F of the wrist helps maintain the optimal length of the extensor digitorum during active finger extension.

## 2.5 Prehension

Strength of the hand and fingers is usually associated with grip strength. Prehension, describes the ability of fingers and thumb to grasp, often for holding, securing and picking up objects. Most forms of prehension are described as *grip*, in where all the digits are used, or as a *pinch*, in where primarily the thumb and index finger are used. Most forms fall into one of the following types:

- 1) *Power grip*, is used when a large force and stability are needed e.x. holding a hammer. The power grip requires strong forces in the finger flexors and the intrinsic muscles, especially of the 4<sup>th</sup> and 5<sup>th</sup> digits, and the thumb adductors and flexors.
- 2) *The precision grip* is used when control or delicate action is needed (i.e. high level of exactness with low force) e.x. holding a pencil. The thumb is usually slightly in ABD and the fingers are also slightly in F. This grip usually uses the thumb and one or more fingers to add force of grip security.
- 3) *The power (key) pinch* is used when large forces are needed to hold an object between the thumb and the lateral border of the index finger. The adductor pollicis and the 1<sup>st</sup> dorsal interossei are the primary muscles working in this grip.
- 4) *The precision pinch* provides fine control to objects held between the thumb and index finger (without high power). This can be done in many ways such as tip-to-tip (especially for small objects) or pulp-to-pulp which provides a greater surface area for contact for bigger objects and a stronger force (40% stronger (1)).
- 5) *The hook grip*, is formed by partially flexed DIP and PIP joints of the fingers and doesn't involve the thumb. It's often used for long periods of time in a static manner e.x. carrying groceries or luggage straps. The flexor digitorum profundus muscle usually provides the force in this grip. (2)

## 2.6 Bone – Mechanism of Injury

*Fracture* of a bone – occurs when an applied load exceeds the bone's ability to withstand the force. The *fracture resistance* of bone is determined by, 1) the material properties of bone as a tissue and 2) structural properties of bone as an organ. It's influenced by the complex interaction of viscoelastic characteristics (e.g. strain rate), bone geometry (e.g. cross sectional dimensions), anisotropic effects (e.g. micro-structural orientation with respect to the loading direction), and bone porosity.

Fractures may occur in response to a single, large magnitude loading, as occurs in collisions (acute loading). Alternately, they may also result from repeated application of low magnitude forces (chronic loading) (e.g. stress fractures).

The risk of a fracture also depends on the type of bone being loaded. Cortical (compact) bone, because of its relatively low porosity (i.e. high density), is generally more fracture resistant than less-dense trabecular (cancellous) bone. (6)

### **Classification of fractures according to the mechanism of injury:**

A fracture at the specific site of force application is termed a direct injury. Indirect injuries can arise from force transmission through other tissues (e.g. avulsion fractures).

Different fracture patterns occur by different loading modes. For example, loading the bone in *tension*, results in a **transverse fracture**. Crushing forces result in **comminuted fractures**. Torsional forces results in **spiral fractures**. A combination of axial compression and angulation (bending) gives both a **transverse** fracture (in the convex side) **and an oblique fracture**. (6,7)

Many injuries occur to the hand as a result of absorbing a blunt force. Injuries of this type in the wrist region are usually associated with a fall, forcing the wrist into extreme hyper-E or F. Extreme hyper-E is the most common injury which can result in; sprain of the wrist ligaments, strain in the wrist muscles, fracture of the scaphoid (70%), other carpals (30%), fracture of distal radius (Colles) or dislocations. The **Colles** fracture is the **most frequently** fractured areas of the body because the bone is not dense and the force of the fall is absorbed by the radius. (1)

## 2.7 Colles' Fracture Etiology and Epidemiology

The most common type of distal radius fracture is the Colles-type fracture. It's usually a *linear transverse* fracture of the distal radius within 2.5cm of the wrist with a dorsal angulation of the distal fragment. It usually occurs from a fall on an outstretched hand.(7,8)

This type of fracture may occur in a young and elderly population. However there's a higher incidence in middle-aged to elderly women (about 40 years and over), as they tend to be more unstable with ambulation and have a high risk of falling, and there's often a precedent history of osteoporosis. Epidemics of fractures occur in periods of snow and ice, resulting in considerable demand on accident and emergency departments. (9)

**Mechanism of injury:** The most frequent injury for this fracture occurs when the hand and arm are extended and placed down to prevent a fall. The wrist is often in hyper-E, and the blunt force impacted on the wrist upon contact with the floor is an intense point of contact. This fracture may also be caused by anything forcing the wrist into hyper-E as the density of the bone is very low in general. The actual type of injury depends on the position of the wrist on impact and the magnitude and direction of the force on impact. When a fall occurs and the outstretched hand has the wrist in a 40°- 90° DF, a Colles' fracture occurs. A fracture of the ulnar styloid in a Colles' fracture results from the force through an intact triangular fibrocartilage complex (*avulsion fracture*). (10)

**Classification:** There are quite a few classification system's used for the assessment of a Colles' fracture. The most known is Frykman's classification and is described below in Table – with an illustrated view of the classification (Picture 5).

Table 6 - Frykman's Classification of Colles' fracture (10)

Type	Fracture
I	Extra-articular radial fracture
II	Extra-articular radial fracture with ulnar fracture
III	Intra-articular fracture of radiocarpal joint
IV	Intra-articular fracture of radiocarpal joint

	with ulnar fracture
V	Fracture of the radioulnar joint
VI	Fracture into the radioulnar joint with an ulnar fracture
VII	Intra-articular fracture involving radiocarpal & radioulnar joint
VIII	Intra-articular fracture involving radiocarpal & radioulnar joint with an ulnar fracture

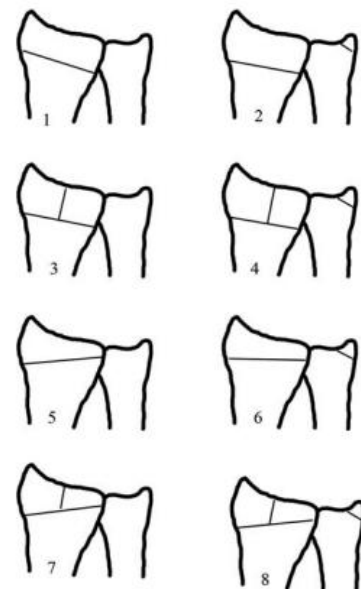
Frykman's classification is on the basis of if there's an intra-articular involvement with or without an ulna styloid fracture. (10)

**Deformities:** The force impact fractures the radius through the cancellous bone of the metaphysis. With great violence, the anterior periosteum tears, and the distal fragment tilts into anterior angulation with loss of the normal 5° forward tilt of the joint surface. With greater force still there is a dorsal displacement of the distal fragment. The deformity in Colles is referred

to as '**dinner fork**' deformity.

In the AP plane, a small lateral component of the force of impact causes lateral displacement of the distal fragment (radially). The distal fragment is attached to the ulnar styloid therefore may avulse the ulnar styloid. Sometimes the fibrocartilage is torn also. In either case, there may be disruption of the inferior radioulnar joint. (8)

**Treatment:** The main goals are to achieve anatomical alignment of the fracture and maintaining it until the fracture heals, and also maintaining the innervations of the nerves supplying motion and sensation to the extremity. When the fracture is put in a cast, x-rays are taken every week to make sure the fracture is not displaced again (which would require re-reduction).



Picture 5 - Frykman's classification of Colles' fracture. (23)

Colles' fractures that are not displaced or noncomminuted are usually managed with a splint. Sometimes percutaneous pinning is used when traction is needed in reduction. If the fracture is comminuted and can't be reduced then external fixation methods are used. If the fracture is severely unstable and comminuted then methods using open reduction and internal fixation are used. (10)

After reduction, the wrist is usually plastered in full pronation, ulnar deviation and slight palmar flexion. The plaster is usually removed 5-6 weeks later. (8)

Colles' fracture in the elderly have traditionally been managed by closed reduction and plaster splinting. However this fracture has a tendency to redisplace and remanipulation is usually attempted. A study showed that **the functional outcome** from two groups; one where external fixation was used to maintain the reduced fracture and another where plaster splinting was used and required remanipulation during cast treatment at least once, did **not** show a significant difference to patients who are 60 years of age and older as they have low functional demands. Both groups showed excellent or good results in their functional outcomes. (11)

**Main complications:** There may *be persistant malunion and deformity* after the fracture is healed; prominence of the distal radius from a radial drift of the fragment, or bony absorption at the fracture site may lead to prominence of the distal ulna as well. These deformities are usually pain free but there may be local tenderness and a reduced supination ROM. Persistent but uncomplicated dinner-fork deformity may also be present but doesn't cause much functional disturbance except a slight reduction in palmar flexion.

A delayed *rupture of extensor pollicis longus*; this may follow the fracture due to attrition of the muscle tendon from roughness at the fracture site, or by lack of blood supply to it. Spontaneous recovery may occur and disability is usually slight.

*Persistant stiffness* with restrictive movements; is not uncommon, even after prolonged physiotherapy. However it's usually not severe enough to affect limb function as there are compensatory (trick) movements are developed by the elbow, shoulder and trunk (e.g. in case of loss of full supination).

*Carpal tunnel syndrome*; may occur following the fracture. Parasthesia in the median nerve distribution is usually the main presenting symptom. More likely to occur if the wrist was in a position of more than 20° (8) PF in the splint or cast. (8,9)

## 2.8 Rehabilitation for Colles' Fractures

**Assessing the need for rehabilitation:** At about 7 weeks post-injury, the decision for further rehab and physiotherapy is based on: 1) Finger movements lack of 'tuck in', 2) Grip strength *marked* weakness, 3) Wrist movements – initially the restriction of palmar flexion is normal but if however there's a total ROM loss in all directions then physiotherapy is advisable. 4) Functional requirements – because of patient's occupation or domestic needs. (8)

The biomechanical and chemical events that occur during fracture healing provide the underlying foundation for the rehabilitation program following a fracture of the distal radius as it helps guide the therapist to the loads that can be placed across the fracture site. Some factors determine the mechanical environment of a healing fracture such as rigidity of selected fixation, fracture configuration, accuracy of reduction and the amount and type of loading at the fracture gap. (12) Fracture healing sequence is usually divided into four stages and those are: (12,13)

- 1) **Inflammation** (1-7 days after injury): There's a fracture hematoma formation, and inflammatory exudates from the ruptured vessels. The fragment in this phase is freely moveable.
- 2) **Soft callus** (3 weeks): Formation of a callus is a mass of repair tissue consisting of collagen fibers and cartilage that bridge the broken ends of the bone. The fragment is here aren't freely moveable and there's enough stability to prevent shortening.
- 3) **Hard callus formation** (3-4 months): Fibrocartilage conversion into spongy bone (bony callus). This lasts until the fragments are united firmly by new bone.
- 4) **Remodelling phase** (few months-several years): Compact bone replaces spongy bone. Thickened areas on the surface of the bone remains as evidence of a healed fracture.(12)

At the time of soft callus formation (3-4 weeks), the fracture is immobilized to limit unwanted motion or excessive forces to prevent shortening, angulation and

displacement. After 8 weeks, during hard callus formation, the fracture has united clinically therefore progressive loading using light strengthening and dynamic exercises may be implemented in the rehabilitation. However, fractures which are comminuted are more unstable therefore have slower paces of fracture site loading during rehabilitation. (12)

All gripping or lifting forces in rehabilitation start after there is sufficient stability of the healing fracture as there are large forces transmitted across the distal radius during power gripping. (12) However, grip strengthening exercises are not to be done too late and an early course for recovery of grip strength is needed. A study in Sweden showed that after two years, patient's who had the injury did not recovery full grip strength on their injured side in comparison to their non-injured side. It also showed that the subjects with their non-dominant side injured, had significantly weaker (more than 20%) grip strength than their dominant side therefore it is also important to identify hand dominance. (14)

According to the sources (12,15,16) from case reports and rehabilitation protocols, there is a **common sequence** for **treatment of Colles' fractures**:

After the removal of the cast, physiotherapy begins immediately with **examination** of the wrist. The examination consists of palpation for local tenderness, tissues surrounding the fracture and tonicity or trophy changes of the muscles. It is then followed by ROM examination to determine the most restricted movements present and where pain is present. Observation of the hand for abnormal colouring, deformities and the edema is also important. (16)

**Controlling of edema and ROM exercises** are the first line of treatment for the physiotherapist. (16) Edema present is the cause of many restrictions and if it is severe it is treated aggressively by means of elevation, finger flexion, sometimes dynamic splints, cryotherapy, contrast bath methods, massage techniques and/or hydrotherapy. All these methods redistribute the fluid to areas with lower pressure and allows the skin to lie closer to the joints of the fingers making it easier to perform ROM exercises of the hand. (12) The ROM exercises are initially done passively and actively with no means of resistance and usually start at the fingers then move onto the wrist motions. Many Colles' fractures do very well simply with regular end range exercise practice and do not need more sophisticated treatments. The physiotherapist checks any restrictions in shoulder and elbow movement then records the forearm rotations, supination and pronation, which

are important functionally. The most common restricted movements are wrist extension and elbow supination. Some programs use dynamic splints for up to 2 weeks after cast removal to assist with daily activities and functional movements, however the patient should be told the risk of prolonged immobilization if the splints are used for too long. (16)

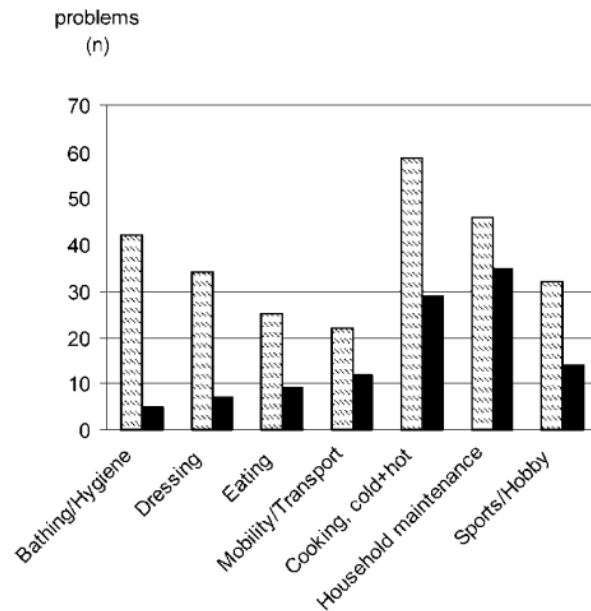
**Joint mobilization** techniques are used traditionally especially when the ROM exercises fail to effectively gain the ROM back alone. Accessory movements can be performed to the inferior radio-ulnar joint to help P and S, and to the RCJ (wrist) and midcarpal joint. They are done either gently or vigorously at the end-range to push against the restrictions within the joints (manipulation). (16)

During increasing mobility, a program of **strengthening the injured extremity** is also introduced. Strengthening the wrist occurs with a gradual increase in functional activities and isometric exercises. In addition to exercises for the wrist, routines were also developed for the finger intrinsics, elbow and shoulder. Patients who present post-Colles' fracture tend to guard the entire upper extremity as a means of protecting the wrist. By introducing basic active and strengthening exercises for the entire limb, disuse atrophy and stiffness due to immobilization will be avoided. (15) Joining a hand class can instruct the patient in practicing the large variety of small movements that can facilitate intrinsic muscles of the hand. Also, exercises use repetitive work at pieces of apparatus (soft balls, theraputty, rubber bands) to strengthen the hand to turning, twisting, pulling, grasping and fine work. This can move on to working with weights or increase of functional activities (e.x. writing, typing, cooking). (16)

As a patient progresses through their program, the physiotherapist should **regularly monitor** patient progress and note changes in; ROM, strength, degree of edema and level of pain and disability. If the symptoms remain the same for a long period of time, the patient should consider referring back to a doctor for a check-up. (15) After approximately 10 weeks of physiotherapy, there are satisfactory and effective results that can then be achieved from a home program in an uncomplicated Colles' fracture. (12)

## Activity limitations during the early stages of rehabilitation of Colles' (17)

A clinical study assessed the main performance problems associated with Colles' fracture during rehabilitation. The assessment was performed 1 and 5 weeks after cast removal. The subjects were 33 women (ages 51-57) treated with closed reduction and plaster cast after a Colles' fracture. It showed that the main problems on 1 week after cast removal were in self-care activities such as bathing, eating and shopping, while the main problems after the 5<sup>th</sup> week were in productivity activities like cooking and housework (refer to Picture 6). The problems with leisure activities such as hobbies remained the same. However the reduction of performance problems in total by the 5<sup>th</sup> week was 57%. By the 5<sup>th</sup> week, it



Picture 6 - Number of problems in the performance of activities following cast removal in 33 female patients. After 1 week (light) and after 5 weeks (dark) (17)

showed that patient's with improved ROM, strength, dexterity may either; perform tasks in a normal manner, become accustomed to the way they're performing, or may compensate and find easier ways to perform some activities. The main subjective problems were pain, poor grip strength and the problems with some productive activities.

The study shows the importance of patient's being admitted into **occupational therapy** as part of their rehabilitation. According to Dekkers (17), **85%** of these patients had finished their occupational therapy successfully within 12 weeks.

### **3 Special part**

#### **3.1 Methodology**

I carried off my practice at the hospital Centrum Léčby Pohybového Aparátu Vysočany (C.L.P.A.), Prague, from 17.1.2011 to 4.2.2011. The physiotherapy department in the hospital specializes mostly in orthopaedic and sports physiotherapy. The patient's are most commonly after a surgery or an injury and range from ages 18-60. The department contains separate ambulances for approximately 6 physiotherapists, electrotherapy rooms equipped with ultra-sound machines, magnetotherapy, laser therapy and electrical stimulation, hydrotherapy area equipped with variety of baths for extremities and whole body, and a fitness gym equipped with modern aerobic machines, strengthening machines, exercise balls and a large variety of senso-motoric equipment.

My patient presented with a state post a Colles' fracture after cast removal. Initial kinesiological examination was conducted, followed by 10 sessions of therapy including a final kinesiological examination at the end.

My clinical practice was under the supervision of Mgr. Zaher El Ali who was present during all the procedures for control. My patient was also informed about the process before the therapy and the work has been approved by the **Ethics Committee** of the Faculty of Physical Education and Sport – Charles University, Prague (Approval number – **041/2011**).

### 3.2 Anamnesis

Examined person: C.R., M

Year of birth: 1942

Diagnosis: Post Colles' wrist fracture (left); **S52.6**

Family: nil

Personal: No serious or chronic medical illnesses.

15 years ago – patella fracture from a fall on a slippery stair (right knee)

10 years ago – 5<sup>th</sup> metacarpal fracture (right hand) from another fall, no treatment and still has limitations in movement

Pharmacology: nil.

Social: Lives alone in a pension house. Spends around 10 hours per week teaching English to private students. Injury does **not** affect his social activities.

Work: Retired.

Abuses: Drinks alcohol only socially.

Allergies: He has no allergies that he knows of.

Other: He is right-handed.

Previous rehabilitation:

Undergone rehabilitation for his patellar fracture 15 years ago, for several continuous months. It included physical therapy modalities, exercises and mobilisation. Results and healing were successful.

Indication to rehabilitation:

Orthopaedic doctor prescription includes: Kinesiological examination, soft tissue techniques and mobilisation (10x), hydrotherapy under 35°C for 15 minutes (10x), PIR techniques to shortened muscles and strengthening exercises of weak muscles (10x) and magnet therapy for 25 minutes, pulsed current (10x).

Medical documentation:

X-ray results (02.12.2010) from first day of injury: Patient arrives after injury from a fall. Pain upon palpation and deformation along with swelling upon observation. X-ray showed a comminuted fracture of distal radius and styloid process of ulna (left wrist). Closed reposition was made.

X-ray results (09.12.2010), control: Showed slight movement of distal fragment out of place. Re-repositioning was made.

Differential Consideration:

- 1 – Swelling and pain: Due to the fracture and removal of the cast
- 2- Stiffness in all hand and wrist joints: Residual stiffness remains after the injury and from the immobilisation from the cast.
- 3- Limited range of motion: Especially for supination and flexion and extension of the hand which are most expected in a Colles fracture. Swelling also plays a big role in restricted range of motion.
- 4- Shortened and tight muscles: That of the flexors of the wrist, as it has been fixated by hard cast in palmar flexion and ulnar deviation. And of flexors of the fingers.
- 5- Weakened muscles: Specifically extensors of the wrist and fingers and hypotrophy of the whole arm is to be expected.
- 6- Deformity: Commonly the ‘dinner-fork’ deformity associated with the Colles fracture (from dorsal displacement of the distal radius).
- 7- Loss of sensation: Mainly from the swelling present that can directly affect the sensation of the hand (especially the deep sensation).

### 3.3 Initial Kinesiologic Examination

18.1.2011

Present state:

Height: 200cm

Weight: 77kg

BMI: 19.3

Patient came in to the hospital on 2<sup>nd</sup> December 2010 following his injury. Whilst walking in the city, he slipped on ice on an outstretched hand. X-ray results showed a Colles fracture (report under Medical Documentation) and a soft cast was placed around it. The soft cast was replaced by a hard cast (Paris plaster) 3 days later (5<sup>th</sup> December 2010) with his wrist in flexion. It was removed about 6 weeks later on 14<sup>th</sup> January 2011.

Subjectively the patient says he feels no pain but the movements are uncomfortable from stiffness. There is barely any grip available but he is able to do independent activities such as putting clothes on and cooking but it just takes much longer than usual, using mostly his right hand. His main complaints are the slowness of activities, uncomfortable sleeping pattern (sometimes wakes up finding his hand in a painful position) and the loss of range of motion. The hand is very swollen (see Picture 7 in Supplement) and the temperature and colour around the fracture site is physiological to that of the healing process. The skin around the hand is extremely dry due to the patient having it wrapped in a bandage for four days.

- Posture evaluation

*Static* Posterior view – normal base width, more lateral loading on feet, winging of scapulas but more pronounced on the right side, slight elevation of left shoulder giving asymmetry and **slight left elbow F**, hypertrophy of paravertebral muscles on the right side. Lateral pelvic tilt (PSIS and iliac crest are higher on the left side).

Lateral view - typical lordo-kyphotic posture, protracted shoulders with a forward head position, **arms are pronated and in front of thigh**.

Anterior view – slight pronation of feet, left shoulder more elevated than the right with more elbow flexion, position of both **arms are in front of the body** and lay on thighs,

umbilical is in neutral position, asymmetry in trophy of arms (left arm looks hypotrophic in comparison). Lateral pelvic tilt (ASIS higher on the right side).

- Gait evaluation

In walking, there were noticeable thumping sounds from the feet. Most of the lower extremity movement comes from flexion of the knees. Length and width of steps are equal and normal. There was no sign of trunk synkinesis and no rotation of the trunk. Patient walks with a forward head position and **no arm swing synkinesis** (left arm swings in a longer arc).

- Basic Movement Patterns (*Liebenson* (18))

Shoulder Abduction - trapezius (ipsilateral) activates first in both left and right shoulder abduction. Result is an altered movement pattern.

Neck flexion – neck was flexed by superficial neck flexors primarily followed by deep neck flexors. Result is an altered movement pattern.

- Palpation

Table 7 – Initial palpation using scale of atonia-hypotonia-normal-hypertonia

Group of Muscles	Right	*Left
<i>Elbow</i> Flexors	hypertonia	hypertonia
Extensors	normal tonicity	hypotonia
<i>Wrist</i> Flexors	hypertonia	hypertonia with TrPs
Extensors	hypertonia	hypotonia

- Anthropometry

Table 8 - Initial anthropometric measurements of upper extremities

Upper Extremities	Right (cm)	*Left (cm)
CIRCUM; Upper arm	26	24
Forearm	25	24.5
Axilla	46	42

Elbow	27	26
Wrist	<b>19</b>	<b>22</b>
Metacarpals	20	22
LENGTH; Whole arm	90	89
Upper arm	41	39
Lower arm	31	30
Hand	23.5	23.5

- Range of Motion (Goniometry)

Table 9 - Initial active and passive ROM of shoulder (SFTR method)

<b><u>Shoulder (in sitting)</u></b>	<b>Right°</b>	<b>*Left°</b>
Active ROM	S 50-0-155	S 55-0-140 (with difficulty)
	F 175-0-0	F 170-0-0
	T 95-0-15	T 90-0-30
	Rf 60-0-60	Rf 60-0-40
Passive ROM	S 50-0-130	S 50-0-125
	F 185-0-0	F 185-0-0
	T 95-0-40	T 90-0-50
	Rf 60-0-65	Rf 60-0-50

Table 10 - Initial active and passive ROM of elbow (SFTR method)

<b><u>Elbow</u></b>	<b>Right°</b>	<b>*Left°</b>
Active ROM	S 0-0-150	S 0-0-160
	R 85-0-90	R <b>5-0-80</b>
Passive ROM	S 0-0-155	S 0-0-165
	R 90-0-90	R <b>15-0-90</b>

Table 11 - Initial active and passive ROM of wrist (SFTR method)

<b><u>Wrist</u></b>	<b>Right°</b>	<b>*Left°</b>
Active ROM	S 60-0-85	S <b>5-0-20</b>
	F 40-0-35	F <b>5-0-5</b>
Passive ROM	S 70-0-95	S <b>10-0-40 (hard barrier)</b>

	F 45-0-35	F <b>5-0-15 (with pain at the end)</b>
--	-----------	--

Metacarpophalangeal and interphalangeal joints examined only orientationally – On the right hand, movements in all directions physiological: MCP S 90-0°, IP S 100-0° and the patient was able to make a close fist, open and spread the fingers apart and oppose the thumb to the little finger. On the left hand, **extension was not possible** in any of the fingers and patient was **unable to perform a closed fist** (MCP S 45-0°, IP S 30-0°) or **spread the fingers apart fully**. Patient was only able to **oppose the thumb to the index** finger (see Picture 8 in Supplement).

- Muscle Length tests (19)

Table 12 - Muscle length tests using Janda shortness scale (0 - no shortness, 1 - moderate, 2 - marked shortness)

Muscle	Shortness Scale	
	Right	Left
Trapezius	1	2
Levator Scapulae	1	1
Pectoralis Minor	2 (hard type barrier)	2 (hard type barrier)
Medial Rotators	0	0
Lateral Rotators	0	2
Supinators	0	0
Pronators	0	2 (hard type barrier)

- Muscle Strength tests (*Kendal*)

Table 13 - Muscle strength testing using Kendal's grading system (19)

Muscle	Grade for Right	Grade for Left
Adductor pollicis	5	3+
Abductor pollicis brevis	5	3+
Abductor pollicis longus	4+	3+
Palmaris longus	5	2+
Flexor carpi radialis	4	2+
Flexor carpi ulnaris	4	3-
Extensor carpi radialis	5	<b>2</b>
Extensor carpi ulnaris	5	<b>2</b>
Flexor pollicis longus	5	3+
Flexor pollicis brevis	5	3+
Extensor pollicis longus	5	4
Extensor digitorum	5	4
Flexor digitorum superficialis	5	<b>2+</b>
Flexor digitorum profundus	5	<b>2+</b>
Pronator teres	5	4
Pronator quadratus	4	4-
Supinator + biceps	5	2+
Supinator	5	<b>2</b>
Biceps + brachialis	5	4
Brachioradialis	5	4
Lumbricales (orientational using paper hold)	Was able to hold it upright + firmly	Was able to hold it upright but with difficulty keeping it

- Neurological examination

**Reflexes:** Right arm – biceps, triceps, wrist flexor reflexes were present and physiological

Left arm – reflexes were also present except for the wrist flexor (because of the swelling present, impossible to find muscle tendons)

**Superficial sensation:** Dermatome Th1 – equal in both arms

Dermatome C5 – equal in both arms

Dermatome C6 – **heightened sensation in left** arm, more tingly feeling.

Dermatome C7 – heightened sensation in left arm

Dermatome C8 – almost equal in both arms, feels slightly different in the left.

**Subjectively**, the patient overall feels the sensation is obviously different on the left arm over the swollen areas of the hand.

**Deep sensation:** Position sense – by placing one hand of the patient in a certain position and allowing him to copy it using the other; okay in both arms.

Movement position sense – (“up” or “down”) 1-1.5 second delay to answer correctly in both arms but more delayed on the left.

- Joint Play examination (*Lewit* (20))

**IP joints (PIP, DIP):** Right hand – present joint play in all directions

Left – present joint play in rotation, but restricted in dorsopalmar and laterolateral directions.

**MCP joints:** Right – present in all directions, except a slight restriction on 3<sup>rd</sup> finger in dorsal direction.

Left – Minimal joint play in all directions, mostly on the index and middle fingers.

**Metacarpal heads (dorsopalmar):** Right – present in all

Left – little joint play, especially in dorsal direction. Most restricted was the index finger.

**CMC joint of thumb (dorsopalmar):** Right – present

Left – Present in dorsal direction, little joint play in palmar direction.

**RCJ: In dorsal direction;** Right – present, Left – very restricted.

**Proximal row in radial direction;** Right – little restricted, Left – restricted.

**ICJ: Distal row in dorsopalmar;** Right – present, Left – very restricted with slight uncomfortable feeling.

**Carpal bones against one another in dorsopalmar;** Right – all bones have present joint play, Left – Capitate joint play very minimal and painful, but the rest have present joint play.

**DRUJ (dorsopalmar):** Right – present, Left – very restricted, blocked in palmar direction.

**PRUJ (dorsoventral):** Right – present, Left – minimal joint play in ventral direction.

Summary of initial examination:

According to the initial kinesiologic examination, the patient has results which are typical and expected of his particular wrist fracture. From the aspection results, his left wrist is in a very swollen state due to the healing process and also subjectively feels very stiff. His left arm is slightly elevated at the shoulder and flexed at the elbow, and also minimized arm swing in gait which already showed an adapted way of the patient holding his arm because of the injury as he tries to keep it as still as possible during movement. In comparison with the right arm, the left arm is generally more in hypotrophy and decreased in mass which can be seen in the differences of circumference specifically of upper arm. The circumferences of the wrist and metacarpals show the extent of swelling present in the left hand (about 2cm differences).

Upon palpation, the muscles of the left arm were generally in hypotonicity and hypotrophy when compared to the right and as expected the right arm was hypertonic because of the overload and compensation placed on it since the injury. According to the ROM tests, the most affected movements are towards supination, wrist movements in all directions especially dorsal flexion and flexion of the finger joints as the patient is unable to perform a closed fist. The restrictions are mostly of hard type barrier (even seen in the muscle length tests performed) and match accordingly to the results of the joint play examination as most joints around the wrist and in the hand are very stiff and restricted in all directions, specifically the metacarpal heads, the radiocarpal joint and the intercarpal joints.

The muscle strength tests show that there is a slight loss of strength in general in the left arm, however overall the strength of the muscles are in good condition but instead can't complete the full range of motion because of the restrictions therefore it is more restricted than weak. The patient finds it difficult to hold some positions in the partial range and fatigues easily. From the neurological perspective, there is an obvious differences in sensation between the left and right hands as there are areas of more

sensitivity on the left hand which may be due to the swelling present. The deep sensation (position sense) is also more affected on the left hand but can also be an expected decrease from the swelling.

### **3.4 Short-term and Long-term Physiotherapy Plan**

#### **Short-term Physiotherapy Plan**

To decrease the swelling present from the injury, stretching and releasing shortened muscles/tissues, mobilize restricted joint movements present, increasing restricted ROM (actively and passively), strengthening of weaker muscles, increase proprioception of upper limbs and advise on regular ergonomic changes and exercises

#### **Long-term Physiotherapy Plan**

To maintain all the improvements made, stabilization of the shoulder and scapula positions, increase proprioceptive sensation in both upper and lower limbs to increase balance, correction of posture and gait as a whole – eliminating asymmetry and imbalances, and continuation of autotherapy.

### 3.5 Therapy Progress

#### Day to day therapy

**Date:** 18.1.2011

**Current status:** *Subjective* – First day of therapy for the patient. He feels little pain around the fracture site. Main complaint is the swelling present and the restricted hand movements especially in ADL such as dressing.

*Objective* – (See Initial Kinesiological Examination) Patient has great limitations in ROM especially in wrist movements and finger flexion. Movements are without pain and the patient subjectively feels that it is from stiffness.

**Objective of today's unit:** To perform all initial examinations to form a base for the patient's progress and collect information necessary to form an appropriate therapy plan.

#### **Therapy applied:**

Hydrotherapy by immersing left wrist, under 35°C in a massage tub for 15 minutes

Mobilization of IP joints in all directions (dorsopalmar, lateral, rotation)

Mobilization of MCP heads in dorsopalmar direction

Mobilization of CMC joint of the thumb in dorsopalmar direction

Mobilization of the RCJ in dorsal direction on radial and ulnar sides

Mobilization of the RCJ in radial direction

Mobilization of the ICJ in palmar direction

Mobilization of all carpal bones by 'shearing'

(All mobilizations are by *Lewit* (20), and done on the **left** hand)

Gentle passive movements and assisted-active movements of finger motions into F and E, wrist E, F, circumduction, P and S (x5 each direction)

Magnet therapy with pulsed current for 20 minutes

#### **Results:**

Patient feels more comfort in between the joints after mobilization techniques. There was a very slight increase in finger movements but no change in wrist movements.

#### **Self-therapy:**

Advice given on how to reduce swelling by means of elevation of the arm above shoulder level when sitting and lying at home with an ice compression and repeated finger movements, several times a day. Patient had very dry dead skin therefore moisturizing the area was also recommended.

**Date:** 19.1.2011

**Current status:** *Subjective* – Doesn't feel much change overnight but felt a positive outcome from following the self-therapy advice.

*Objective* – The skin around the site looks healthier. There is still a large amount of swelling however the colouring of the hand is better.

**Objective of today's unit:** Release tightness in shortened muscles and tissues, release joint restrictions and continue with ROM exercises.

**Therapy applied:**

Additions: PIR of supinator (x3) (20)

PIR for flexors and extensors of the wrist (x3 each) (20)

Same as previous therapy applied (18.1.2011) however also adding finger ROM exercises whilst hand was immersed in the massage tub at the beginning of the therapy.

**Results:**

Patient feels more comfort again especially after the hydrotherapy. The ROM increased slightly after PIR of the flexors and supinator. Minimal change was seen in wrist extension.

**Self-therapy:**

To keep aggressively treating the swelling as advised before. In addition, to try hot and cold contrast bath method (immerse in cold for 1 minute, then immediately in hot for around 4 minutes and repeating the cycle 3x) using the shower head whilst bathing at home to help reduce the swelling.

**Date:** 21.1.2011

**Current status:** *Subjective* – Feels that the swelling has slightly decreased and that the self-therapy methods are working. He also finds it easier to dress himself (i.e. unbuttoning and buttoning shirts) and is taking a shorter time doing so than previously.

*Objective* – Functional finger flexion is increased slightly and patient is able to oppose the thumb more towards the middle finger.

**Objective of today's unit:** Further releasing of joint restrictions, relaxing tightened muscles and to facilitate lymphatic drainage by massage to help reduce swelling.

**Therapy applied:**

Same as previous therapy applied (19.1.2011).

Additions: Soft ball gripping exercises (3-4 minutes)

Classical massage techniques of the whole arm (15 minutes)

**Results:**

Patient was very relaxed after the therapy session, especially during the classical massage. ROM of supinator slightly increased again (however less than 5) and in wrist PF, but still no change in wrist E (hard barrier felt).

**Self-therapy:**

To continue with already given advise from previous session over the weekend as much as possible. Patient was also advised on performing active ROM exercises at home at least every 2-3 hours, sets of 5 reps each direction in all joints. Self PIR techniques for supinators, pronators and wrist extensors and flexors were shown to patient, to do several times a day.

**Date:** 24.1.2011

**Current status:** *Subjective* – The patient was in a good mood and feeling optimistic about his progression as he can see his own improvements when performing ADL.

*Objective* – The swelling has reduced a lot in comparison to the first therapy session especially around the finger joints. Thumb opposition of the patient reaches towards the middle finger now. Finger flexion increased slightly but most improved movements are from the thumb.

**Objective of today's unit:** Releasing of restricted tissue and emphasizing on different functional exercises using different materials.

**Therapy applied:**

Same as previous therapy applied (19.1.2011).

Additions: Mobilization of the MCP heads by dorsal and palmar fans. (20)

Soft tissue techniques using the soft ball (from the fingers to the elbow) for 5-8 minutes

Finger ROM exercises: each one individually into F and E, ABD and ADD, finger F and circumduction using a tennis ball as support, and soft ball gripping (10 minutes)

Shoulder, elbow and wrist ROM exercises: passing a ball from one hand to the other while emphasizing on rotation, fixating hand on table palm down and going into E until tolerated, and ROM of shoulder in all directions. (5 minutes)

**Results:**

The patient enjoyed the implementation of the new exercises and is with increased motivation in performing them. The ROM of the thumb is the largest improvement with increase of opposition towards the ring finger.

**Self-therapy:**

All the exercises that have been done in the session are to be done at home at least 3 times a day after contrast bath method. Patient was advised on trying to perform more tasks at home using the injured hand such as cooking, pressing on cleaning sprays to increase strength and to place a hammer in the hand whilst supinating and pronating.

**Date:** 25.1.2011

**Current status:** *Subjective* –The patient feels that he is using his hand more in ADL, even in activities such as turning the page using the injured hand. He also feels that the 4<sup>th</sup> and 5<sup>th</sup> finger have more strength than the rest. He is also able to change clothes faster and more effectively.

*Objective* – The swelling has reduced remarkably compared to the first session. The bony parts of the hand became more visible. There is subjectively an increase in grip strength which correlates with the diminished swelling and increased finger F.

**Objective of today's unit:** To use the entire upper limb in resistive or progressive movement and to strengthen muscles of the forearm, using PNF.

**Therapy applied:**

Same as in initial therapy session (18.1.2011).

All the finger, wrist and elbow ROM exercises applied in the previous therapy (24.1.2011)

PNF technique, by *Kabat*, in lying position – 1<sup>st</sup> diagonal flexion, repeated contractions for biceps muscle (x6) (21)

**Results:**

The patient found the PNF technique challenging but has good outcomes. Even though the biceps and shoulder area were emphasized, there was facilitation of the forearm muscles during the diagonals.

**Self-therapy:**

Patient was recommended to buy dough or putty as an exercise to the intrinsic hand muscles. Also to start doing more resistive exercises using different material such as a rolled up sock for gripping and a rubber band around the phalanges for resistance in E of the fingers.

**Date:** 27.1.2011 to 31.1.2011

**Current status:** *Subjective* – The patient felt a large improvement over the course of those therapies. He accustomed to the PNF technique really well and begins to see it working. He continues his self-therapy daily and regularly. He's happy about the improvements in the ROM, and increase in grip strength however started to feel a little pain with movement in fracture site.

*Objective* – The swelling has nearly fully diminished, when comparing to the healthy side. The flow of movement of the whole arm is improving with the PNF techniques. ROM of wrist in all directions improved but is still low in wrist E. He is able to oppose the thumb now fully towards the 5<sup>th</sup> finger.

**Objective of today's unit:** To use the entire upper limb in resistive or progressive movement and to strengthen and relax muscles of the forearm, using PNF.

**Therapy applied:**

Same as initial therapy session (18.1.2011) **without** the ROM exercises.

PNF technique, by *Kabat*, in lying position – 1<sup>st</sup> diagonal flexion and extension patterns - Repeated contractions for strengthening biceps muscle (x6), Hold-relax for relaxation of supinator and wrist extensors (x4), Contract-relax for relaxation of supinator and wrist extensors (x4). (21)

**Results:**

Quick results can be seen after every PNF performance, especially during the relaxation techniques with an increase of ROM into new points of restrictions. There's no pain during the movements but subjectively just *overload* pain after the therapy.

**Self-therapy:**

Patient was advised on taking more breaks in between all the self-therapy exercises as he might be starting to overload his tissues. Self-PIR techniques were encouraged more than anything else.

**Date:** 2.2.2011

**Current status:** *Subjective* – Patient feels much better today with no pain at all. He is able to perform almost all his ADL's with the same speed pre-injury but his main concern is full recovery of the ROM in the fingers and wrist.

*Objective* – Finger F available is sufficient enough to hold moderate to large-sized objects but still not enough to create a closed fist position. The grip strength and the

muscles of the forearm are in good strength but are almost all reaching a hard-type barrier when passively moved.

**Objective of today's unit:** To overcome the barriers in the ROM by relaxation of hypertonic muscles, PNF and introducing a senso-motoric part to the therapy.

**Therapy applied:**

PIR technique for the supinator (x5) and wrist extensors (x5) (20)

PNF technique, by *Kabat*, in lying position – 1<sup>st</sup> diagonal flexion and extension patterns - Repeated contractions for strengthening biceps muscle (x6), Hold-relax for relaxation of supinator and wrist extensors (x4), Contract-relax for relaxation of supinator and wrist extensors (x4). (21)

Sensomotoric training of the upper extremity using the propriomed (8 minutes)

Kinesiotaping on the dorsal part of the forearm, for reduction of swelling and facilitation of wrist extensors.

**Results:**

Quick results can be seen after every PNF performance, especially during the relaxation techniques with an increase of ROM into new points of restrictions. There's no pain during the movements but subjectively just *overload* pain after the therapy. The patient enjoys the use of the propriomed as he finds it new and challenging and there shows a good improvement in stability of the wrist after some time of using it.

**Self-therapy:**

Sitting and standing posture correction advise given, especially with correcting position of the head, neck and arms alongside the body.

**Date:** 4.2.2011

**Current status:** *Subjective* – Patient feels the same as in previous session. Also, he feels that the kinesiotaping helped as movements feel easier, more supported and stronger.

*Objective* – (See Final Kinesiological Examination) Patient has improved in all aspects of the therapy goal, however, there remains a large restriction for wrist E and elbow supination which may require more time.

**Objective of today's unit:** Final kinesiological examinations to mark progress and to give final advice on how to continue with the therapy.

**Therapy applied:**

Same as previous therapy applied (2.2.2011) **with out** kinesiotaping as the patient still had the previous taping on.

**Results:**

Patient performed all the PNF diagonals with a greater force against the resistance which may be due to increase of strength or decrease of apprehension to move the limb due to the taping. However, ROM increased following the relaxation techniques even further therefore therapy was successful.

**Self-therapy:**

To continue performing slow, gentle passive ROM to the joints around the fracture site. To continue with isometric and resistive exercises to the shoulder girdle and upper arm muscles. He was also advised to follow as many of the exercises as possible to regain hand functions, especially with the use of putty. He was educated about postural control likewise the previous session and also about the importance of not overloading the fracture site with high gripping forces and exercises which may affect the healing.

### 3.6 Final Kinesiologic Examination

4.02.2011

- Posture evaluation

*Static* Posterior view – normal base width, more lateral loading on feet, winging of scapulas, shoulders are level but slightly more hypertrophy of trapezius muscle on the left side, trunk rotated in a clockwise direction slightly. Iliac crest and PSIS are slightly higher on the left side.

Lateral view - typical lordo-kyphotic posture, protracted shoulders with a forward head position, **arms are by the patient's** sides with an **extended elbow**.

Anterior view – slight pronation of feet, position of the arms are more by the side, umbilical is in neutral position, asymmetry in trophy of arms (left arm looks hypotrophic in comparison). ASIS is higher on the left side.

- Gait evaluation

Noticeable thumping sounds from the feet. Most of the lower extremity movement comes from flexion of the knees. Length and width of steps are equal and normal. Patient leans to his right side more whilst walking. Minimal trunk synkinesis with little rotation but arm swing synkinesis present.

- Basic Movement Patterns (18)

Shoulder Abduction - trapezius (ipsilateral) activates first in both left and right shoulder abduction. Result is an altered movement pattern.

Neck flexion – neck was flexed by superficial neck flexors primarily followed by deep neck flexors. Result is an altered movement pattern.

- Palpation

Table 14 - Final palpation results using scale of atonia-hypotonia-normal-hypertonia

Group of Muscles	Right	*Left
<i>Elbow</i> Flexors	hypertonia	normal tonicity
Extensors	normal tonicity	normal tonicity
<i>Wrist</i> Flexors	normal tonicity	hypertonia

Extensors	hypertonia	hypotonia
-----------	------------	-----------

- Anthropometry

Table 15 - Final anthropometric measurements of upper extremities

Upper Extremities	Right (cm)	*Left (cm)
CIRCUM; Upper arm	25	<b>24</b>
Forearm	24.5	24
Axilla	<b>45</b>	<b>48</b>
Elbow	26.5	26
Wrist	18.5	<b>20</b>
Metacarpals	20.5	21
LENGTH; Whole arm	90	89
Upper arm	41	39
Lower arm	32	31
Hand	24	23.5

- Range of Motion (Goniometry)

Table 16 - Final active and passive ROM of shoulder (SFTR method)

<u>Shoulder (in sitting)</u>	Right°	*Left°
Active ROM	S 40-0-130	S 45-0-140
	F 175-0-0	F 175-0-0
	T 100-0-50	T 100-0-45
	Rf 60-0-60	Rf 60-0-40
Passive ROM	S 50-0-130	S 55-0-130
	F 185-0-0	F 185-0-0
	T 95-0-50	T 90-0-55
	Rf 60-0-60	Rf 60-0-50

Table 17 - Final active and passive ROM of elbow (SFTR method)

<u>Elbow</u>	Right°	*Left°
Active ROM	S 0-0-150	S 0-0-150
	R 85-0-90	R <b>15-0-90</b>
Passive ROM	S 0-0-160	S 0-0-160
	R 90-0-100	R <b>20-0-90</b>

Table 18 - Final active and passive ROM of wrist (SFTR method)

<u>Wrist</u>	Right°	*Left°
Active ROM	S 70-0-85	S <b>15-0-20</b>
	F 40-0-35	F <b>15-0-20</b>
Passive ROM	S 90-0-95	S <b>30-0-60</b>
	F 45-0-35	F <b>10-0-30</b>

Metacarpophalangeal and interphalangeal joints examined only orientationally – On the right hand, movements in all directions physiological: MCP S 90-0, IP S 100-0 and the patient was able to make a closed fist, open and spread the fingers apart and oppose the thumb to the little finger. On the left hand, extension was possible in all the fingers and patient was **unable to perform a closed fist** (MCP S 60-0, IP S 95-0), but fingers were **close to the palm**. He was able to **adduct and then spread the fingers apart fully**. Patient **was able to oppose the thumb to touch the 5<sup>th</sup> finger** (see Picture 10 in Supplement).

- Muscle Length tests (19)

Table 19 - Final muscle length tests using Janda's shortness scale (0 - no shortness, 1 - moderate, 2 - marked shortness)

Muscle	Shortness Scale	
	Right	Left
Trapezius	1	1
Levator Scapulae	1	1
Pectoralis Minor	2 (hard type barrier)	2 (hard type barrier)

Medial Rotators	0	0
Lateral Rotators	0	1
Supinators	0	<b>0</b>
Pronators	0	<b>1 (hard type barrier)</b>

- Muscle Strength tests (19)

Table 20 - Final muscle strength testing using Kendal's grading system

Muscle	Grade for Right	Grade for Left
Adductor pollicis	5	5
Abductor pollicis brevis	5	5
Abductor pollicis longus	4+	4
Palmaris longus	5	4
Flexor carpi radialis	4	<b>3+</b>
Flexor carpi ulnaris	4	<b>3+</b>
Extensor carpi radialis	5	<b>2+</b>
Extensor carpi ulnaris	5	<b>2+</b>
Flexor pollicis longus	5	4
Flexor pollicis brevis	5	4
Extensor pollicis longus	5	5
Extensor digitorum	5	5
Flexor digitorum superficialis	5	<b>3+</b>
Flexor digitorum profundus	5	<b>3+</b>
Pronator teres	5	4
Pronator quadratus	5	5
Supinator + biceps	5	2+
Supinator	5	<b>2+</b>
Biceps + brachialis	5	4
Brachioradialis	5	5
Lumbricales (orientational using paper hold)	Was able to hold it upright + firmly	Was able to hold it upright and kept it against moderate resistance

- Neurological examination

**Reflexes:** Right arm – biceps, triceps, wrist flexor reflexes were present and physiological

Left arm – reflexes were also **all present**

**Superficial sensation:** Dermatome Th1 – equal in both arms

Dermatome C5 – equal in both arms

Dermatome C6 – equal in both

Dermatome C7 – equal in both

Dermatome C8 – equal in both

**Deep sensation:** Position sense – by placing one hand of the patient in a certain position and allowing him to copy it using the other; **okay in both arms.**

Movement position sense – (“up” or “down”) 1-1.5 second delay to answer correctly when movements are slow but in faster movements the delay is shorter (0.5s on right, little longer in left).

- Joint Play examination (*Lewit*) (18)

**IP joints (PIP, DIP):** Right hand – present joint play in all directions

Left – present joint play in all directions

**MCP joints:** Right – present in all directions

Left – present in all directions, most restricted only in middle finger towards dorsal direction

**Metacarpal heads (dorsopalmar):** Right – present in all

Left – present in all directions. Most restricted was slightly in the index finger in dorso-palmar direction.

**CMC joint of thumb (dorsopalmar):** Right – present

Left – Present in all directions.

**RCJ: In dorsal direction;** Right – present, Left – present

**Proximal row in radial direction;** Right – little restricted, Left – present.

**ICJ: Distal row in dorsopalmar;** Right – present, Left – little restriction towards palmar direction.

**Carpal bones against one another in dorsopalmar;** Right – all bones have present joint play, Left – joint play present in all bones.

**DRUJ (dorsopalmar):** Right – present, Left – present but slightly painful on radial emphasis.

**PRUJ (dorsoventral):** Right – present, Left – present.

Summary of final examination:

The results from the final kinesiological examination show a significant improvement in the patient's wrist. The first one can be seen directly from the posture evaluation, of the changed position of the arm (it lies more by his sides rather than in front of his thighs) and the presence of arm swing during his gait. From the results of palpation, it shows that overall his muscles are less hypertoned and more also in normal trophy in both upper limbs. The anthropometry results are almost the same as in the initial but show a small improvement in the circumference of the wrist and metacarpals which may be due to the reduction of swelling. The ROM results have the most improvements especially in the movements that were most restricted before. Supination in the left hand increased by 15 degrees, dorsal flexion increased by 10 degrees and both ulnar and radial deviation of the wrist increased by about 5 degrees each. The opposition of the thumb towards the 5<sup>th</sup> finger is also a significant improvement as he was unable to properly reach the 2<sup>nd</sup> finger initially. The patient is still unable to perform a closed fist but the range of motion in all the fingers also improved bringing them closer to a fist. The muscles all improved by grades strength wise as the range of motion increased a long with the more strengthened intrinsic hand muscles. The patient is able to move his fingers more freely and withstand more resistance and pressure on them. Subjectively he feels it is because they are less stiff and less swollen (see Picture 9 in Supplement).

### 3.7 Evaluation of the Effect of the Therapy

*Tables of the main changes that improved during the therapy progress*

Evaluation of posture and gait

Table 21 - Posture and gait evaluation

	18.01.2011	4.02.2011
<b>Anterior</b>		
	Position of arms are pronated in front of the body	Arms are by the patient's sides
<b>Lateral</b>		
	Slight flexion of the left elbow	Elbows are more extended
<b>Gait</b>		
	No arm swing present	Arm swing synkinesis present

Evaluation of ROM of the **left** extremity

Table 22 - Main improvements of ROM (Goniometry results and orientational results)

Movement	18.01.2011		4.02.2011	
	Active	Passive	Active	Passive
<b>Elbow S</b>	5°	15°	15°	20°
<b>Elbow P</b>	80°	90°	90°	90°
<b>Wrist E</b>	5°	10°	15°	30°
<b>Wrist F</b>	20°	40°*	20°	60°
<b>Wrist Radial dev.</b>	5°	5°	15°	10°
<b>Wrist Ulnar dev.</b>	5°	15°**	20°	30°

Key: \* = hard barrier, \*\* = with pain

	18.01.2011	4.02.2011
<b>Finger movements</b>		
	E of the fingers wasn't possible	E of the fingers was possible
	Unable to perform closed fist	Unable to perform closed fist but fingers are much closer to the palm
	ABD of fingers is not full ROM	ABD of fingers is full
	OPP of thumb reaches only the index finger.	OPP to thumb reaches the little finger.

Evaluation of muscle length tests of the **left** extremity (19)

Table 23 - Evaluation of muscle length tests using shortness scale by Janda (0 - No shortness, 1 - Moderate, 2 - Marked shortness)

	18.01.2011	4.02.2011
Lateral rotators of the shoulder	2	1
Supinator of the elbow	0	0
Pronators of the elbow	2 with hard barrier	1

Evaluation of muscle strength tests of the **left** extremity (19)

Table 24 - Evaluation of muscle strength tests using Kendal's grading system

	18.01.2011	4.02.2011
Adductor pollicis	3+	5
Abductor pollicis brevis	3+	5
Abductor pollicis longus	3+	4
Flexor carpi radialis	2+	3+
Flexor carpi ulnaris	3-	3+
Extensor carpi radialis	2	2+
Extensor carpi ulnaris	2	2+
Flexor digitorum superficialis	2+	3+
Flexor digitorum profundus	2+	3+
Supinator	2	2+

Evaluation of joint play of the **left** extremity (20)

Table 25 - Evaluation of joint play in the joints of the fingers, wrist and elbow.

IP joints:		
	<b>18.01.2011</b>	<b>4.02.2011</b>
<b>Ventro-dorsal</b>	Restricted	Present
<b>Latero-lateral</b>	Restricted	Present
<b>Rotation</b>	Present	Present
MCP joints:		
<b>Ventro-dorsal</b>	Restricted	Present, but with slight restriction in dorsal.
<b>Latero-lateral</b>	Restricted	Present
<b>Rotation</b>	Restricted	Present
MC heads:		
<b>Ventro-dorsal</b>	Restricted, especially in the index finger	Present in all digits but most restriction is in index finger
CMC joint of thumb:		
<b>Ventro-dorsal</b>	Restricted in ventral	Present
RCJ:		
<b>Dorsal</b>	Blockage (severely restricted)	Present
<b>Radial</b>	Blockage	Present
DRUJ:		
<b>Ventro-dorsal</b>	Blockage in ventral direction mostly	Present, but presents pain <i>with radial emphasis.</i>
PRUJ:		
<b>Ventro-dorsal</b>	Blockage in ventral more.	Present

## Evaluation of palpation results of the **left** extremity

Table 26 - Evaluation of palpatory results of the tonicity of the muscles using. Scale atonia-hypotonia-normal-hypertonia

	<b>18.01.2011</b>	<b>4.02.2011</b>
Elbow Flexors	hypertonic	normal tonicity
Extensors	hypertonic	normal tonicity
Wrist Flexors	hypertonic with TrPs	hypertonic without TrPs
Extensors	hypotonic	hypotonic

## Evaluation of anthropometric results of the **left** extremity

Table 27 - Evaluation of significant anthropometric measurements (cm)

Circumference (cm)	<b>18.01.2011</b>	<b>4.02.2011</b>
Upper arm	24	24
Axilla	42	48
Wrist	22	20

### **Therapy proposal**

Lymphatic drainage massage for effective facilitation of lymph nodes and reduction of swelling.

Sensomotoric training for the lower extremities using 3-point training, wobble boards, posturomeds as a preventive method for risk of falls.

PNF strengthening techniques for scapular muscles for better fixation and correct position.

## **Prognosis**

Given that my patient is a 69 year old male, with low functional demands, he is on the way to a very good prognosis. From the evaluation of the therapy effect and comparisons of results, especially in the ROM and strength of the muscles; with given time and effort in keeping a regular home therapy for his injury he would be capable of achieving the state that he was performing his ADL and other productive activities pre-injury. This is to be said even if his full ROM isn't reached. However there was a great increase in wrist DF, S, radial deviation (all have a 10° difference between the initial and final examination), and ulnar deviation (with a 15° difference) within a short period of time. I find these outcomes most important. The strength of his muscles in general is considerably good for his age and he is in good condition. From the examinations provided, I saw that the strength of his muscles were still there but what was restricting him mostly was the stiffness and hard barriers preventing from going in to full ROM.

As an elderly with low functional demands, grip strength is needed to be sufficient enough for his just his daily and simple activities as he does not participate in hobbies, sports, or activities that require high gripping forces therefore subjectively he is content with his progress. His only complaint is the period of time it will take to regain enough grip strength to at least perform a closed fist position. In my opinion, given his age, reaching that stage will require a long-term therapy of a year or more therefore a program of occupational therapy would suit him best and help him achieve effective results quicker. His motivation and optimism in always following his self-therapy exercises thoroughly are the important factors needed that will help leading him to a successful prognosis.

## 4 Conclusion

When my patient was presented to me, it was his first day of therapy and a few days after his cast removal. He was treated after a slip and fall injury causing a typical Colles' fracture with involvement of the styloid process of the ulna. Given that during my past clinical practices there was always a lack of patients with this type of fracture, even though the incidence of it is very high, therefore I was lucky enough to follow-up on his case from the very beginning.

When he first arrived his wrist was in a very bad but expected condition. He had severe swelling around the fracture site and also above it between all the finger joints. He also had abnormal colouring of his hand, increased temperature, dry dead outer layer skin, residual stiffness in the joints from the cast and he held his arm in a position of slight elbow flexion and had a large apprehension to move it. This was expected due to recent removal of cast after several weeks of immobilization but all his symptoms, especially the swelling, were preventing him from performing simple ADL tasks such as putting clothes on, carrying groceries and feeding which were all important for him as he lives alone. The patient felt lucky that it was his non-dominant hand injured as he was still able to perform other one-handed tasks easily.

At the clinic I was attending, it is usual to receive patients from the orthopaedic department therefore they were specialized with patients post-fractures. The most common procedure that physiotherapists use there are joint mobilizations and manipulation after fractures to help restore ROM and release blockages present to make rehabilitation process faster and quicker. That, in combination with passive and active ROM exercises for the hand and wrist, were my first line of treatment procedure including the reduction of edema. The reduction of edema was the base line to start the rehabilitation process as according to the differential consideration of what to expect after the fracture, it is the cause of most restrictions present and proper rehabilitation can't start without it reducing first.

During the therapy, I added techniques from PNF for strengthening and relaxation of muscles, and PIR techniques for relaxing hypertonicity in some muscles also. The biggest part of the therapy were use of many different materials such as small stones, soft balls, tennis balls, therabands, rubber bands, putty, all in a variation of sizes

and resistances. They helped tremendously in increasing the ROM and also strength of the hand muscles (intrinsic and extrinsic) as the exercises all resembled functional activities and movements that are used every day. All of these therapies resulted in good therapeutic results by the end of the 10 sessions, with some main improvements in ROM, strength of muscles, dexterity of the hand and swelling reduction.

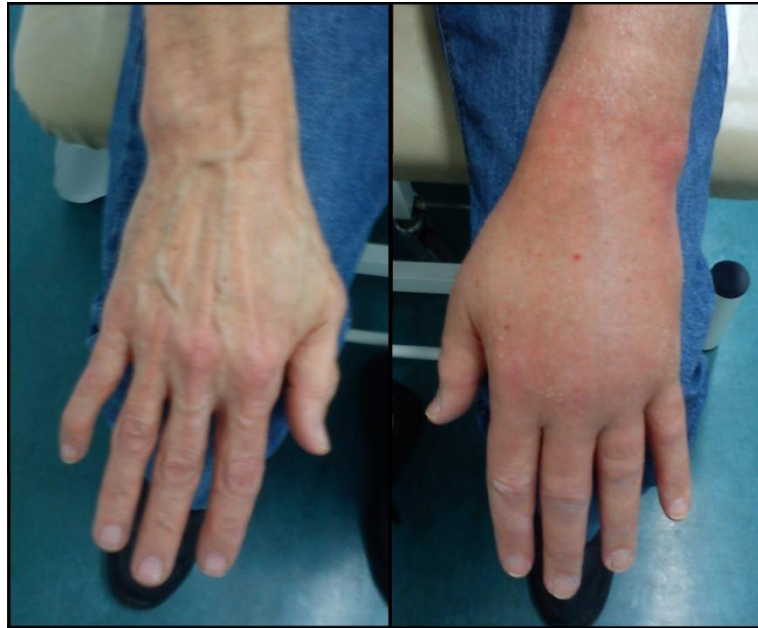## 5 Bibliography

1. **Hamill, J and Knutzen, K M.** *Biomechanical Basis of Human Movement*. 3rd Edition. USA : Lippincott Williams & Wilkins , 2010. 145-110-901-6.
2. **Newmann, D A.** *Kinesiology of Musculoskeletal System*. 2nd Edition. USA : Mosby Inc., 2010. 978-0-323-03-989-5.
3. **Snell, R S.** *Clinical Anatomy by Systems*. USA : Lippincott Williams & Wilkins, 2007. 978-0-7817-9164-9.
4. **Hall, S J.** *Basic Biomechanics*. 2nd Edition. USA : Mosby Inc., 1995. 0-8151-4077-0.
5. *Functional ranges of motion of the wrist joint.* **Ryu, J, et al.** 3, USA : Elsevier Inc. , 1991, The Journal of Hand Surgery , Vol. 16. 10.1016/0363-5023(91)90006-W .
6. **Whiting, W. C. and Zernicke, R. F.** *Biomechanics of Musculoskeletal Injury* . USA : C. Whiting & F. Zernicke , 1998. 0-87322-779-4 .
7. **Greene, W. B.** *Netter's Orthopaedics* . USA : Saunders Elsevier , 2006. 192-900-702-7.
8. **McRae, R.** *Pocketbook of Orthopaedics and Fractures*. 2nd Edition. UK : Elsevier Health Sciences, 2006. 04-431-027-24.
9. *Colles' fracture, Management may cause permanent disability.* **Wadsworth, T. G.** 6744, UK : BMJ Publishing Group, 1990, British Medical Journal, Vol. 301. 10.1136/bmj.3016745.
10. *Colles' fracture Orthopaedic Essentials.* **Altizer, L. L.** 2, USA : Lippincott Williams & Wilkins, 2008, Orthopaedic Nursing, Vol. 27. 0744-6020.
11. *Conservative treatment of redisplaced Colles' fractures in elderly patients older than 60 years old.* **Chang, H. C., et al.** 2, Singapore : World Scientific Publishing Company, 2001, Hand Surgery, Vol. 6. 10.1142/S0218810401000606.
12. *Rehabilitation of Distal Radius Fractures: A biomechanical guide.* **Slutsky, D. J.** 3, USA : Elsevier Saunders, 2005, Hand Clin, Vol. 21. 10.1016/j.hcl.2005.01.004.
13. **Tortora, G. J. and Derrickson, B.** *Principles of Anatomy and Physiology*. 12th Edition. Asia : John Wiley & Sons, 2008. 0470084715.
14. *Recovery of grip strength after Colles' fracture: 2 year prospective study.* **Lagerstrom, C., Nordgren, B. and Rahme, H.** 1, Sweden : SJRM, 1999, Scand J Rehabil Med, Vol. 31. 0036-5505.

15. *Rehabilitation protocol for undisplaced Colles' fractures following cast removal.* **Balsky, S. and Goldford, R. J.** 1, USA : JCCA, 2000, J Can Chiropr Assoc, Vol. 44. PMC2485487.
16. **Smyth, J. B.** Physiotherapy Rehabilitation of Colles' fractures. *EzineArticles*. [Online] January 19, 2009. [Cited: April 1, 2011.] <http://EzineArticles.com/1896192>.
17. *Activities and Impairments in early stages of rehabilitation after Colles' fracture.* **Dekkers, M. K. and Soballe, K.** 11, Denmark : Taylor & Francis, 2004, Disability and Rehabilitation, Vol. 26. 1464-5165.
18. **Liebenson, C.** *Rehabilitation of the Spine.* USA : Lippincott Williams & Wilkins, 2007. 0-7817-2997-1.
19. **Kendal, F. P.** *Muscles testing and function with posture and pain.* USA : Lippincott Williams & Wilkins, 2005. 0-7817-4780-5.
20. **Lewit, K.** *Manipulative therapy in rehabilitation of the locomotor system.* UK : Butterworth-Heinemann, 2000. 0-7506-2964-9.
21. **Adler, S. S., Beckers, D. and Buck, M.** *PNF in Practice: An illustrated guide.* 3rd Edition. Germany : Springer, 2008. 978-3-540-73901-2.
22. *Functional Elbow Range of Motion for Contemporary Tasks.* **Sardelli, M, Tashjian, R Z and MacWilliams, B A.** 5, USA, MA : J Bone Joint Surgery, 2011, Vol. 93. 10.2106/JBJS.I.01633.
23. *Dorsally angulated fractures of the distal radius.* **Deakin, D. E. and Deshmukh, S. C.** 1, UK : SAGE, 2010, Trauma, Vol. 12. 10.1177/1460408609354532.

## 6 Supplement

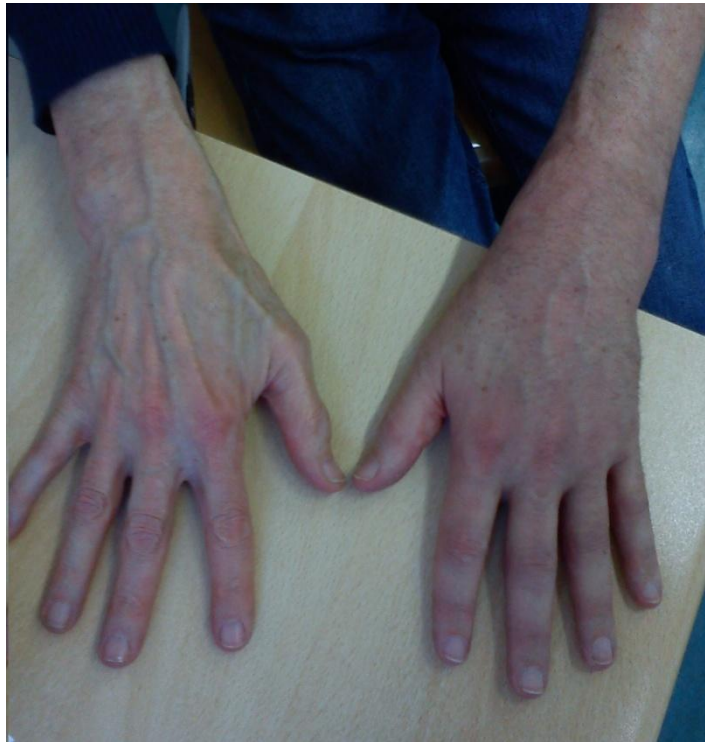### Pictures



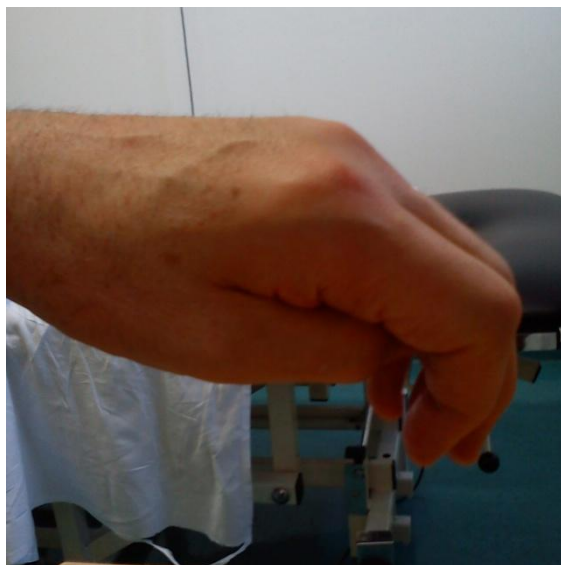Picture 7 - The state of the patient's hands upon initial examination (Left: healthy hand, Right: injured hand)



Picture 8 - (Left hand) Opposition of thumb upon initial examination



Picture 9 - State of the patient's hands upon final examination (Left: healthy hand, Right: injured hand)



Picture 10 - (Left hand) Opposition of the thumb upon final examination

## List of pictures

Picture 1 - Carrying angle (1) _____	9
Picture 2 - Activity requiring arc of elbow motion (22) _____	11
Picture 3 - The bones of the wrist and hand. (4) _____	12
Picture 4 - Compression forces produced in 3 different wrist positions (2) _____	20
Picture 5 - Frykman's classification of Colles' fracture. (23) _____	24
Picture 6 - Number of problems in the performance of activities following cast removal in 33 female patients. After 1 week (light) and after 5 weeks (dark) (17) _____	29
Picture 7 - The state of the patient's hands upon initial examination (Left: healthy hand, Right: injured hand) _____	63
Picture 8 - (Left hand) Opposition of thumb upon initial examination _____	63
Picture 9 - State of the patient's hands upon final examination (Left: healthy hand, Right: injured hand) _____	64
Picture 10 - (Left hand) Opposition of the thumb upon final examination _____	64

## List of tables

Table 1 - ROM at elbow joint and muscles involved (1) .....	8
Table 2 - ROM at the radioulnar joints and muscles involved (1) .....	10
Table 3 - ROM at the wrist joint and the muscles involved (2) .....	14
Table 4 - ROM of the thumb joints and the muscles involved (2) .....	17
Table 5 - ROM of the finger joints and the muscles involved (1) .....	17
Table 6 - Frykman's Classification of Colles' fracture (10) .....	23
Table 7 – Initial palpation using scale of atonia-hypotonia-normal-hypertonia, and atrophy-hypotrophy-normal-hypertrophy .....	34
Table 8 - Initial anthropometric measurements of upper extremities .....	34
Table 9 - Initial active and passive ROM of shoulder (SFTR method) .....	35
Table 10 - Initial active and passive ROM of elbow (SFTR method) .....	35
Table 11 - Initial active and passive ROM of wrist (SFTR method) .....	35
Table 12 - Muscle length tests using Janda shortness scale (0 - no shortness, 1 - moderate, 2 - marked shortness) .....	36
Table 13 - Muscle strength testing using Kendal's grading system (19) .....	37

Table 14 - Final palpation results using scale of atonia-hypotonia-normal-hypertonia and atrophy-hypotrophy-normal-hypertrophy .....	48
Table 15 - Final anthropometric measurements of upper extremities .....	49
Table 16 - Final active and passive ROM of shoulder (SFTR method) .....	49
Table 17 - Final active and passive ROM of elbow (SFTR method) .....	50
Table 18 - Final active and passive ROM of wrist (SFTR method) .....	50
Table 19 - Final muscle length tests using Janda's shortness scale (0 - no shortness, 1 - moderate, 2 - marked shortness) .....	50
Table 20 - Final muscle strength testing using Kendal's grading system .....	51
Table 21 - Posture and gait evaluation .....	54
Table 22 - Main improvements of ROM (Goniometry results and orientational results) .....	54
Table 23 - Evaluation of muscle length tests using shortness scale by Janda (0 - No shortness, 1 - Moderate, 2 - Marked shortness) .....	55
Table 24 - Evaluation of muscle strength tests using Kendal's grading system .....	55
Table 25 - Evaluation of joint play in the joints of the fingers, wrist and elbow. ....	56
Table 26 - Evaluation of palpatory results of the tonicity of the muscles using. Scale atonia-hypotonia-normal-hypertonia .....	57
Table 27 - Evaluation of significant anthropometric measurements (cm) .....	57

## **Abbreviations**

ABD - Abduction

ADD - Adduction

ADL - Activities of daily living

CMC - Carpometacarpal

DIP - Distal interphalangeal

DF - Dorsal flexion

DRUJ - Distal radioulnar joint

E - Extension

F - Flexion

ICJ - Intercarpal joint

IP - Interphalangeal

M CJ - Midcarpal joint

M CP - Metacarpophalangeal

OP P - Opposition

P - Pronation

PI P - Proximal interphalangeal

PI R - Post-isometric relaxation

PF - Palmar flexion

PN F - Proprioceptive neuromuscular facilitation

PR UJ - Proximal radioulnar joint

RC J - Radiocarpal joint

RO M - Range of motion

S - Supination

TrPs - Trigger points



CHARLES UNIVERSITY IN PRAGUE  
 FACULTY OF PHYSICAL EDUCATION AND SPORT  
 José Martího 31, 162 52 Praha 6-Veleslavín  
 tel. +420 2 2017 1111  
 http://www.ftvs.cuni.cz/

### Application for Ethics Board Review

of the research project, doctoral research, master degree research, undergraduate research, involving human subjects

**Project title:** Case study of a patient post Colles wrist (left) fracture

**Nature of the research project:** undergraduate research

**Author** Farah Droubi

**Supervisor** PhDr. Jitka Čemusová, PhD.

**Research project description**

Case study of a physiotherapy treatment plan for a patient after a wrist fracture (Colles, left) will be conducted under the expert supervision of an experienced physiotherapist at the hospital, Centrum léčby pohybového aparátu (CLPA).

No invasive methods will be used. Personal data obtained during the investigation will not be published.

**Informed consent** (attached)

Date: 24.1.2011

Author's signature:

**Faculty of Physical Education and Sport, Charles University in Prague  
 ETHICS BOARD REVIEW**

**Ethics Board members:** Doc. MUDr. Staša Bartůňková, CSc.  
 Prof. Ing. Václav Bunc, CSc.  
 Prof. PhDr. Pavel Slepíčka, DrSc.  
 Doc. MUDr. Jan Heller, CSc.

The Ethics Board at the Faculty of Physical Education and Sport, Charles University, approved the research project.

Approval number: ..... 041 / 2011 .....  
 Date: ..... 31.1.2011 .....

The Ethics Board at the Faculty of Physical Education and Sport, Charles University, reviewed the submitted research project and **found no contradictions with valid principles**, regulations and international guidelines for biomedical research involving human subjects.

**The chief investigator of the project met the necessary requirements for receiving the Ethics Board approval.**

Official school stamp

UNIVERZITA KARLOVA v Praze  
 Fakulta tělesné výchovy a sportu  
 sekretariát děkana  
 José Martího 31, 162 52, Praha 6

Signature, REB Chairman

## INFORMOVANÝ SOUHLAS

V souladu se Zákonem o péči o zdraví lidu (§ 23 odst. 2 zákona č.20/1966 Sb.) a Úmluvou o lidských právech a biomedicíně č. 96/2001, Vás žádám o souhlas k vyšetření a následné terapii. Dále Vás žádám o souhlas k nahlížení do Vaší dokumentace osobou získávající způsobilost k výkonu zdravotnického povolání v rámci praktické výuky a s uveřejněním výsledků terapie v rámci bakalářské práce na FTVS UK. Osobní data v této studii nebudou uvedena.

Dnešního dne jsem byla odborným pracovníkem poučena o plánovaném vyšetření a následné terapii. Prohlašuji a svým dále uvedeným vlastnoručním podpisem potvrzuji, že odborný pracovník, který mi poskytl poučení, mi osobně vysvětlil vše, co je obsahem tohoto písemného informovaného souhlasu, a měla jsem možnost klást mu otázky, na které mi řádně odpověděl.

Prohlašuji, že jsem shora uvedenému poučení plně porozuměla a výslovně souhlasím s provedením vyšetření a následnou terapií.

Souhlasím s nahlížením níže jmenované osoby do mé dokumentace a s uveřejněním výsledků terapie v rámci studie.

Datum:.....

Osoba, která provedla poučení:.....

Podpis osoby, která provedla poučení:.....

Vlastnoruční podpis pacienta /tky:.....